

## Evaluation of percutaneous release of trigger finger

A.S.Ghazy, E.M.Bayoumy and E.E.Ali

Orthopedic surgery, Dept., Faculty of Medicine, Benha Univ., Benha, Egypt

E-mail: drghazy1986@gmail.com

### Abstract

The current study's goal was to determine the effectiveness of a percutaneous approach for evaluating the effects of surgical trigger finger release. During flexion or extension, hypertrophy at the junction of the tendon with the tendon pulley hinders normal forward and backward movement of the tendon beneath the pulley. This results in an abrupt locking of the finger. Many trigger and locking events throughout the day, if accompanied with carpal tunnel release; many trigger fingers in the same or both hands; and, if percutaneous release was persuaded in the patient on the first appointment. After at least one prior corticosteroid injection, the research comprised twenty patients at Benha University Hospital and Zifta general hospital with a total of 23 trigger fingers with chronic symptoms. The trigger fingers of three individuals were found to be on both hands. According to Tanaka et al., the overall outcomes at the conclusion of the trial were outstanding in 17 patients (85%), good in 2 patients (10%), and bad in 1 patient (5%). (5 percent). (95 percent) of the 19 individuals had good outcomes; just one patient had a negative outcome (5 percent). The percutaneous release of trigger finger is a safe, straightforward, and effective alternative to open surgical release, with outcomes that are comparable.

**Keywords:** Trigger finger, percutaneous release.

### 1. Introduction

Hand discomfort and incapacity may result from trigger finger, which is an extremely prevalent ailment. Hand outpatient clinic referrals are also the fourth most frequent [1]. But it isn't only hand surgeons who treat it; rheumatologists, for example, are frequently called in to treat it since it is a secondary symptom of a fundamental systemic ailment [2]. The A1 pulley's proximal edge and the disparity between the flexor tendon's diameter and its sheath at the metacarpal head have been linked to this condition. Recurring trauma may be a factor in this illness, but the underlying cause remains a mystery [3].

It is common for trigger finger to show with popping and locking of the fingers; however, patients may report with discomfort and swelling over the affected flexor sheath, as well as avoidance of finger mobility, if symptoms begin suddenly [4]. An outpatient procedure known as percutaneous trigger finger release is a safe and effective treatment that gives instant relief from symptoms such as discomfort and catching. Before attempting open release on any patient who has trigger finger, it is recommended that the percutaneous method be tried on all of them first [5].

### 2. Patients and methods:

The study was conducted, at Benha University hospital and Zifta general hospital, on 20 patients with a total of 23 trigger fingers with persistent symptoms after at least one previous corticosteroid injection were included in the study. Three patients had two trigger fingers. Case selection was according to:

#### Inclusive criteria

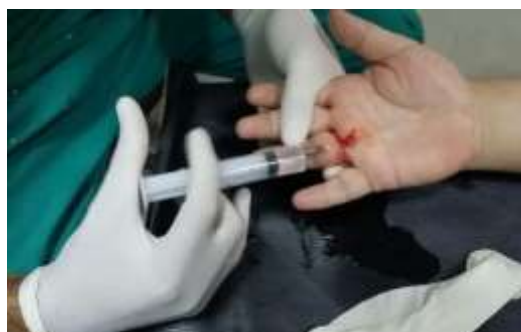History of triggering for at least 3months, failure of previous steroid injection into the flexor sheath at least once, adult patients 16:80 years, all fingers, any medical co morbidity (e.g Diabetes, Rheumatoid arthritis), and multiple fingers affected or association with carpal tunnel syndrome.

#### The exclusion criteria

Recent trauma, rheumatoid disease, loss of follow ups, children <16 years, presence of local infection, and uncontrolled diabetes mellitus.

#### Percutaneous release of trigger finger

Percutaneous release of trigger finger was done after an informed consent was taken from every patient. The palm and affected finger were prepared with antiseptic solution. The release was done under local anesthesia by infiltrating the skin and flexor tendon sheath with 3-5 cm of lidocaine solution.



**Fig. (1)** Local anesthesia infiltration.

### Local anesthesia infiltration

The affected finger was held firmly with the metacarpophalangeal joint hyperextended over a rolled towel throughout the procedure. Hyperextension is essential as it causes the flexor tendon sheath to lie directly under the skin and allows the digital neurovascular bundles to displace to either side and dorsally then the A1 pulley was palpated directly over the metacarpal head. The needle insertion point through the skin is several millimeters distal to the distal palmar crease for the middle, ring and small fingers and the proximal palmar crease for the index finger. The thumb is through the metacarpophalangeal crease.

An 18-gauge needle was introduced percutaneously, perpendicularly through the A1 pulley into the flexor tendon (figure 8). The position of the needle within the flexor tendon was confirmed by asking the patient to actively flexing the finger and observing the motion of the needle. The needle was

then withdrawn from the tendon and the bevel of the needle oriented longitudinally with the longitudinal axis of the tendon. The length of the A1 pulley was incised using the bevel of the needle by a sweeping motion back and forth to score and section the A1 pulley proximal and distal. The loss of a gritty sensation, as the pulley was cut, is to indicate and confirm completion of the release.

### 18-gauge needle is introduced percutaneously perpendicularly.

After percutaneous release, the patient was asked to actively flex and extend the finger several times to confirm complete release of the triggering. If a patient demonstrates continued triggering, the needle was reinserted an additional release performed.

**Assessment:** The results were assessed according to the score rating system during the last examination at 3 months.

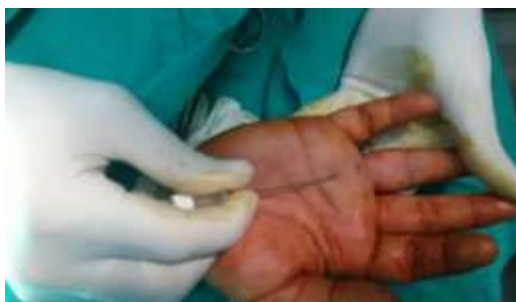

Fig. (2) Procedure of trigger finger release

Table (1) Score rating system to assess trigger finger.

Results	Pain	Activity and patient satisfaction
Excellent	No pain	Return to work or activity Patient satisfied
Good	Pain with heavy use only.	Return to work or activity Patient satisfied
Poor	Pain unchanged	Patient unsatisfied

The results were assessed according to another method used by **Tanaka, et al.** at the end of the follow up period of 3 months.

Table (2) Tanaka et al. method to assess trigger finger:

Results	Symptoms	Points
Excellent	-No symptoms.	1
	OR	
Good	-One of minor symptoms whose score 1 point	2
	-Two of minor symptoms whose score 1 point	
	OR	
Fair	-One of minor symptoms whose score 2 points	3
	-One of minor symptoms whose score 1 point	
	OR	
Poor	-One of minor symptoms whose score 2 points	4
	-Sum of minor symptoms is 4 points.	
	OR	
	-One major symptom.	

**3. Results**

The study was conducted on twenty patients with age ranged from 16 to 80 years old. 14(70%) were female and 6(30%) were male. The duration of symptoms was 10 months or less in 11 (55%) patients, while was more than 10 months in 9 (45%) patients, with mean  $\pm$ S.D was  $10.97 \pm 6.34$ . There were 13 patients without history of medical comorbidities (65%) and 7 patients with history of DM (35%).

The right hand was affected in 14 patients (70%), while the left hand was affected in 6 patients (30%). The dominant hand was affected in 14 patients (70%), while the non-dominant hand was affected in 4 patients (20%) and both hands were affected in multiple finger affection in 2 patients (10%). There were 17 patients

(85%) with only one finger affection and 3 patients (15%) with Multiple finger affection (table 3).

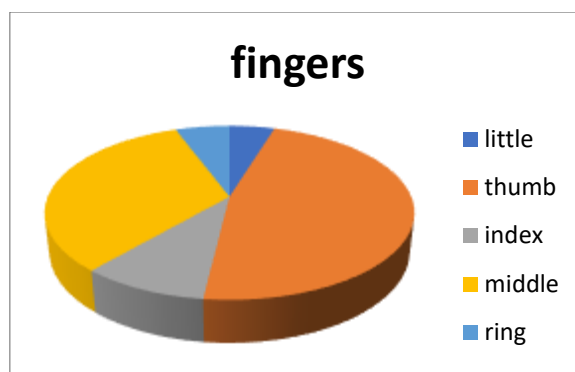
There were 1 patient with triggering (4.3%) in little finger, 2 patients (8.8%) in index finger, 3 patients (13%) in ring finger, 7 patients (30.4%) in middle finger and 10 patients (43.5%) in thumb finger figure (3).

The overall results at the end of the study according to the method used by Tanaka et al. were excellent in 17 patients (85%), good in 2 patients (10%) and poor in 1 patient (5%) figure(4). Also, the results were satisfactory in 19 patients (95%) and unsatisfactory in 1 patient (5%) figure (5).

According to the grade of green's classification there were 1 patient with grade 2, 16 patients with grade 3, and 3 patients with grade 4 table (4).

**Table (3)** Distribution of the studied cases according to multiple finger affection (n=20).

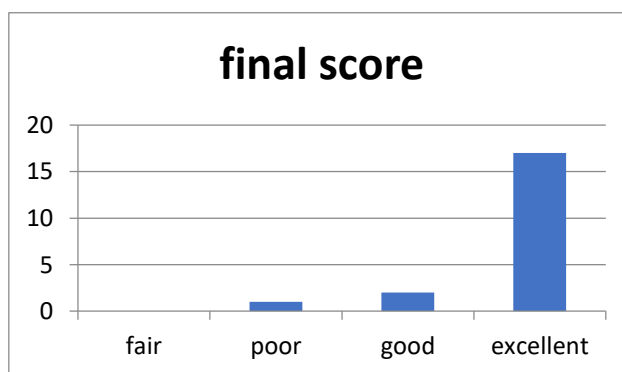
Multiple finger affection	No.	%
No	17	85
Yes	3	15



**Fig. (3)** Distribution of the studied cases according to affected finger (n=23).

**Table (4)** Distribution of the studied cases according to the grade of Green's classification.

Grade	No.	%
Grade II	1	5
Grade III	16	80
Grade IV	3	15
Min. – Max.	2.0 – 4.0	
Median	3.0	



**Fig. (4)** Distribution of the studied cases according to final score (n=20).

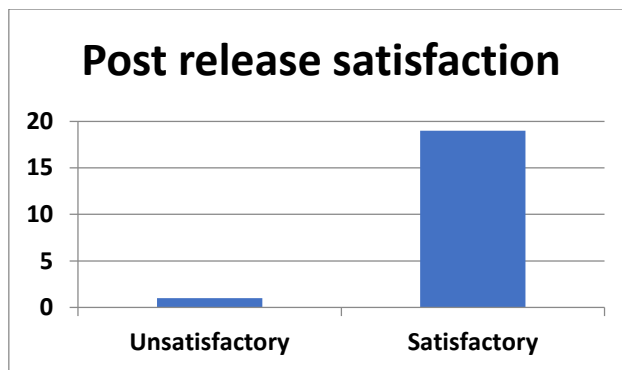


Fig. (5) Distribution of the studied cases according to post-release satisfaction (n=20).

#### 4. Discussion

For individuals who fail to react to conservative treatment, percutaneous trigger finger release and surgery are available choices [6]. In our research, we found Percutaneous release with an 18-gauge needle has been reported to have a 95% success rate, with A1 pulleys entirely freed. Prasad Chaudhari D, et al, found that 81 percent of patients were satisfied with the needle 16 percutaneous technique. Patients were happy and had less pain following treatment with the percutaneous approach after one and three months, according to the findings of this research [7].

Excision of the A1 pulley was not entirely completed by Kumar S et al, which may have contributed to consequences such nerve damage and longitudinal wound scarring. With regard to percutaneous release, a major issue is ensuring that the A1 pulley does not come into contact with the digital nerve. Hyperextensive fingers and precutaneous release using the midway line prevent this from happening [8]. It has been shown that older individuals with diabetes and inflammatory arthritis who are also at risk of delayed wound healing should be treated with percutaneous trigger finger release rather than amputation. Additionally, patients who want to return to their normal routines within a short amount of time should be given preference for this treatment method [9]. There is little risk of complications with the percutaneous trigger finger release procedure.

#### 5. Conclusion

The percutaneous release of trigger finger is a safe, straightforward, and effective alternative to open surgical release, with outcomes that are comparable. An 18-gauge syringe needle, which is readily accessible, is all that is required for the release. In order to avoid the complications of general anaesthesia, this procedure is performed under local anaesthetic. After the release, the hand may be immediately used for activities. It's a simple, quick, and painless office treatment that people like.

#### References

- [1] A.Abdoli, M.Asadian, SH.Banadaky, R.Sarram. A cadaveric assessment of percutaneous trigger finger release with 15° stab knife: its effectiveness and complications. *J Ortho Surg Res.* Dec .vol.16(1),pp.1-6, 2021.
- [2] M.Arumugam, H.Sallehuddin, and F.M.N.Rashdeen. A Clinical Approach to Diagnosing Trigger Wrist. *Indian journal of orthopaedics.*vol. 55,pp.(2):492-497, 2021.
- [3] M.Azizian, H.Bagheri, G.Olyaei. Effects of dry needling on tendon-pulley architecture, pain and hand function in patients with trigger finger: a randomized controlled trial study. *J Phys Ther Sci.*vol.31(4),pp.295–298,2019.
- [4] Bianchi, Stefano, Salvatore Gitto, and Ferdinando Draghi. Ultrasound features of trigger finger: review of the literature. *Journal of Ultrasound in Medicine.*vol.38; 12,pp. 3141-3154, 2019.
- [5] Y.P.Chen, C.Y.Lin, Y.J.Kuo, and O.K.S.Lee. Extracorporeal shock wave therapy in the treatment of trigger finger: A randomized controlled study. *Arch Phys Med Reh,*2021.
- [6] G.Rajeswaran, J.C.Healy, and J.C Lee. Percutaneous Release Procedures: Trigger Finger and Carpal Tunnel. *SeminMusculoskeletRadiol.*vol.20 (5),pp.p.432-440,2016.
- [7] D.Prasad Chaudhari, G.Kanade, S.Kale, VA.Janardhan. Percutaneous trigger finger release or steroid injection-which is better in trigger finger treatment. *Int J Orthop.*vol. 5(3),pp.512–4. 2019
- [8] S.Kumar, K.Muzzafar, I.Tasaduq, A.Bijyal. Results of percutaneous release of stenosing tenosynovitis (trigger finger) using hypodermic needle. *Int J Res Orthop.*vol. 5(4),pp.578, 2019.
- [9] D.Toprak, F.Dogar, B.Kuscu, A.A.Karadeniz, and BilalO. Comperative outcomes of the patients undergoing percutaneous and open trigger finger release. *Medicine.*vol.9,pp. (4): 950-3, 2020.