

## Digital imaging versus computed tomography for evaluation of calcaneal fractures

M.G.Montaser<sup>1</sup>, S.A.E.Abdelsatar<sup>2</sup> and K.A.Abdelkhalik<sup>2</sup>

<sup>1</sup>Orthopedic surgery Dept., Faculty of Medicine, Benha Univ., Benha, Egypt

<sup>2</sup>Radiology, Dept., Faculty of Medicine, Benha Univ., Benha, Egypt

E-Mail: Khalid121@yahoo.com

### Abstract

Background: The first assessment of the calcaneus suspected fractures is performed with conventional radiography. Modern calcaneal fracture classification systems depend mainly on computed tomography (CT) because of its three-dimensional nature, rather than on two-dimensional plain radiography as was used previously. The aim of this study was to assess Digital X ray imaging versus computed tomography for evaluation of calcaneal fractures. Patients and methods: This study was conducted Benha University Hospitals on 30 patients with isolated calcaneal trauma and was diagnosed radiologically by plain x ray and CT to have calcaneal fractures. lateral view images was obtained to measure the Böhler's angle, the angle of Gissane, the inclination angle and the facet height. Each angle was measured by two different interpreters (a senior radiologist and a resident) in order to verify accuracy Results: there was a statistically significant difference between Digital X-ray and CT images finding in Intraarticular Fractures and total fractures. there was a statistically significant difference in (The Böhler's angle , The angle of Gissane and The facet height The angle of Gissane) and no statistically significant difference in (The inclination angle) Conclusion: CT scanning is a valuable non-invasive common technique and has gained use in identifying the diagnosis, classification, and treatment planning of extra-articular and intra-articular calcaneal fractures

**Keywords:** Digital X ray, computed tomography, calcaneal fractures.

### 1. Introduction

The calcaneus is the greatest tarsal bone, and has the function of sustaining the body. Fractures of the calcaneus represent about 1-2% of all fractures and 60% of the tarsal bones fractures [1].

Diagnosis of fracture is based on X-rays radiological studies. Two main landmark of lateral view X-ray are Böhler's and Gissane's angles and the axial view has advantage for evaluation of Varus deformity of the calcaneus and widening of the heel [ 2].

Various measurements (the Böhler's angle, the angle of Gissane, etc.) of calcaneal fractures on lateral radiography images correlate with the fracture type and, hence, the severity of the fracture based on the Sanders classification. So its possible to estimate the prognosis and proper clinical management of intraarticular fractures by observing the digital X-ray radiographs alone. [3]

CT has changed the evaluation of calcaneal fractures because it allows better visualization of subtalar joint [4]. Through MPR and VR reconstruction is possible to assess accurately the fracture lines, dislocation, crushing, the morphology and the involvement of the articular surfaces, allowing to choose the appropriate treatment and have a better prognostic evaluation. The split between intra- and extra-articular fractures is based on the involvement of the subtalar joint [5]

Early diagnosis of fracture facilitates treatment of fracture and may reduce complications. In addition, knowing the best way of diagnosis may decrease economic burden and accelerate proper management of patients. Nowadays, CT-scan is the most reliable tool for diagnosis of calcaneus fracture and CT-scan is more accurate for assessment of fracture. Detecting stress fractures of the calcaneus can be made by Technetium scans and MRI, but it is not appropriate to apply them in the acute setting [6].

The aim of this study was to assess Digital X ray imaging versus computed tomography for evaluation of calcaneal fractures.

### 2. Patients and methods

This was a cross sectional observational study. This study included 30 patients with isolated calcaneal trauma and was diagnosed radiologically to have calcaneal fractures, who were admitted to Benha University hospitals.

Inclusions criteria was Patients with direct isolated calcaneal trauma with agreement to give written consent of both sex and Age >18 years old

Exclusion criteria was Pathological calcaneal fractures , Radiographs and coronal CT scans of bad quality and didn't allow for measurements on the digital computer system and patients with polytraumatic injuries of the lower limbs or severe medical ailments.

All patients were subjected to complete history taking and Radiological assessment calcaneal lateral and axial digital X-rays and conventional CT of the injured foot, Digital X-ray lateral view images was obtained to measure the Böhler's angle, the angle of Gissane, the inclination angle and the facet height. Each angle was measured by two different interpreters (a senior radiologist and a resident) in order to verify accuracy

#### Statistical design

The collected data was tabulated and analyzed by suitable statistical methods using the statistical package for social science (SPSS). Categorical data are expressed as number and percentage. Continuous are expressed as mean and standard deviation (SD). Suitable tests of significance was used. The accepted level of significance in this work is 0.05.

### 3. Results

There mean age of patients was 46 years . and 18 patients (60%) were males and 12 patients (40 %) were female (Table 1)

In our patient population, the two main injury mechanisms were falling from a height (13 patients [43.4%]) and a traffic accident (17 patients [56.6%]). According to Associated injuries in the present study's sample, 16 patients (23.3%) had soft tissue edema , 2 patients (11.1%) had muscle injuries and 3 patints (16.7%) had tendon injuries (Table 2)

6 patients (20%) had multiple fractures. Of which 4 patients (66.7%) had ankle and calcaneal fractures, two patients (33.3%) had calcaneal and talar fractures. Intra-articular fracture types, frequency and percentage

according to Sanders classification are showed in table (3)

In the term of comparison between Digital X-ray and CT images finding according to sensitivity of diagnosis of fructures, there was a statistically significant difference between Digital X-ray and CT images finding in Intraarticular Fractures and total fructures (Table 4)

In the term of Comparison between extraarticular and intraarticular fractures measurements by CT, there was a a statistically significant difference in (The Bo`hler's angle , The angle of Gissane and The facet height The angle of Gissane) and no statistically significant difference in (The inclination angle). (Table 5)

**Table (1)** General characteristic.

Age (years)	Mean $\pm$ SD	46 $\pm$ 8.1
Gender	Males n (%)	18 (60)
	Females n (%)	12 (40)
Total		18

**Table (2)** Associated injuries.

Associated injuries	Soft tissue edema n (%)	16 (23.3)
	Muscle injuries n (%)	2 (11.1)
	Tendon injuries n (%)	3 (16.7)
Total		18 (60%)

**Table (3)** Intra-articular fracture types, frequency and percentage according to Sanders classification.

Sanders types	Type I : Nondisplaced posterior facet (regardless of number of fracture lines) n (%)	2 (11.1)
	Type II : One fracture line in the posterior facet (two fragments) n (%)	3 (16.7)
	Type III Two fracture lines in the posterior facet (three fragments) n (%)	7 (38.9)
	Type IV Comminuted fracture in posterior facet (four or more fragments) n (%)	6 (33.3)
Total		18 (60%)

**Table (4)** comparison between Digital X-ray and CT images finding according to sensitivity of diagnosis of fructures.

Type of fructures	Type of radiological method	True positive	False negative	P
Extraarticular fractures	CT	12	0	0.47
	Digital X-ray	10	2	
Intraarticular fractures	CT	18	0	0.045
	Digital X-ray	13	5	
Total	CT	30	0	0.010
	Digital X-ray	23	7	

**Table (5)** Comparison between extraarticular and intraarticular fractures measurements by CT.

	Extraarticular fractures	Intraarticular fractures	p
The Bo`hler's angle	38.9 $\pm$ 9.48	24.43 $\pm$ 15.91	0.0001
The angle of Gissane	112.8 $\pm$ 8.16	121.45 $\pm$ 13.92	0.012
The facet height (mm)	46.1 $\pm$ 3.51	42.33 $\pm$ 6.09	0.013
The inclination angle	18.6 $\pm$ 3.6	18.22 $\pm$ 5.58	0.782

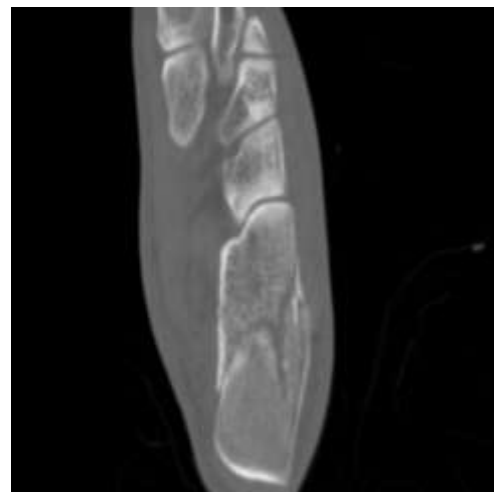
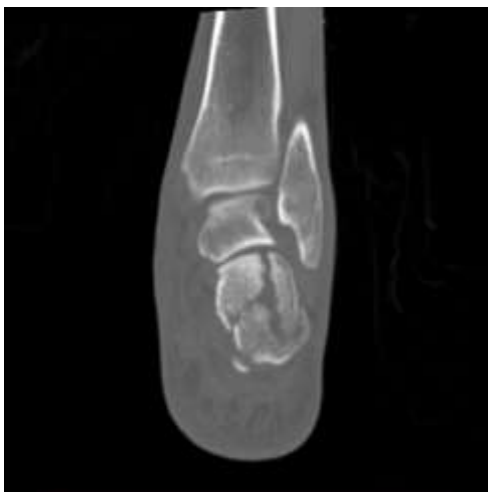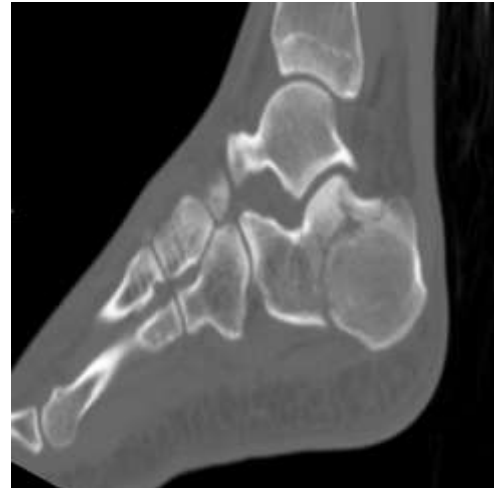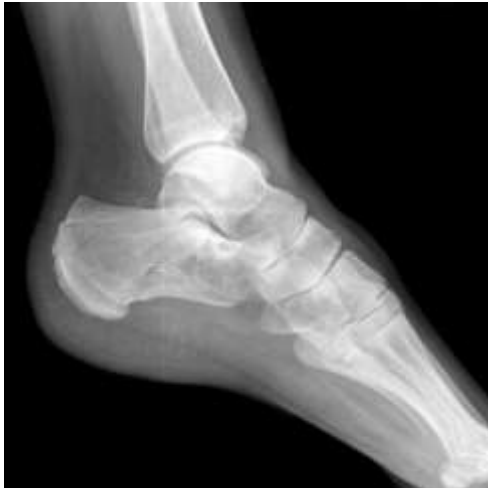**Case (1):**

- 40-years old female patient presented after a fall from a height.
- Her plain X rays and CT scan showed an intraarticular fracture ( one primary fracture line that courses through the lateral aspect of the posterior facet)
- Sanders type IIa

(A) Plain X ray

(B) CT scan

(C) 3D reconstruction CT

**4. Discussion**

The ankle is one of the most commonly injured joints. Although injuries to the lower extremity exert significant influence on long-term outcome after discharge from the acute care facility, they are often missed or underestimated during the initial care for poly-traumatized patients [7].

As the ankle and the rearfoot are positioned along the load line of the lower limbs, the force that primarily contributes to the fracture mechanism is the axial load. The biomechanics of the foot and ankle have been studied with the experimentation of a high axial load. Fracture of the calcaneus was the most frequent fracture shown in cadaveric studies. [8]

The development of multi-detector CT (MDCT) has transformed CT from a simple, cross-sectional imaging

technique to an advanced, three-dimensional (3-D) imaging modality, enabling excellent 3-D displays. Its advantages over its predecessor, single-slice helical CT, are isotropic imaging capability and ease of interpretation [9]

Analysis of recent calcaneal fracture studies leads to a diagnostic approach geared to the choice of treatment and improvement of patient outcomes. In particular, the classification of Harroongroj et al could change the diagnostic approach to this type of lesion, having a direct correlation with choice of treatment and the quality of fracture reduction. [10]

Further studies have shown correlation of calcaneal fractures with fractures of other bone structures or soft tissue impairment (peroneal tendon dislocation or increased risk of developing peroneus brevis and

peroneus longus tendons injuries). In this context, the measurement of the calcaneotalar ratio plays an important role, providing the possibility of performing a targeted surgery to the actual size of the heel of the patient. These data suggest an approach geared to the specific choice of treatment and to improving patient outcomes. [1]

The aim of this study was to assess Digital X ray imaging versus computed tomography for evaluation of calcaneal fractures.

In the present study There mean age of patients was 46 years . and 18 patients (60%) were males and 12 patients (40 %) were female .

This agreed with the study done by **Mitchell et al. 2009 [11]** as in their epidemiological study, they detected two frequency peaks around 20 and 50 years of age, and most patients were males.

In our patient population, the two main injury mechanisms were falling from a height (13 patients [43.4%]) and a traffic accident (17 patients [56.6%])

This was also stated by **Stoller et al., 2004 [12]** who considered the increased axial load caused by falling from a height and landing on the feet was the most common cause of calcaneal fractures. Motor car accidents, in which a seated passenger's feet was pressed hard against the floor of the car, became another commonly encountered cause, however, less frequent than fall from height.

This was also postulated by **Berberian et al., 2013 [13]** who found that the usual cause of calcaneal fractures was fall from height, but this does not agree with a retrospective study performed on 62 patients by **Worsham et al. , 2016** who evaluated the association of calcaneus fractures with lesions. The most common causes were motor vehicle accidents (56.4%) and falls from height (24.1%), whereas the other causes were motorcycle crashes, crush injuries, and pedestrian versus automotive accidents.

According to Associated injuries in the present study's sample, 16 patients (23.3%) had soft tissue edema , 2 patients (11.1%) had muscle injuries and 3 patients (16.7%) had tendon injuries

In the present study, 6 patients (20%) had multiple fractures. Of which 4 patients (66.7%) had ankle and calcaneal fractures, two patients (33.3%) had calcaneal and talar fractures.

In the present study, In the term of comparison between Digital X-ray and CT images finding according to sensitivity of diagnosis of fractures, there was a statistically significant difference between Digital X-ray and CT images finding in Intraarticular Fractures and total fractures.

In the term of Comparison between extraarticular and intraarticular fractures measurements by CT in the present study, there was a statistically significant difference in (The Bohler's angle , The angle of Gissane and The facet height The angle of Gissane) and no statistically significant difference in (The inclination angle)

Ranging from type I to type IV, higher classifications are meant to correspond to greater severity, which may have prognostic indications. Sanders type I fractures includes intraarticular fractures that have less than 2 mm of articular displacement, regardless of the number of fracture lines/fragments present and can often be managed nonoperatively [14]

Sanders type II and III fractures have one and two primary fracture line(s), respectively, whereas Sanders type IV involves three or more primary fracture lines with greater than 2 mm of articular displacement, and are therefore severely comminuted. [15]

CT assessment is important for excluding articular surface involvement and determining the extent of the fracture. Patients with calcaneal body fractures usually have a better prognosis than those with intraarticular fractures, and management is usually conservative . [16]

Only CT can give a clear understanding of the size of fragment and the number of intraarticular fracture lines. In addition, CT shows the location and plane of variable fracture lines that separate the anterolateral fragment. This guides the surgeon for the dissection necessary to visualize and treat the fracture. The precise location of the lateral wall, particularly in relation to the lateral malleolus and peroneal tendons, is much more easily appreciated with CT than with axial radiographs [17]

## 5. Conclusion

CT scanning is a valuable non-invasive common technique and has gained use in identifying the diagnosis, classification, and treatment planning of extra-articular and intra-articular calcaneal fractures

## References

- [1] **M.Galluzzo, F.Greco, M.Pietragalla, De A.Renzis, M.Carbone, M.Zappia, N.Maggialetti, .**“Calcaneal fractures: radiological and CT evaluation and classification systems”, *Acta Bio Medica: Atenei Parmensis, Mattioli*.vol. 89,pp.138-140,**2018**.
- [2] **E.Guerado, M.L. Bertrand, and J.R. Cano** .“Management of calcaneal fractures: what have we learnt over the years?”, *Injury, Elsevier*.vol. 43 ,pp.1640–1650,**2012**.
- [3] **G.Arslan, I.K.Yirgin, and A.Tasguzen** .“A measuremental approach to calcaneal fractures”, *European Journal of Trauma and Emergency Surgery, Springer*.vol. 40 , pp. 593–599,**2014**.
- [4] **S.Rodrigues-Gomes, J. C.Vasconcelos, P.Portugal, R.Aguiar, A.Skaf, & N. Sousa** .Imaging in Football Lesions. In *Injuries and Health Problems in Football Springer, Berlin, Heidelberg* .vol.15,pp.pp.65-79, **2019**.
- [5] **Galluzzo, M., Greco, F., Pietragalla, M., De Renzis, A., Carbone, M., Zappia, M., N.Maggialetti, A.D'andrea, G.Caracchini, & V.Miele** . Calcaneal fractures: radiological and CT evaluation and classification systems. *Acta*

- bio-medica : Atenei Parmensis.vol. 89,pp. 138–150,2018.
- [6] **F.Madadi, F.Madadi, and A.S. Moghaddam** . “Diagnostic Value of Imaging Modalities for Suspected Calcaneal Fracture: A Systematic Review of Literatures”, Clin Res Foot Ankle.vol. 4, ,pp. 186-170,2016.
- [7] **J.R.Peschman, K. Brasel** .Medical Imaging and Injury Scaling in Trauma Biomechanics. In: Yoganandan N., Nahum A., Melvin J., The Medical College of Wisconsin Inc on behalf of Narayan Yoganandan (eds) Accidental Injury. Springer, New York.vol.15,pp.144-180,2015.
- [8] **A.Aliprandi, F.Di Pietto, P.Minafra, M. Zappia, S.Pozza, LM.Sconfienza**. Femoro-acetabular impingement: what the general radiologist should know. Radiol .vol.119,pp.103–12,2014.
- [9] **M.Geijer, GY.El-Khoury** MDCT in the evaluation of skeletal trauma: principles, protocols, and clinical applications. Emerg Radiol.vol.13,pp.7-18,2006.
- [10] **M. P.Ebaugh, W. C.McGarvey, M. J.Penner, & G. C. Berlet** .Revision Total Ankle Arthroplasty. In Primary and Revision Total Ankle Replacement Springer, Cham.vol.14,pp. 421-446,2021.
- [11] **M.J.Mitchell, JC.McKinley, CM.Robinson** The epidemiology of calcaneal fractures Foot .vol.19,pp.197–20,2009.
- [12] **DW.Stoller, PFJ.Tirman, M.Bredella** . Ankle and foot, osseous fractures, calcaneal fractures. In: Diagnostic imaging: orthopaedics. Salt Lake City, Utah: Amirsys.vol.40,pp.70–74,2004.
- [13] **W.Berberian, A.Sood, B. Karanfilian**. CT classification and results of operative treatment Foot Ankle Clin.vol. 55,pp.43–51,2013.
- [14] **J. H.Jiménez-Almonte, J. D.King, T. D.Luo, A.Aneja, & E.Moghadamian**. in brief: Sanders classification of intraarticular fractures of the calcaneus. Clinical Orthopaedics and Related Research.vol.477(2),pp.150-158,2019.
- [15] **P. J.Sharr, M. M.Mangupli, I. G.Winson, & R. E.Buckley** . Current management options for displaced intra-articular calcaneal fractures: non-operative, ORIF, minimally invasive reduction and fixation or primary ORIF and subtalar arthrodesis. A contemporary review. Foot and Ankle Surgery.vol. 22(1),pp.1-8,2016.
- [16] **D.Griffin, N.Parsons, E.Shaw, Y.Kulikov, C.Hutchinson, M.Thorogood & S. E. Lamb**. Operative versus non-operative treatment for closed, displaced, intra-articular fractures of the calcaneus: randomised controlled trial. Bmj.vol. 349,pp.400-485,2014.
- [17] **A.Daftary, AH.Haims, MR.Baumgaertner** Fractures of the calcaneus: a review with emphasis on CT. RadioGraphics.vol.25(5),pp.1215–26, 2005.