

Optical Coherence Tomography Angiography versus Fundus Fluorescein Angiography in Assessment of Clinically Undetected Neovascularization in Severe Non-Proliferative Diabetic Retinopathy Patients

HUSSEIN Sh. EL MARKAPY, M.D.; MOHAMMED H. HASHEM, M.D.;
NOURELDIN H. ABOZEID, M.D. and YOUSTIENA R. MORIES, M.Sc.

The Department of Ophthalmology, Faculty of Medicine, Ain Shams University

Abstract

Background: Diabetic retinopathy is one of the most important challenges that faces the diabetic patients, simply it is a microangiopathy of the retina which leads to impairment of visual abilities if neglected, consists of many factors such as vascular walls changes and alterations in blood physiological criteria. These factors leads to capillary occlusion and so to fluid leakage and retinal ischemia.

Aim of Study: Evaluation of the superiority and sensitivity of the OCT angiography technique over fundus fluorescein angiography in detection of clinically undetected neovascularization.

Patients and Methods: Prospective, observational study. Sample consists of 30 eyes of patients presented to the outpatient clinic with severe non-proliferative diabetic retinopathy and clinically undetected neovascularizations.

Results: Results showed that FFA and OCTA were equal in diagnosing 23 eyes as Severe NPDR with no obvious proliferative activity in all retinal slabs. As well as OCTA could confirm the FFA diagnosis of suspected PDR in 6 eyes in a form of NVDs. However, OCTA was superior to FFA in diagnosing PDR and detecting neovessles (mainly NVDs) in 1 eye. In brief, this study revealed a highly significant correlation between OCT and FFA which means that OCTA shows a great utility in the clinical practice in discovering invisible neovascularization especially in the central part of the retina and to predict the progression of diabetic retinopathy, which in turn affects the management decisions and prevents unfavorable complications.

Conclusion: This study demonstrated that Conventional OCTA is very useful clinically in evaluation of new vessels formation mainly in the central retina, however FFA still owns the upper hand in assessment of proliferative activity in the peripheral retina.

Key Words: *Optical coherence tomography angiography – Fundus fluorescein angiography – Diabetic retinopathy.*

Correspondence to: Dr. Youstiena R. Mories,
[E-Mail: youstiena.raafat@gmail.com](mailto:youstiena.raafat@gmail.com)

Introduction

DIABETIC retinopathy is a microangiopathy of the retina from which nearly all persons with diabetes eventually suffer [1].

It causes changes in the vascular wall structure and in the rheological properties of the blood. The combination of these factors leads to capillary occlusion and thereby to retinal ischemia and angiographically demonstrable leakage [2].

Early Treatment Diabetic Retinopathy Study (ETDRS) grading scheme consists of mild and moderate non-proliferative diabetic retinopathy (background diabetic retinopathy), severe non-proliferative retinopathy (pre-proliferative diabetic retinopathy) and non-high-risk and high-risk proliferative diabetic retinopathy (proliferative diabetic retinopathy) [3].

Progressing of Non-proliferative Diabetic retinopathy from mild, moderate to severe depends on the severity of flame shaped and blot haemorrhages, hard exudates, fluctuations of venous calibre (venous beading) and intraretinal microvascular anomalies [4].

As hypoperfusion in the retinal capillary bed becomes more severe and spreads across the retinal area, proliferative diabetic retinopathy develops

Abbreviations:

NPDR : Non-Proliferative Diabetic Retinopathy.
NVD(s) : New Vessel(s) at the Disk.
OCT : Optical Coherence Tomography.
OCTA : Optical Coherence Tomography Angiography.
PDR : Proliferative Diabetic Retinopathy.
CNVM : Choroidal neovascular membranes.
FFA : Fundus Fluorescein Angiography.

in the form of neovascularization arises at the papilla (neovascularization of the disk, NVD), on the retina outside the papilla (neovascularization elsewhere, NVE) and on the iris (neovascularization of the iris, NVI) as an attempt to compensate the ischemia [5].

For decades, dye-based angiography has been the gold standard clinical imaging modality for evaluating retinal and choroidal vascular pathologies [6].

The main idea of FFA based on injection of fluorescein dye intravenously, exciting the dye with blue light with the aid of a cobalt filter, and photographically recording the fluorescein filling sequence of the retinal vasculature [7].

One of the clear advantages of fundus fluorescein angiography is their ability to capture a much wider area of the retinal and choroidal vasculature, another advantage is that its images are less liable to show artifacts than other imaging techniques [6].

Despite its success, fundus fluorescein angiography has some weak points as being invasive and time-consuming, in addition to having the potential for allergic reactions to the dye. Moreover, it is only a two-dimensional study focusing on the superficial retinal circulation, without the ability to visualize the deeper capillary structures [6,8].

Neovascularization in proliferative diabetic retinopathy is formed by capillaries with very fragile single cell walls and may cause vitreal haemorrhages with ensuing glial proliferation, these new vessels generally appear at the edges of the ischemic areas; initially they can be recognized because they are very irregular and give rise to an intense leakage of the fluorescein [9,10].

Optical coherence tomography angiography is a relatively new, non-invasive technology that has revolutionized imaging of the retinal and choroidal microvasculature, a convenient cross-sectional and three-dimensional display [11,12].

It provides a highly-detailed, depth-resolved angiographic representation of the individual retinal capillary plexuses, facilitating qualitative and quantitative assessments of the perfusion state of the superficial, middle and deep capillary plexuses of the fovea, unobscured by leakage [6].

OCTA shows valuable practical advantages such as fast acquisition time allows images to be acquired in seconds compared to the 10-30min required by traditional dye-based angiography [11].

It is based on the detection of movement changes in moving red blood cells (Flow Motion detection) so there is no need for dye injections with their serious adverse reaction [11].

Also retinal layers segmentation one of the most precious advantages, enhancing its ability to visualize retinal neovascular lesions, such as retinal angiomatous proliferation, subretinal neovascularization and other vascular changes in type 2 macular telangiectasia, as well as choroidal lesions like CNVM and polypoidal growths [6].

The en-face acquisition areas currently range from 2 x 2mm to 12 x 12mm with the scan quality greatly decreased with a widened field of view since the same number of OCT b-scans is used for all scanning areas. Using of the montage technique allows for a larger field of view much like FA/ICGA while maintaining this improved resolution [13].

The wide-field montage OCTA image has an evident benefit in patients with Diabetic retinopathy as it allows visualization of an enlarged FAZ, perifoveal intercapillary area, and multiple microaneurysms. It also provides a larger field of view allowing more peripheral detection of microvascular changes, early NVE, and areas of capillary non-perfusion including areas too small to visualize on FA [13].

Despite being superior to dye-based angiography in some points, OCTA still has weak points and disadvantages such as being easily prone to artifacts with patient movement blinking and motion detection process, leakage not appreciated, limited imaging field precludes imaging of the retinal periphery (may be overcome with the montage image), its inability to visualize low-flow lesions [6].

Aim of the work:

Evaluation of the superiority and sensitivity of the OCT angiography technique over fundus fluorescein angiography in detection of clinically undetected neovascularization.

Patients and Methods

Methodology: Prospective, observational study.

Sample size: Sample consists of 30 eyes of diabetic patients presented to the outpatient clinic with severe non-proliferative diabetic retinopathy and clinically undetected neovascularizations.

Study setting: Ain Shams University Hospitals-Ophthalmology Department. From October 2019 – March 2021.

Study population:

Inclusion criteria: Patients with type 1 & type 2 diabetes. Patients with no clinically evident proliferative diabetic retinopathy. Naive patients with no previous injections or laser sessions.

Exclusion criteria: Patients with Glaucoma. Pregnant females. Patients with elevated kidney function tests. Patients had previous attacks of anaphylactic reactions with dye-injection. Other causes of proliferative retinopathy (retinal arterial or venous occlusion-sickle cell retinopathy-radiation retinopathy-ocular ischemic \$). Significant Media opacity (corneal edema-cataract-vitreous haemorrhage).

Data collection:

Clinical examination was done to confirm the DR grading and to exclude presence of clinically obvious neovascularization. Patients underwent for FFA using Heidelberg imaging device then for OCTA imaging using the (6x6) mm scans in The AngioVue OCTA system (RTVue-XR Avanti; Optovue, Fremont, CA, USA) with a split-spectrum amplitude decorrelation angiography (SSADA) software algorithm (version 2017.1.0.49) was used. To obtain wider field images, a montage image view was performed by merging 6x6 scan of retina and 6x6 scan of disc. Comparison was done between data obtained from the two imaging techniques.

Statistical analysis:

Data were collected, revised, coded and entered to the Statistical Package for Social Science (IBM SPSS) version 23. The quantitative data were presented as mean, standard deviations and ranges when parametric. Also qualitative variables were presented as number and percentages. The comparison between groups with qualitative data were done by using Chi-square test. The comparison between two groups with quantitative data and parametric distribution were done by using Independent *t*-test. Receiver operating characteristic curve (ROC) was used in the qualitative form to determine sensitivity, specificity, positive predictive value (PPV), negative predictive value (NPV) and Accuracy of FFA to predict results of OCTA The confidence interval was set to 95% and the margin of error accepted was set to 5%. So, the *p*-value was considered significant as the following: *p*>0.05: Non significant. *p*<0.05: Significant. *p*<0.01: Highly significant.

Results

Table (1): Distribution of age and sex.

		No.=30
Age:		
Mean ± SD		48.93±17.29
Range		23-74
Sex:		
Female		16 (53.3%)
Male		14 (46.7%)

Table (2): Distribution of type of diabetes, duration, disease control.

		No.=30
Type of diabetes:		
Type I		10 (33.3%)
Type II		20 (66.7%)
Duration:		
Mean ± SD		16.70±5.06
Range		8-30
Control of disease:		
Non-controlled		16 (53.3%)
Controlled		14 (46.7%)

Table (3): Data distribution according to FFA & OCTA results.

	No.	%
FFA:		
Severe NPDR	24	80.0
Proliferation	6	20.0
OCTA:		
No proliferation	23	76.7
Proliferation	7	23.3
Cases with proliferation:		
(NVD)	6	85.7
(NVD+IRMA)	1	14.3

Table (4): Relation between FFA, age and sex.

	FFA		Test value	<i>p</i> -value	Sig.
	Severe NPDR No.=24	Proliferation No.=6			
Age:					
Mean ± SD	50.25±18.37	43.67±11.83	0.830*	0.414	NS
Range	23-74	30-59			
Sex:					
Female	13 (54.2%)	3 (50.0%)	0.033*	0.855	NS
Male	11 (45.8%)	3 (50.0%)			

p-value >0.05: Non-significant (NS).

p-value <0.05: Significant (S).

p-value <0.01: Highly significant (HS).

Table (5): Correlation between FFA, type of diabetes, duration and control of disease.

	FFA		Test value	p-value	Sig.
	Severe NPDR No.=24	Proliferation No.=6			
<i>Type of diabetes:</i>					
Type I	7 (29.2%)	3 (50.0%)	0.938*	0.333	NS
Type II	17 (70.8%)	3 (50.0%)			
<i>Duration:</i>					
Mean ± SD	17.54±5.00	13.33±4.08	1.903*	0.067	NS
Range	8-30	10-20			
<i>Control of disease:</i>					
Non-controlled	13 (54.2%)	3 (50.0%)	0.033*	0.855	NS
Controlled	11 (45.8%)	3 (50.0%)			

p-value >0.05: Non-significant (NS).
 p-value <0.05: Significant (S).
 p-value <0.01: Highly significant (HS).

Table (7): Correlation between OCTA with type of diabetes, duration and disease control.

	OCTA		Test value	p-value	Sig.
	No proliferation No.=23	Proliferation No.=7			
<i>Type of diabetes:</i>					
Type I	6 (26.1%)	4 (57.1%)	2.329*	0.127	NS
Type II	17 (73.9%)	3 (42.9%)			
<i>Duration:</i>					
Mean ± SD	17.74±5.01	13.29±3.73	2.165*	0.039	s
Range	8-30	10-20			
<i>Control of disease:</i>					
Non-controlled	13 (56.5%)	3 (42.9%)	0.403*	0.526	NS
Controlled	10 (43.5%)	4 (57.1%)			

p-value >0.05: Non-significant (NS).
 p-value <0.05: Significant (S).
 p-value <0.01: Highly significant (HS).

Table (6): Correlation between OCTA with age and sex.

	FFA		Test value	p-value	Sig.
	No proliferation No.=23	Proliferation No.=7			
<i>Age:</i>					
Mean ± SD	51.04±18.36	42.00±11.66	1.222*	0.232	NS
Range	23-74	30-59			
<i>Sex:</i>					
Female	12 (52.2%)	4 (57.1%)	0.053*	0.818	NS
Male	11 (47.8%)	3 (42.9%)			

Table (8): Correlation between FFA & OCTA.

OCTA	FFA				Test value	p-value	Sig.
	Severe NPDR		Proliferation				
	No.	%	No.	%			
No proliferation	23	95.8	0	0.0	24.643	0.000	HS
Proliferation	1	4.2	6	100.0			
(NVD)	1	100.0	5	83.3	0.194	0.659	NS
(NVD+IRMA)	0	0.0	1	16.7			

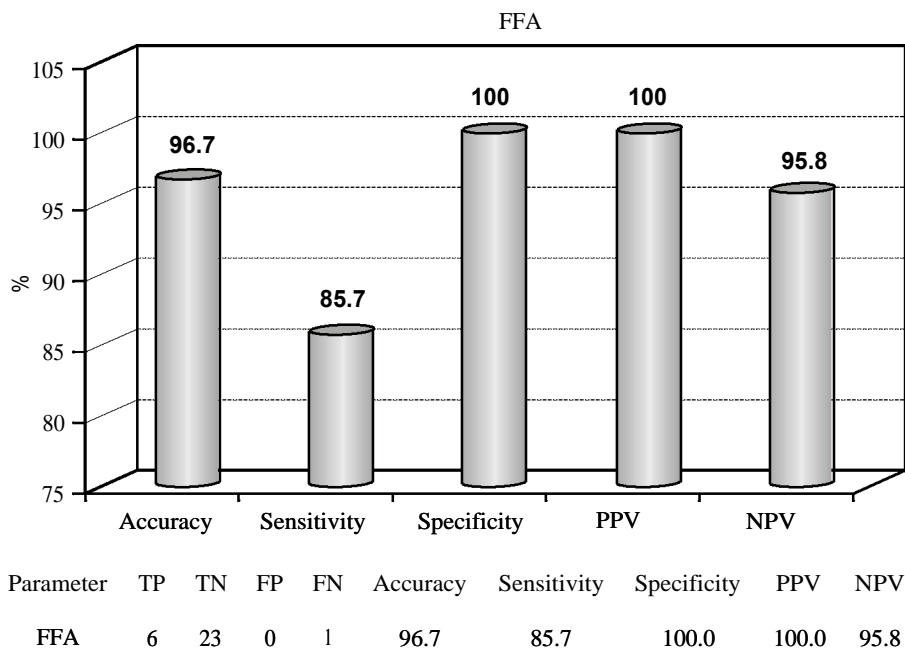


Fig. (1): Sensitivity and specificity of FFA in relation with OCTA.

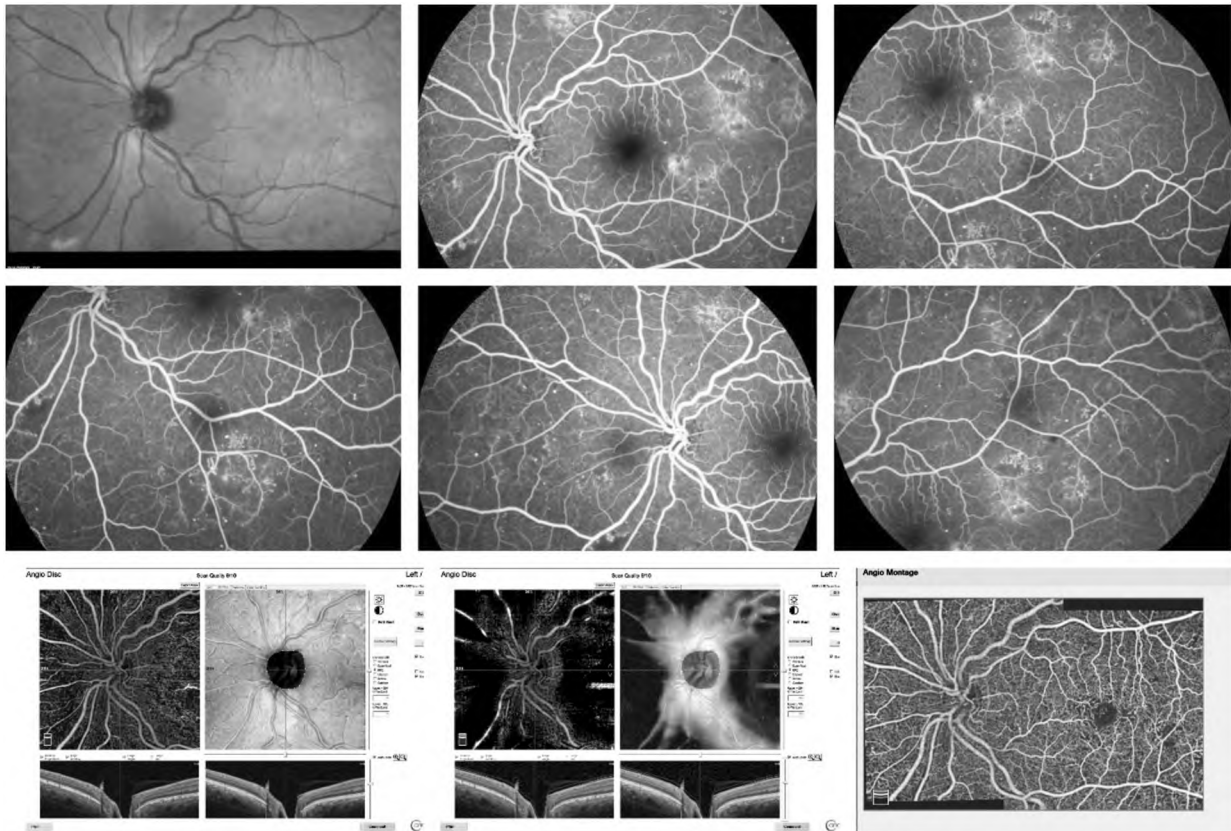


Fig. (2): Case (1): FFA demonstrates Severe NPDR (microaneurysms with IRMAs) in all phases, OCTA also confirms the diagnosis (no proliferation).

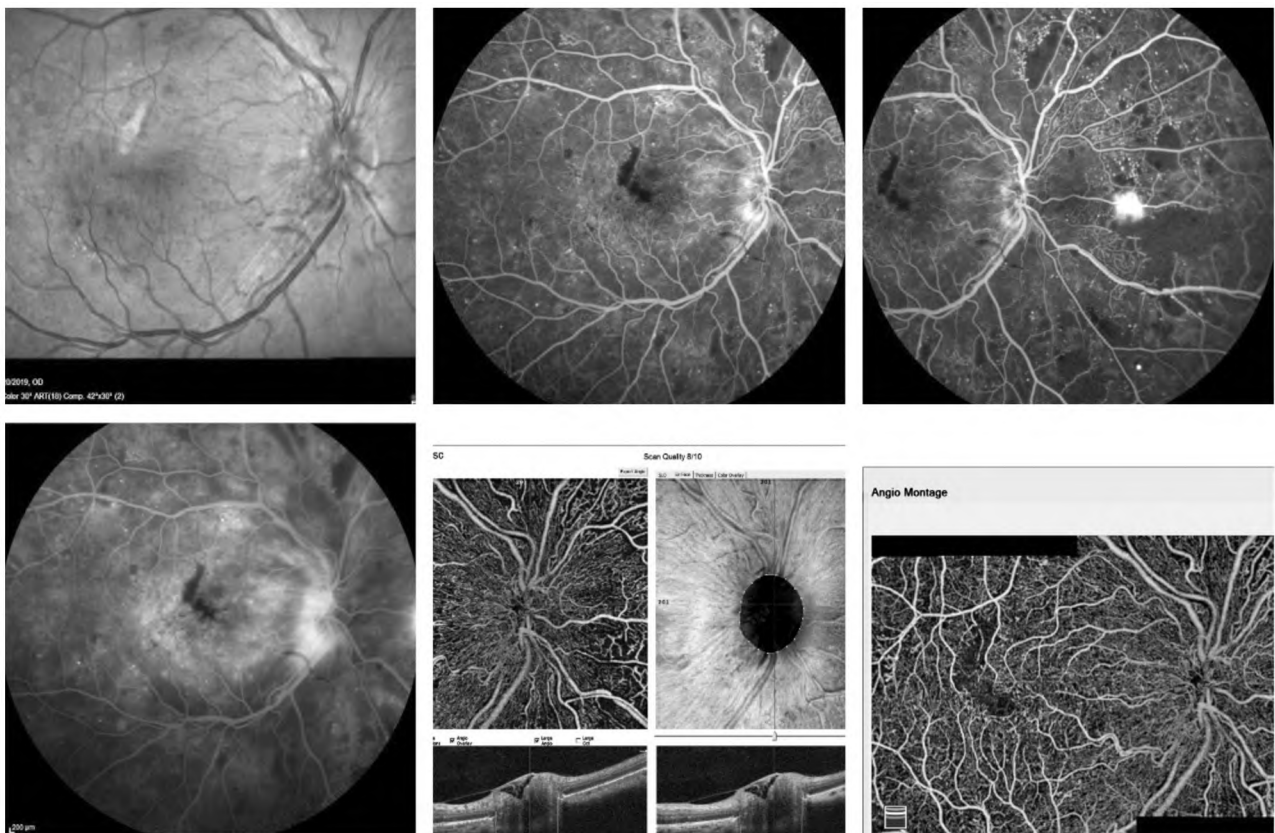


Fig. (3): Case (2): FFA demonstrates suspected proliferative activity (NVD, NVE), OCTA confirms the diagnosis and shows NVD.

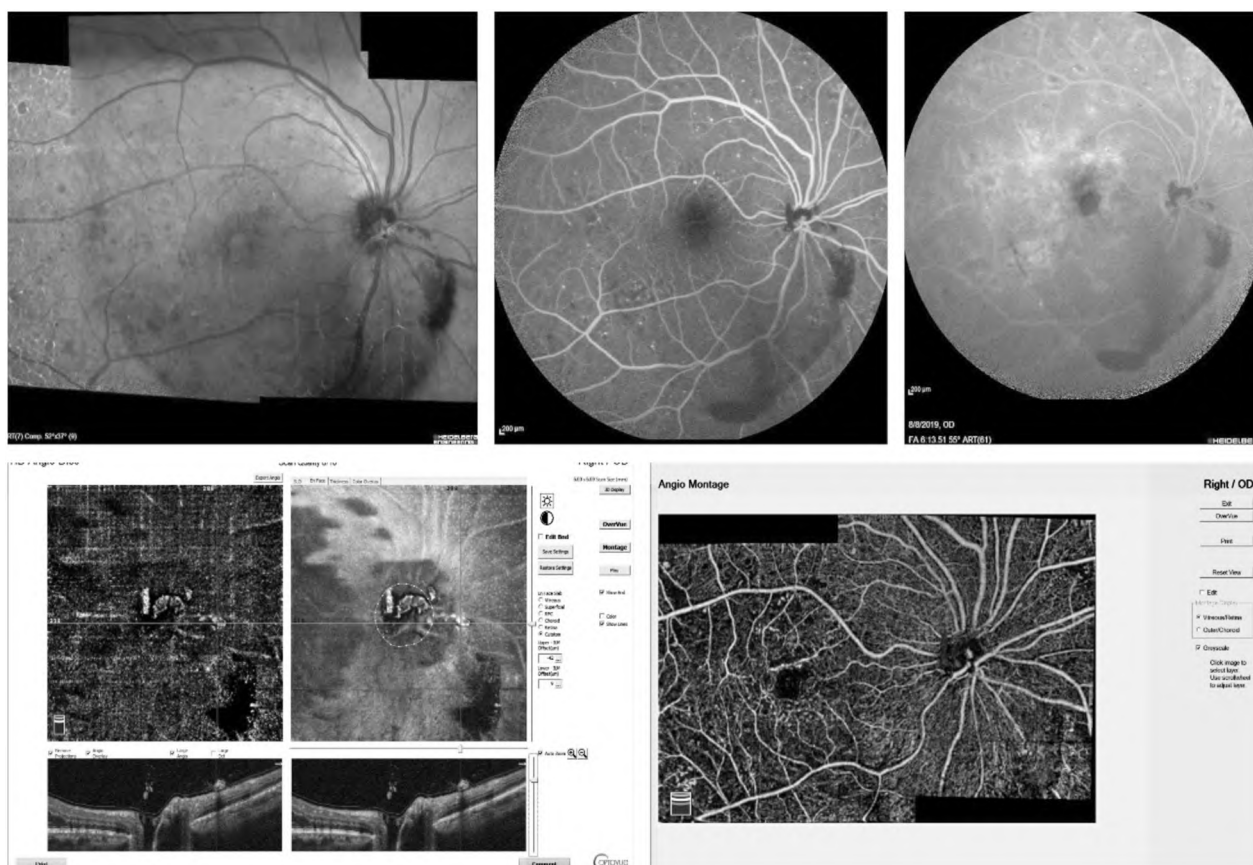


Fig. (4): Case (3): FFA showed preretinal haemorrhage above the disc which blocked fluorescence in all phases, however OCTA could detect underlying NVD.

Discussion

This study based on comparison between the clinical influence of FFA and OCTA in detection of clinically unsuspected neovascularization in patients with severe NPDR.

This study included 30 eyes, with FFA imaging 24 eyes showed severe NPDR with no evidence of neovessles and 6 eyes showed suspected proliferative diabetic retinopathy.

However, with OCTA imaging the 30 eyes were divided into 23 eyes which showed no proliferative activity and 7 eyes showed proliferation (6 eyes showed NVDs only, and 1 eye showed NVD with IRMAs).

This means that FFA and OCTA were equal in diagnosing 23 eyes as severe NPDR with no obvious proliferative activity in all retinal slabs.

As well as OCTA could confirm the FFA diagnosis of suspected PDR in 6 eyes in the form of NVDs.

However, OCTA was superior to FFA in diagnosing PDR and detecting neovessles (mainly NVDs) in 1 eye.

In brief, this study revealed a highly significant correlation between OCT and FFA which means that OCTA shows a great utility in the clinical practice in discovering invisible neovascularization especially in the central part of the retina and to predict the progression of diabetic retinopathy, which in turn affects the management decisions and prevents unfavorable complications Al-Khersan et al., [14].

This study is consistent with Al-Khersan et al., in the point of comparison between Conventional OCTA and FFA in identification of NVs in severe NPDR patients with high suspicion of neovascularization.

But results are contradicted as Al-Khersan et al., showed equal accuracy between OCTA and FFA in Diabetic NV identification however this study demonstrated the superiority of OCTA over FFA You et al., [15].

This study results are consistent with You et al., as they reported that OCTA could discover subtle neovascularization especially in patients with severe NPDR that expert clinicians did not suspect, but results are different in the point that this study used conventional Optovue OCTA software however You et al., depended on wide field OCTA imaging software which provided more peripheral field to judge on.

Unlike this study, You et al., just contented with color photography and didn't involve FFA to be compared with OCTA.

Also You et al., included patients from all stages of non-proliferative diabetic retinopathy (mild-moderate-severe) in their study, unlike this study which stressed only on the severe NPDR category Pan et al., [16].

This study agree with Pan et al., as they reported that conventional OCTA was very successful in close observation of neovascularization morphology in early stages of PDR over FFA and color photography.

But they are contradicted in the point that patients included in Pan et al., were already diagnosed as PDR using FFA however, this study precisely analyzed the usefulness of OCTA over FFA in diagnosing of early neovascularization formation in severe NPDR patients which will extremely reflect on the diabetic retinopathy stages classification in the future Sawada et al., [17].

This study differs than Sawada et al., in the point of diabetic retinopathy class enrolled in the study, as it focuses mainly on Severe NPDR patient before the invasion of the proliferative activity, however Sawada et al., included patients whom already diagnosed as PDR.

Also in the point of Sawada et al., larger sample size, usage of wide field softwares either in OCTA or FFA to overcome field restriction and limited results range Pichi F. et al., [18].

This study is similar to Pichi et al., in the point of comparison between clinical picture, Fundus Fluorescein angiography and OCT angiography to evaluate sensitivity and superiority in NV identification and results were almost convenient as OCTA was superior to other imaging modalities.

However they contradicted as Pichi et al., enrolled patients already diagnosed as active PDR patients with apparent neovascularization and used wide-field imaging softwares to cover larger field Khalid et al., [19].

This study is similar to Khalid et al., in the point of comparison between OCT angiography and clinical examination to evaluate sensitivity in NV identification also both studies enrolled patients diagnosed as severe NPDR and results were similar as OCTA was superior and showed higher detection rate.

However they are contradicted as Khalid et al., depended on wide-field imaging softwares and so OCTA could identify peripheral NVEs de Carlo et al., [20].

This study results were consistent with de Carlo et al., as they reported that conventional optovue OCTA could visualize preretinal neovascularization and IRMAs weren't apparent with clinical examination.

However, they are contradicted as de Carlo et al., enrolled patients already diagnosed as PDR and didn't consider comparison with FFA Enders et al., [21].

This study is similar to Enders et al., as they compared between OCTA and FFA in evaluation of neovascularization.

But they are contradicted as Enders et al., enrolled patients already diagnosed as PDR and depended on Zeiss angioplex OCTA.

Limitations:

The main obstacle that faced this study represented in the restricted field obtained from conventional OCTA softwares in comparison with the wider field of FFA which provides a broad surface area of the peripheral retina to evaluate, which prohibited the precise judgment on the neovascularization elsewhere (NVE) were found in the periphery.

Conclusion:

This study demonstrated that Conventional OCTA is very useful clinically in evaluation of new vessels formation mainly in the central retina, however FFA still owns the upper hand in assessment of proliferative activity in the peripheral retina.

References

- 1- KOLIAS A.N. and ULBIG M.W.: Diabetic retinopathy. In: Continuing Medical Education, p. 346-53, 2004.
- 2- GILDEA D.: The diagnostic value of optical coherence tomography angiography in diabetic retinopathy: A systematic review. *Int. Ophthalmol.* [Internet], 39 (10): 2413-33, 2019.

- 3- HENG L.Z., COMYN O., PETO T., TADROS C., NG E., SIVAPRASAD S., et al.: Diabetic retinopathy: Pathogenesis, clinical grading, management and future developments. *Diabet. Med.*, 30 (6): 640-50, 2013.
- 4- CAO D., YANG D., HUANG Z., ZENG Y., WANG J., HU Y., et al. Optical coherence tomography angiography discerns preclinical diabetic retinopathy in eyes of patients with type 2 diabetes without clinical diabetic retinopathy. *Acta. Diabetol.*, 55 (5): 469-77, 2018.
- 5- LI L., ALMANSOOB S., ZHANG P., ZHOU Y. DAN, TAN Y. and GAO L.: Quantitative analysis of retinal and choroid capillary ischaemia using optical coherence tomography angiography in type 2 diabetes. *Acta. Ophthalmol.*, 97 (3): 240-6, 2019.
- 6- FAYED A. and FAWZI A.A.: OCTA vs. Dye: The Pros and Cons. *Rev. Ophthalmol.*, 2019.
- 7- SPAIDE R.F., KLANCNIK J.M. and COONEY M.J.: Retinal vascular layers imaged by fluorescein angiography and optical coherence tomography angiography. *JAMA Ophthalmol.*, 133 (1): 45-50, 2015.
- 8- LA MANTIA A., KURT R.A., MEJOR S., EGAN C.A., TUFAIL A., KEANE P.A., et al.: Comparing Fundus Fluorescein Angiography and Swept-Source Optical Coherence Tomography Angiography in the Evaluation of Diabetic Macular Perfusion. *Retina.*, 39 (5): 926-37, 2019.
- 9- LUMBROSO B. and RISPOLI M.: Practical Handbook of Fluorescein Angiography. *Practical Handbook of Fluorescein Angiography*, 2014.
- 10- SUN Z., YANG D., TANG Z., NG D.S. and CHEUNG C.Y.: Optical coherence tomography angiography in diabetic retinopathy: An updated review. Vol. 35, *Eye (Basingstoke)*, p. 149-61, 2021.
- 11- ONISHI A.C. and FAWZI A.A.: An overview of optical coherence tomography angiography and the posterior pole. *Ther. Adv. Ophthalmol.*, 11: 251584141984024, 2019.
- 12- KIM K., IN YOU J., PARK J.R., KIM E.S., OH W.Y. and YU S.Y.: Quantification of retinal microvascular parameters by severity of diabetic retinopathy using wide-field swept-source optical coherence tomography angiography. *Graefe's Arch. Clin. Exp. Ophthalmol.*, 2021.
- 13- KHAN H.A., MEHMOOD A., KHAN Q.A., IQBAL F., RASHEED F., KHAN N., et al.: A major review of optical coherence tomography angiography. Vol. 12, *Expert Review of Ophthalmology*, p. 373-85, 2017.
- 14- Comparison Between Graders in Detection of Diabetic Neovascularization with Swept Source OCT Angiography and Fluorescein Angiography. *Am. J. Ophthalmol.*, 2021.
- 15- YOU Q.S., GUO Y., WANG J., WEI X., JIA Y. and HWANG T. S.: Detection of Clinically Unsuspected Retinal Neovascularization with Wide-Field Optical Coherence Tomography Angiography, 2020.
- 16- PAN J., CHEN D., YANG X., ZOU R., ZHAO K., CHENG D., et al.: Characteristics of Neovascularization in Early Stages of Proliferative Diabetic Retinopathy by Optical Coherence Tomography Angiography. *Am. J. Ophthalmol.* [Internet], 192: 146-56, 2018.
- 17- SAWADA O., ICHIYAMA Y., OBATA S., ITO Y., KAKINOKI M., SAWADA T., et al.: Comparison between wide-angle OCT angiography and ultra-wide field fluorescein angiography for detecting non-perfusion areas and retinal neovascularization in eyes with diabetic retinopathy. *Graefe's Arch. Clin. Exp. Ophthalmol.*, 256 (7): 1275-80, 2018.
- 18- PICHI F., D.SMITH S., B.ABBOUD E., NERI P., WOODSTOCK E., HAY S., et al.: Wide-field optical coherence tomography angiography for the detection of proliferative diabetic retinopathy. *Graefe's Arch. Clin. Exp. Ophthalmol.*, 1: 118-23, 2020.
- 19- KHALID H., SCHWARTZ R., NICHOLSON L., HUEMER J., EL-BRADEY M.H., SIM D.A., et al.: Widefield optical coherence tomography angiography for early detection and objective evaluation of proliferative diabetic retinopathy. *Br. J. Ophthalmol.*, 105 (1): 118-23, 2020.
- 20- De CARLO T.E. and BONINI FILHO MARCO A.: Evaluation of Preretinal Neovascularization in Proliferative Diabetic Retinopathy Using Optical Coherence Tomography Angiography, 2016.
- 21- ENDERS C., BAEURLE F., LANG G.E., DREYHAUPT J., TRICK S., KILANI A., et al.: Visualization of Retinal Neovascularization with Optical Coherence Tomography Angiography in Comparison with Fluorescein Angiography. *Klin Monbl Augenheilkd*, 236 (11): 1325-30, 2019.

مقارنة ما بين التصوير المقطعي للأوعية الدموية بالشبكية وتصوير الأوعية الدموية بالشبكية باستخدام صبغة الفلوريسين في تقييم الأوعية الدموية غير المكتشفة بالفحص الإكلينيكي في مرضى اعتلال الشبكية السكرى غير التكاثرى الحاد

المقدمة: الاعتلال الشبكي السكرى من أهم التحديات التي تواجه مرضى السكرى، فهو ببساطة اعتلال الأوعية الدقيقة في شبكية العين وإهماله يؤدي لمضاعفات خطيرة تصل إلى حد فقدان البصر، ويتكون من العديد من العوامل مثل تغيرات جدران الأوعية الدموية والتغيرات في المعايير الفسيولوجية للدم. تؤدي هذه العوامل إلى انسداد الشعيرات الدموية وبالتالي تسرب السوائل ونقص تروية الشبكية.

ينقسم الاعتلال الشبكي السكرى إلى الاعتلال غير التكاثرى (خفيف - متوسط - شديد) واعتلال الشبكية التكاثرى وفقاً لشدة التغيرات التي تحدث شبكية العين ودرجة نقص التروية وتكاثر الأوعية الدموية الجديدة.

لتعويض نقص التروية الناتج عن انسداد الشعيرات الدموية الدقيقة ونقص تدفق الدم الذي يغزو جزءاً كبيراً من أنسجة الشبكية تنمو أوعية دموية جديدة كمحاولة يائسة لتعويض نقص الإمداد الدموي في منطقة ما حول العصب البصرى ومناطق الشبكية المختلفة وبهذا يتحول الاعتلال الغير تكاثرى إلى اعتلال تكاثرى.

تصوير الأوعية الدموية باستخدام الصبغة هي طريقة التصوير الأساسية لتقييم أمراض الأوعية الدموية بالشبكية ومشيمة العين والتي تعتمد على حقن صبغة الفلوريسين في الوريد، وإصابة الصبغة بالضوء الأزرق، وتسجيل تصوير تسلسلي لملء الفلوريسين في الأوعية الدموية في شبكية العين.

التصوير المقطعي للأوعية الدموية بالشبكية، تقنية جديدة احدثت ثورة في تصوير الأوعية الدموية الدقيقة للشبكية والمشيمة، تعتمد على تحليل مفصل وثلاثي الأبعاد لضفائر الشعيرات الدموية السطحية والمتوسطة والعميقة، بطريقة لا تتأثر بوجود أى ارتشاحات في الشبكية.

الهدف من الدراسة: أجريت هذه الدراسة على ٣٠ عين لمصابى الاعتلال الشبكي السكرى بهدف تحديد مدى تفوق تقنية التصوير المقطعي للأوعية الدموية بالشبكية على تقنية التصوير باستخدام صبغة الفلوريسين في تقييم وجود الأوعية الدموية غير المكتشفة بالفحص الإكلينيكي في المرضى الذين يعانون من اعتلال الشبكية السكرى غير التكاثرى الحاد.

اعتمدت هذه الدراسة على الفحص الإكلينيكي للشبكية لمرضى الاعتلال الشبكي السكرى والتأكد على عدم وجود أوعية دموية جديدة ونازفة ثم تصوير الأوعية الدموية للشبكية باستخدام صبغة الفلوريسين لتحديد درجة الاعتلال الشبكي السكرى .

النتائج: أظهرت نتائج هذه الدراسة تفوق التصوير المقطعي للأوعية الدموية على طريقة التصوير باستخدام صبغة الفلوريسين في اكتشاف وجود أوعية دموية جديدة خاصة في الجزء المركزى من الشبكية والتي لم تكتشف بالفحص الإكلينيكي.

وتحتفظ تقنية التصوير باستخدام الفلوريسين ببعض التفوق في تقييم نمو الأوعية الدموية الجديدة في الاعتلال الشبكي السكرى التكاثرى فيما يتعلق بتصوير أطراف الشبكية والتي لا يتوفر تصويرها حتى الآن باستخدام النسخ المتاحة لدينا من أجهزة التصوير المقطعي للأوعية الدموية.