

# Assessment of Angle of Anterior Chamber by Anterior Segment Optical Coherence Tomography before and after Implantable Phakic Contact Lens in High Myopia

ISMAIL I. HAMZA, M.D.; MONA M. EL FIKY, M.D.; MOHAMMED A. KABIL, M.D. and OSAMA M.S. MORSY, M.Sc.

The Department of Ophthalmology, Faculty of Medicine, Ain Shams University

## Abstract

**Background:** Near-sightedness is the most common eye problem and is estimated to affect 1.5 billion people (22% of the population), rates vary significantly in different areas of the world. The underlying cause is believed to be a combination of genetic and environmental factors. Identical twins are more likely to be affected than non-identical twins which indicates at least some genetic factors are involved.

**Aim of Study:** The aim of this work was for assessment of angle of anterior chamber by anterior segment optical coherence tomography before and after implantable phakic contact lens in high myopia, in an attempt to achieve better management for such condition.

**Patients and Methods:** This study was a prospective interventional trial 908 that was carried out on 20 eyes of 11 patients with high myopia, who were not amenable to laser refractive surgery correction, the patients divided into two groups: Group A: Ten eyes from -7D to -12D. Group B: Ten eyes from more than -12D to -20D, all patients consecutively scheduled for IPCL implant to treat myopia.

**Results:** This study found that there was a significant reduction in angle of anterior chamber, after IPCL implantation, with no significant difference between studied groups. And there was a significant reduction in both sphere, cylinder BCVA, and UCVA, after IPCL implantation, with no significant difference between studied groups.

**Conclusion:** IPCL implantation for correction of high myopia leads to significant changes in the anterior chamber angle, volume and depth. It is safe and effective for the correction of high myopia specially, who were not suitable for other refractive surgery correction.

**Key Words:** Angle of anterior chamber – Optical coherence tomography – Myopia.

## Introduction

**MYOPIA** has been increasing rapidly throughout the developed world, suggesting environmental

factors are involved [1]. Myopia is generally classified into two groups: Non-pathologic and pathologic myopia. Both groups have separate disease processes, clinical features, and prognoses [2].

Implantable Phakic Contact lens (IPCL) surgery has become a predictable and widely accepted technique for the correction of high myopia. Although this technique has been reported to be a relatively safe, effective, alterable, and even reversible surgical approach, patients must consider a variety of possible complications, such as lens opacification, endothelial cell loss, high intraocular pressure (IOP), rotation of IPCL, anterior chamber inflammation [3].

Usually, the anterior segment parameters are the crucial indicator of suitability of refractive surgery and post-surgical evaluation [4].

## Aim of the work:

The aim of this work was for assessment of angle of anterior chamber by anterior segment optical coherence tomography before and after implantable phakic contact lens in high myopia, in an attempt to achieve better management for such condition.

## Patients and Methods

This study was carried out after being approved by the local Ethics Committee of the Faculty of Medicine, Ain Shams University, Cairo, Egypt from June 2020 – February 2021.

## Patients:

This is a prospective interventional study that was carried out on 20 eyes of 11 patients with myopic refractive error, who were not amenable

**Correspondence to:** Dr. Osama M.S. Morsy,  
[E-mail: Osamamorsy333@gmail.com](mailto:Osamamorsy333@gmail.com)

to laser refractive surgery correction and willing to participate in the study, the patients divided into two groups:

- Group A (6 patients): Ten eyes from  $-7$  D to  $-12$  D.
- Group B (5 patients): Ten eyes from more than  $-12$  D to  $-20$  D.

All patients consecutively scheduled for IPCL implant to treat myopia over the period June 2020 to February 2021.

#### *Selection of the patient:*

##### *Inclusion criteria:*

Patients of both gender, more than 20 years, Myopia from  $-7$ D to  $-20$ D, Phakic with clear cornea and willing for the procedure.

##### *Exclusion criteria:*

Patients with history of corneal and lens opacity, glaucoma, retinal detachment, macular degeneration, pigmentary dispersion, monocular vision or neurophthalmic disease, ocular inflammation, ocular trauma, or ocular surgery, active infection at the local site, history of systemic diseases such as kidney diseases, hematologic diseases, immune diseases or a history of drug use.

#### *Methods:*

All patients were subjected to the following:

##### *Complete history taking include:*

Personal history including; name, age, sex, occupation, residence. Past history of any ocular disorders, chronic illness or associated disease either involving the eye or other system e.g., hypertension, DM, COPD, thyroid or other autoimmune diseases.

##### *Examination:*

General examination, to exclude medical conditions that increase the risk of intraoperative and postoperative complications as, hypertension, DM, COPD, and also to exclude systemic conditions that are usually associated with rising of IOP.

Detailed ocular examination in order to define uncorrected visual acuity (UCVA), best-corrected visual acuity (BCVA), refractive error, anterior slit-lamp biomicroscopy, posterior segment Ophthalmoscope, IOP was measured by the Goldmann Applanation Tonometer.

Anterior chamber depth measurement: The Pentacam was used for anterior chamber depth, ACD was measured from the corneal epithelium to the anterior lens surface.

For iridocorneal angle measurements, we used anterior segment optical coherence tomography (AS-OCT) imaging (Heidelberg Engineering, Heidelberg, Germany) for iridocorneal angle dimensions.

Postoperative UCVA, BCVA, IOP, AS-OCT iridocorneal angle measurements were performed at 1 week. Angle parameters were obtained from AS-OCT images captured by an expert doctor.

*Surgical technique:* All surgeries were done under topical anesthesia using 0.5% proparacaine hydrochloride. Pupillary dilatation was achieved with a combination of eye drops containing 1% tropicamide and 2.5% phenylephrine. With a temporal approach, two 1mm paracentesis ports were made using angled keratome or  $15^\circ$  micro-vitreoretinal blade at 12 and 6 o'clock positions. Hypromellose 2% (Viscomet PF, Unimed technologies) viscoelastic was then injected into the AC by taking care not to overfill the chamber.

A temporal 3.2mm clear corneal incision was made using keratome. The IPCL was loaded into the cartridge and injected into the AC. The two paracentesis incisions were used to position the footplates under the iris using the special manipulating instrument (Vukich's manipulator) to ensure that all haptics were tucked posterior to the iris. In the case of toric IPCL (TICL) proper alignment was ensured.

At the end of the surgery, viscoelastic was cleared from the AC. A standard postoperative regime consisting of topical prednisolone acetate 1% four times a day for 5 days tapering over 2 weeks and topical moxifloxacin 0.5% four times a day for 2 weeks was followed.

Postoperatively, the patient was examined at day 1 to check for proper IPCL positioning and lens vault on slit-lamp and IOP was checked. The patient was followed-up at 1 week after the surgery for UCVA, BCVA, IOP and angle parameters were measured using AS-OCT.

##### *Outcome measures:*

The primary outcome measure was to assess the changes in IOP and ACA after IPCL implantation after 1 week.

##### *Statistical analysis:*

The data was analyzed using SPSS version 20 (Statistical Package for Social Sciences) with paired *t*-test for intragroup comparison and Mann-Whitney U value test for intergroup comparison. *p*-value of less than 0.05 was considered significant.

IR 30° ART + OCT 30° (16.7mm) ART (32) Q: 46 EDI [HR]

30° (16.7mm) ART (60) Q: 37 EDI [HS]

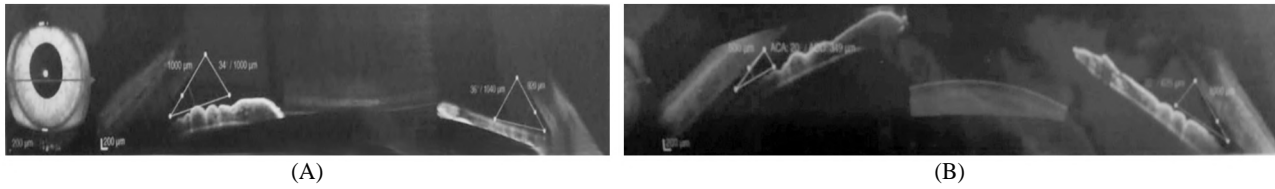


Fig. (1): (A) Pre-operative and (B) post-operative anterior chamber angle in case 2 in group B.

**Results**

This study was conducted on 20 eyes of 11 patients with myopic refractive error, the patients divided into two groups:

- Group A: Ten eyes from -7 D to -12 D.
- Group B: Ten eyes from more than -12 D to -20 D.

There was no significant difference between studied groups as regard demographic data, as shown in (Table 1 & Fig. 2).

Table (1): Comparison between studied groups as regard demographic data.

	Group A	Group B	p-value
<i>Age (Years):</i>			
(Range)	(20-28)	(24-29)	0.090
Mean ± SD	25.0±2.9	27.0±2.0	
<i>Gender: n (%)</i>			
Male	7 (70)	4 (40)	0.070
Female	3 (30)	6 (60)	

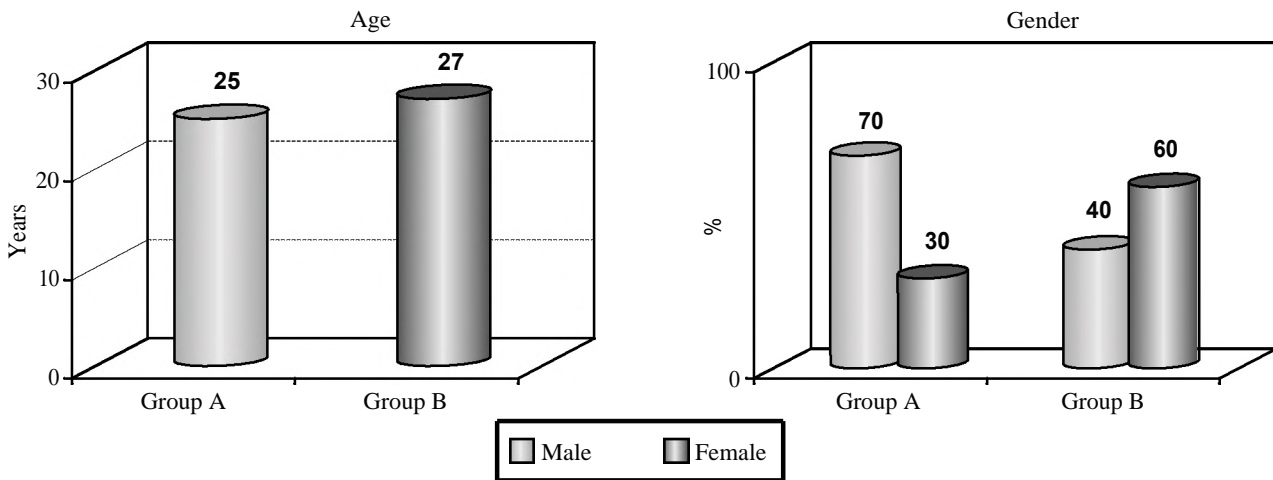


Fig. (2): Comparison between studied groups as regard demographic data.

With reference to refractive error of studied groups, there was significant difference between studied groups as regard sphere before IPCL implantation, however, there was no significant difference between studied groups as regard cylinder and axis, as shown in (Table 2 & Fig. 3).

Table (2): Comparison between studied groups as regard refractive error before IPCL implantation.

Refractive error	Group A	Group B	p-value
(Range) Mean ± SD			
Sphere	(7.75-11.5) 9.025±1.25	(12.5-16.5) 14.35±1.28	0.001*
Cylinder	(0.25-3) 1.52±1.62	(0.75-2.25) 1.65±0.45	0.481
Axis	(15-175) 107.2±59.64	(10-170) 85.30±49.93	0.385

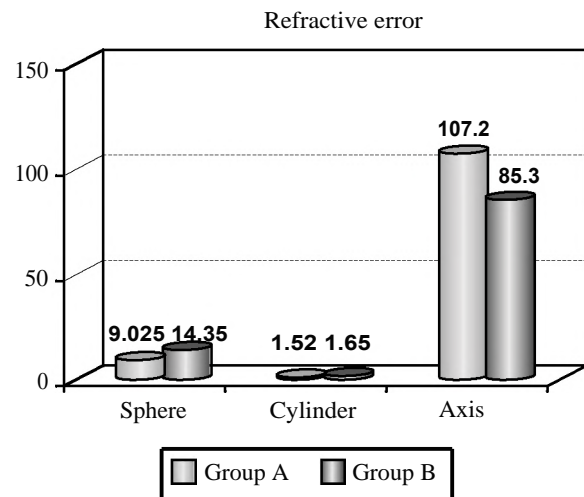


Fig. (3): Comparison between studied groups as regard refractive error before IPCL implantation.

With reference to anterior chamber parameters of studied groups, there was significant difference between studied groups as regard BCVA and UCVA before IPCL implantation, however, there was no significant difference between studied groups as regard angle and IOP, as shown in (Table 3 & Fig. 4).

Table (3): Comparison between studied groups as regard AC angle, BCVA, UCVA and IOP before IPCL implantation.

Anterior chamber parameters	Group A	Group B	p-value
	(Range) Mean ± SD		
Angle (°)	(26-40.75) 33.75±3.87	(34.25-39) 36.57±1.73	0.050
BCVA (log mar)	(0-0.9) 0.12±0.28	(0.3-0.8) 0.49±0.16	0.002*
UCVA (log mar)	(1.2-1.5) 1.31±0.11	(1.3-1.5) 1.43±0.08	0.018*
IOP (mm hg)	(10-13.5) 11.62±1.23	(10.5-14) 11.83±1.11	0.695

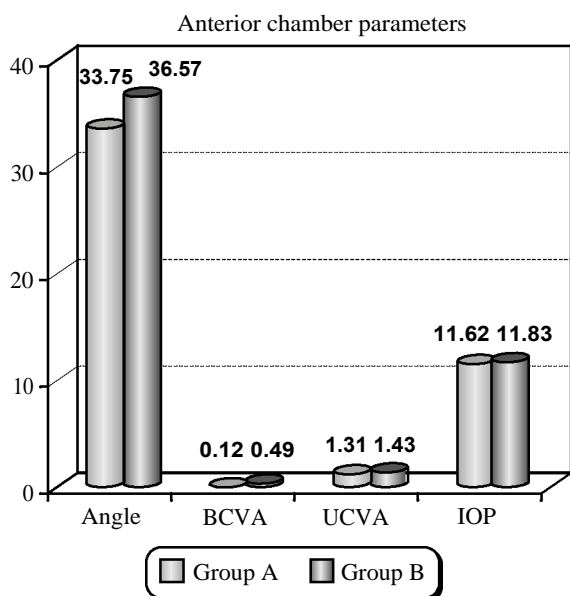


Fig. (4): Comparison between studied groups as regard AC angle, BCVA, UCVA and IOP before IPCL implantation.

As regard group A, there was significant reduction in both sphere and cylinder after IPCL implantation. However, there was no significant difference in axis before and after IPCL implantation, as shown in (Table 4 & Fig. 5).

Table (4): Change in refractive error before and after IPCL implantation in group A.

Refractive error	Before	After	p-value
	(Range) Mean ± SD		
Sphere	(7.75-11.5) 9.025±1.25	(0-1.75) 0.5±0.47	0.001*
Cylinder	(0.25-3) 1.52±1.62	(0.25-2.25) 0.92±0.67	0.038*
Axis	(15-175) 107.2±59.64	(10-170) 102.60±58.51	0.864

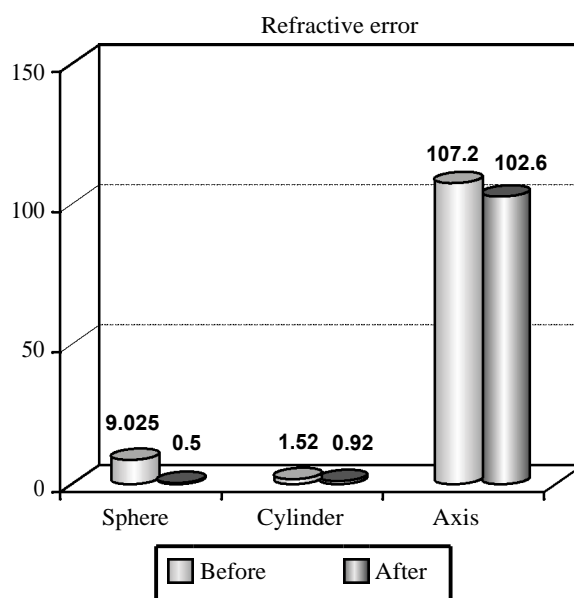


Fig. (5): Change in refractive error before and after IPCL implantation in group A.

As regard group A, there was significant reduction in angle and UCVA after IPCL implantation. However, there was no significant difference in BCVA and IOP before and after IPCL implantation, as shown in (Table 5 & Fig. 6).

Table (5): Change in AC angle, BCVA, UCVA and IOP before and after IPCL implantation in group A.

Anterior chamber parameters	Before	After	p-value
	(Range) Mean ± SD		
Angle (°)	(26-40.75) 33.75±3.87	(18.25-33.25) 25.75±3.94	0.001*
BCVA (log mar)	(0-0.9) 0.12±0.28	(0-0) 0±0	0.195
UCVA (log mar)	(1.2-1.5) 1.31±0.11	(0-0.1) 0.08±0.04	0.001*
IOP (mm hg)	(10-13.5) 11.62±1.2	(10.6-13.8) 12.33±1.22	0.211

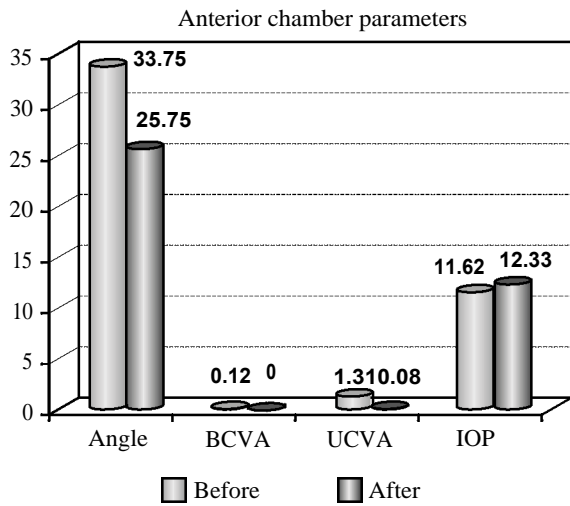


Fig. (6): Change in AC angle, BCVA, UCVA and IOP before and after IPCL implantation in group A.

As regard group B, there was significant reduction in both sphere and cylinder after IPCL implantation. However, there was no significant difference in axis before and after IPCL implantation, as shown in (Table 6 & Fig. 7).

Table (6): Change in refractive error before and after IPCL implantation in group B.

Refractive error	Before	After	p-value
	(Range) Mean ± SD		
Sphere	(12.5-16.5) 14.35±1.28	(0.5-1.5) 0.87±0.35	0.001*
Cylinder	(0.75-2.25) 1.65±0.45	(0.5-1.75) 1.05±0.36	0.005*
Axis	(10-170) 85.30±49.93	(15-175) 87.0±50.23	0.940

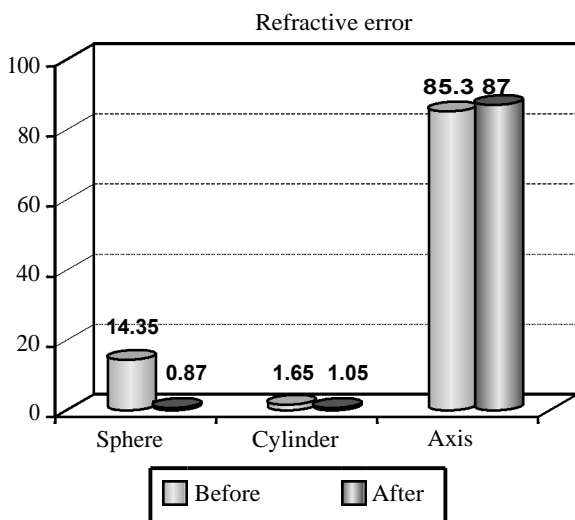


Fig. (7): Change in refractive error before and after IPCL implantation in group B.

As regard group B, there was significant reduction in angle and UCVA after IPCL implantation. However, there was no significant difference in BCVA and IOP before and after IPCL implantation, as shown in (Table 7 & Fig. 8).

Table (7): Change in AC angle, BCVA, UCVA and IOP before and after IPCL implantation in group B.

Anterior chamber parameters	Before	After	p-value
	(Range) Mean ± SD		
Angle (°)	(34.25-39) 36.57±1.73	(21-31.25) 26.95±3.09	0.001*
BCVA (log mar)	(0.3-0.8) 0.49±0.16	(0.2-0.5) 0.35±0.097	0.234
UCVA (log mar)	(1.3-1.5) 1.43±0.08	(0.3-0.6) 0.46±0.10	0.001*
IOP (mm hg)	(10.5-14) 11.83±1.1	(11.3-14.5) 12.73±1.02	0.074

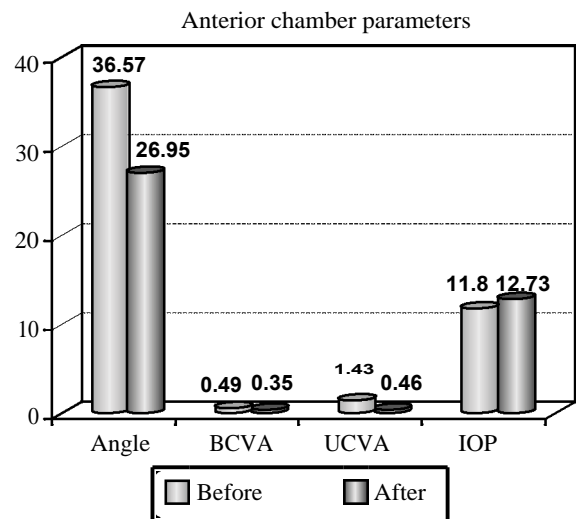


Fig. (8): Change in AC angle, BCVA, UCVA and IOP before and after IPCL implantation in group B.

With reference to refractive error of studied groups, there was no significant difference between studied groups after IPCL implantation, as shown in (Table 8 & Fig. 9).

Table (8): Comparison between studied groups as regard refractive error after IPCL implantation.

Refractive error	Group A	Group B	p-value
	(Range) Mean ± SD		
Sphere	(0-1.75) 0.5±0.47	(0.5-1.5) 0.87±0.35	0.061
Cylinder	(0.25-2.25) 0.92±0.67	(0.5-1.75) 1.05±0.36	0.610
Axis	(10-170) 102.60±58.51	(15-175) 87.0±50.23	0.530

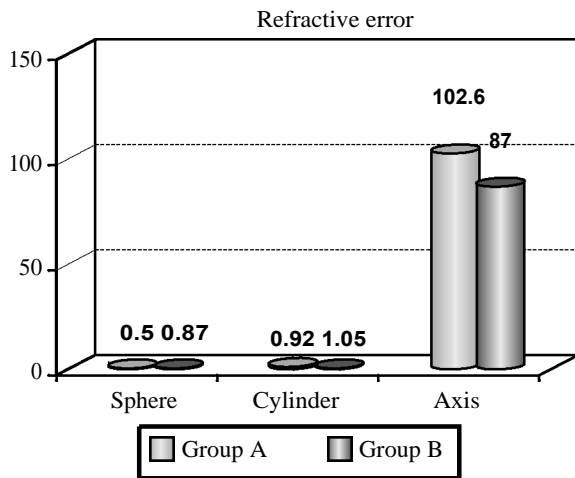


Fig. (9): Comparison between studied groups as regard refractive error after IPCL implantation.

With reference to anterior chamber parameters of studied groups, there was significant difference between studied groups as regard BCVA and UCVA after IPCL implantation, however, there was no significant difference between studied groups as regard angle and IOP, as shown in (Table 9 & Fig. 10).

Table (9): Comparison between studied groups as regard AC angle, BCVA, UCVA and IOP after IPCL implantation.

Anterior chamber parameters	Group A	Group B	p-value
	(Range)	Mean ± SD	
Angle (°)	(18.25-33.25) 25.75±3.94	(21-31.25) 26.95±3.09	0.459
BCVA (log mar)	(0-0) 0±0	(0.2-0.5) 0.35±0.097	0.001*
UCVA (log mar)	(0-0.1) 0.08±0.04	(0.3-0.6) 0.46±0.10	0.001*
IOP (mm hg)	(10.6-13.8) 12.33±1.2	(11.3-14.5) 12.73±1.1	0.441

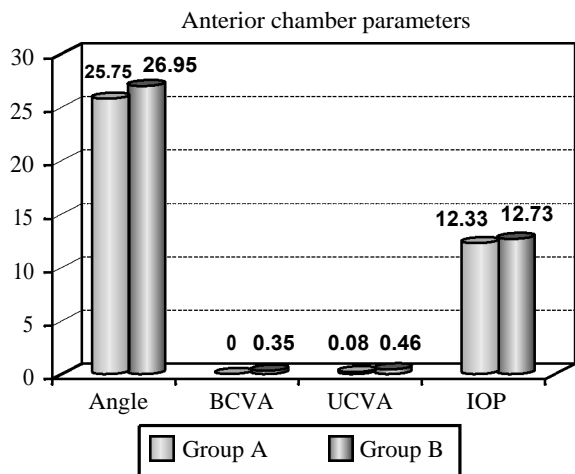


Fig. (10): Comparison between studied groups as regard AC angle, BCVA, UCVA and IOP after IPCL implantation.

### Discussion

IPCL is a good cheap alternative for the correction of errors of refractions up to -30 D while ICL up to -18 D, with reduced risk of pigment dispersion, decreased risk of pupillary block glaucoma with decreased incidence of cataract formation due to maintained aqueous current between the anterior capsule of lens and posterior surface of IPCL [5].

To date, there were a few studies that concerned with the exact changes in the anterior segment parameters after IPCL implantation. So, the current study aimed to assess the angle of anterior chamber by anterior segment optical coherence tomography before and after implantable phakic contact lens in high myopia.

#### Anterior segment parameters:

This study was conducted on 20 eyes of 11 patients with myopic refractive error, the patients divided into two groups: Group A: Ten eyes from -7 D to -12 D. Group B: Ten eyes from more than -12 D to -20 D, we found significant reduction in angle of anterior chamber, after IPCL implantation, with no significant difference between studied groups.

In accordance to our findings, Lu et al., [6], made a retrospective observational study on 98 eyes of 50 patients who underwent implantation of an IPCL to correct myopia, and they found that, ICL implantation offered good outcomes in visual acuity and the remaining spherical refraction of efficacy and stability for the correction of high myopia from the majority of patients was achieved after surgery and during a 4-year follow-up period. There was no statistically significant difference in BCVA during the follow-up period.

Similarly, Mahmoud et al., [7], made a prospective observational study involving 30 myopic eyes which were implanted with IPCL with AS-OCT was used for evaluation of the anterior chamber angle parameters as anterior chamber angle (ACA), angle opening distance (AOD) and, trabecular iris space area (TISA) and lens vault at 1, 3 and 6 months postoperatively. They found that, there were high significant changes between the preoperative values of ACA, AOD and, TISA and first follow-up after 1 month postoperatively with no significant changes between second and third follow-up after 3 and 6 months postoperatively. Regarding the vault, there were stable vault values with no significant changes after 6 months follow-up.



Zhou et al., [8], made a retrospective study included 105 eyes of 53 patients implanted with the Visian ICL V4c model, and 106 eyes of 54 patients implanted with the Visian ICL V4 model, and found that, the anterior chamber angle changes were essentially equivalent in both groups, although implantation of both models will lead to the decrease in anterior chamber angle width, with no significant change in IOP pre and postoperatively.

Chung et al., [9], also reported similar results one month after surgery. As well, Lim et al., [4], reported that, decreases were observed in iridocorneal angle measurements with a shallow anterior chamber, with no further angle changes during follow-up. Also, Ju et al., [10], found that mean ACD measured with AS-OCT showed a statistically significant reduction 3 months after surgery in their study.

Elmohamady and Abdelghaffar [11], evaluated AC changes after ICL implantation in 34 patients with high myopia who underwent ICL implantation using Pentacam imaging and noted that the average ACA decreased significantly at 1 and 3 months, postoperatively. They found that, mean ACV was reduced significantly at 1 and 3 months, postoperatively. Mean central AC depth decreased significantly at 1 and 3 months, postoperatively.

Eissa et al., [12], have done a study to evaluate ACA after ICL implantation. They enrolled 54 eyes of 27 patients undergoing phakic posterior chamber Collamer lens implantation for myopic refractive correction. ACA measured using Pentacam imaging was found to decrease significantly at 1, 6, and 18 months. They noted a moderate correlation between ICL vault and AC angle.

#### *Refractive errors and visual acuity:*

In our study, we found significant improvement in visual acuity (reduction in both sphere, cylinder BCVA, and UCVA) after IPCL implantation, with no significant difference between studied groups.

In continuation with our findings, Gomez-Bastar et al., [13], made A retrospective chart review of a consecutive clinical case series study performed on patients with the diagnosis of myopia, hyperopia, or myopic or hyperopic astigmatism treated with IPCL, they found significant reduction in both sphere and cylinder postoperatively [14]. As well, Lim et al., [4], reported that, IPCL implantation exhibited good visual outcomes and has several advantages, including faster visual recovery, more stable refraction, and better visual quality over keratorefractive surgeries.

Zhou et al., [8], reported that, there was a statistically significant improvement between the preoperative and 12 months postoperative CDVA for both groups.

Yu et al., [15], made an observational study on patients who underwent the implantation of IPCL were followed up for 3 months. Uncorrected visual acuity (UCVA), best corrected visual acuity (BCVA) were measured pre- and postoperatively. They reported that, the UCVA at 1 week, 1 month and 3 months postoperatively were significantly better than those preoperatively. Also, The BCVA at 1 week, 1 month and 3 months after surgery, were better than those before surgery significantly.

Miao et al., [16], made a prospective non-randomized study on patients underwent IPCL implantation, and they reported that, there was improvement in visual acuity and refraction by comparing pre and postoperative values, IPCL implantation has little influence on IOP.

Among the main limitations of our study beside the small sample size is its short term follow-up in relation to the mean lifetime of this lens, which could be between 10 and 20 years. Another limitation of our study is the lack of comparison of different methods for anterior chamber evaluation. Further study with large sample size and longer follow-up period after surgery is required to ascertain the vault changes of IPCL and the factors affecting vault in the long-term. Possibility of primary angle closure and increment of pigmentation of trabecular meshwork after longterm follow-up should also be concerned.

#### *Conclusion:*

From our study we can conclude that, IPCL implantation for correction of high myopia leads to significant changes in the anterior chamber angle, volume and depth. It is safe and effective for the correction of high myopia specially, who were not suitable for other refractive surgery correction.

#### **References**

- 1- DOLGIN E.: The myopia boom. *Nature News*, 519 (7543): 276, 2015.
- 2- FRIEDMAN N.J. and KAISER P.K.: *Essentials of Ophthalmology*. Philadelphia, PA: Elsevier, 253-254, 2007.
- 3- IGARASHI A., SHIMIZU K. and KAMIYA K.: Eight-year follow-up of posterior chamber phakic intraocular lens implantation for moderate to high myopia. *Am. J. Ophthalmol.*, 157 (3): 532-539, 2014.
- 4- LIM D.H., LEE M.G., CHUNG E.S. and CHUNG T.Y.: Clinical results of posterior chamber phakic intraocular

- lens implantation in eyes with low anterior chamber depth. Am. J. Ophthalmol., 158 (3): 447-54, 2014.
- 5- SACHDEV G. and RAMAMURTHY D.: Long-term safety of posterior chamber implantable phakic contact lens for the correction of myopia. Clin. Ophthalmol., 13: 137-142, 2019.
- 6- LU Y., YANG N., LI X. and KONG J.: Four-year Follow-up of the Changes in Anterior Segment After Phakic Collamer Lens Implantation. Am. J. Ophthalmol., 178: 140-149, 2017.
- 7- MAHMOUD M.S.E., MOHAMED A.A. and ZEIN H.A.: Evaluation of the Anterior Chamber Angle by Anterior Segment Optical Coherence Tomography After Implantable Phakic Contact Lens Implantation in Myopic Eyes. Research Square, 2021.
- 8- ZHOU T., JIANG H., WANG Y., XIE C., XIA J. and SHEN Y.: Comparison of anterior chamber angle changes following phakic intraocular lens with and without a central hole implantation for moderate to high myopic eyes. Medicine, 99: 49 (e23434), 2020.
- 9- CHUNG T.Y., PARK S.C. and LEE M.O.: Changes in iridocorneal angle structure and trabecular pigmentation with STAAR implantable collamer lens during 2 years. J. Refract Surg., 25 (3): 251-8, 2009.
- 10- JU Y., GAO X.W. and REN B.: Posterior chamber phakic intraocular lens implantation for high myopia. Int. J. Ophthalmol., 6 (6): 831-5, 2013.
- 11- ELMOHAMADY M.N. and ABDELGHAFAR W.: Anterior chamber changes after Implantable Collamer Lens implantation in high myopia using Pentacam: A prospective study. Ophthalmol. Ther., 6: 343-9, 2017.
- 12- EISSA S.A., SADEK S.H. and EL-DEEB M.W.: Anterior Chamber Angle Evaluation following Phakic Posterior Chamber Collamer Lens with Centra FLOW and Its Correlation with ICL Vault and Intraocular Pressure. J. Ophthalmol., 2016: 1383289, 2016.
- 13- GOMEZ – BASTAR A., JAIMES M., GRAUE – HERNANDEZ EO, RAMIREZ – LUQUIN T., RAMIREZ-MIRANDA A. and NAVAS A.: Long-term refractive outcomes of posterior chamber phakic (spheric and toric implantable collamer lens) intraocular lens implantation. Int. Ophthalmol., 34: 583-590, 2014.
- 14- HUANG D., SCHALLHORN S.C., SUGAR A., FARJO A.A., MAJMUDAR P.A., TRATTLER W.B. and TANZER D.J.: Phakic intraocular lens implantation for the correction of myopia: A report by the American Academy of Ophthalmology. Ophthalmology, 116: 2244-2258, 2009.
- 15- YU Z., LI J. and SONG H.: Short-time evaluation on intraocular scattering after implantable collamer lens implantation for correcting high myopia. BMC Ophthalmology, 20: 235, 2020.
- 16- MIAO H., CHEN X., TIAN M., CHEN Y., WANG X. and ZHOU X.: Refractive outcomes and optical quality after implantation of posterior chamber phakic implantable collamer lens with a central hole (ICL V4c). Miao et al. BMC Ophthalmology, 18: 141, 2018.

## تقييم زاوية الغرفة الأمامية بواسطة التصوير المقطعي الأمامي التناسقي البصري قبل وبعد عدسة التلامس القابلة للزرع في مرضى قصر النظر العالي

قصر النظر خطأ في الإنكسار وهو منتشر بصورة مرتفعة جداً معظم المرضى الذين يعانون من قصر النظر متوسط إلى مرتفع يسعون إلى العلاج عن طريق الجراحة أو الليزر. لقد حظيت جراحات القرنية الانكسارية لتصحيح قصر النظر بقبول واسع في جميع أنحاء العالم. ومع ذلك، فإن الجراحة ليست آمنة للمرضى الذين لديهم مستوى عال من خطأ الانكسار أو قرنيات رقيقة نسبياً، حيث يمكن أن تزيد هذه الجراحات من خطر توسع القرنية بعد الجراحة.

الهدف من هذه الدراسة: هو تقييم زاوية الغرفة الأمامية بواسطة التصوير المقطعي الأمامي التناسقي البصري قبل وبعد عرسة التلامس القابلة للزرع في مرضى قصر النظر العالي. تم أخذ تاريخ مرضى كامل من المرضى ويشمل الإسم والعمر والجنس والمهنة والإقامة. التاريخ الحالي بما في ذلك، بداسة ظهور، ومدة قصر النظر. التاريخ السابق والتاريخ العائلي لأي مرض مزمن أو مرض مرتبط، أو أي اضطرابات بصرية أو تاريخ جراحة العين السابقة. تم فحص جميع المرضى عن طريق الفحص العام، والفحص الموضوعي لاستبعاد الحالات الطبية التي تزيد من خطر حدوث مضاعفات أثناء وبعد الجراحة، وكذلك لاستبعاد الحالات التي ترتبط بارتفاع ضغط العين. بالإشارة إلى البيانات الديموغرافية للمرضى الخاضعين للدراسة وجدنا لا يوجد فرق كبير بين المجموعات المدروسة فيما يتعلق بالعمر والجنس والعيون المصابة. بالإشارة إلى بيانات الغرفة الأمامية، وجدنا انخفاض في زاوية الغرفة الأمامية، بعد زرع عدسة التلامس القابلة للزرع (IPCL)، دون وجود فرق كبير بين المجموعات المدروسة. بالإشارة إلى حدة البصر، وجدنا تغييراً كبيراً في حدة البصر الغير مصححة (UCVA)، وأفضل حدة بصرية مصححة (BCVA)، بعد زرع عدسة التلامس القابلة للزرع (IPCL)، دون وجود فرق كبير بين المجموعات المدروسة.

من دراستنا يمكننا أن نستنتج أن زرع عدسة التلامس القابلة للزرع (IPCL) لتصحيح قصر النظر العالي يؤدي إلى تغييرات كبيرة في زاوية الغرفة الأمامية. كما إنه علاج آمن وفعال لتصحيح قصر النظر العالي خاصة لدى المرضى الذين لم يكونوا مناسبين لتصحيح الجراحات الانكسارية الأخرى.