

Anterior Approaches for Sub-Axial Cervical Fractures: Case Series

KHALED ISMAIL, M.D.*; RADWAN NOUBY, M.D.**; AHMED HAMAD, M.D.***;
AHMED BAKEER SAAD, M.Sc.* and AHMED HANY, M.D.*

The Department of Neurosurgery, Faculty of Medicine, Aswan*, Assuit** and Ain Shams*** Universities

Abstract

Background: Sub-axial cervical spine fractures can have devastating sequelae. A third of all spine injuries occur in the cervical region. 70% of cervical trauma occurs in sub axial region. Failure of proper management to sub-axial cervical spine trauma can lead to permanent disability lack of consensus in the management of sub-axial fracture questions the efficiency of different surgical approaches.

Aim of Study: Evaluation of different anterior surgical methods in treatment of sub-axial cervical spine trauma and fracture.

Patients and Methods: 42 patients with sub-axial cervical spine fractures who all were treated surgically with anterior approach were recruited. Of 42, 21 (50%) had corpectomy and Pyramesh placement with plate and 21(50%) had ACDF with single/multiple cages with or without plating. We collected operative data and performed follow-up for 12 months post-operatively. The collected data were analyzed using the SPSS to detected significant differences between both groups.

Study Design: Case series.

Results: Age of patients in the Study groups ranged from 15 years to 70 years, (average 39.1 ± 13.8 years). The injury levels in the majority of the 42 cases were at C4-5 (47.6%), C5-6 in (33.3%), C3-4 in (9.5%), C6-7 in (9.5%). Corpectomy group had significantly more blood loss and longer operative time than ACDF group. Both groups had similar rate of postoperative complications.

Conclusion: Anterior approaches for sub-axial fractures are efficient in preserving neurological function and stabilizing the fractures. Moreover, anterior procedure takes short time and could be of significant value in patients with medical comorbidities or when a short operative time is required.

Key Words: Cervical spine trauma – Sub-axial cervical fracture – Corpectomy with pyramesh placement – Cage or multiple cages placement with or without plating.

Correspondence to: Dr. Khaled Ismail, The Department of Neurosurgery, Faculty of Medicine, Aswan University

Introduction

THE Cervical spine is vulnerable to injury especially in polytraumatized patients because of its wide range of movement. The Subaxial cervical spine which includes from C3-C7 is responsible for 50% of cervical motion [1]. Injuries to this region yield the majority of morbidities and mortalities associated with spine injuries [1,2]. Two main mechanisms of injuries explain the vast majorities of cases; high energy motor vehicle accident in young age group and lower-energy traumas in older age group [3,4]. Sub-axial Cervical Spine Injury Classification (SLICS) scoring system is currently the most widely accepted classification for managing such injuries [5].

This system is based on three major criteria that should be taken in account in the decision taking: 1- Injury morphology; 2- Integrity of the Disco-ligamentous Complex (DLC) and 3- The neurological status of the patient. Each of these three factors is classified separately, with a final score resulting from the summation of these three variables, the system recommends management based on the final severity score [6,7].

Injuries with SLIC score of less than 3, and sometimes 4, points are treated nonsurgically. Soft collars used in mild cervical trauma without evident bone fractures Cervical collar help in healing of soft tissue injuries and in management of acute pain [8].

Computed tomography (CT), the golden standard imaging modality for cervical fractures and dislocations can detect and predict injuries ranging from minor ligamentous injuries to very severe burst fractures. Accurate clinical history, careful physical examination and detailed radiological evaluation must be done especially in such emer-

gency settings. Until now, there is no universally agreed protocol for managing sub axial cervical spine fractures [9]. Moreover, several questions emerge for dealing with such cases such as appropriate surgical approach, and the ideal timing for decompression [10,11]. In this study, we reported Postoperative Neurological condition as a primary outcome in patients who underwent anterior approach for sub axial cervical spine fracture in our University Hospital. Secondary outcome is the need for revision surgery through posterior approach in case of failure of fusion of anterior surgical approach.

Anterior approaches have the advantages of supine position, minor iatrogenic trauma, and direct anterior decompression of the neural elements, removing anterior compressive structures such as disk and bone. Anterior stabilization can also be used successfully in select posterior injuries [2].

Patients and Methods

Patients: We conducted a prospective case series at the Neurosurgery Department, Aswan University Hospital (Aswan, Egypt) from January 2019 to April 2020. 42 patients with sub-axial cervical spine fractures who were surgically treated with anterior approaches were recruited in the study. The study protocol was approved by Ethical Research committee at Aswan University Hospitals and all included patients signed a written informed consent before participation. Inclusion criteria are: Age between 15-70 years old, all post traumatic fractures, and SLIC ≥ 4 points. We excluded patients above 70 years old and below 15 years old, those who have pathological fracture or degenerative compression of spinal cord, and SLIC < 4 points.

Preoperative assessment: Evaluation included taking detailed history, neurological examination, routine lab investigations, and different imaging modalities (plain X-ray, CT, and MRI cervical spine), and application of Sub-axial Cervical Spine Injury Classification (SLICS) scoring system. Moreover, All patients were assessed using the Oswestry Disability Questionnaire, walking distance, and VAS pain score.(12) (13).

Skull traction:

In cases of facet dislocation, skull tongs such as Cones calipers were used for traction. Weights: 2.5kg for head and 1/2kg for each uninjured cephalad vertebra.

Surgical procedure:

Timing: Early decompression in Patients with Neurologic Deficits (less than 24 hours), whereas,

patients without deficits were operated within 48 hours of injury.

Procedure: Patients were placed in the supine position with the head in slight extension after removal of neck collar. Slight stretching of the head of the patient to unlock unilateral facet dislocation, allowing the inferior articular process of the dislocated vertebra to cross the superior process of the lower vertebra. Slight rotation of the neck toward the dislocated side allows reduction of the bilateral facet dislocation. Intraoperative X-ray fluoroscopy was utilized to confirm the reduction of dislocated vertebra.

Either a transverse skin incision or a longitudinal one on the right side of neck were made according to number of levels involved. Smith Robinson approach was used to access the cervical spine. An avascular dissection plane was developed between the esophagus and trachea, medially, and the sternocleidomastoid muscle and carotid sheath, laterally. Handheld retractors were utilized to provide good exposure of the anterior vertebral column and the adjacent muscles. Curettes and Kerrisons were used to remove the disc material and cartilage (Discectomy) or a drill to remove fractured vertebral body (corpectomy) to expose the posterior longitudinal ligament. Fusion was done with either a cage or Pyramesh and bone graft according to the need of each case.

Intraoperative data were recorded and included: operative time, blood loss, intraoperative complication, method of fusion, and number of involved levels.

Outcomes and follow-up: A neck collar was used for 1.5-2 months postoperatively.

We followed our patients in the immediate postoperative period (for post-operative complications), 2 weeks, 3 months, 6 months, and one year after surgery with clinical examination and follow-up, using X-ray and CT scan and MRI of cervical spine if needed.

Statistical analysis: The collected data were analyzed using Statistical analysis for Social Science (SPSS version 25 for windows, IBM, IL). Data summarized as mean \pm standard deviation. Categorical data displayed as frequency and percentage. We used Student's *t*-test to assess the statistical significance of the difference between two study group means.

Results

Table (1): Demographics and clinical data of patients included in study.

Variable	Number/range
<i>Total cases:</i>	42
ACDF	21 (50%)
Corpectomy	21 (50%)
<i>Sex:</i>	
Male	38 (90.5%)
Female	4 (9.5%)
<i>Age</i>	15-70 (39.1 ± 13.8)
<i>Risk factors:</i>	
Hypertension	15 (35.7%)
Diabetes	7 (16.7%)
Obesity	5 (11.9%)
Smoking	17 (40.5%)
Osteoporosis	3 (7.1%)
<i>Level of injury:</i>	
C3-4	4 (9.5%)
C4-5	20 (47.6%)
C5-6	14 (33.3%)
C6-7	4 (9.5%)

In this study, 42 cases were recruited with sub-axial cervical fractures that were operated anteriorly, 21 (50%) had ACDF, and the other 21 patients had corpectomy and Pyramesh placement.

Of 42 cases, 8 (19.05%) cases improved in postoperative follow-up, 29 (69.05%) maintained their neurological status and 4 cases (9.52%) deteriorated in early follow-up (3 months) but improved in late follow-up (6 months). Last one case (2.3%) deteriorated, and died post-operatively due to pneumonia.

As regard the secondary outcome, only one case (2.38%) out of 42 cases needed revision surgery through posterior approach.

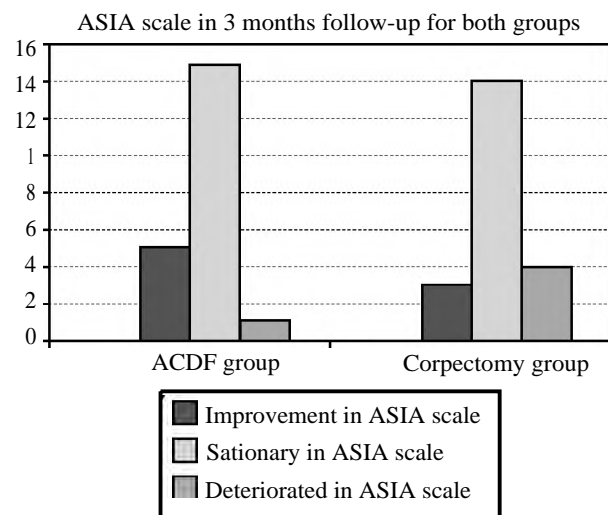


Fig. (1): Showing ASIA scale in a 3 months follow-up in both ACDF and Corpectomy group.

The subjective evaluation according to neck disability index after 6-month follow-up ranged from 0% to 37.1% with mean value 16.3% with a standard deviation of 11.3%.

The visual analogue scale (VAS) for pain after one-year follow-up ranged from 0 to 8 with mean value 1.4 (SD 2.3).

Operative data outcomes:

The median value and interquartile range of the period between admission and the operation is 3 days (2-4), Operative time ranges from 1 hour to 4 hours in some cases, The blood loss during operations ranges from 100ml blood loss to 500ml so blood transfusion was done in such cases, Number of image shots ranges from 5 shots in some cases to 20 shots in other cases.

But the mean value of the operative time, blood loss and image shots is as shown in the Table (2) below:

Table (2): Operative data outcomes.

	Mean value
Blood loss	216.7 ml (SD 82.7 ml)
Operative time	95.2 minutes (SD 25.1 minutes)
Number of image shots	9.3 shots (SD 2.3 shots)

Imaging studies:

1- Local kyphotic angle:

The median value and interquartile range of local kyphotic angle prior to surgical procedure was found to be 16° [11 - 20°]. This decreased to 1° [-5 - 8°] at early follow-up and further to 0° [-8 - 7°] at the late follow-up after one year.

The paired *t*-test showed that the mean difference between pre-surgery and late follow-up was significant (*p*<0.001) with a difference of 14.7° (Table 3).

2- Cervical lordosis:

Cervical lordosis readings were similar to local kyphotic angle ones in terms of statistical significance levels. The median value and interquartile range reading preoperative was 35° [29-43]. This increased to 40° [35-45°] and further to 44° [33-51°] at early and late follow-up respectively. A paired *t*-test detected significant difference (*p*=0.003) between pre-surgery and late follow-up readings with a mean difference of 7.3° (Table 3).

3- Step off distance:

The median value of step off distance decreased from 0.9cm (0.7-0.95) to 0.6cm (0.5-0.75). This was found to be of significance at 5% significance level with a mean difference of -0.2 and *p*-value of 0.001. (Table 3).

Table (3): Local Kyphotic Angle, Cervical Lordosis and Step off Distance at Preoperative and Late postoperative of 29 patients who complete one year postoperative

	Preoperative	One year postoperative	<i>p</i> -value
Local kyphotic angle	16° [11-20]	0° [-8-7]	<0.001
Cervical lordosis	35° [29-43]	44° [33-51]	0.003
Step off distance	0.9 cm (0.7-0.95)	0.6 cm (0.5-0.75)	0.001

Complications: Fig. (2).

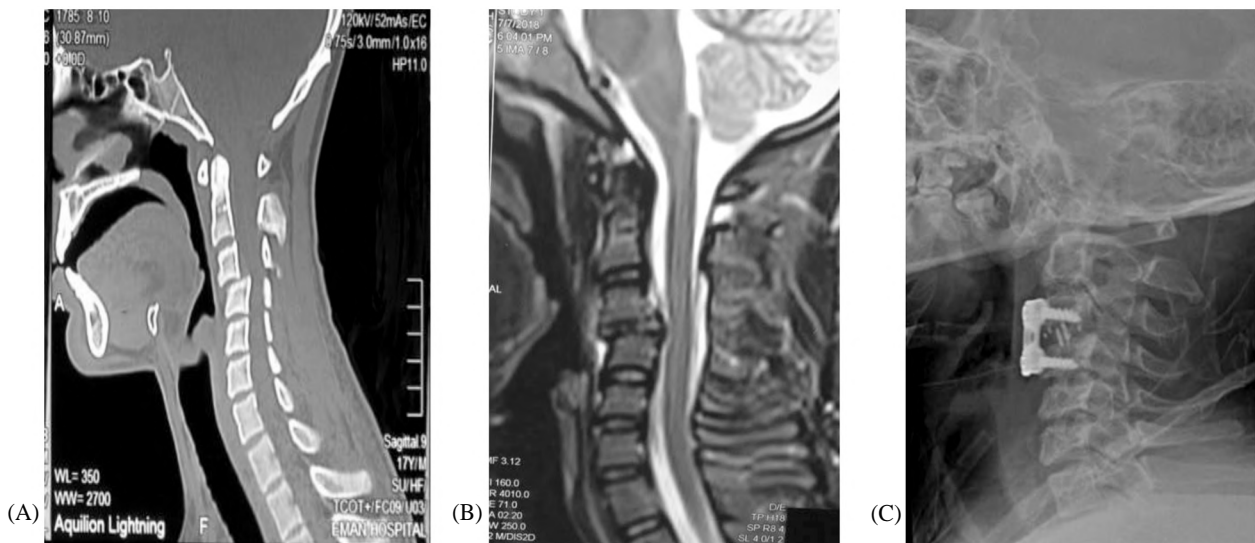
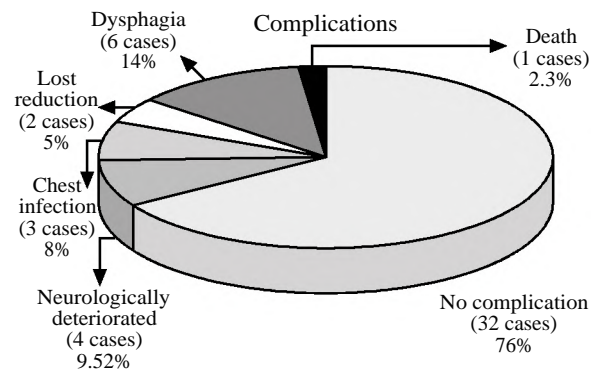


Fig. (3): (A) CT cervical spine sagittal view showing anterior displacement of C3 over C4, (B) MRI of cervical spine sagittal view showing anterior displacement of C3 over C4, (C) postoperative follow-up plain X-ray lateral view of cervical spine showing cage placement in C3-4 disc space and plate and screw insertion. Case presentation 2:

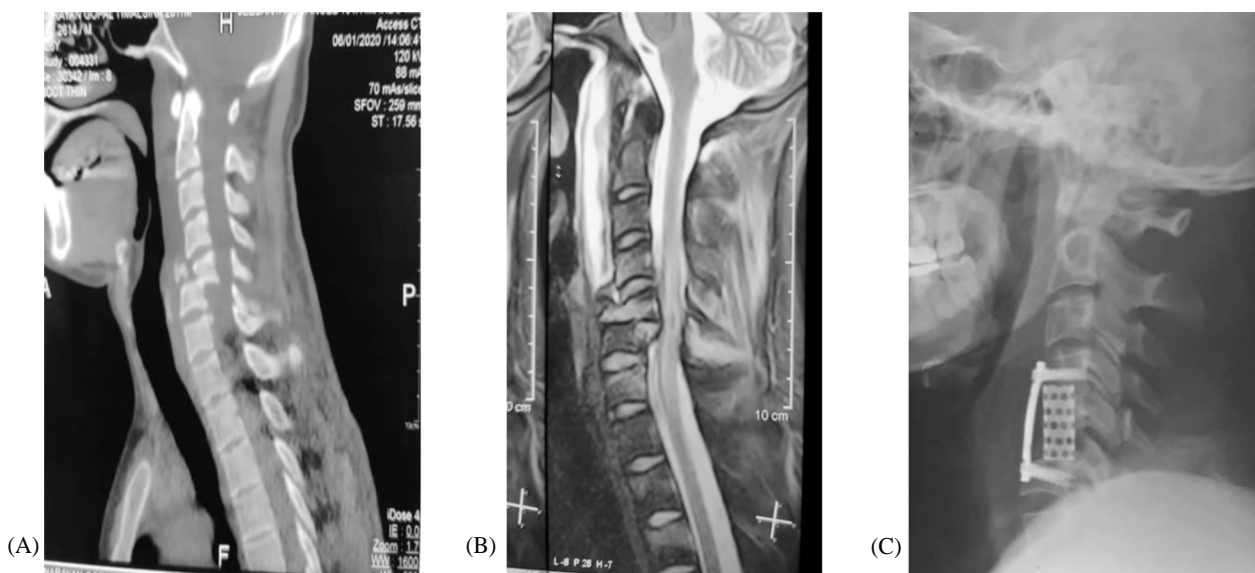


Fig. (4): (A) CT cervical spine sagittal view showing C5-6 fracture dislocation, (B) MRI of cervical spine sagittal view showing fracture dislocation of C5-6, (C) Post-operative plain X-ray lateral view of cervical spine showing corpectomy of C5 and pyramesh placement and plate insertion.

Discussion

Benefits of early surgery especially in patients with neurological deficit were demonstrated by The Surgical Timing in Acute Spinal Cord Injury Study (STASCIS). (STASCIS) recruited 222 patients with ages between 16 to 80 [14]. Neurological status was the primary outcome. The Study showed improvement in ASIA scale in 19.8% of the early group (operated in less than 24 hours) compared with only 8.8% in late group. Moreover, No additional risk was associated with early decompression. From there comes the emphasis of the literature on the importance of early intervention wherever resources and suitable circumstances existed.

Choosing the best approach (anterior, posterior, combined) could be sometimes tricky. As a general rule, the approach is chosen based on the needs of cervical decompression, reconstruction, and stabilization.

Advances in spine biomechanics, instrumentation and improved radiologic imaging have greatly expanded our understanding of cervical sub-axial traumatic injuries. Whereas, most cervical sub-axial trauma was treated by posterior approaches in the past, there is now significant evidence suggested that an anterior approach is similarly effective for stabilization [15].

Being less traumatic and providing interbody grafting with reconstruction and maintenance of lordosis are important advantages of the anterior approaches [16].

Additionally, they provides direct anterior decompression of the neural elements, removing ventral compressive structures such as disk and bone. Also, they utilise the supine position which is favourable when compared with the prone position especially in polytraumatized patient.

Moreover, Anterior stabilization could be successfully used in selected posterior injuries [17].

Posterior approaches can produce a disastrous outcome if reduction without a reliable neurologic examination is attempted in case of the anterior cord compression [18].

MRI is recommended to avoid clinical worsening in case of disk herniation prior to open surgical reduction.

In this study, 42 cases were recruited with sub-axial cervical fractures that were operated anteriorly, 21 (50%) had ACDF, and the other 21 patients had corpectomy and Pyramesh placement.

Of 42 cases, 8 (19.05%) cases improved in postoperative follow-up, 29 (69.05%) maintained their neurological status and 5 cases (11.91%) deteriorated in early follow-up (3 months) but improved in late follow-up (6 months). Of the 5 cases that deteriorated, one died postoperatively due to pneumonia.

As regard the secondary outcome, only one case (2.38%) out of 42 cases needed revision surgery through posterior approach.

In a study conducted by Reindl et al., on 92 patients with sub-axial cervical injuries operated by anterior approaches, satisfactory reductions occurred in 90 patients in the anterior group. There were two cases of failure of anterior reduction who needed additional posterior reduction. All patients achieved solid fusion within two years after surgery [19].

Mean of operative time in our study was 95.2 ± 25.1 minutes while that of blood loss was 216.7 ± 82.7 ml. It is obvious that the anterior approach takes shorter operative time than the posterior approach.

Brian Kown et al., reported that the mean operative time was 103 minutes and the average blood loss was less than 100ml. [20]. Also the same results were revealed by the study of Yasutsugu Yukawa et al., in which the mean operative time was 101 minutes and the mean blood loss was 190ml. [21].

In Elizabeth Chong, Ralph J. Mobbs, et al., [25] patients with traumatic and degenerative cervical disc prolapse operated with discectomy and cage placement without plate, VAS scores for neck and arm pain showed significant improvement ($p < 0.001$) between pre- (7.1 ± 1.9) and postoperative (2.0 ± 1.7) scores (average improvement 4.6 ± 2.1). There was no significant difference in VAS score improvement between the plated and non-plated groups. Mean preoperative neck disability index (NDI) scores were 44.0 ($SD \pm 15.2$) with a mean improvement of 24.7 ($SD \pm 8.8$) to an average postoperative score of 26.4 ($SD \pm 21.7$) ($p = 0.039$). According to Odom's criteria, there were 16 excellent, 7 good, 2 fair and no poor outcomes, 92% of patients achieving a good or excellent clinical outcome. There was no significant difference between the plated and non-plated groups [22].

In our study, 21 cases operated by corpectomy of single level and pyramesh placement.

One case died due to chest infection, and another case had posterior stabilization later on. All the 20

cases show clinical and neurological improvement by at least one grade according to ASIA impairment scale and one or more than one degree by visual analogue score, the follow-up period from 2 weeks till one year post-operative.

The current study shows that the anterior approach is effective in neurological improvement of the neurological impaired patients at the late follow-up as it allows easy decompression of the disco-ligamentous material of the affected segment which was proven to be the commonest cause of neurological deterioration in lower cervical trauma. Moreover, 4 case of 42 cases (9.5%) that neurologically deteriorated in early postoperative, have improved at late follow-up, and only one case died of pneumonia.

In Zeena Dorie, M.D., Howard Morgan, et al., In 44 patients out of 45 patients a solid arthrodesis was achieved without complications related to the cage and plate reconstruction, based on cervical CT scans or flexion-extension X-ray films. Twenty-three patients underwent with one-level, 17 with two-level, and five with three-level corpectomy. The follow-up period ranged from 6 to 33 months (mean 12.9 months). Cervical fusion rate was determined by means of cervical CT scanning and/or flexion-extension radiography. Four patients underwent two-level corpectomies and discectomies at adjacent levels. Fibular allograft bone was used to fuse the discectomy sites, and this required extension of the ACP implant. Patients in whom placement of posterior instrumentation was planned were excluded from the study [23].

Brodke et al., study included 52 patients with reduced unstable cervical spine injuries who were randomized for anterior versus posterior stabilization and fusion [24]. He excluded cases who required reduction and decompression. He concluded that no significant differences in neurologic recovery, fusion rates, or long-term complaints with regards to the approach chosen.

A prospective randomized study was by Kwon et al., comparing anterior versus posterior stabilization for unilateral facet injuries in 42 patients [25].

The authors had a similar results to Brodke et al., study and moreover, they found that anterior approaches had a lower rate of wound infections, less postoperative pain, and a higher fusion rate. There were no reported differences in patient outcome measures. The authors conclude that either anterior or posterior fixation approaches are valid and safe techniques to treat unilateral facet injuries.

Conclusion:

Surgical treatment of lower cervical traumatic instability by means of anterior decompression and fusion is efficient regarding the neurological outcome and the patients' satisfaction; also the anterior procedure takes short time and appears to be less traumatic to patients. However, the angle of the injured segment doesn't return to its normal lordosis, and the full reduction was not achieved. Consequently, we recommend the anterior approach alone in cases with neurological impairment and in patients with medical co-morbidities or when a short operative time is required.

References

- 1- KWON B.K., VACCARO A.R., GRAUER J.N., et al.: Subaxial cervical spine trauma. *J. Am. Acad. Orthop. Surg.*, 14: 78-89, 2006.
- 2- VACCARO A.R., HULSERT R.J., PATEL A.A., et al.: The subaxial cervical spine injury classification system: A novel approach to recognize the importance of morphology, neurology, and integrity of the disco-ligamentous complex. *Spine (Phila Pa 1976)*, 32: 2365-74, 2007.
- 3- UHRENHOLT L., CHARLES A.V., HAUGE E., et al.: Pathoanatomy of the lower cervical spine facet joints in motor vehicle crash fatalities. *J. Forensic Leg Med.*, 16: 253-60, 2009.
- 4- LOWERY D.W., WALD M.M., BROWNE B.J., et al.: Epidemiology of cervical spine injury victims. *Ann. Emerg. Med.*, 38: 12-6, 2001.
- 5- AARABI B., WALTERS B.C., DHALL S.S., et al.: Subaxial cervical spine injury classification systems. *Neurosurgery*, 72: 170-86, 2013.
- 6- Med. per Hjalmar Nakstad. Classification of acute subaxial cervical spine injury. [dissertation on the Internet] Oslo: University of Oslo, 2012.
- 7- JOAQUIM A.F. and PATEL A.P.: Occipito-cervical trauma: evaluation, classification and treatment. *Contemporary Spine Surgery*, 32 (12): 1-6, 2010.
- 8- SANCHEZ B., WAXMAN K., JONES T., CONNER S., CHUNG R. and BECERRA S.: Cervical spine clearance in blunt trauma: Evaluation of a computed tomography-based protocol. *J. Trauma*, 59 (1): 179-183, 2005.
- 9- CARLSON G.D., GORDEN C.D., OLIFF H.S., et al.: Sustained spinal cord compression: Part I: Time-dependent effect on long-term pathophysiology. *J. Bone Joint Surg. Am.*, 85: 86-94, 2003.
- 10- FEUCHTBAUM E., BUCHOWSKI J. and ZEBALA L.: Subaxial cervical spine trauma. *Curr. Rev. Musculoskelet Med.*, 9: 496-504, 2016.
- 11- PARK J.H., ROH S.W. and RHIM S.C.: A single-stage posterior approach with open reduction and pedicle screw fixation in subaxial cervical facet dislocations. *J. Neurosurg. Spine*, 23: 35-41, 2015.
- 12- MEHRA A., BAKER D., DISNEY S. and PYNSENT P.B.: *Oswestry Disability Index Scoring Made Easy*, 2008.

- 13- LUDGER KLIMEK, KARL-CHRISTIAN BERGMANN, TILO BIEDERMANN, JEAN BOUSQUET, et al.: Visual analogue (VAS): Measuring instruments for the documentation of symptoms and therapy monitoring in cases of allergic rhinitis in everyday health care, 2017.
- 14- FEHLINGS M.G., VACCARO A., WILSON J.R., et al.: Early versus delayed decompression for traumatic cervical spinal cord injury: Results of the Surgical Timing in Acute Spinal Cord Injury Study (STASCIS). *PLoS ONE*, 7 (2): e32037, 2012.
- 15- WOODWORTH R.S., MOLINARI W.J., BRANDENSTEIN D., GRUHN W. and MOLINARI R.W.: Anterior cervical discectomy and fusion with structural allograft and plates for the treatment of unstable posterior cervical spine injuries. *J. Neurosurg. Spine*, 10: 93-101, 2009.
- 16- REINDL R., OUELLET J., HARVEY E.J., BERRY G. and ARLET V.: Anterior reduction for cervical spine dislocation. *Spine*, 31: 648-52, 2006.
- 17- WOODWORTH R.S., MOLINARI W.J., BRANDENSTEIN D., GRUHN W. and MOLINARI R.W.: Anterior cervical discectomy and fusion with structural allograft and plates for the treatment of unstable posterior cervical spine injuries. *J. Neurosurg. Spine*, 10 (2): 93-101, 2009.
- 18- EISMONT F.J., ARENA M.J. and GREEN B.A.: Extrusion of an intervertebral disc associated with traumatic subluxation or dislocation of cervical facets. Case report. *J. Bone Joint Surg. Am.*, 73 (10): 1555-1560, 1991.
- 19- REN C., QIN R., WANG P. and WANG P.: Comparison of anterior and posterior approaches for treatment of traumatic cervical dislocation combined with spinal cord injury: Minimum 10-year follow-up. *Scientific Reports*, 10 (1). doi:10.1038/s41598-020-67265-2, 2020.
- 20- BRIAN K. KWON, ALEXANDER R. VACCARO, JONATHAN N. GRAUER, et al.: Sub-axial Cervical Spine Trauma. *Journal of the American Academy of Orthopaedic Surgeons*. February, Vol. 14, 2006.
- 21- YASUTSUGU YUKAWA, FUMIHIKO KATO, KEIGO ITO, et al.: Placement and complications of cervical pedicle screws in 144 cervical trauma patients using pedicle axis view techniques by fluoroscope. *European Spine Journal*, Vol. 18: P. 1293-1299, 2009.
- 22- ELIZABETH CHONG, M.D. 1,2, RALPH J. MOBBS, M.D. 1,3,4, MATTHEW H. PELLETIER, Ph.D.2 and WILLIAM R. WALSH, Ph.D.2,1: University of New South Wales, 2 Surgical and Orthopaedic Research Laboratories, Prince of Wales Clinical School, 3 NeuroSpine Clinic and 4 Department of Spine Surgery, Prince of Wales Hospital, Randwick, NSW, Australia, 2016.
- 23- ZEENA DORAI, M.D., HOWARD MORGAN, M.D. and CAETANO COIMBRA, M.D. Titanium cage reconstruction after cervical corpectomy Department of Neurological Surgery, University of Texas and Southwestern Medical Center, Dallas, Texas, 2003.
- 24- BRODKE D.S., ANDERSON P.A., NEWELL D.W., GRADY M.S. and CHAPMAN J.R.: Comparison of anterior and posterior approaches in cervical spinal cord injuries. *J. Spinal Disord Tech.*, 16 (3): 229-235, 2003.
- 25- KWON B.K., FISHER C.G., BOYD M.C., et al.: A prospective randomized controlled trial of anterior compared with posterior stabilization for unilateral facet injuries of the cervical spine. *J. Neurosurg Spine*, 7 (1): 1-12, 2007.

التدخل الجراحي من الأمام لكسور الفقرات العنقية بعد الفقرة الثانية العنقية : لعدد من الحالات

مقدمة: كسور العمود الفقري العنقي ما بعد الفقرة العنقية الثانية من الممكن أن تسبب مضاعفات وإصابات شديدة تضر بالحبل الشوكي والأعصاب مما يؤدي إلى مضاعفات حركية وحسية قد تصل إلى فقدان الإحساس والحركة في الاطراف الأربعة.

إصابات وكسور الفقرات العنقية تمثل ثلث إصابات العمود الفقري. ٧٠٪ من إصابات الفقرات العنقية تحدث في المنطقة من الفقرة العنقية الثالثة وحتى الفقرة العنقية السابعة.

نوع الدراسة: دراسة حالات ومتابعتها.

الهدف من الدراسة: تقييم طرق الجراحة الأمامية المختلفة في علاج إصابات وكسور العمود الفقري العنقي ما بعد الفقرة العنقية الثانية.

نوعية المرضى وطريقة البحث: تم تشخيص ومتابعة ٤٢ مريضاً يعانون من إصابات وكسور العمود الفقري العنقي ما بعد الفقرة العنقية الثانية والذين تم علاجهم جميعاً جراحياً باستخدام الطرق الجراحية الأمامية. ٢١ حالة (٥٠٪) خضعوا لاستئصال الغضروف ووضع القفص العنقي و ٢١ حالة (٥٠٪) خضعوا لاستئصال الفقرة المتضررة والغضروف ووضع الشبكة العنقية. قمنا بجمع البيانات الجراحية وأجرينا المتابعة لمدة ١٢ شهراً بعد الجراحة.

النتائج: تراوح العمر في مجموعات الدراسة من ١٥ سنة إلى ٧٠ سنة (متوسط ١.٣٩ ± ٨.١٣ سنة). كانت مستويات الإصابة في غالبية الحالات الـ ٤٢ بين الفقرة الرابعة والخامسة إلى ٦.٤٧٪، وبين الفقرتين العنقية الخامسة والسادسة إلى ٣.٢٣٪، وبين الفقرة الثالثة والرابعة العنقية إلى ٥.٩٪، وبين الفقرة السادسة والسابعة العنقية إلى ٩.٥٪.

في الحالات التي تم إجراء استئصال للفقرة المكسورة والغضروف وتركيب شبكة عنقية تم فقدان دم أكبر بشكل ملحوظ ووقت إجراء أطول في الجراحة من الحالات التي تم إجراء استئصال الغضروف فقط وتركيب قفص عنقي. كان لدى كلا المجموعتين معدل مماثل من مضاعفات ما بعد الجراحة.

الخلاصة: الطرق الجراحية الأمامية المختلفة في علاج إصابات وكسور العمود الفقري العنقي ما بعد الفقرة العنقية الثانية فعالة في الحفاظ على الوظيفة العصبية وتثبيت الكسور. علاوة على ذلك، فإن الإجراء الأمامي يستغرق وقتاً قصيراً ويمكن ذا قيمة كبيرة في المرضى الذين يعانون من أمراض طبية مشتركة أو عندما يتطلب الأمر وقتاً قصيراً للعملية.