

Bone Plug Fixation in ACL Reconstruction: A Clinical and Radiological Assessment of Post-Operative Tunnel Widening

ABDELAZEZ SENGERGY, M.D.; HISHAM MISBAH, M.D.; HAZEM FAROUK, M.D.;
TAREK BEN ZIAD MORAD, M.D.; SABRY M.H. MANAA, M.D.; AHMED SHABAN HASSAN, M.D. and
AHMED HAMDY TOLBA, M.D.

The Department of Orthopedic Surgery, Faculty of Medicine, Cairo University

Abstract

Background: The decision regarding graft choice and fixation in ACL reconstruction procedure remains controversial. Free cylindrical bone plugs has been used as a graft fixation method successfully. Still some concerns exist about how well these plugs integrate with the bony walls of the tunnel.

Aim of Study: Is to assess bone to bone healing and tunnel widening, and evaluating its effect on the clinical outcomes of the procedure.

Patients and Methods: From January 2015 to December 2017, 30 patients (21-40 yrs) with torn ACL were operated upon and followed-up for 24 months after surgery. All patients were assessed clinically using (IKDC & T-L), instrumentally (KT1000 & Rolimeter), and radiologically with X-rays, CT & MRI. Young active patients with torn ACL were included while those with previous ligamentous injury and/or surgery were excluded.

Results: All bone grafts showed solid bone healing after 6 months of surgery; bone healing is Good to Excellent (Tibial side; 66.6%-Femoral Side; 86.6%). No correlation between age or time interval with graft incorporation. Positive correlation shown between tibial and femoral graft incorporation within the same patient. Only one patient abnormal in our final Objective IKDC scores (graded C). The mean side-to-side differences with KT 1000 and Rolimeter was 1.9 and 1.8 respectively.

Conclusion: Free cylindrical bone plug could be used safely for hamstring tendon graft fixation. It enhances bone to bone healing and tunnel narrowing within the first 6 months. It yields comparable clinical outcomes yet avoiding potential hazards of foreign hardware implants.

Study Design: Case series.

Key Words: Bone plug fixation in ACL reconstruction – Press fit technique – ACL tunnel dilatation.

Introduction

THE anterior cruciate ligament (ACL) is regarded as critical to the normal functioning of the knee,

Correspondence to: Dr. Tarek Ben Ziad Morad,
[E-Mail: tarekebnziad2009@hotmail.com](mailto:tarekebnziad2009@hotmail.com)

and its rupture affects knee stability [1]. When treating a torn ACL, many decisions must be made, especially if surgery is to be performed. The decision regarding graft choice and fixation remains the most controversial [2,3].

Complications related to internal fixation devices are many, and tunnel dilatation are among those which might jeopardise graft stability and makes any revision surgery even more difficult. With the increase of ACLR procedures at a young age, the potential for a revision surgery later in life increases as well.

The use of bone plugs on either end of the tendon graft has been studied previously and proved efficient as a hardware-free ACL reconstruction technique [4,5]. Recently, Free cylindrical bone plugs press fitted within the drilled ACL tunnels has been described with successful clinical outcomes [6]. This technique facilitates bone to bone integration and leaves less bone defects after the procedures which allows an easier revision surgery. The aim of this study is assess tunnel widening after ACL reconstruction procedure with press fit bone plug fixation. We hypothesise that using cylindrical bone plug fixation decrease tunnel widening after the procedure, yet provides stable fixation for the graft that sequentially improves the clinical outcome.

Patients and Methods

From January 2015 to December 2017, 30 patients with torn ACL as confirmed by clinical tests and MRI were operated upon by same surgeon using the same technique and followed-up for at least 24 months after surgery. All patients were assessed clinically pre operatively using International Knee Documentation Committee score (IK-

DC), Lysholm activity score. Patients were discharged on the 2nd day after surgery and were followed-up by weekly for 3 months. Clinical assessment with IKDC & Lysholm activity score were done starting 12 weeks post operatively, then repeated at 3 months interval for the first year. The final clinical evaluation at the end of the second year is documented. Instrumental testing with the Rolimeter 50A (Aircast Incorporated USA) & KT1000TM (MEDmetric® Corporation, San Diego, CA) were done at the end of the follow up period (2 years). Radiological assessment with plain X rays were performed at 3 months and CT scan performed at 6 months postoperative. Our study population included 28 males & 2 females aged between 21 and 40 years (mean 27.9 yrs) with right side dominance in 21 (70 %). Young active patients with torn ACL and symptoms of knee joint instability were included in our study while those with either previous ipsilateral knee ligamentous injury and/or surgery are excluded. Patients aged less than 18 years and more than 50 with radiological evidence of osteoarthritis were also excluded. Time interval between injury and operation ranged from 1-12 months, the mean interval 4.7 months with $2.6 \pm SD$. More than 50% were injured during sporting activity and less than 7 % had level IV pre injury level of activity. (Table 1) patients had meniscal injury, 5 of which had repair with an outside-in technique, while partial meniscectomy was done for 14 patients. Only 2 patients had chondral lesions for which micro fracture procedure has been done. Subjective clinical assessment was done for all patients using the IKDC and the Tegner-Lysholm Knee Scoring system. Results were expressed as a percentile score pre operatively at the same day of surgery then postoperatively with every postoperative visit at 3, 6, 9 and 12 months. The results of these scoring systems at the end of twenty fourth months were considered the final results. Objective assessment was done by an independent examiner using the IKDC knee examination form and graded into A, B, C, and D. Instrumentally, numerical values for the side to side difference were measured using a KT1000 and digital rollimeter in every follow up visit. Radiological assessment for the tunnel diameter was done through post-operative X-ray & CT scan imaging. A slice multi-detector CT scan of the femoral and tibial tunnel (Philips 16 slice-MX 16). Post-processing multi-slab reconstructions on the sagittal, axial and coronal planes was also done. MSCT scanning was performed from a level just above the femoral external foramen to a level below the outer hole of the tibial tunnel in order to visualise the positioning of 40 the graft. The

slice thickness was 1mm, with retro-reconstruction of 0.75mm made in all patients before post processing imaging with multi-slab views. The tunnels size were analyzed. This was done by visual analysis of the CT layers by an independent radiologist (software of CT work station Brilliance EBW). Slice thickness and table increment either were 1x1mm or 1.25x1.25 mm, for total of approximately 20 images. Comparison of numerical variables between pre and post-operative values were done using paired *t*-test. *p*-values less than 0.05 was considered statistically significant. All statistical calculations were done using computer program SPSS (Statistical Package for the Social Science; SPSS Inc., Chicago, IL, USA) release 15 for Mi70crosoft Windows (2006).

Table (1): Shows the patients categorized according to the time interval between the knee injury and the operation.

Time Interval	N	%
Less than one month	2	6.67
1-6 months	20	66.67
7-12 months	8	26.66
Total	30	100%

Bone tunnels diameter assessment:

A sagittal, coronal and axial cuts perpendicular to the sagittal and coronal axis of the femoral and tibial bone tunnel were generated.

The reference tunnel diameter measurements were taken as follows:

A- Femoral tunnel:

- F1: Femoral tunnel at the notch, axial.
- F2: Femoral tunnel in the middle point, axial.
- F3: Femoral tunnel in the middle point, coronal image.
- F4: Femoral tunnel in the middle point, sagittal image.

From the measured values at the level of the notch (F 1) will be (F0), from the measured values at the level of the midpoint (F2, F3, F4) an arithmetical mean (F1) was formed. (Fig. 1).

B- Tibial tunnel:

The distal part of tibial tunnel not assessed due to over drilling of this part during surgery, we assess from tibial plateau to 10mm below. (The distal part of the tibial tunnel is over dilated using a conical trephine drill to enlarge the diameter of the tunnel distally and extend proximally to stop

around 10mm distal to the articular surface of the tibial plateau.).

- T 1: Tibial tunnel axial at plateau.
- T2: Tibial tunnel axial at 5mm below plateau.
- T3: Tibial tunnel sagittal at plateau.
- T4: Tibial tunnel sagittal at 5mm below plateau.

From the measured values at the level of the tibial plateau (T1, T3) an arithmetical mean (T0) was formed, from the measured values at the level of the midpoint (T2, T4) an arithmetical mean (T 1) was formed. These bone tunnel diameters compared with the intraoperative tunnel diameter. (Fig. 2).

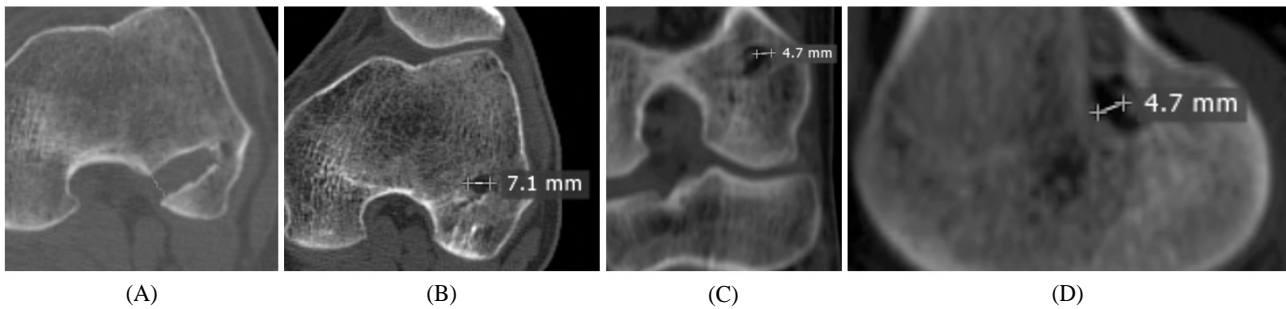


Fig. (1): (A): F1 femoral tunnel at the notch, axial, (B): F2, femoral tunnel in the middle point, axial & (C): F3, femoral tunnel in the middle point, on coronal image reconstruction & (D): F4, femoral tunnel in the middle point, on sagittal image reconstruction.

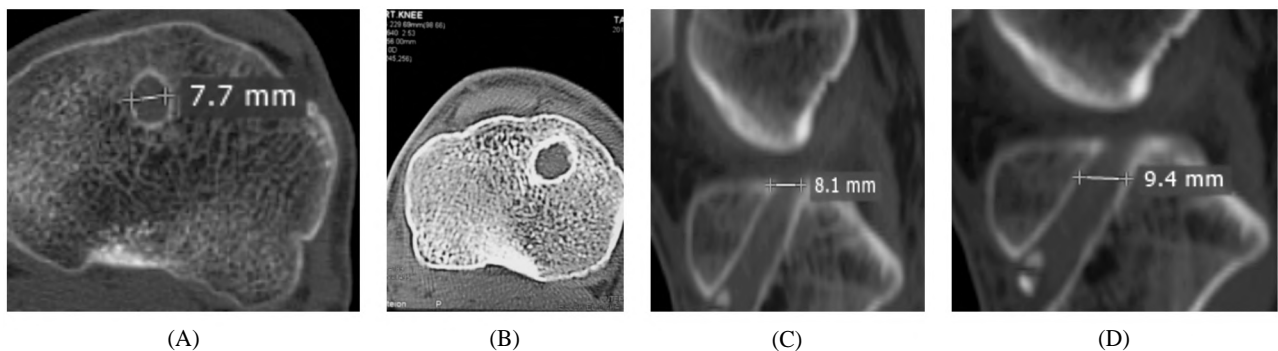


Fig. (2): (A): T1, tibial tunnel, axial at plateau. (B): T2, tibial tunnel, axial at 5mm below plateau. (C): T3, tibial tunnel, sagittal at plateau. (D): T4, tibial tunnel, sagittal 5mm below plateau.

Surgical technique:

Hamstring tendon graft were initially harvested and prepared. Then, the first bone plug is harvested from the proximal tibial through the same incision nearly 15mm below the joint line using SDI (Surgical Diamond Instruments). The bone plug is then incorporated into the 2 distal end of the graft with sutures through, above and below the bone plug to secure it in place, leaving 2 bony windows in which the bone plug is not covered by the 2 slips of the tendon ends. Routine ACL reconstruction procedure continues with the femoral tunnel reamed using the SDI as well. The bony cylinders extracted out of both tunnels were kept in saline for use during fixation after graft passage. The distal part

of the tibial tunnel is over dilated using a conical trephine drill to enlarge the diameter of the tunnel distally and extend proximally to stop around 10 mm distal to the articular surface of the tibial plateau. The graft is then passed through the tibial tunnel till the distal end of the graft (Plug-graft composite) press-fits into the funnel shaped distal part of the tibial tunnel and further pushed into the tunnel using a push rod and a hammer to ensure a press-fit distal fixation. The bony cylinder extracted from the femoral tunnel is now divided in two pieces and each piece is place inside the applicator and pushed into the tunnel above the tendon graft (Fig. 3). The tendon flattens as the plug is introduced in a press-fit manner taking a crescent semilunar shape. (Fig. 4).




Fig. (3): Graft preparation (A&B): Harvesting, (C): Bone plug inside tendon.

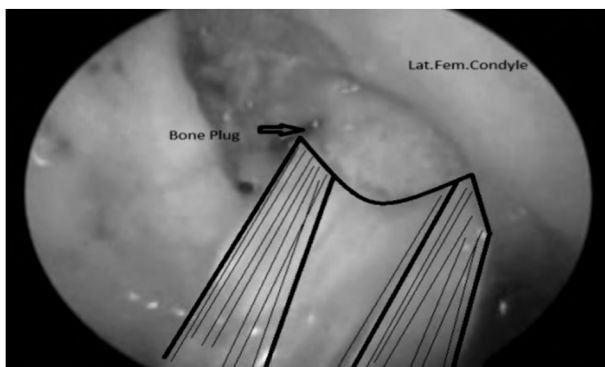


Fig. (4): A crescent semilunar shape.

Post-operative protocol:

During the first week, signs of infection or effusion are sought after, then stitches are removed 10-14 days post-operative. Follow-up visits are scheduled every weeks for the first 3 months after surgery and every 3 months thereafter to monitor the rehabilitation process. The accelerated rehabilitation protocol starts with home exercises on the day of hospital discharge (2nd day post-operative) and after 14 days post-surgery, the patient continues his rehabilitation in a facility with a specialised physiotherapy team. It entails full weight bearing with a knee immobilizer and crutch, immediate unlimited range of motion, strengthening exercises emphasizing full extension of the knee, and an early return to athletic activity (4-6 months). Patients with meniscal repair (2 patients) follow a similar protocol except for using a hinged knee brace that does not allow flexion range to exceed 90 degrees during the first 6 weeks then range is increased gradually.

Results

Radiological assessment:

Immediate post-operative X-ray:

Immediate postoperative X-ray measurement of tibia and femoral tunnels diameter measurement at fixed point 5mm from articular surface in both tunnels. (Table 2, Fig. 5).

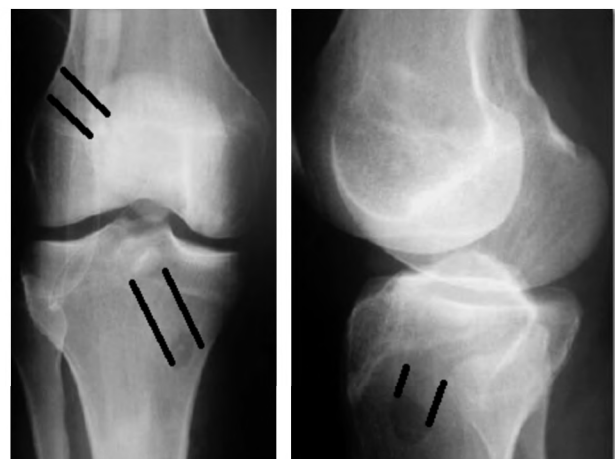


Fig. (5): Immediate post operative X-ray AP & lat.

Table (2): Post operative X-ray measurement.

	N	Mini- mum	Maxi- mum	Mean	Std. Deviation
PO X-ray Tibia	30	8	10	8.50	.572
PO X-ray Femur	30	7	9	8.10	.548
Total	30				

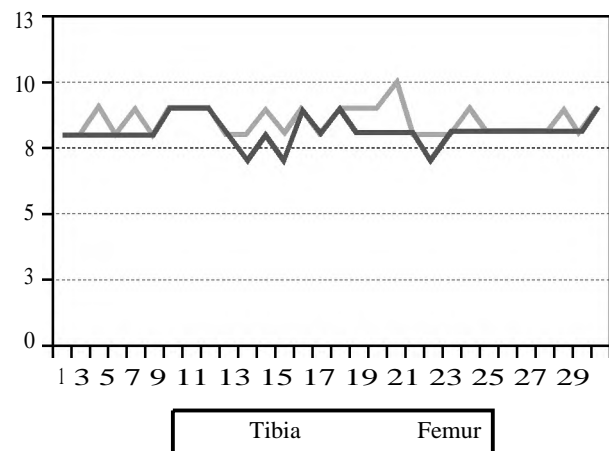


Fig. (6): Immediate post operative X-ray measurement Femoral & tibial bone tunnels.

Assessment of tibial tunnel diameter:

Within the interval from surgery to follow-up, the bone tunnel diameter on the articular cortex level (T0) was 11 % larger than the size of the reamer used intraoperatively (MD 9.437mm ± SD; 0.71mm; $p < 0.05$). At mid-point (T1) the bone tunnel size was 5% smaller than the reamer used intraoperatively (MD 8.07mm; SD 0.70mm; $p = .0002$) (Table 3, Fig. 7).

Assessment of femoral tunnel diameter:

the bone tunnel diameter on the Notch (F0) was 5.59% smaller than the size of the reamer used intraoperatively (MD 7.6mm ± SD; 0.488mm; $p < 0.05$). At mid-point (F1) the bone tunnel size was 7.4% smaller than the reamer used intraoperatively (MD 7.4mm; SD 0.503mm; $p < 0.05$) (Table 4, Fig. 8).

The results of one sample *t*-test between post operative femoral and tibial X-ray measurement and 3 months post operative CT measurement are

statistically significant, as demonstrated below (Table 4).

The results indicate that with improvement of graft integration the tunnel dilation decrease. With Increasing in femoral graft incorporation the tibial graft incorporation improve (p -value < 0.05).

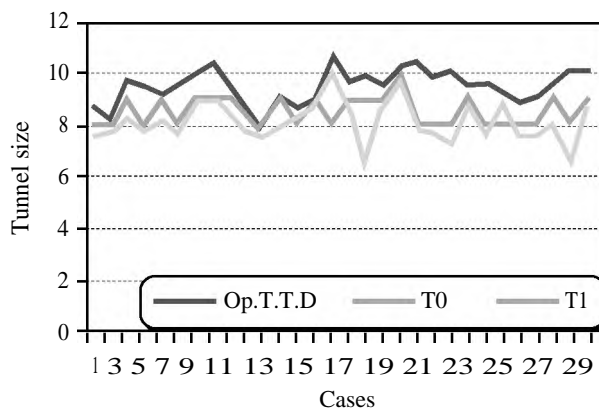


Fig. (7): Operative Tibial Tunnel Diameter (Op.T.T.D) and 3 months postoperative at tibial plateau (T0) and at mid. tunnel point (T1).

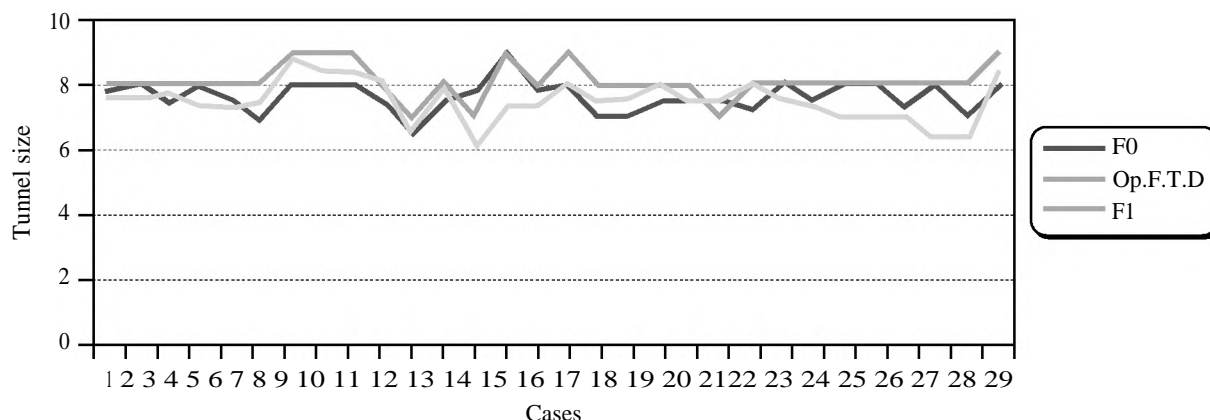


Fig. (8): Operative Femoral Tunnel Diameter (Op.F.T.D) and 3 months postoperative at Notch (F0) and at mid. tunnel point (F1).

Table (3): Mean statistic values and SD of bone tunnel diameter, size of intraoperative reamer and bone tunnel diameter 3 months post-operative.

	Paired Differences					<i>t</i>	df	<i>p</i> -value
	Mean	Std. Deviation	Std. Error Mean	95% Confidence Interval of the Difference				
				Lower	Upper			
tib.tunnel.diam - T0	-0.9367	0.7122	0.1300	-1.2026	-0.6707	-7.203	29	0.000
tib.tunnel.diam - T1	0.4300	0.7013	0.1280	0.1681	0.6919	3.358	29	0.002
fem.tun.diam - F0	0.4533	0.4883	0.0892	0.2710	0.6357	5.085	29	0.000
fem.tun.diam - F1	0.6033	0.5034	0.0919	0.4154	0.7913	6.564	29	0.000

Table (4): One-Sample Test post operative X-ray and CT.

	Test value=0					
	t	df	P-value	Mean Difference	95% Confidence Interval of the Difference	
					Lower	Upper
PO X-ray Tibia	81.342	29	.000	8.500	8.29	8.71
PO X-ray Femur	81.000	29	.000	8.100	7.90	8.30
<i>CT:</i>						
F0	86.911	29	.000	7.647	7.47	7.83
F1	63.126	29	.000	7.49667	7.2538	7.7396
T0	79.078	29	.000	9.43133	9.1874	9.6753
T1	58.337	29	.000	8.05667	7.7742	8.3391

Table (5): Correlation between femoral and tibial tunnel dilatation and Femoral & Tibial Graft Incorporation.

Control Variables	F.G Incorporation	T. G Incorporation
F0 & F1 & T0 & T1:		
Correlation	0.715	0.715
p-value	0.00	0.00

Table (6): Correlations between tibial & femoral graft incorporation.

	F.G Incorporation
<i>T. G Incorporation:</i>	
Correlation	0.686
p-value	0.000

Discussion

Tunnel enlargement has not been reported before 1990. There are 2 major reasons for that. First of all, the patellar tendon was the graft of choice for the majority of surgeons, the other major difference for patients who underwent ACL reconstruction in the 1980s was the rehabilitation protocol. Postoperatively, these patients were immobilized for a prolonged period of time (4 to 6 weeks) with a brace or a cast, this treatment allowed enough time for graft incorporation [11].

The philosophy of rehabilitation changed dramatically in the 1990s, and the hamstring graft increased in popularity [12]. Probably, the combination of these 2 changes in ACL surgery resulted in the increased number of papers about tunnel enlargement. The major percentage (75%) of tunnel widening occurred during the first 3-6 months, with no significant increase after this period. These results are in accordance with other series [13].

Bone tunnel enlargement plays an important role in revision surgery. In ACL revision surgery one stage and two stage procedures are performed. Advantages of one stage revision are earlier return to normal activity and lower costs. The most important factor in deciding one or two stage revision is the location and the size of the existing bone tunnels. With a bone tunnel diameter of 10-15mm a two stage procedure is recommended [14].

Peyrache et al., reported that tunnel enlargement did not increase after 3 months, [15] and Fink et al., using computed tomography, showed that more than 50% of tunnel widening occurred in the first 6 weeks. In other words, tunnel enlargement develops before biologic incorporation [16].

Hoher et al., proposed that both biologic and mechanical factors are associated with tunnel widening. Mechanical factors contributing to tunnel enlargement include stress deprivation of bone within the tunnel wall and graft tunnel motion. Biological factors associated with tunnel enlargement include inflammatory and immune response (synovial fluid can enter the graft-bone interface, the increased levels of inflammatory cytokines), cell necrosis due to toxic products in the tunnel, and heat necrosis as a response to drilling [17].

The clinical relevance of tunnel enlargement is not fully understood. In most studies, as well as in our investigation, bone tunnel enlargement has no influence on various clinical outcome scores or knee laxity [18].

Few long-term studies have analyzed the results of biological fixation with patellar tendon graft. It has been proposed that graft fixation more closely to the joint line may reduce bone tunnel widening, and presented bone plug facilitated graft integration inside tunnels. Adversely, a larger extent of bone tunnel diameter was shown, when using bioabsorbable screws compared to an extra cortical fixation at the tibial side, in case of revision it may make the procedure more difficult to perform, as two-stage revision surgery with bone grafting and delayed ligament reconstruction may be necessary. Therefore surgical techniques for ACL reconstruction reducing the phenomenon of bone tunnel widening are required. Press-fit fixation for ACL reconstruction has shown good clinical results with different types of grafts [15].

To avoid disadvantages related to internal fixation devices, especially on femoral side, a hardware-free ACL reconstruction technique was developed. This technique uses the bone plugs on either end of the patellar tendon graft and quadri-

ceps tendon for press-fit fixation. The presented technique was originally developed in 1987 for femoral press-fit fixation and in 1989 for tibial press-fit fixation. Press fit standard was possible with the SDI (Surgical Diamond Instruments) instruments since 1998. Based on this procedure at 2003 the press fit fixation for hamstring was developed.

Jagodzinski et al., reported a decrease of the tibial bone tunnel diameter for a tibial press-fit fixation technique using cylindrical bone graft. However reports about bone tunnel enlargement for quadriceps tendon bone press fit technique using an autologous tibial bone plug are rare [19].

The press fit fixation has been shown to have a similar pullout strength and stiffness compared to fixation with interference screws in animal models. It could be shown that the bone blocks are fully incorporated after a healing period of six weeks. [20].

Mohammad Hasan Kaseb, et al., reported in his study Press-fit Femoral Fixation in ACL Reconstruction using Bone-Patellar Tendon-Bone Graft (The trapezoidal press-fit fixation) that complete graft osteo-integration in femoral tunnel after 6 months postoperative by X-ray. But in this study they had evaluated only femoral tunnels and the evaluation had done by postoperative X-ray and the graft was trapezoidal not cylindrical as our technique by diamond instruments which allow engagement of trabecular bone of bone graft inside tunnels which causes rapid graft incorporation [21].

Akoto et al., [10] his study depends on assessment of tunnel dilation and free bone plug integration in tibial & femoral tunnels 3 months postoperative by CT. In this study all free bone blocks showed bony in growth in the bone tunnel without a sclerotic margin between the bone block and the bone tunnel and homogeneous bone morphology between bone block and bone tunnel. The integration into bone of the free bone block in the tibial tunnel seems to be at least comparable to the good results of bony integration observed for the bone block of a bone patella-tendon bone graft in the tibial tunnel.

In our technique we used the SDI (Surgical Diamond Instruments). The Diamond Bone Cutting System (DBCS) was developed to provide a less traumatic cutting and grinding of bone, Sensitive and accurate grinding of the bone dowels. Diamond core reaming is based on the principle of non-traumatic wet grinding of bones, with which can be obtained an artifact-free vital transplant cylinder

and an intact implant support. Due to this method the in growth of the bone cylinder is faster and rehabilitation is shortened, but in trapezoidal plug the contact surface area between bone plug and tunnels less than that in cylindrical free bone plug and trabecular interfere between bone plug and tunnel bone which done by using diamond surgical instrument not exist so the in growth is slow with rigid graft fixation.

In our study all free bone plugs showed bony in growth in the bone tunnel without a sclerotic margin between the bone block and the bone tunnel and homogeneous bone morphology between bone block and bone tunnel, the tibial plug main healing after 3 months was 37.2%, Healing was evaluated as excellent in 7 patients (23.3%), good in 13 patients (43.3%) and fair in 10 patients (33.3%). In femoral plug main healing was 64.4%, healing was evaluated as excellent in 23 patients (76.6%), good in 6 patients (20%) and fair in one patients (3.33%). The bone integration of the press fit technique in the tibial & femoral tunnel seems to be much better than results of bony integration observed for the trapezoidal bone block of a bone patella-tendon bone graft or free bone graft in the tibial & femoral tunnels according to rapid and solid integration and that explain the role of diamond bone cutter in our technique [22].

In our results the femoral plugs healing more than tibial plug and cause may be due to:

Contact Surface area between femoral plug and tunnel more than it in tibial plug.

In our results age & time interval has no influence on femoral and tibial graft integration but there is a relation between graft integration and post operative clinical scores, with increasing graft integration the clinical scores improved.

The results also indicate that with increase femoral graft integration the tibial graft integration also increase.

Bone tunnel widening was reported to increase to almost 50% of its maximum after six weeks and reaches a steady state after three to six month [20]. Therefore in our study it was chosen to perform a CT investigation three month postoperatively.

Up to our knowledge this is the only study including the assessment of tunnel size through tibia and femur with assessment of osteo-integration through both tunnels.

In this study we have found ACL reconstruction by press fit technique didn't causes post operative

dilation but also cause tunnel narrowing mainly at femoral tunnel through the notch and midpoint about 5.5% and 7.4% respectively 3 months after operation compared with operative reamer size and, at the tibial tunnel the study shows dilation occurs at tibial plateau portion about 11 % from the operative reamer size and narrowing about 5% at mid tunnel point. The bone tunnel diameter on the articular cortex level in the tibia did not change significantly. The reason for this could be, that the free bone plug was introduced 10mm distal to the tibial articular cortex.

In our study all age groups show satisfactory clinical scores and no difference between groups, either postoperative femoral and tibial tunnel measurement not influenced by age and time interval, this is one of advantages of our technique. The clinical relevance of tunnel enlargement is not fully understood. In most studies, as well as in our investigation, bone tunnel enlargement has no influence on various clinical outcome scores or knee laxity.

Our results are in line with Kim et al., who showed significantly less bone tunnel widening for press-fit fixation with autologous bone block with an achilles tendon allograft [23]. In contrast to Kim et al., in our population the diameter of the tibial & femoral bone tunnel was reduced three month postoperatively. This may be explained by the fact that Kim et al., used a MRI scan device for measuring the bone tunnel diameter.

Conclusion:

Free bone plug press fit fixation could be considered as an alternative method among the other standard methods for hamstring tendon graft fixation, especially for patients with a high risk of re injury. It enhances graft tunnel integration within the first 6 months post-operatively and stabilizes the graft within the tunnel safely with Reduction of the diameter of the bone tunnel after three months. Our findings confirm that press-fit fixation may result in less bone loss in the bone tunnel It yields comparable clinical outcomes yet avoiding potential hazards of foreign hardware implants. Further studies investigating free bone plug press-fit fixation with other soft tissue grafts are needed.

References

- 1- HEIJINK A., GOMOLL A.H., MADRY H., DROBNIC M., FILARDO G., ESPREGUEIRA-MENDES J. and VAN DIJK C.N.: Biomechanical considerations in the pathogenesis of osteoarthritis of the knee. *Knee Surg Sports Traumatol. Arthrosc.*, 20: 423-35, 2012.
- 2- CHEN J., XU J., WANG A. and ZHENG M.: Scaffolds for tendon and ligament repair: Review of the efficacy of commercial products. *Expert Rev. Med. Devices*, 6: 61-73, 2009.
- 3- DROGSET J.O., STRAUME L.G., BJØRKMO I. and MYHR G.: A prospective randomized study of ACL-reconstructions using bone-patellar tendon-bone grafts fixed with bioabsorbable or metal interference screws. *Knee Surg. Sports Traumatol. Arthrosc.*, 19: 753-9, 2011.
- 4- REPLOGLE W.H., BARRETT G.R. and JOHNSON W.D.: Outcome evaluation of ACL reconstruction using patellar tendon allograft. *Arthroscopy*, 26: 1018-9, 2010.
- 5- HERTEL P., BEHREND H., CIERPINSKI T., MUSAHL V. and WIDJAJA G.: ACL reconstruction using bone-patellar tendon-bone press-fit fixation: 10-year clinical results. *Knee Surg. Sports Traumatol. Arthrosc.*, 13: 248-55, 2005.
- 6- PAVLIK A., HIDAS P., CZIGÁNY T. and BERKES I.: Biomechanical evaluation of press-fit femoral fixation technique in ACL reconstruction. *Knee Surg Sports Traumatol. Arthrosc.*, 12: 528-33, 2004.
- 7- KIM S.G., KUROSAWA H., SAKURABA K., et al.: The effect of initial graft tension on postoperative clinical outcome in anterior cruciate ligament reconstruction with semitendinosus tendon. *Arch. Orthop. Trauma Surg.*, 126: 260-264, 2006.
- 8- LUI P.P.Y., HO G., LEE Y.W., HO P.Y., LO W.N. and LO C.K.: Inferior tendon graft to bone tunnel healing at tibia compared to femur after anterior cruciate ligament reconstruction. *J. Orthop. Sci.*, 15 (3): 389-401, 2010.
- 9- MATSUMOTO A., HOWELL S.M. and LIU-BARBA D.: Time-related changes in the cross-sectional area of the tibial tunnel after compaction of an autograft bone dowel alongside a hamstring graft. *Arthroscopy*, 22 (8): 855-60. doi:10.1016/j.arthro.2006.04.092, 2006.
- 10- AKOTO, et al.: *BMC Musculoskeletal Disorders*, 16: 200 DOI 10.1186/s12891-015-0656-5, 2015.
- 11- SHELBOURNE D.K., KLOOTWYK T.E. and DECARLO M.S.: Clinical development of preoperative and postoperative ACL rehabilitation. In: Feagin J.A., ed. *The crucial ligaments*. New York: Churchill Livingstone, 737-757, 1994.
- 12- HARNER C.D., FU F., IRRGANG J.J. and VOGRIN T.M.: Anterior and posterior cruciate ligament reconstruction in the new millennium: A global perspective. *Knee Surg. Sports Traumatol. Arthrosc.*, 9: 330-336, 2001.
- 13- WEBSTER K.E., FELLER J.A. and HAMEISTER K.A.: Bone tunnel enlargement after anterior cruciate ligament reconstruction: A randomized comparison of hamstring and patellar tendon grafts with 2-year follow-up. *Knee Surg. Sports Traumatol. Arthrosc.*, 9: 86-91, 2001.
- 14- BATTAGLIA T.C. and MILLER M.D.: Management of bony deficiency in revision anterior cruciate ligament reconstruction using allograft bone dowels: Surgical technique. *Arthroscopy J. Arthroscopic Relat. Sur.*, 21 (6): 6. doi:10.1016/J.Arthro.2005.03.029, 2005.
- 15- PEYRACHE M.D., DJIAN P., CHRISTEL P. and WITVOET J.: Tibial tunnel enlargement after anterior cruciate ligament reconstruction by autogenous bone-

- patellar tendon-bone graft. *Knee Surg. Sports Traumatol. Arthrosc.*, 4: 2-8, 1996.
- 16- FINK C., ZAPP M., BENEDETTO K.P., et al.: Tibial tunnel enlargement following anterior cruciate ligament reconstruction with patellar tendon autograft. *Arthroscopy*, 17: 138-143, 2001.
- 17- HOHER J., MOLLER H.D. and FU F.H.: Bone tunnel enlargement after anterior cruciate ligament reconstruction: Fact or fiction? *Knee Surg. Sports Traumatol. Arthrosc.*, 6 (4): 231-240, 1998.
- 18- MARCHANT Jr. M.H., WILLIMON S.C., VINSON E., PIETROBON R., GARRETT W.E. and HIGGINS L.D.: Comparison of plain radiography, computed tomography, and magnetic resonance imaging in the evaluation of bone tunnel widening after anterior cruciate ligament reconstruction. *Knee Surg. Sports Traumatol. Arthrosc.*, 18 (8): 1059-64. doi: 10.1007/s00167-009-0952-4, 2010.
- 19- JAGODZINSKI M., GEIGES B., VON FALCK C., KNOBLOCH K., HAASPER C., BRAND J., et al.: Biodegradable screw versus a press-fit bone plug fixation for hamstring anterior cruciate ligament reconstruction: A prospective randomized study. *Am. J. Sports Med.*, 38 (3): 501-8. doi:0363546509350325 [pii] doi:10.1177/0363546509350325, 2010.
- 20- SCHMIDT-WIETHOFF R., DARGEL J., GERSTNER M., SCHNEIDER T. and KOEBKE J.: Bone plug length and loading angle determine the primary stability of patellar tendon-bone grafts in press-fit ACL reconstruction. *Knee Surgery, Sports Traumatology, Arthroscopy* DOI 10.1007/s00167-005-0645-6 108-111 Springer Link, 2005.
- 21- MOHAMMAD HASAN KASEB1, AMIR REZA SADEGHIFAR1 and SEYED MOHAMMAD JAVAD: 13 May 2007; Received in revised form: 3 Jun. 2007; Accepted: 13 Jun. 2007.
- 22- JARVELA T., MOISALA A.S., PAAKKALA T. and PAAKKALA A.: Tunnel Enlargement After Double-Bundle Anterior Cruciate Ligament Reconstruction: A Prospective, Randomized Study. *Arthroscopy J. Arthroscopic Relat. Sur.*, 24 (12): 1349-57. doi:10.1016/j.arthro.2008.07.018, 2008.
- 23- KIM S.G., KUROSAWA H., SAKURABA K., et al.: The effect of initial graft tension on postoperative clinical outcome in anterior cruciate ligament reconstruction with semitendinosus tendon. *Arch. Orthop. Trauma Surg.*, 126: 260-264, 2006.

تقييم سلوك النفق العظمي في عملية إعادة بناء الرباط الصليبي الأمامي باستخدام طريقة الحشر بالأسطوانات العظمية

معدل الإصابات بحالات القطع في الرباط الصليبي الأمامي للركبة في تزايد مستمر، وبالتالي تعتبر جراحات إعادة بناء الرباط الصليبي الأمامي واحدة من الإجراءات الأكثر شيوعاً في جراحة العظام في جميع أنحاء العالم.

وقد وصفت تقنيات مختلفة على مدى سنوات لإعادة بناء الرباط الصليبي الأمامي، وكانت من أكبر التحديات التي واجهت الجراحين ومن ثم المرضى التغيرات التي قد تطرأ على النفق العظمي في عظمة الفخذ أو القصبية من حيث تغير حجم هذه الأنفاق واتساعها وقد تم وضع العديد من النظريات لأسباب هذه الظاهرة وما تسببه في حدوث تأخر ألتئام أنسجة الرباط الصليبي مع العظام المحيطة به وبالتالي انعكاسها على نتائج الجراحة بالإضافة إلى صعوبة إجراء إعادة بناء للرباط الصليبي مرة أخرى لنفس الركبة في حالة فشل العملية الجراحية الأولية. ومن بين العديد من التقنيات الموصوفة لإعادة بناء الرباط الصليبي طريقة الحشر باستخدام الأسطوانات العظمية وفيها يتم تجنب استخدام أي أجسام غريبة ويتم التثبيت بأسطوانات عظمية من نفس المريض وفي هذه الدراسة حاولنا أن نثبت أن استخدام هذه الطريقة لا تسبب حدوث اتساع للأنفاق العظمية بعد إجراء الجراحة بالإضافة إلى سرعة ألتئام أنسجة الرباط الصليبي مع عظام النفق العظمي من حوله مما يعطى نتائج ممتازة بعد الجراحة وبتيح للمريض سرعة العودة إلى الأنشطة الخاصة به، وفي حالة الاحتياج إلى إعادة العملية في نفس الركبة لأي سبب يتم تجنب المشاكل الخاصة بوجود إنفاق سابقة من الممكن أن تكون قد يتغير أو اتساع قطرها وحجمها، وتبين من النتائج أن طريقة الحشر باستخدام الأسطوانات العظمية تؤكد هذه الفرضية.