

CD 105/Endoglin is a Challenging Marker of Angiogenesis in Renal Cell Carcinoma with Specific Pattern of Sarcomatoid Component

FATMA EL-ZAHRAA SALAH EL-DEEN YASSIN, M.D.¹; MAISA HASHEM MOHAMMED, M.D.²;
ATEF GALAL ABDEL-WAHAB, M.D.³ and EMAN MUHAMMAD SALAH EL-DEEN, M.D.⁴

The Department of Pathology^{1,2,4} and Urology Department³, Faculty of Medicine, Sohag University

Abstract

Background: Renal cell carcinoma (RCC) is a heterogeneous tumor entity with variable prognostic parameters; microvessel density (MVD) is still a point of controversial as a predictor of prognosis in RCC. We aimed to evaluate CD105-MVD as an applicable prognostic indicator for renal cell carcinoma.

Aim of Study: To evaluate the prognostic value of CD105/Endoglin in RCC through its correlation with other clinical and pathological parameters.

Material and Methods: Histopathological diagnosis was based on Hematoxylin-Eosin stained sections and included the followings: Histological subtypes, tumor grade, pathological stage (pT), sarcomatoid components, tumor necrosis, capsular and perinephric fat invasion.

Results: We found a significant correlation between the histopathological subtypes and the Fuhrman's nuclear grading system ($p=0.016$). CD105-MVD was significantly inversely correlated with Fuhrman's Nuclear grade ($p=0.009$) and Leibovich Score ($p=0.012$); patients with high expression of CD105 showed low Fuhrman nuclear grade and low risk of metastasis. However, insignificant correlation was detected regarding other separate parameters such as size, necrosis and pathological stage. Sarcomatoid clear cell renal cell carcinoma (CCRCC) recorded the largest diameter, the highest frequency of positive capsular and perinephric fat invasions and the lowest score of CD-105 MVD.

Conclusion: We concluded that high CD105-MVD may be a marker of less aggressiveness of RCC, it was associated with more favorable pathological parameters; clear cell type, lower Fuhrman grade and low LS. Sarcomatoid CCRCC draws unique immunohistochemical expression of CD-105 MVD.

Key Words: CD105 – Renal cell carcinoma – Sarcomatoid.

Introduction

RCC is a heterogeneous tumor entity, comprises several subtypes with emerging new entities. Each subtype has unique histological, immunohistochemical, genetic behavior, prognosis and response to

treatment. Thus the behavior of RCCs is still unpredictable.

Over the last decades, several researchers [1] investigated the different clinical and histopathological parameters to draw an algorithm for prediction the outcome of renal cell carcinoma. No Single clinical or even histopathological parameter was adequate for this prediction.

Leibovich and his colleagues, 2003 [1] investigated several histopathological factors (tumor size, nuclear grade, tumor stage with regional lymph node status and histological tumor necrosis) to develop an algorithm for prediction the RCC course after radical nephrectomy.

Later on, several authors [2,3] used meticulous panels of immunohisto-chemical markers for prediction the metastasis of renal cell carcinoma, some of them [2] used stem cell markers and others [3] used angiogenic markers.

Therefore, identifying a better prognostic factor is needed for more accurate RCC prognosis. One of the promising angiogenic factors is CD105/Endoglin.

Endoglin (CD105-cluster of differentiation 105) is an accessory receptor of transforming growth

Abbreviations:

AJCC : American Joint Committee on Cancer.
CCRCC : Clear cell renal cell carcinoma.
CD105 : Cluster of differentiation 105.
DAB : Diaminobenzidine.
H&E : Hematoxylin and Eosin.
ISUP : International Society of Urological Pathology.
MVD : Microvessel density.
Non CCRCC: Non clear cell renal cell carcinoma.
pT : Pathological stage.
RCC : Renal cell carcinoma.
TGF-B : Transforming growth factor B.
WHO : World Health Organization.

Correspondence to: Dr. Fatma El-Zahraa Salah El-Deen Yassin,
[E-Mail: Fatmaf2002@yahoo.com](mailto:Fatmaf2002@yahoo.com)

factor B (TGF- β). It is overexpressed on proliferating (activated) endothelial cells of solid tumors; breast and RCC as well as it was considered as a stem cell tumor marker. Therefore, several studies investigated it as a target for antiangiogenic therapy [3].

Material and Methods

Tissue samples:

Tissue samples were obtained from 48 patients who underwent nephrectomy at XXX-University Hospital from May 2018 to January 2020, and did not receive any adjuvant chemotherapy or radiotherapy.

Age, sex and side of nephrectomy were reported for each specimen. Gross assessments for tumor size, capsular and peri-renal fat invasion were done.

Histopathological diagnosis was based on Hematoxylin-Eosin stained sections and included the followings: Histological subtypes, tumor grade, pathological stage (pT), sarcomatoid components, tumor necrosis, capsular and perinephric fat invasion.

The histopathological classification was conducted according to WHO specification 2016 [4] into: Clear cell renal cell carcinoma (CCRCC), CCRCC with sarcomatoid element, papillary and chromophobe subtypes. Pathological stage was done according to the 6th AJCC TNM [5] staging system; tumor size and the perinephric fat invasion were used to determine pT-stage of the resected tumor.

The tumor grade was assessed according to Fuhrman's nuclear grading system [1]. Tumor necrosis (Coagulative microscopic necrosis) could be identified at H&E stained sections as homogeneous clusters and sheets of dead tumor cells with nuclear and cytoplasmic debris, whether the underlying architecture is retained or not [6].

Leibovich Score is a histological score that integrates five parameters to predict the progression of RCC. Using these parameters, tumors are given a score ranging from zero to 11 and categorized into low (0-2), intermediate (3-5) and high risk (≥ 6) groups (Table 2) [1].

We assessed tumor size, nuclear grade, histological tumor necrosis and the pathological stage to categorize our patients, all cases of RCC were included whatever its subtype. Regional lymph node status was not available and could not be assessed.

Immunohistochemical staining of Anti-CD105:

Formalin-fixed paraffin-embedded renal tumor tissue blocks were sectioned into 4 μ m thickness. Deparaffinization and hydration were done. Sections were incubated in 3% H₂O₂ for 30 minutes at room temperature. Then heated in 0.01mmol/L citrate buffer fluid at 92°C for seven minutes. Sections were incubated with primary antibody overnight at 25°C. The primary antibody was a mouse monoclonal antibody raised against CD105 in human species (clone ERP19911, catalogue RM0281-S, in a concentrated form 0.1ml, dilution 1:100). The sections then were incubated with goat serum secondary antibody followed by streptavidine biotin for ten minutes each separated by washing in PBS for five minutes after each step. The reaction products were visualized by immersing the sections in diaminobenzidine (DAB) for fifteen minutes at room temperature. Sections were counterstained by immersion in hematoxylin stain for few seconds and rapid wash in tap water to remove extra dye.

Dehydration, clearance and cover mounting were done.

Sections from normal human placental tissue were used as positive control for CD105. Also negative controls were lacking reactivity to confirm the validity of the staining results.

Evaluation of CD105 immunostaining:

Expression of CD105 in vessels was recorded as negative (absence of staining) or positive (presence of brown staining). Any CD105-positive endothelial cell or endothelial cell cluster clearly separated from the adjacent microvessel was considered as a single, countable microvessel.

We used the median of the microvessel density (MVD) as cut off point to divide the cases into low and high MVD score groups [7]. MVD was recorded as low (1; 190 vessels per mm²), and high (2; >191 vessels per mm²).

The applied protocol for counting intra-tumoral microvessels [8]:

- 1- All histological slides from the tumor were examined and the most generous cross section of the representative tumor was selected. It was immunostained by CD 105/Endoglin to highlight the micro vessel density.
- 2- The CD105 immunostained sections were scanned at low magnification (~x40 to 100) to select the 3 hot spots (with the greatest numbers highlighted micro vessels).
- 3- Count all vessels within a 0.74 mm² area (x200) of this neovascularization "hotspot" and the

mean value of the vessels count was used as final MVD value.

- 4- The median was used as the cutoff point to divide the patients into high and low scores of MVD.

Any brown staining of endothelial cell or endothelial cell cluster, clearly separate from adjacent micro vessels, tumor cells and other connective tissue elements was considered as single countable micro vessels regardless its site within the tumor (centrally or at the margins). Identification of the lumen or presences of RBCs were not essential to identify the micro vessels [8].

Statistical analysis:

Data was analyzed using SPSS version 26 (Statistical Software package version 26). Descriptive analysis was performed. Quantitative data was represented as mean, standard deviation. When the data was not normally distributed Mann-Whitney test was used to compare between two groups. Qualitative Data are reported as frequencies and percentages and compared using either Chi-Square test or Fisher's Exact test.

Spearman's rank correlation coefficient was used. Graphs were produced by using Excel or SPSS version 26. *p*-value was considered significant if it was less than 0.05.

Results

The current study included 48 patients with renal cell carcinomas. All histopathological features were summarized in (Table 1). Their ages ranged from 28 to 75 years (mean \pm SD was 57.27 ± 7.5 and median was 58). The study included 31 male patients and 17 females.

According to histopathological diagnosis, we categorized our patients into two major groups; CCRCCs (33) versus non-clear cell renal cell carcinoma (Non-CCRCCs) (15). CCRCC included two subtypes; conventional (23) and CCRCCs with sarcomatoid component (10). Non-CCRCCs included two different variants; chromophobe (11) and papillary (4) subtypes (Table 1) (Fig. 1).

Their size ranged from 4 to 15cm (mean \pm SD was 7.19 ± 2.1), the highest mean value (8.8cm) was recorded in sarcomatoid CCRCC. While the lowest mean value (6.5m) was found in conventional type CCRCC with insignificant statistical correlation (Table 1).

A histologically confirmed coagulative necrosis was detected in 37.5% (18/48) of patients; nine cases were CCRCC with sarcomatoid element (Fig.

2C), 4 cases were clear cell type (Fig. 3C,D), 3 with chromophobe and 2 cases with papillary subtypes. No statistical significant association was detected between the necrosis and the histopathological types (Table 1).

We detected 73% (35/48) of patients with capsular invasion, 77% (27/35) of capsular invasion were detected in CCRCCs versus 23% (8/35) Non-CCRCCs. 90% (9/10) of sarcomatoid CCRCCs and 75% of papillary type (Non-CCRCC) revealed positive capsular invasion (the frequency of positivity was the highest in sarcomatoid CCRCCs).

The perinephric fat invasion was seen in 60% (29/48) of patients, 69% of positive cases were CCRCCs versus 31% of Non-CCRCCs (the frequency of positivity was the highest in sarcomatoid [90% (9/10)] CCRCCs) (Fig. 2D). Neither capsular nor perinephric invasion showed significant associations with the histopathological subtypes (Table 1).

CCRCCs had bimodal records in Fuhrman's nuclear grades; 91% (21/23) of the conventional type were grade I&II (Fig. 1A), while all cases of CCRCC with sarcomatoid components by their name were considered as grade IV (Figs. 1D,2B).

Both papillary and chromophobe subtypes showed a spectrum of nuclear grades (I-III) (Table 1 & Figs. 1B,C).

There is a significant correlation between the histopathological subtypes and the Fuhrman's nuclear grading system with $p=0.016$ (Table 1).

Although we used the WHO/ISUP grading system for CCRCCs and papillary RCCs only, it did not achieve any statistically significant results (not shown in the tables).

None of the resected nephrectomy specimens contained adrenal tissues, lymph nodes (Nx) or definite vascular structures. So, the tumor size and the peri-nephric fat invasion were used to broadly determine pT-stage of the tumor. 58% (28/48) of cases were staged as pT3, 27% (13/48) were pT1 and about 15% (7/48) were pT2 (Table 1).

CCRCCs recorded the highest percent of stage III compared to Non-CCRCC (19 versus 9). It did not achieve any statistically significant results (Table 1).

We categorized all cases into 3 risk groups according to the modified Leibovich's score (LS); low, intermediate and high risk patients according to their tumor size, nuclear grade, necrosis and pathologic stage Tables (1,2) (Scoring algorithm of Leibovich and his colleagues, 2003) [1].

The CCRCCs with sarcomatoid element reported 77% of high Leibovich score (LS), while 64% of intermediate Leibovich score was CCRCCs

conventional type. No significant statistical association was detected between LS and histopathological subtypes (Table 1).

Table (1): Correlation between RCC subtypes, histopathological parameters, CD105 expression and MVD.

Parameters	Cases No (48)	Histological subtypes				P-value
		CCRCC (N=33)		Non-CCRCC (N=15)		
		Conventional (N=23)	With sarcomatoid component (N=10)	Chromophobe* (N=11)	Papillary (N=4)	
Tumor size (Mean value)	48	6.5	8.8	6.6	8.1	(NS)
Tumor necrosis	18	4	9	3	2	(NS)
<i>Fuhrman grade:</i>						
I	15	12	0	2	1	0.016*
II	18	9	0	8	1	
III	5	2	0	1	2	
IV	10	0	10	0	0	
<i>pT stage:</i>						
Ia	1	1	0	0	0	0.57 (NS)
Ib	12	6	1	4	1	
II	7	5	1	1	0	
III	28	11	8	6	3	
<i>Leibovich score:</i>						
Low	10	6	0	3	1	0.34 (NS)
Intermediate	25	16	0	8	1	
High	13	1	10	0	2	
Capsular invasion	35	18	9	5	3	(NS)
Perinephric fat invasion	29	11	9	6	3	(NS)
<i>CD105:</i>						
Negative	3	0	3	0	0	0.15 (NS)
Low	27	11	5	7	4	
High	18	12	2	4	0	
Mean of MVD**	48	282.5±165.9	135.7±106.7	183.1±73.2	153±71	0.27 (NS)
Median			190 with range (0-600)			

Chi-Square, Fisher's Exact tests were used for categorical data. Mann-Whitney U test was used for non parametric continuous data.

*=Significant. NS=Non significant. ** Negative cases were included.

Table (2): Leibovich Scoring Algorithm for patients with RCC*.

Parameter	Score
<i>Tumour size (cm):</i>	
<10	0
≥10	1
<i>Nuclear grade (Fuhrman's grade):</i>	
1	0
2	0
3	1
4	3
<i>Tumour necrosis:</i>	
No	0
Yes	1
<i>Pathological T stage:</i>	
pT1a	0
pT1b	2
pT2	3
pT3a	4
N stage	0**

Score (0-2) = Low risk. Score (3-5) = Intermediate risk.

Score (≥6) = High risk groups.

* The score was applied for all histopathological subtypes of RCC.

**All cases were pNx (=0) in the current study.

Immunoreactivity of CD105-MVD:

CD105/Endoglin expression was evaluated using MVD measurements (Fig. 3). CD 105-MVD expression was classified into low and high as we justify the cutoff point of MVD according to the median (=190, with range 0-600). Three cases (6%) of RCC give negative expression versus 45 (94%) showed positive staining, 60% (27/45) of positive cases recorded low score while 40% (18/45) of cases showed high score of expression (Table 1).

CD105 expression in different histopathological RCC subtypes:

No a statistical correlation was found between CD105 expression and the histological subtypes (CCRCCs versus Non-CCRCCs). However, 80% of the sarcomatoid CCRCCs showed either negative or low score CD105 expression (Table 1) (Figs. 2E,F).

Table (3): Correlation between CD105 expression and different histopathological parameters.

Parameters	Cases No (48)	CD105 expression						p**-value
		Negative N=3		Low N=27		High N=18		
		CCRCC	Non CCRCC	CCRCC	Non CCRCC	CCRCC	Non CCRCC	
Fuhrman Grades:	48							
Grade I (n=15)		0	0	3	2	9	1	0.009
Grade II (n=18)		0	0	6	7	3	2	
Grade III (n=5)		0	0	2	2	0	1	
Grade IV (n=10)		3	0	5	0	2	0	
Modified Leibovich score (Risk score):	48							
Low (n=10)		0	0	4	3	2	1	0.012
Intermediate (n=25)		0	0	6	6	10	3	
High (n=13)		3	0	6	2	2	0	
pT stage:	48							
Ia (n=1)		0	0	1	0	0	0	0.55 (NS)
Ib (n=12)		0	0	5	3	2	2	
IIa (n=7)		1	0	1	0	4	1	0.55 (NS)
IIIa (n=28)		2	0	9	8	8	1	
Size:	48							
Mean ± SD		6.8±1.6		7.26±2.3		7.21±1.99		0.91 (NS)
Associated necrosis:	48							
Negative		1		15		14		0.61 (NS)
Positive		2		12		4		0.61 (NS)

**Using Spearman's rank correlation coefficient(r).

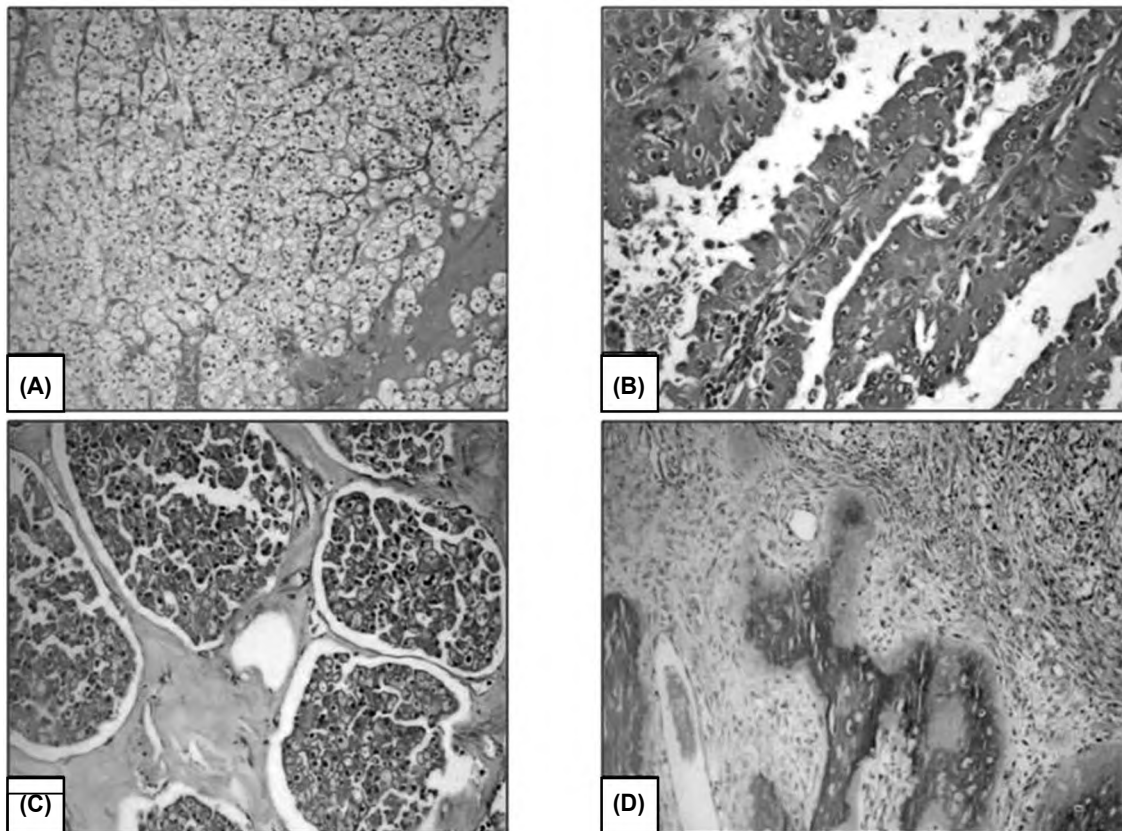


Fig. (1): Renal cell carcinoma with different Fuhrman's nuclear grades. (A) Conventional type (CCRCC) grade I. (B) Papillary subtype (Non-CCRCC) grade II. (C) Chromophobe subtype (Non-CCRCC) with amyloid stroma grade II. (D) Sarcomatoid CCRCC with osseous metaplasia grade IV. Original (HE; x100, 200,100,200).

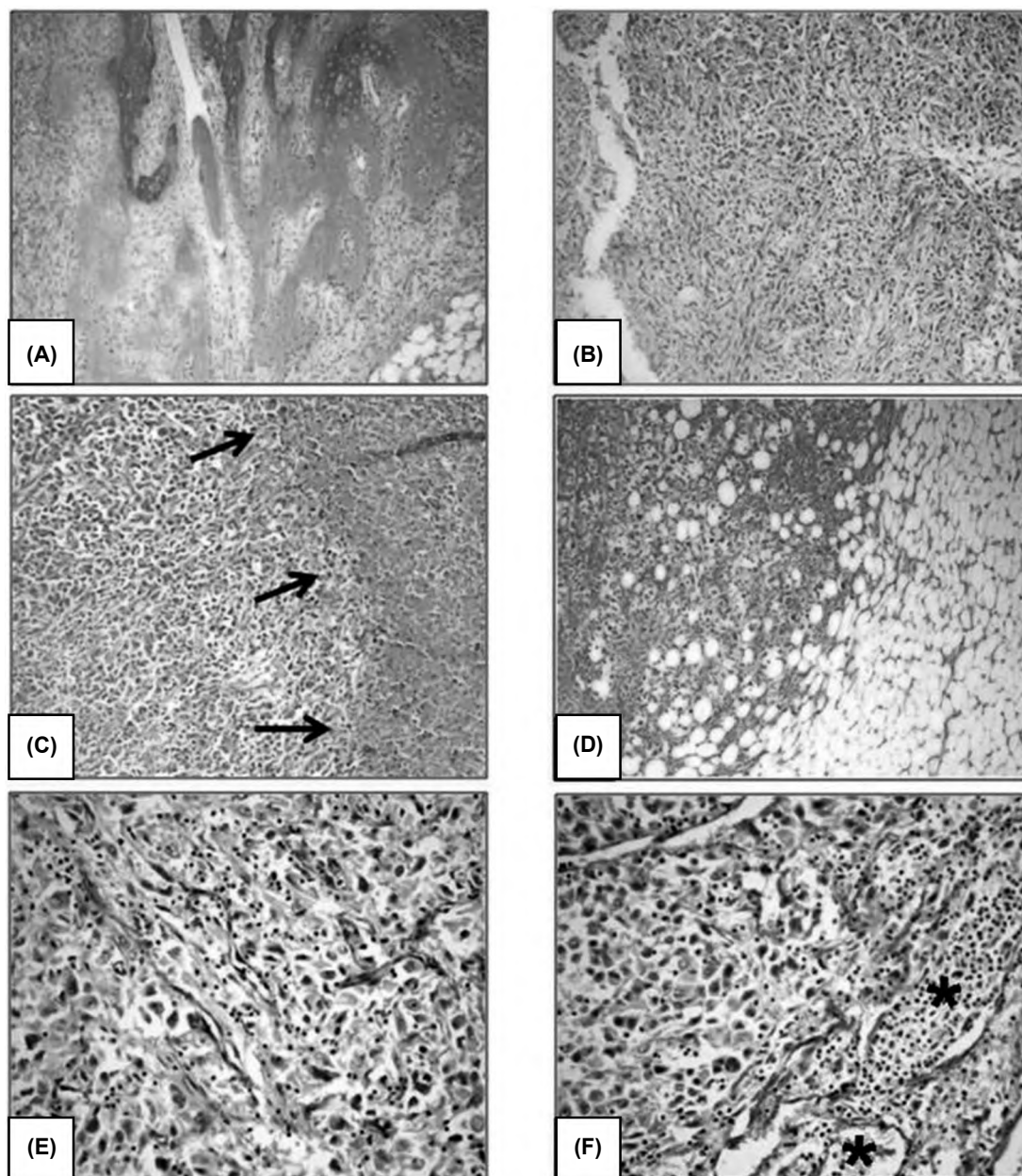


Fig. (2): Sarcomatoid CCRCC showed (A) osseous metaplasia. (B) Fuhrman grade IV. (C) Coagulative necrosis at the right side (black arrows), and (D) Perinephric fat invasion (original HE; x100,100,200,100). (E&F) CD105 expressed low score MVD with obvious large nutrient vessels (astrix). (Original x400,400).

We reported the maximum mean values of MVD in both conventional CCRCCs (282.5 ± 165.9) and chromophobe type (Non-CCRCCs) (183.1 ± 73.2). The minimum value of mean was detected in sarcomatoid CCRCCs (135.7 ± 106.7). The mean of MVD in papillary subtype (Non-CCRCCs) was (153 ± 71). No statistical significant correlation was found between different means of MVD and the histopathological subtypes) (Table 1) (Fig. 4).

CD105 expression in different Fuhrman's nuclear grades; there is a significant moderate negative correlation between Fuhrman's nuclear grades and CD105 expression in RCC (p -value=0.009): 80%

of RCCs with Fuhrman's Grade IV showed either negative or low score of CD105 expression. However, the highest expression was detected in lower Fuhrman's grades (I and II) (Table 3, Fig. 4).

CD105 expression in different pT stages; No significant correlation was found between CD105 expression and the pathological stage (pT) of different RCC subtypes (Table 3).

CD105 expression and necrosis & tumor size; 87% (14/18) of RCCs with necrosis showed negative or low expression of CD105. CD105 expression and MVD values were not related to the tumor size or necrosis as shown in (Table 3).

CD105 expression with different scores of Leibovich:

There's a significant moderate negative correlation was found between CD105 and Leibovich scores (LS) (p -value=0.012): 85% (11/13) of pa-

tients with high risk LS were associated with negative or low CD105 expression. We detect 52% (13/25) of intermediate LS score with CD105 high expression. The highest expression of CD105 was associated with low risk group of LS (Table 3).

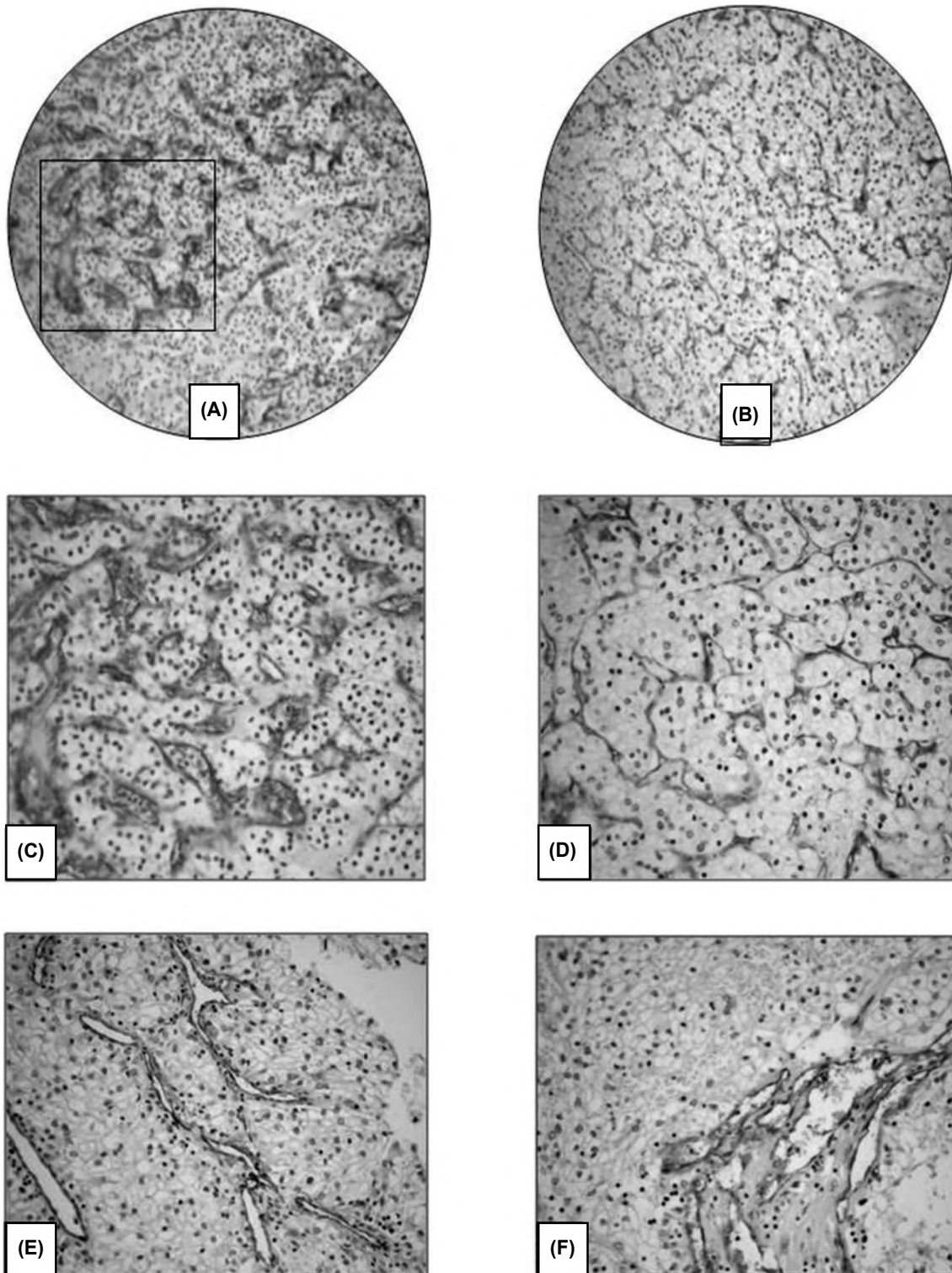


Fig. (3): Scoring of CD105-MVD: (A-D) High score MVD versus (E-F) Low score. CC. (Original x100,100,200,200,200,200) of two different cases of clear cell R.

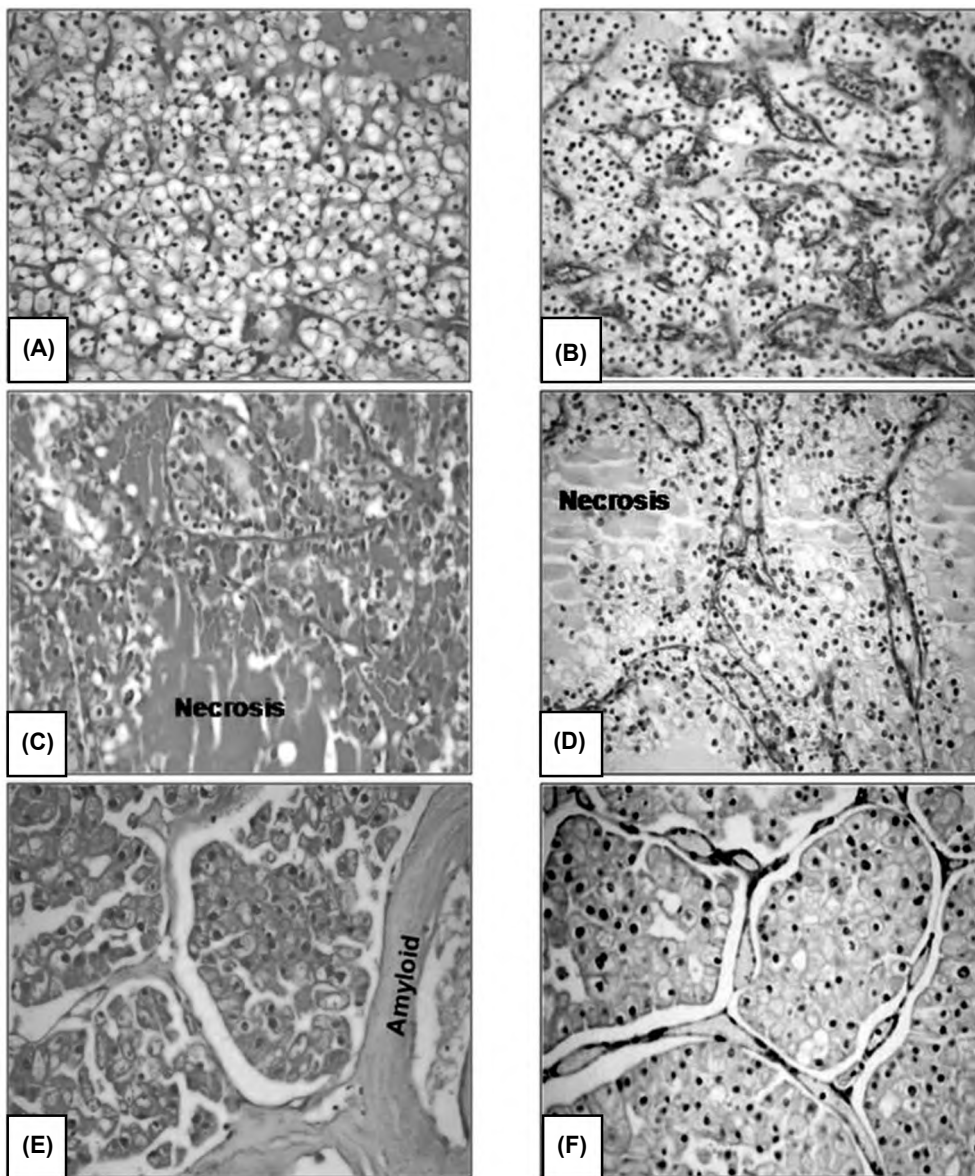


Fig. (4): Variable scores of CD105-MVD in different types of RCC. (A,B) Conventional type RCC, Fuhrman's grade I showed high score MVD. (C,D) RCC with coagulative necrosis, Fuhrman's grade II revealed low score MVD. (E,F) Chromophobe RCC, Fuhrman's grade II showed low score MVD. (HE & CD105 all x200, Original).

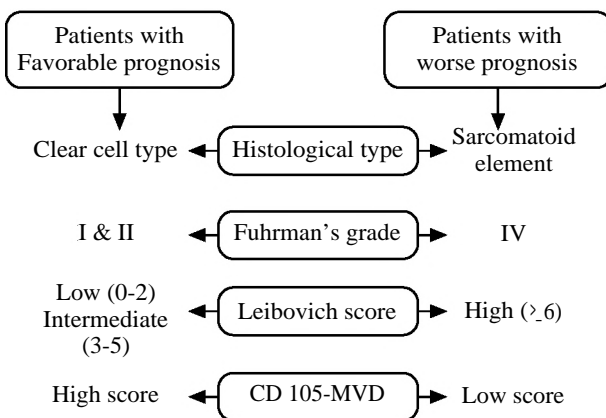


Fig. (5): Suggested predictive parameters for RCC.

Discussion

The current study enabled us to draw an abroad algorithm (Fig. 5) for prediction RCC outcome, it depends mainly on integrated histopathological features and MVD assessment used CD105/ Endoglin.

To assess the histopathological features, we categorized our patients into two major groups (CCRCCs versus Non-CCRCCs) to highlight the difference between them regarding all clinical and histopathological parameters. We found the chromophobe RCC is the second most frequent subtype after clear cell subtype while others re-

corded the papillary subtype as the second most common variant of RCC [9].

Many authors [10,11] reported that the behavior of renal cell carcinoma differs significantly according to their histopathological types. We did not detect any significant correlation between the histopathological subtype of RCCs and the investigated parameters (either clinical or histopathological). Except in, Fuhrman Nuclear grading system revealed a significant difference in relation to the histopathological subtypes with special pattern in sarcomatoid variant of CCRCCs.

Although we used the WHO/ISUP grading system for CCRCCs and papillary RCCs only, it did not achieve any statistically significant results; its prognostic utility has not been validated for other tumor types [12].

In review 2019 [12] reported that Rochester Grading Panel applied certain criteria to validate any grading system of RCC as a prognostic tool; it should be applied by experienced nephropathologist and based upon the worst/highest nuclear grade. Subsequently, they recommended that the ideal grading system would be valid for both CCRCCs & papillary subtypes as well as for chromophobe subtype.

In the current study, we applied Fuhrman's grading system for all subtypes of RCC (clear, papillary and chromophobe) as some researchers [12] stated that Fuhrman's nuclear grading system could be used for chromophobe subtypes. The recent series of WHO stated that the chromophobe subtype cannot be graded due to its innate nuclear atypia and absence of valid alternative grading system [13].

Another histopathological parameter could be assessed in the study; we identified the coagulative tumor necrosis, either as homogenous clusters of degenerated and dead tumor cells with ghost outlines or as a homogenous pink coagulum with complete loss of underlying architectures, both views were admixed with a variable density of nuclear and cytoplasmic debris.

Sengupta and his colleagues, 2005 [6] reported that the associated adjacent areas to the necrosis was typically high grade (grade 3 or 4), which is came in agreement with ours, as we found 50% of coagulative necrosis were seen in RCC with sarcomatoid element (Grade 4).

The underlying mechanisms of tumor necrosis in RCC were investigated by several authors, some authors reported its occurrence due to rapidly

proliferating aggressive tumor over its own blood supply; similar to our results. While others [14,15] considered the host anti tumoral immune reaction and the cytotoxic effect of T cells were the main insults in the pathogenesis of coagulative necrosis in RCCs.

Although, several authors [6,16] reported the coagulative tumor necrosis as a negative prognostic marker for RCC, it must be applied in combinations with other variables. In the current study, we did not find any statistical significant association between the histopathological subtypes and separate parameters like size, necrosis or stage. So we applied LS to provide more valuable combined predictive score for RCC.

Due to unavailability of regional lymph nodes with the resected renal neoplasms in addition to the absence of information about vascular, nodal or adrenal involvement in the submitted pathological reports; tumor size in addition to peri-nephric fat invasion were used to broadly determine the pathological (p)T-stage of the tumor in the current work.

We used LS to prognosticate our patients into low, intermediate and high risk groups. Several authors [17] in different countries used LS and considered it an accurate score for prognostication the metastasis in patients with RCC after radical nephrectomy.

Although, we combined several parameters (size, pT, grade and necrosis) to categorize our patients into risk groups. Lymph nodes were not included in the current LS. Supporting evidences came from the clinician point of view [18], they reported that the potential benefits of lymph node dissection must be weighed against the possible risks and lymph nodes were not always available. Subsequently, we did not consider it as a corner stone for LS.

Another different point in the current study, we used LS in both types CCRCCs and Non-CCRCCs. Paucity of Non-CCRCCs made the others depend mainly on CCRCCs to establish LS. The current work credits modified LS (for CCRCCs as well as Non-CCRCCs and excluding the lymph node status). This modified form of LS achieved a significant correlation with alarming marker CD 105/Endoglin.

We used CD105 for assessment MVD in RCC as it was reported and considered as a superior angiogenic tumor marker due to its affinity to highlight the activated endothelial cell [19].

Furthermore, Yao and his colleagues [19] confirmed that both mature differentiated vessels and immature undifferentiated ones of RCC could be stained by CD105/Endoglin, opposite to other angiogenic markers like CD34 that could be expressed only in mature differentiated vessels of RCC.

We should differentiate between Endothelial and Tumoral expressed CD105; the endothelially expressed CD105 had been used to assess the microvessel density (MVD) of the solid tumor e.g. breast, prostate and RCC. While others [20] considered CD105 as stem cell marker of CCRCC and they evaluated it as intra tumoral cell marker. Our study evaluated CD105/Endoglin in activated endothelial cells only of RCC using MVD measurements.

In the current study, we found a statistically significant association between CD105 expression as MVD marker and Fuhrman's nuclear grade, the highest expression was detected in lower Fuhrman's grades.

Cioca and his colleagues study, 2019 [21] came in agreement with us; they reported that a high CD105-MVD was identified in a low Fuhrman's grade compared to those with a high grade RCC. However, Saroufim et al., 2014 [22] confirmed the same inverse relation between the tumor grade and the CD105 expression when it was evaluated as endothelial cell marker, but when it was evaluated as intra-tumoral stem cell marker of RCC, they reported a positive correlation.

Our results regarding CD105-MVD and the used Fuhrman grade raised the attention that this grade could not be used for diagnostic purpose only but also for a prognostic value especially if combined with integrated prognostic algorithm.

Another prognostic parameter (LS) recorded a significant moderate negative correlation with CD105-MVD; the group of high risky patients of metastasis (high LS) is associated with negative or low expression of CD105-MVD.

Conflicting results were published for assessment the CD 105/Endoglin as a prognostic indicator for RCC. Some studies [22,23] reported inverse correlation between CD105-MVD and survival in RCC similar to ours, other said no correlation [24], while some showed positive correlation [25].

This controversy may be attributed to several factors: Firstly, the researchers have been used different markers for assessment the MVD (CD34,

CD31, CD105 and Von Wilbrand factor), Even within the same marker, there is a big difference in the cutoff point of measurement and different scores of MVD. Our study used the median value of MVD as a cutoff point to record two tiers score (low versus high) similar to Habib et al., study [7] while others [22] used 3 tiers score system (low, intermediate and high score).

Secondly; we used semi-quantitative analysis (manually) with individual variations to estimate CD105-MVD by the average number of positive endothelial cells from the most three hot spots. While others [26] used an image analysis (automatized) with larger surface areas and different numbers of hot spots (5 or more) on each slide.

Thirdly; some researchers prefer assessment of MVD from the periphery of tumor while others and we did not select certain areas or zones from tumor regardless the center or the periphery. It is best to standardize certain zones for measurement as reported by Yao and his colleagues [19], they preferred the periphery of the tumor: It is usually the starting point of growth and progression of the tumor (advancing edge), away from the coagulative necrosis and to avoid the misinterpretation of mature normal vessels near to the center of tumor or adjacent to the normal renal tissue as a hotspot area.

Another contributing factor in the controversy is: The assessment of endothelial CD105 is differed completely from the assessment of intra tumoral CD105 as previously explained; the first was considered as a tool of MVD assessment in RCC and several authors showed inverse relation with prognosis. Opposite to the intra tumoral CD105 which assess the cancer stem cells inside the tumor, many authors [22] revealed positive relation between it and more aggressive behavior of RCC.

In our study, we could not detect any statistically significant correlation between CD105-MVD and each of the following parameters separately (size, necrosis and stage). However, Saroufim and his colleagues, 2014 [22] reported that increased CD105-MVD was associated with advanced pathological stage and poor clinical outcome of RCC.

Updated WHO classification declared that sarcomatoid renal cell carcinoma is no longer considered a separate tumor entity because it can be detected with all histological subtypes. However, the clinician is still considered the sarcomatoid RCC as one group whatever its histopathological subtitles [27].

As mentioned earlier, we did not achieve any significant association between the histopathological subtypes of RCCs and the investigated parameters except the sarcomatoid type CCRCC which could draw unique histopathological features among others. Thus, we will emphasize on these features.

Sarcomatoid differentiation was defined and identified by spindle cell proliferation, high cellularity and nuclear pleomorphism. Additionally we detected osseous metaplasia and necrosis. Cheville with his colleagues [28] reported 90% of sarcomatoid differentiation was associated with coagulative necrosis similar to our percent. By their name all sarcomatoid RCC recorded Fuhrman nuclear grade IV.

Our study clarified that all sarcomatoid differentiations were included under the category of clear cell RCC. This finding came in agreement with Shuch and his colleagues [29]; they stated that more than 80% of sarcomatoid RCC were associated with clear cell type. However, others [28] had been documented that whatever the associated primary histology (clear or chromophobe or papillary) would not alter the prognosis or treatment outcome. We are in need to more characterization of molecular profile of this sarcomatoid entity in each subtype separately.

Sarcomatoid CCRCC recorded the largest diameters of tumor size, harbored the characteristic coagulative necrosis in considerable large percentages, and showed the highest frequency of positive capsular and perinephric fat invasions. Although, there is obvious difference in the sarcomatoid features among others, they did not achieve any statistical significant association. It could be explained by type (II) statistical error due to small sample size.

Our study revealed that sarcomatoid type CCRCC recorded the lowest score of CD-105 MVD; however, the highest value of CD-105 MVD was detected in patients with conventional type CCRCC. These findings did not achieve any significant statistical association due to small sample size of each RCC subtypes (Type II statistically Error).

But histopathologically, they are indicating that the high MVD might be of a less aggressive tumor, this came in accordance with previous study by Jilaveanu et al., 2017 [30], who suggested the MVD is a hallmark of better tumor differentiation and less aggressive behavior.

One of the important associated features of sarcomatoid type is presence of coagulative necrosis adjacent to areas of spindle cell differentiation. Those areas exhibited low or negative expression of CD105-MVD due to insufficient tumor vascularization and inadequate oxygenation which display low MVD as reported by Sengupta and his colleagues [6].

We concluded that CD105- MVD can be used as a reliable predictive angiogenic marker for RCC with special precautions: Should be assessed endothelially, at the periphery of the invasive tumor, by lens x200 (0.74mm²) in three areas of hot spots, using the median value as cut off point for appropriate two or three tiers scoring system.

So in communities lacking the follow-up system, it can be used as alarming marker for prediction the outcome of RCC. Furthermore, it can be used as a target therapy (anti angiogenic factor).

We acknowledge the limitation of the present study which includes small sample size of each subtype, the wide base data for more accurate staging and additional panel of angiogenic markers for comparison and confirmation.

Conclusion:

We concluded that high CD105-MVD was correlated with more favorable pathological features, including clear cell type, lower Fuhrman grade and low LS. While Low CD105-MVD was indicator for worse pathological features: As sarcomatoid element, higher Fuhrman nuclear grade and high LS.

Declarations:

Ethical approval and consent to participate: The current study was approved by Ethical Committee of Sohag Faculty of Medicine (reference number is session: 15-4, 2018). Written informed consent was obtained from all patients.

Consent for Publication: Consent was obtained from all patients.

Availability of data and material: All raw data and materials were available.

Competing interests: Author declares no conflict of interest.

Funding: No specific funding was included or contributed.

Authors Contribution: Fatma El-Zahraa Salah El-Deen Yassin carried out manuscript writing & design, figures analysis & manipulation and his-

topathological diagnosis. Maisa Hashem Mohamed carried out manuscript writing & design and histopathological diagnosis. Atef Galal Abdel-Wahab carried out manuscript writing & design and clinical & surgical examinations. Eman Muhammad Salah El-Deen revised manuscript writing & design and histopathological diagnosis. All authors read and approved the manuscript in its submitted form.

Acknowledgements: Not applicable.

References

- 1- LEIBOVICH B.C., BLUTE M.L., CHEVILLE J.C., LOHSE C.M., FRANK I., KNOWN E.D., et al.: Prediction of Progression after Radical Nephrectomy for Patients with Clear Cell Renal Cell Carcinoma. A Stratification Tool for Prospective Clinical Trials. *CANCER*, 97 (7): 1663-1671, 2003.
- 2- D'Alterio C., Cindolo L, Portella L, Polimeno M, Consales C, Riccio A et al. Differential role of CD 133 and CXCR4 in renal cell carcinoma. *Cell Cycle* 2010; 9: 4492-4500.
- 3- KOPCZYNSKA E. and MAKAREWICZ R.: Endoglin-a marker of vascular endothelial cell proliferation in cancer. *Wspolczesna Onkologi*, 16 (1): 68-71, 2012.
- 4- HUMPHREY P.A., MOCH H., REUTER V.E., ULBRIGHT T.M., eds.: World Health Organisation (WHO) Classification of tumours. Pathology and genetics of the urinary system and male genital organs. Lyon, France: IARC Press, pp. 12-21, 2016.
- 5- SWAMI U., NUSSENZVEIG R.H., HAALAND B. and AGARWAL N.: Revisiting AJCC TNM staging for renal cell carcinoma: Quest for improvement. *Ann. Transl. Med.*, 7 (1): 1-5, 2019.
- 6- SENGUPTA S., LOHSE C.M., LEIBOVICH B.C., FRANK I., THOMPSON R.H., WEBSTER W.S., et al.: Histologic Coagulative Tumor Necrosis as a Prognostic Indicator of Renal Cell Carcinoma Aggressiveness. *CANCER*, 104 (3): 511-520, 2005.
- 7- HABIB M.A., RASHEED N.A. and IBRAHIM M.J.: Microvessel density in renal cell carcinoma. *J. Fac. Med. Baghdad*, 52 (4): 424-425, 2010.
- 8- WEIDNER N.: Current pathologic methods for measuring intratumoral microvessel density within breast carcinoma and other solid tumors. *Breast Cancer Res. Treat.*, 36: 169-80, 1995.
- 9- AKHTAR M., AL-BOZOM I.A. and AL HUSSAIN T.: Papillary Renal Cell Carcinoma (PRCC): An Update. *Adv. Anat. Pathol.*, 26 (2): 124-132, 2019.
- 10- LAU W.K., BLUTE M.L. and CHEVILLE J.C.: Pathologic stage T1 renal cell carcinoma: Prognostic value of tumor subtype, size, and Fuhrman grade after radical nephrectomy. *Urology*, 59: 532-537, 2002.
- 11- MOCH H., GASSER T., AMIN M.B., TORHORST J., SAUTER G. & MIHATSCH M.J.: Prognostic utility of the recently recommended histologic classification & revised TNM staging system of renal cell carcinoma: A Swiss experience with 588 tumors. *Cancer*, 89: 604-614, 2000.
- 12- DELAHUNT B., EBLE J.N., EGEVAD L. and SAMARATUNGA H.: Grading of renal cell carcinoma (Review). *Histopathology*, 74: 4-17, 2019.
- 13- VERA-BADILLO F.E., CONDE E. and DURAN I.: Chromophobe renal cell carcinoma: A review of an uncommon entity. *International Journal of Urology*, 19: 894-900, 2012.
- 14- FORIA V., SURENDRA T. and POLLER D.N.: Prognostic relevance of extensive necrosis in renal cell carcinoma. *J. Clin. Pathol.*, 58: 39-43, 2005.
- 15- UZZO R.G., KOLENKO V., FROELICH C.J., TANNENBAUM C., MOLTO L., NOVICK A.C., et al.: The T cell death knell: Immune-mediated tumor death in renal cell carcinoma. *Clin. Cancer Res.*, 7: 3276-3281, 2001.
- 16- FRANK I., BLUTE M.L., CHEVILLE J.C., LOHSE C.M., WEAVER A.L. and ZINCKE H.: An outcome prediction model for patients with clear cell renal cell carcinoma treated with radical nephrectomy based on tumor stage, size, grade and necrosis: The SSIGN score. *J. Urol.*, 168: 2395-2400, 2002.
- 17- VASDEV N., ALTAL Y., MAFELD S., WONG K., CHADWICK D., GOWDA B.D.R., et al.: Can the Leibovich score for clear cell renal cell carcinoma (ccRCC) be accurately reported by a general pathologist? *BJU Int.*, 113: 581-585, 2014.
- 18- FREEDLAND S.J. and DEKERNION J.B.: Role of lymphadenectomy for patients undergoing radical nephrectomy for renal cell carcinoma. *Rev. Urol.*, 5: 191-195, 2003.
- 19- YAO X., QIAN C.N., ZHANG Z.F., TAN M.H., KORT E.J., YANG X.J., et al.: Two Distinct Types of Blood Vessels in Clear Cell Renal Cell Carcinoma Have Contrasting Prognostic Implications. *Clin. Cancer Res.*, 13 (1): 161-196, 2007.
- 20- GRANGE C., TAPPARO M., COLLINO F., VITILLO L., DAMASCO C., DEREGIBUS M.C., TETTA C., BUS-SOLATI B. and CAMUSSI G.: Microvesicles released from human renal cancer stem cells stimulate angiogenesis and formation of lung premetastatic niche. *Cancer Res.*, 71 (15): 5346-5356, 2011.
- 21- CIOCA I. A., MUNTEAN D. and BUNGARDEAN C.: CD 105 as a tool for assessing microvessel density in renal cell carcinoma. *Indian Journal of Pathology and Microbiology*, 62 (2): 239-243, 2019.
- 22- SAROUFIM A., MESSAI Y., HASMIM M., RIOUX N., IACOVELLI R., VERHOEST G., et al.: Tumoral CD105 is a novel independent prognostic marker for prognosis in clear-cell renal cell carcinoma. *Br. J. Cancer*, 110: 1778-84, 2014.
- 23- SANDLUND J., HEDBERG Y., BERGH A., GRANKVIST K., LJUNGBERG B. and RASMUSON T.: Endoglin (CD 105) expression in human renal cell carcinoma. *BJU Int.*, 97: 706-10, 2006.
- 24- BAUMAN T., HUANG W., LEE M.H. and ABEL J.E.: Neovascularity as a prognosis marker in renal cell carcinoma. *Hum. Pathol.*, 57: 98-105, 2016.
- 25- DUBINSKI W., GABRIL M., IAKOVLEV V.V., SCORILAS A., YOUSSEF Y.M., FARAGALLA H., et al.: Assessment of the prognostic significance of endoglin (CD 105) in clear cell renal cell carcinoma using automated image analysis. *Hum. Pathol.*, 43: 1037-43, 2012.

- 26- QIAN H., YANG L., ZHAO W., CHEN H. and HE S.: A comparison of CD105 and CD31 expression in tumor vessels of hepatocellular carcinoma by tissue microarray and flow cytometry. *Experimental and Therapeutic Medicine*, 16: 2881-2888, 2018.
- 27- SHUCH B., BRATSLAVSKY G., LINEHAN W.M. and SRINIVASAN R.: Sarcomatoid Renal Cell Carcinoma: A Comprehensive Review of the Biology and Current Treatment Strategies. *The Oncologist*, 17: 46-54, 2012.
- 28- CHEVILLE J.C., LOHSE C.M., ZINCKE H., WEAVER A.L., LEIBOVICH B.C., FRANK I., et al.: Sarcomatoid renal cell carcinoma: An examination of underlying histologic subtype and an analysis of associations with patient outcome. *Am. J. Surg. Pathol.*, 28: 435-441, 2004.
- 29- SHUCH B., SAID J., LA ROCHELLE J.C., ZHOU Y., LI G., KLATTE T., et al.: Cytoreductive nephrectomy for kidney cancer with sarcomatoid histology is up-front resection indicated and, if not, is it avoidable? *J. Urol.*, 182: 2164-2171, 2009.
- 30- JILAVEANU L.B., PULIGANDLA M., WEISS S.A., WANG X.V., ZITO C., FLAHERTY K.T., et al.: Tumor Microvessel Density as a Prognostic Marker in High-Risk Renal Cell Carcinoma Patients Treated on ECOG-ACRIN E2805. *Clin. Cancer Res.*, 24 (1): 217-223, 2018.

تقييم سى دى ١٠٥ لتولد الأوعية الدموية كدلالة أورام مثيرة للجدل فى سرطان الكلية وذو طابع خاص فى سرطان الأنسجة الرخوة

يشمل سرطان الكلية مجموعة غير متجانسة من الأورام ذات متنبآت مختلفة. ولا تزال كثافة تكون الأوعية الدموية معامل مثير للجدل فى التنبؤ بمصير هذا السرطان.

ويهدف البحث لتقييم كثافة الأوعية الدموية باستخدام سى دى ١٠٥ فى هذا السرطان واستخدامه كمعامل للتنبؤ بمصير سرطان الكلية ولقد وجدنا علاقة إحصائية قوية بين الخواص الهستوباثولوجية ونظام تقييم وتدرج الانوية (فيرمان) وبين (لبى بفيوتش) سكور. بينما ثبت عدم وجود علاقة إحصائية بينه وبين معاملات أخرى مثل الحجم والتخثر والمرحلة الباثولوجية.

ويمثل سرطان الكلية ذو الطابع الخاص أعلى نسبة لغزو الغشاء الخارجى والدهون وأقل درجة فى تعبير سى دى ١٠٥.

ويستخلص من البحث أن التعبير العالى لسى دى ١٠٥ يمثل تنبؤ جيد لسرطان لكية ويكون مصاحباً لصفات جيدة للمرض مثل نوعه ودرجة تميزه.

كما وضع سرطان الكلية ذات الطابع الرخو صفات مميزة جداً باستخدام سى دى ١٠٥.