

Reproductive Impairment of *Tilapia zillii* (Gerv.) Living in Different Basins of Lake Mariut, Alexandria

Hala A. Abdel-Mohsen[†], Mahmoud B. Abu-Shabana[‡], Hamed H. Saleh[†], Soheir M. E. Khadre[‡], Sherief E. Ramadan[†]

Abstract: This study aimed at inspecting pollution impact on the reproduction process of *Tilapia zillii* (Gerv.) living in three main basins of Lake Mariut. Our results revealed that there were two main seasons detected for males and females during a whole year of investigation, namely, non-spawning and spawning seasons. In males, though the two seasons started and ended simultaneously, gonadosomatic index values of males living in the relatively clean area were significantly higher than those of the other two polluted areas. However, no structural alterations could be detected in sections of male gonads from the three basins. All stages of maturation were represented in all gonad sections. In females, gonadosomatic index values of fish living in the relatively clean basin were significantly higher than those of fish living in the other two polluted areas. Females living in the relatively clean area attained two prominent peaks during the spawning season compared to one peak for the other two polluted areas. Spawning season for one of the two polluted areas was one month shorter than the reference area. Histologically, belated and deformed maturation stages as well as ruptured and empty follicles were observed in female gonad sections from the two polluted areas.

Keywords *Tilapia zillii*, gonadosomatic index, gonads histology, Lake Mariut, pollution.

INTRODUCTION

Lake Mariut is the smallest lake and the most polluted one among the shallow brackish-water Delta Lakes that used to have high fishery production and that gradually became loaded with polluted discharge from the adjacent urban and industrial settlements.¹ The combination

of pollutants in the Lake caused many sensitive fish genera to disappear. In addition, the quantity and the quality of the least sensitive species that survived had greatly deteriorated and became of low survival rate due to the absence of dissolved oxygen and the presence of high

[†] National Institute of Oceanography and Fisheries, Kayet-Bay, Al-Anfoushy, Alexandria, Egypt.

[‡]Zoology Dept., Faculty of Science, Alexandria University, Alexandria, Egypt.

levels of toxic gases such as ammonia and hydrogen sulphide.^{2,3} The main basins of the Lake are known to receive nearly all types of pollutants due to sewage, industrial and agricultural effluents discharged in it.⁴⁻⁷ These effluents can contain chemicals capable of mimicking endogenous hormones, and hence have the potential to disrupt endocrine-mediated processes such as reproduction.⁸ Male fish exposed to these compounds in the ecosystem may exhibit a range of reproductive problems including constrained or disrupted testicular development and physiological and anatomical feminization, coupled with elevated levels of the female-specific protein, vitellogenin (VTG).⁹⁻¹¹ In mature females of zebrafish, the synthetic estrogen 17 α -ethynylestradiol (EE2), detected in sewage effluents and in surface waters,^{12,13} was proved to reduce yolk-filled oocytes.¹⁴ Therefore, the aim of the present work was to detect the reproductive impairment in *Tilapia zillii* males and females living in three

different basins of Lake Mariut, during a whole year of investigation. The approach to this aim mainly based on following up gonadosomatic index (GSI) values of *T. zillii* males and females throughout the investigation period and by taking sections in gonads of both sexes during two distinct seasons, namely, the non-spawning and spawning seasons.

MATERIAL AND METHODS

Sampling Site:

Lake Mariut is an important fishing Lake at the southern area of Alexandria City, Egypt (Fig. 1). It lies at a longitude of 30°10' E and a latitude of 31°10' N and has no direct connection with the Mediterranean Sea. Lake Mariut is mainly divided into four main basins; these are Lake Proper or the main basin, the Fish Farm, the North-western (N.W.), and South-western (S.W.).

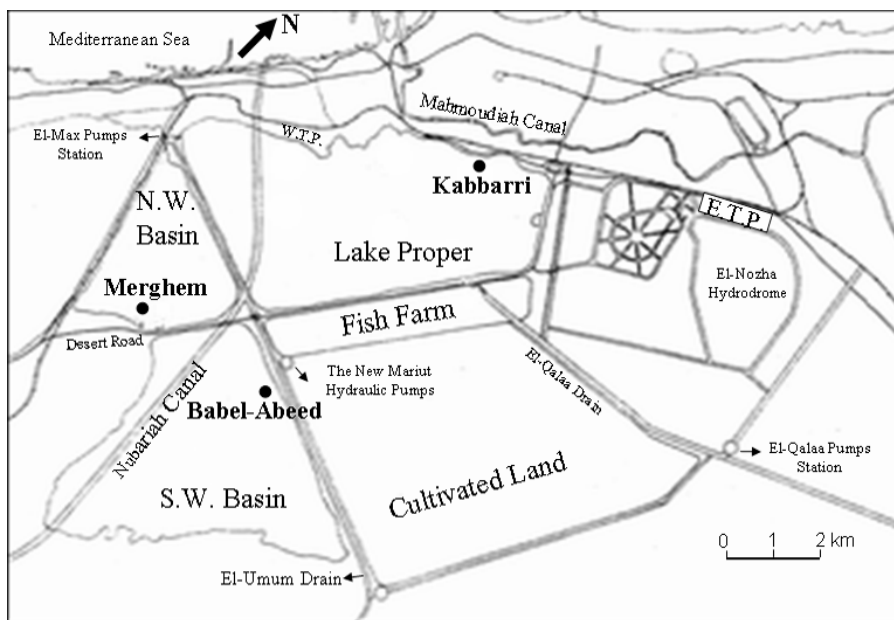


Fig. 1: Lake Mariut Map showing the three sampling sites: the reference area Babel-Abeed and the two polluted areas Kabbarri and Merghem.

In this study, three stations were chosen for sampling representing three main basins of Lake Mariut. The first station is Babel-Abeed (BA) which represents the S.W. basin. This basin receives seepage from El-Umum Drain and Nubariah Canal. It is a relatively clean station and was thus taken

as a reference area. The second station is Kabbarri (Ka) which represents the main basin of Lake Mariut or Lake Proper. This basin is boarded by highways from three sides and by the Nubariah Canal and El-Umum Drain at the West.⁵ It is a highly polluted area that receives flow from El-Qalaa Drain which carries agricultural wastewater, sewage discharge, and industrial effluents to the basin. It also receives effluents from the West Treatment Plant (WTP), and El-Umum Drain.⁷ The third station in the present study is Merghem (Me) which represents the N.W. basin. This area is heavily polluted with petroleum hydrocarbons due to its connection with a drain carrying effluents from El-Amereyya Petroleum Refinery Company.⁴

Study Species:

Each month, for a whole year, about 30 specimens of *Tilapia zillii* (Gerv.) were bought alive from various fishermen at each

basin and brought to the laboratory in oxygen-packed plastic containers.

Gonadosomatic Index (GSI):

To follow up quantitative gonadal growth of *T. zillii* males and females during a whole year, GSI of gonads were computed using the following equation of Schaefer and Orange¹⁵; $GSI = \frac{\text{Gonad Weight}}{\text{Gutted weight}} \times 100$; where both gonad and gutted weight of fish were expressed in grams.

Gonads Histology:

Gonads of males and females of *T. zillii* specimens collected from the three basins of Lake Mariut were cut free and excised into small portions. These portions were fixed in Carnoy's Solution for 24 h, then transferred to 70% alcohol and processed using routine histological techniques. Paraffin sections of 4 -5 μm were stained with Haemtoxylin and Eosin and examined microscopically (Olympus CX41).

Statistical Analyses:

Data were expressed as mean \pm S.D. Student *t*-test was used to compare between the mean values of GSI of the reference area and the heavily polluted areas (*t* was considered significant at $p < 0.05$).

RESULTS

GSI of *Tilapia zillii*:

In this study we tried to detect the effect of different types of pollution present in three main basins of Lake Mariut on *T. zillii* reproduction process through one year of investigation. Our GSI results generally revealed that through a whole year of investigation there were two distinct seasons for all males in all studied areas (Fig. 2). These two seasons are the non-spawning season and the spawning one. In the relatively clean area of BA and the other two polluted areas, non-spawning season extended from October until April with the minimum value recorded in January for BA, in March for Ka and in October for Me. On

the other hand, spawning season, in which main spermatogenic activities took place, started in May and ended in September for all males of all studied regions with maximum values recorded in May for males of BA and Ka and in July for Me. However, it was worth noting that during the spawning season, BA area (reference area) exhibited higher values than that of Ka and Me. Statistically, the difference was significant ($p < 0.05$).

As for females of *T. zillii* living in the three studied basins of Lake Mariut, the present study showed that two distinct seasons were distinguishable (Fig. 3). The non-spawning season started in October for females living in BA (reference area) and Ka and ended in April. However, in Me, the non-spawning season extended from September till April. The minimum GSI value was recorded in February for BA and Me. In Ka, the least GSI value was recorded in March. On the other hand, the spawning

season for females in all studied regions started in May, while it ended in September for females of the relatively clean area and that of Ka. In Me, the spawning season ended in August which is a month earlier

and Me were detected in May. Noticeably, BA recorded two peaks during the spawning season, one in August and the second one was noticed in May. The other two polluted basins only exhibited one peak during the same season. There was a significant difference between the mean values of females GSI recorded in BA and those of Ka and Me ($p < 0.05$).

than the reference area. The highest recorded value of GSI in BA area was in August, whereas the highest values in Ka

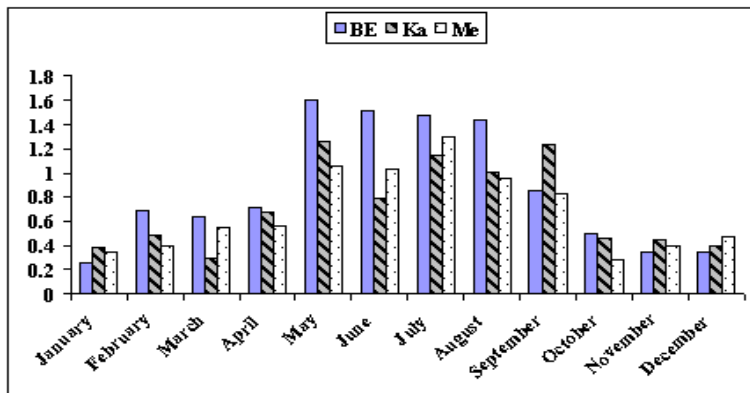


Fig. 2: Gonadosomatic index (GSI) of *T. zillii* males recorded in the three basins during one year; the reference area BA and the two polluted areas Ka and Me.

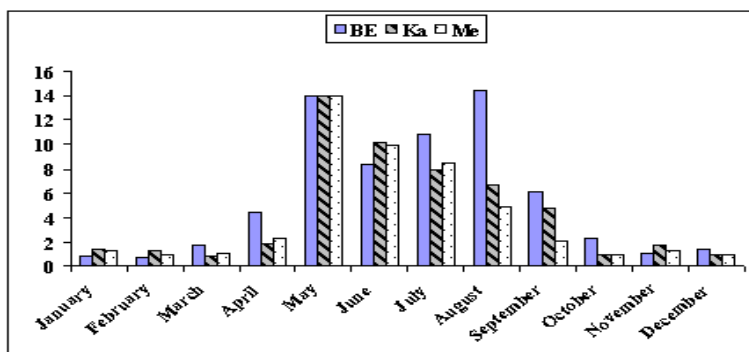


Fig. 3: Gonadosomatic index (GSI) of *T. zillii* females recorded in the three basins during one year; the reference area BA and the two polluted areas Ka and Me.

Histology of *Tilapia zillii* gonads:

Histological changes are highly desirable as an aid in understanding the mechanism of different pollutants and can have a diagnostic value in fish mortality investigation. According to our histological results, it was found that maturation of *T. zillii* males of the three studied regions passed through five stages, namely, spermatogonia (spg), primary spermatocyte (1st spc), secondary spermatocyte (2nd spc), spermatids (spT), and sperms (sp). During the non-spawning season, it was revealed that gonads of males in the three studied areas displayed more or less the same histological details (Fig. 4). Structurally, these gonads were shown to have an outer layer or tunica propria (tp) and radial arrangement of seminiferous tubules (st). Large numbers of spg were found to be preponderating in between radial seminiferous tubules. Enlarged sections of these gonads revealed the presence of few

numbers of 1st spc, 2nd spc, and spT, thus indicating an early stage of maturation. It was worth noting that, there was no conspicuous histological differences between sections taken from the relatively clean area of BA and the other two heavily polluted areas of Ka and Me. During the spawning season, all gonad sections showed relatively empty seminiferous tubules with few numbers of unshed sperms (Fig. 5). Apparently large dispatches of sperms had already been dispatched to the surrounding medium during the spawning season. Larger numbers of 1st spc, 2nd spc, and spT could be seen in preparation for the next spawning season. As was the case during the non-spawning season, no obvious histological differences could be detected between the structures of male gonads in all three studied basins.

Histological pictures taken for gonads of females living in the three studied regions revealed five stages of maturation during

the non-spawning season and the spawning one. These stages were identified as primary oocyte (Po), developing oocyte (Do), yolk vesicle oocyte (Yvo), and mature ovum (Mo). One more stage was detected in females of Me basin and identified as ripe ovum (Ro). While mature ova were characterized by thin layer of zona radiate (ZR), ripe ova were distinguished by thicker ZR. During the non-spawning season, sections taken from females of BA region displayed normal histological picture of ovary including different stages of oocytes, namely, Po, Do, and few Yvo (Fig. 6). On the other hand, deformed oocyte stages in addition to empty follicles and distended follicle epithelium were clearly shown in sections taken from females of the two polluted areas of Ka and Me. During the spawning season, sections taken from the relatively clean area of BA and the polluted area of Me showed advanced stage of maturation in which mature and ripe ova were seen to fill the whole volume of the ovary (Fig. 7). Conversely, a lesser stage of maturation was detected in female sections taken from Ka. Large Yvo were only seen in these sections. Neither mature nor ripe ova could be detected in these sections.

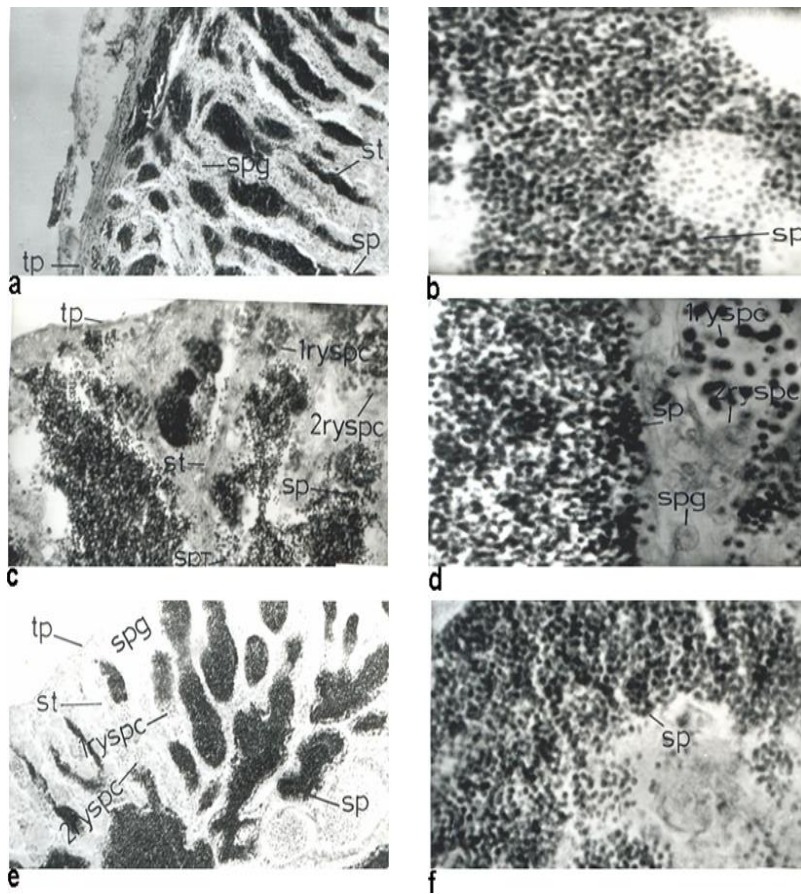


Fig. 4: Histological sections in male gonads of *T. zillii* from the reference area BA (a) x 500 and (b) x 1250, polluted areas; Ka (c) x 500 and (d) x 1250 and Me (e) x 500 and (f) x 1250, during non-spawning season. 1^{ry} spc: primary spermatocytes; 2^{ry} spc: secondary spermatocytes; st: seminiferous tubules; spT: spermatids; sp: sperms; spg: spermatogonia; tp: tunica propria.

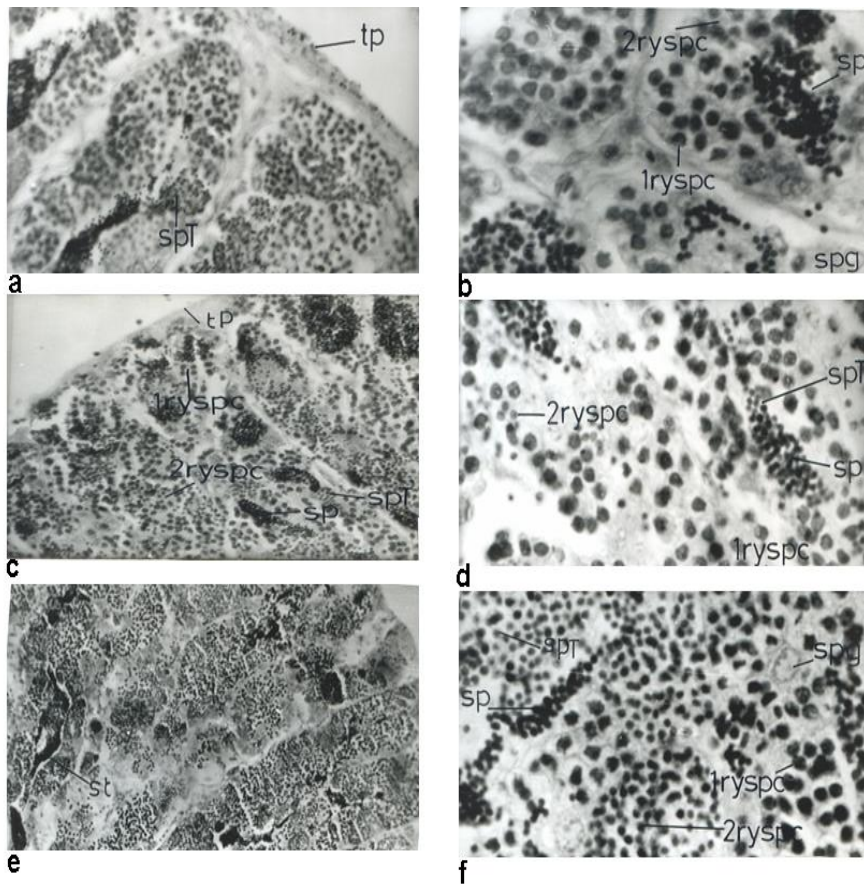


Fig. 5: Histological sections in male gonads of *T. zillii* from the reference area BA (a) x 500 and (b) x 1250, polluted areas; Ka (c) x 500 and (d) x 1250 and Me (e) x 500 and (f) x 1250, during spawning season. 1^{ry} spc: primary spermatocytes; 2^{ry} spc: secondary spermatocytes; st: seminiferous tubules; spT: spermatids; sp: sperms; spg: spermatogonia; tp: tunica propria.

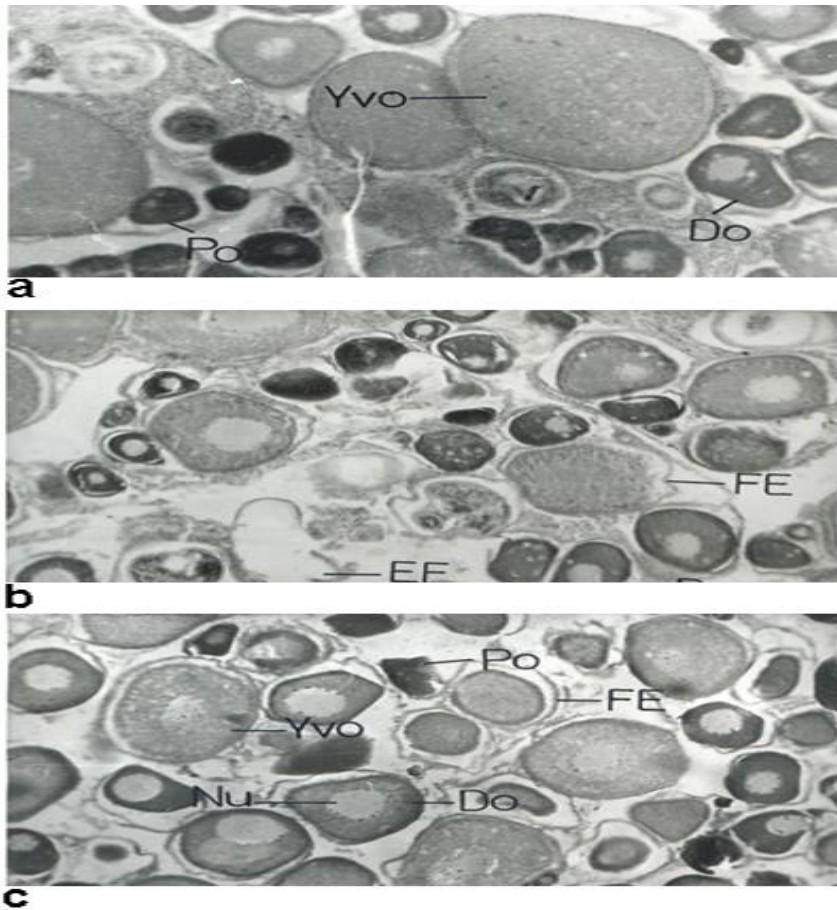


Fig. 6: Histological sections in female gonads of *T. zillii* from a) x 125 and polluted areas; Ka (b) x 125 and Me (c) x 125, during non-spawning the reference area BA (season. Do: developing oocyte; EF: epithelial follicle; FE: follicular epithelium; Nu: nucleus; Po: primary oocyte; Yvo: yolk vesicle oocyte.

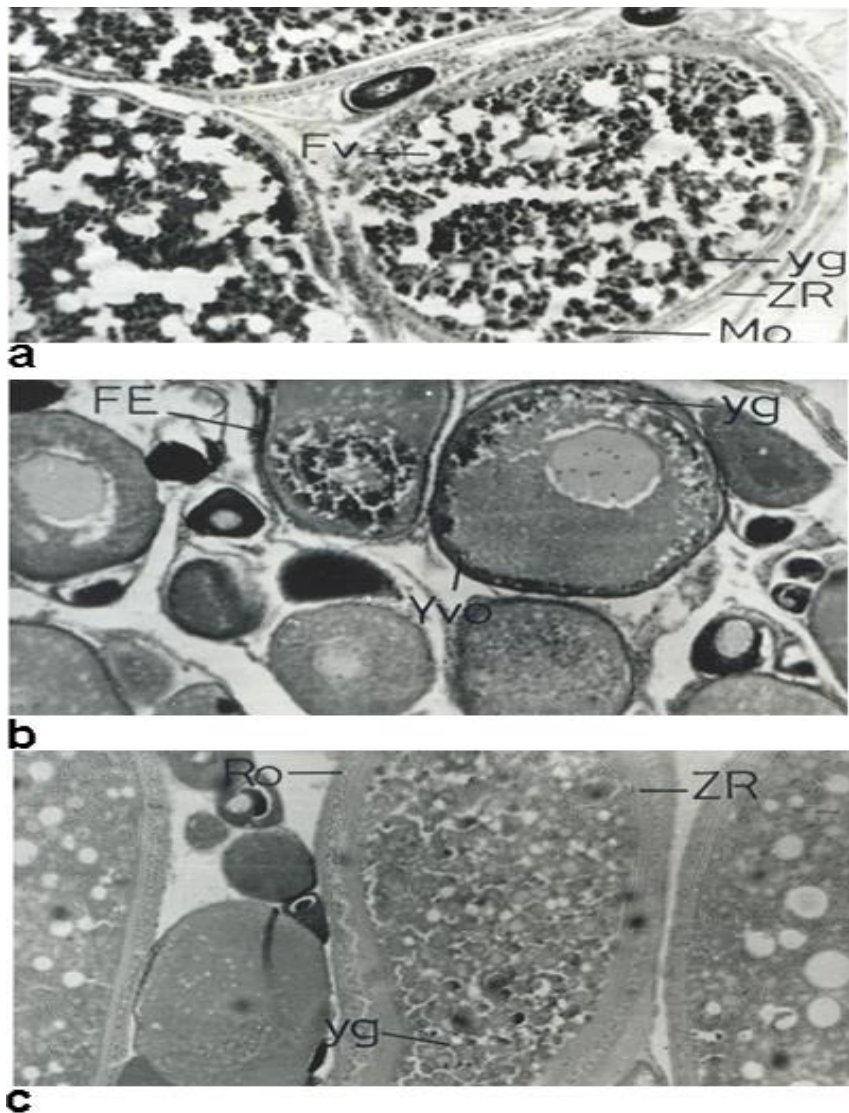


Fig. 7: Histological sections in female gonads of *T. zillii* from the reference area BA (a) x 125 and polluted areas; Ka (b) x 125 and Me (c) x 125, during spawning season. FE: follicular epithelium; Fv: fat vacuoles; Mo: mature ovum; Ro: ripe ovum; yg: yolk globule; Yvo: yolk vesicle oocyte; ZR: zona radiata.

DISCUSSION

Many fresh water habitats, particularly rivers and lakes in urban areas, now receive substantial volumes of effluents from various sources, including industrial, agricultural, and domestic ones. These effluents can contain chemicals capable of mimicking endogenous hormones, and hence has the potential of disrupting endocrine-mediated processes such as reproduction.⁸ Lake Mariut is a typical example of these habitats since it receives nearly all types of industrial, agricultural and sewage discharges.^{4,7} While many fish genera have disappeared from the Lake, *Tilapia zillii* was one of those few which had proved to be of higher tolerance and resistance to the surrounding challenges. Therefore, the present study aimed at testing the reproductive status of *T. zillii* in response to the severe environmental conditions in which it lives.

Indeed, the present results revealed that though GSI of *T. zillii* male fish living in relatively clean area and the heavily polluted started and ended both the non-spawning and the spawning in the same months, GSI values recorded in the relatively clean area (especially during the spawning season) were significantly higher than those recorded in the heavily polluted basins. This result agreed with many other investigators who found that there had been a decrease in GSI values reported in adult male trout and carp exposed to estrogens either in water or via food.¹⁶ Additionally, many had recorded apparent effects of xenobiotic compounds on gonads included reduction of gonad size (thus a reduction in gonadosomatic index) and the reduction in numbers of germ cells which sometimes bring animals to complete sterility.^{9,17}

It was worth noting, however, that

pollution in the Lake, apparently, had not yet extended its effect on the structure of male gonads in any of the three studied basins. All stages of maturation were well represented in all gonad sections. This could mean that *T. zillii* males living in the Lake were tolerant and resistant to the already existing pollutants. In accordance with this result was the study on *T. zillii* sperm from the reference area of BA and the polluted areas of Ka of Lake Mariut which detected no morphological differences between sperms from the two areas.¹⁸ Nevertheless, our result contradicted with many other authors who reported severe histological alterations in testes structure subjected to different xenobiotic compounds, such as: damage in epithelial cells of seminal ducts and reduction of spermatozoa number in them.¹⁹ These contradictory outcomes might have

stemmed out from the fact that different fish species react differently to the same stress. Additionally, fish of the genera tilapia are generally characterized by a wide tolerance to spacious range of environmental conditions.²⁰

Following up the GSI values or the quantitative characteristics of female gonadal growth in the three studied basins during one year of investigation revealed many points of interest regarding pollution effect. In addition to significantly reducing GSI values of female fish living in the two polluted areas (as was the case in males), pollution had an effect on the duration of spawning season too which was reduced one month in Me basin. Pollution also had an effect on the number of maximum spawning activity and gonadal growth in females. Female fish living in the relatively clean area exhibited two maximum peaks at

spawning season. On the other hand, male fish living in the two polluted areas failed to attain but one peak of gonadal growth. These results were also detected by many authors who reported inhibition of gonadal recrudescence in the catfish *Clarias batrachus* (L.) and in *Chana punctatus*^{21,22} and inhibition of gametogenesis in *Poecilia reticulata* (guppy)²³ due to the exposure to different pollutants. Others reported reduced growth of the mummichog, *Fundulus heteroclitus*²⁴ and of rainbow trout²⁵ from polluted habitat.

Contrary to the intact male gonadal sections, female histological ones showed many aspects of pollution impact which were manifested in the deformation of different maturation stages (primary oocyte and developing oocyte) and the belated stage of maturation recorded in one of the heavily polluted basins (Ka). This was in agreement with other authors who recorded that ovaries of female rare minnow in 25 ng/l

of a xenobiotic compound treatment group were degenerated.²⁶

In conclusion we can say that females of *T. zillii* living in polluted basins of Lake Mariut were more vulnerable to pollution hazards than males of the same species. Though GSI values of *T. zillii* males were significantly affected, males were proved to be more tolerant or resistant to gonadal structure alterations and gonadal growth delay or inhibition in response to external environmental challenges.

REFERENCES

1. El-Rayis OA, El-Sabrouti MA. Pollution problems and proposals for restoration. J Arab Acad Sci Techn. 1998;23: 16–28.
2. Saleh HH, Hamza A, El-Baghdadi BS. Effect of water pollution on fish population of Lake Mariut. Bull HIPH. 1983;13 (5): 233-47.
3. Saleh HH, Hamza A, El-Baghdadi BS. Effect of water pollution in Lake Mariut mortality and survival of *Tilapia zillii* (Gerv.). Bull HIPH. 1983: 13 (5): 59-76.
4. Saleh HH, Hamza A. Study on the health condition of *Tilapia zillii* (Gerv.) living in polluted water of Merghem zone, Lake Mariut, Alexandria (Egypt). FAO Fish Report. 1984: 334 (supplementary): 132-41.
5. Smaan A, Abdel-Moneim MA. Some physical features of the polluted basin

- and Fish Farm in Lake Mariut, Egypt. Bull Natl Inst Oceanogr Fish. 1986: 12: 149-63.
6. El-Sharkawi FM. Management of Lake Mariut pollution. Proceedings of International Conference of "Environmental Protection is a Must", U.S.P.D. 1991.
 7. El-Rayis O. Impact of man's activities on a closed fishing-lake, Lake Maryout in Egypt, as a case study. Mitig Adapt Strateg Glob Change. 2005: 10: 145–57.
 8. Sumpter JP. Environmental control of fish reproduction: a different perspective. Fish Physiol Biochem. 1997: 17 (1-6): 25-31.
 9. Jobling S, Sheahan D, Osborne JA, Matthiessen P, Sumpter JP. Inhibition of testicular growth in rainbow trout *Oncorhynchus mykiss* exposed to estrogenic alkylphenolic chemicals. Environ Toxicol Chem. 1996: 15 (2): 194-202.
 10. Harries JE, Sheahan DA, Jobling S, Matthiessen P, Neall P, Sumpter JP, et al. Estrogenic activity in five United Kingdom rivers detected by measurement of vitellogenesis in caged male trout. Environ Toxicol Chem. 1999: 16: 534–42.
 11. Kime DE, Nash JP. Gamete viability as an indicator of reproductive endocrine disruption in fish. Sci Total Environ. 1999: 233: 123–9.
 12. Stumpf M, Ternes TA, Ilaber K, Baumann W. Determination of natural and synthetic estrogens in sewage plants and river water. Vom Wasser. 1996: 87: 251–61.
 13. Ternes TA, Stumpf M, Mueller J, Haberer K, Wilken RD, Servos M. Behavior and occurrence of estrogens in municipal sewage treatment plants – I. Investigations in Germany, Canada and Brazil. Sci Total Environ. 1999: 225, 81–90.
 14. Van den Belt K, Verheyen R, Witters H. Reproductive effects of ethynylestradiol and 4 t-octylphenol on the zebrafish (*Danio rerio*). Arch Environ Contam Toxicol. 2001: 41: 458- 67.
 15. Schaefer MB, Orange CJ. Studies on the sexual development and spawning of yellowfin tuna (*Neothunnus macropterus*) and skipjack (*Katsuwonus pelamis*) in the three areas of eastern Pacific Ocean by examination of gonads. Bull. I-ATTC. 1956: 1(16): 281-349.
 16. Komen J, Lodder PAJ, Huskens F, Richter CJJ, Huisman EA. Effect of oral administration of 17-methyltestosterone and 17 β -estradiol on gonadal development in common carp, *Cyprinus carpio* L. Aquaculture. 1989: 78: 349–63.
 17. Leatherland J. Endocrine and reproductive functions in Great Lakes salmon. In: Colborn T, Clement C, eds. Chemically induced alterations in sexual and functional development: the wildlife/human connection. Princeton Scientific Publishing; 1992. p. 129–145.
 18. Khadre SEM. Ultrastructure and X-ray microanalysis of spermatozoa in *Tilapia zillii* survived in Lake Mariut, Alexandria, Egypt. Proceedings of International Conference of "Environmental Protection is a Must", U.S.P.D. 1992.
 19. Mochida K, Ito K, Kono K, Onduka T, Kakuno A, Fujii K. Molecular and histological evaluation of tributyltin toxicity on spermatogenesis in a marine fish, the mummichog (*Fundulus heteroclitus*). Aquat Toxicol. 2007: 83: 73–83.
 20. Chervinski J. Environmental physiology of tilapias. In: Pullin, RSV, Lowe-McConnell, RH, eds. The biology and culture of tilapias. Int Cent Liv Aquat Resour Manage. Manila: 1982. p. 119-128.

21. Kirubakaran R, Joy KP. Inhibition of testicular 3β -hydroxy-5 steroid dehydrogenase (3β -HSD) activity in the catfish *Clarias batrachus* (L.) by mercurials. Indian J Exp Biol. 1988; 26: 907-8.
22. Dey S, Bhattacharya S. Ovarian damage to *Chana punctatus* after chronic exposure to low concentration of elsan, mercury and ammonia. Ecotoxicol Environ Safety. 1989; 17 (2): 247-57.
23. Wester PW, Canton HH. Histopathological effects in *Poecilia reticulata* (guppy) exposed to methylmercury chloride. Toxicol Pathol. 1992; 20 (1): 81-92.
24. Weis, JS, Khan, AA. Effect of mercury on the feeding behavior of the mummichog, *Fundulus heteroclitus* from a polluted habitat. Mar Environ Res. 1990; 30: 243-9.
25. Niimi AJ, Kisson GP. Evaluation of the critical body burden concept based on inorganic and organic mercury toxicity to rainbow trout (*Oncorhynchus mykiss*). Arch Environ Contam Toxicol. 1994; 26 (2): 169-78.
26. Zha J, Wang Z, Wang N, Ingersoll C. Histological alternation and vitellogenin induction in adult rare minnow (*Gobiocypris rarus*) after exposure to ethynylestradiol and nonylphenol. Chemosphere. 2007; 66: 488–95.