

# ASDJ

AINSHAMS DENTAL  
JOURNAL

Print ISSN 1110-7642

Online ISSN 2735-5039

AIN SHAMS DENTAL JOURNAL

Official Publication of Ain Shams Dental School

June 2021 • Vol. XXIV

## The accuracy of implant placement using opened versus closed sleeve computer surgical guide A Split mouth technique

*Samah Ahmed Abdallah<sup>1</sup>, Amal Fathy Kaddah<sup>2</sup> & Amr Hosney Elkhadem<sup>3</sup>*

### Abstract

**Statement of problem:** The proper implant placement requires a proper and adequate planning for the anatomic limitations and achievement of the best restorative results. The Cone Beam C.T can properly diagnose implant positioning, but transfer of the preplanned position to the surgical field was missed. From there it became mandatory to perform surgical guide to transfer the preplanned position of implants to the surgical field to ensure accuracy of implant placement.

**Purpose:** The interest from this study was to evaluate the accuracy of implant placement using different surgical guides; the surgical guides with closed sleeve versus the surgical guides with open sleeve. After placement of the implants via the surgical guides investigate if there was any deviation of the preplanned implant position with the actual placed implant positioning to evaluate the accuracy of implant placement.

Many radiographic techniques had been used to diagnose implant placement positioning, computed tomography considered to be the most superior above all other radiographic technique. After scanning of the patient by cone beam C.T the scanned file was uploaded to a specialized software (BLUE SKY), through this software virtual planning of implant was done and after that fabrication of the surgical guide to place the implant in the preplanned position that had been done. After implant placement another cone beam scan was done and then superimpose of the preoperative cone beam C.T with the Post-operative cone beam C.T was done through BLUE SKY software to calculate if there were any deviation from the preplanned implant positioning.

**Keywords :** Computer guided, Accuracy, Implant , surgical guides, Cone Beam CT

- 
1. Master student, Faculty of Dentistry Cairo University.
  2. Professor of Prosthodontics, Faculty of Dentistry, Cairo University.
  3. Assistant Professor of Prosthodontics, Faculty of Dentistry, Cairo University

## Introduction:

The dental implant had revolutionized the oral rehabilitation of both partially and completely edentulous patients. Dental implants are the golden slandered treatment in restoring the missing teeth [1] [2] [3].

Conventional surgical implant placement has some hazards in placing implants in relation with adjacent anatomical structure, in addition that implants prosthetic part wasn't well planned before placement [4] [5].

The introduction of computer aided implant placement has greatly helped in precise diagnosis and implant planning for complex cases with anatomical limitations, as well as prosthetic implant placement with the aid of advanced radiographic techniques. Not only but also less post-operative complications due to flapless surgery as well as better in patient satisfaction [6] [7] [8].

With no doubt the good osteointegration relies on two main factors, precise surgical placement as well as proper loading of implant later. Prosthetic implant placement ensures not only successful implant placement but also optimal prosthetic part later in regards to implant positioning [9] [10] [11].

Planning for implant positioning starts with diagnostic teeth set up, and then make a radiographic stent, upon which scanning of the patient wearing the stent is done to virtually plane of implants in their suspected position later [12] [13] [14].

Radio-opaque markers are added to the stent at the proposed implant site to relate the desired implant location with underlying bone. There are many radiographic techniques that have been used in imaging implants; however the most recent 3D diagnostic imaging protocol is done using

computed tomography machine [15] [16] [17].

Thanks to the 3D implant planning software, image guided template production techniques, computed aided surgery have introduced to make planning much easier and much more accurate [18] [19] [20].

The 3D image in DICOM format is demonstrated with planning soft-ware to manage the plan, moreover constructing a rapid prototype surgical guide for creating provisional or definitive restorations [7] [21] [22].

Surgical guides could be classified according to what had been stated in the literature; degree of limitations; none limiting, partially limiting and completely limiting guides, also classified to cast based surgical guide, CAD/CAM surgical guide. As well as type of support; bone supported, mucosa supported and tooth support [23] [24] [25].

Not only but also according to degree of guidance partially guided and fully guided surgical guides. Surgical guides are also classified by methods of manufacturing, as well as static guides or dynamic surgical guides [6] [26] [27].

Surgical guides according to sleeve design closed surgical sleeve and open or half channeled surgical sleeve, although closed surgical guides showed to be high accuracy than open or half channeled sleeves, there was no statistically significant difference between them as concluded from further studies [28] [29].

To the best of our knowledge so this study was done to investigate if there was any different in accuracy provided from different surgical guide sleeve design (closed versus open sleeve) and investigate as well it is effect upon heat generation and osteotomy.

As heat generation could greatly affect osteotomy and it is one of the main factors in implant success, could the half

channeled or open sleeve be better lowering the heat generation by making more space for providing coolant during osteotomy[30].

## Material and methods:

### Study design and sample size selection:

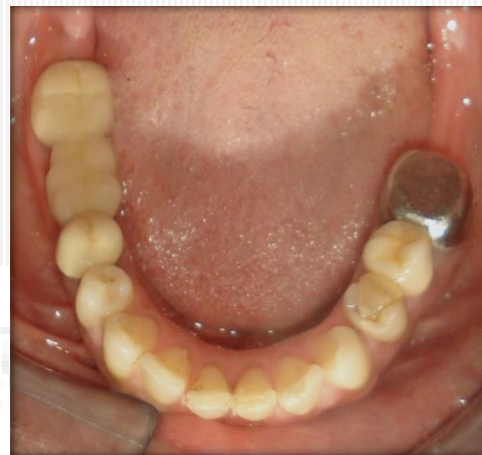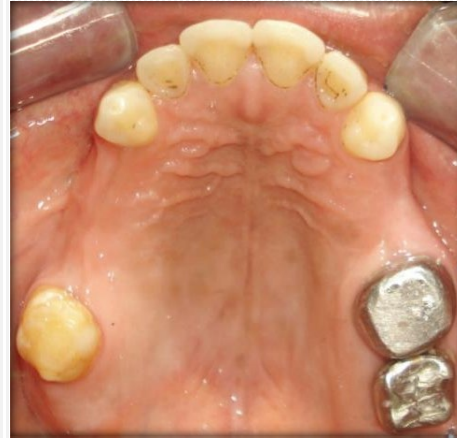The study was split mouth study design, so that implant driven for each patient through a surgical guide that was designed to have closed a surgical sleeve in one side and opened surgical sleeve in the other side. Four patients were selected to participate in this study, with total of sixteen implant four implant for each patient.

### Patient selection:

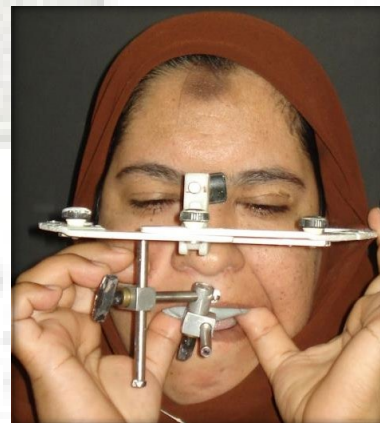Partially edentulous patients were selected to participate in this study. The patients selected upon eligibility criteria; all the patients followed Kennedy class three with one modification space. The patients' age ranged from 21-25. All the patients were medically free; buccolingual width was 7mm or more. Smokers and patients with para functional habits were excluded.

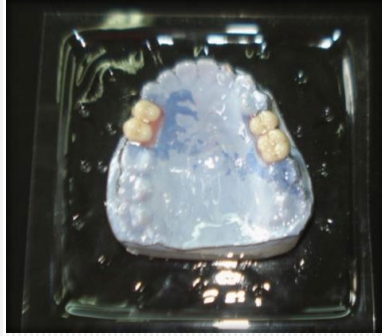### Diagnosis and clinical steps:

Primary impressions (Irreversible hydrocolloid, Cavex A37, Cavex, Netherlands) were made and poured (Zhermack Elite, Italy). Occlusion blocks were then made and mounted using maxillary earbow (BIOART, Brazil), while the lower occlusion block was mounted following centric occlusion. Teeth are waxed up to the casts at the edentulous area, then vacuum sheet 1.5 mm was used to make vacuum stent for the waxed up casts, holes had been drilled at the site of the teeth to be replaced then composite balls are applied with glue (cyanoacrylate super glue, Egypt) to be fixed to these holes.



**Intra oral occlusal view of maxillary and mandibular arch**





### Patient facebow records

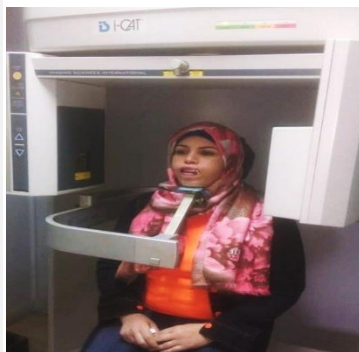Construction of vacuum formed stent with composite peds.

### Scanning of the patients and virtually planning:

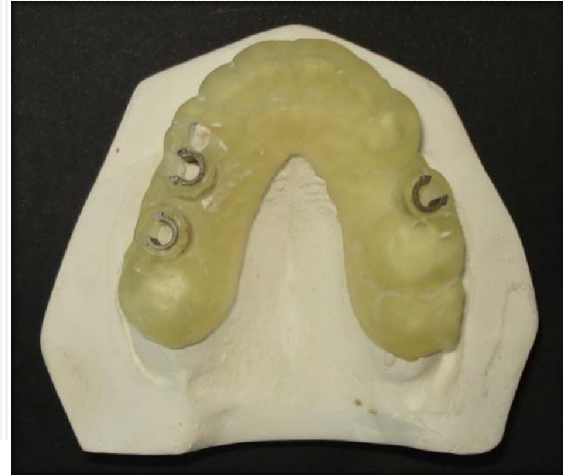CBCT (Planmeca Viso, Germany, 1-15 mA at 90-120 kVp), Scan for each patient was done while wearing the stent, the patients were instructed to bite on cotton rolls during the scan to allow separation of the both jaws. DICOM file was exported to Blue Sky software implant positioning virtually with selection of implant size, diameter, length and angulation.

Followed by designing of the sleeve design, anchor pin channels positioning in which it was designed to have three halls or channels one in anterior region in midline and two posterior one on each side at molar area.

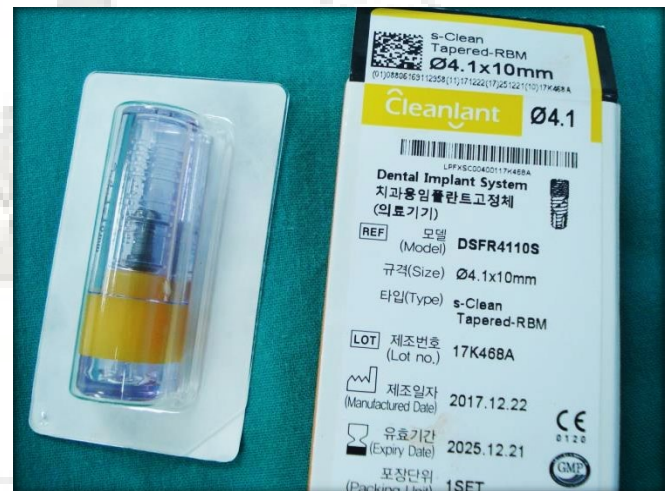After design the STL file was exported to the printing machine( Sirona 5 axis mill ,inLab MC X5, Germany).



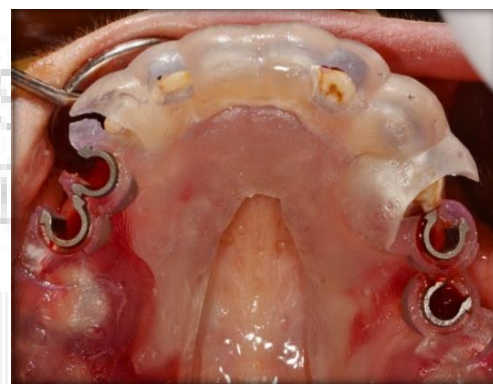CBCT for the patient

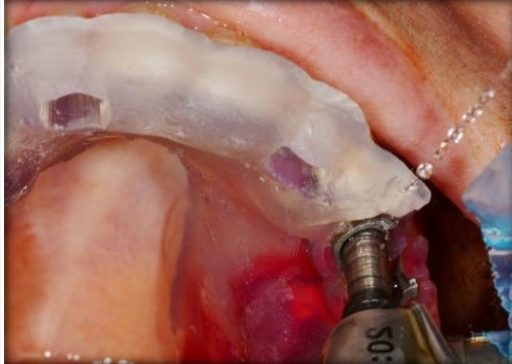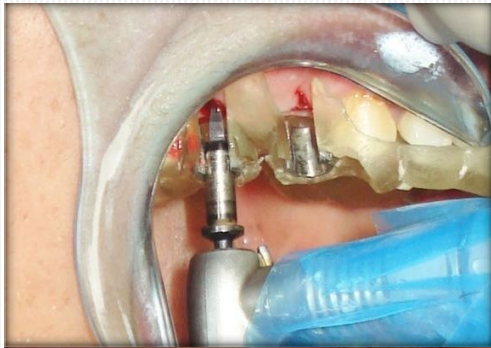


The manufactured guide with open sleeves on one side and closed sleeves on the other

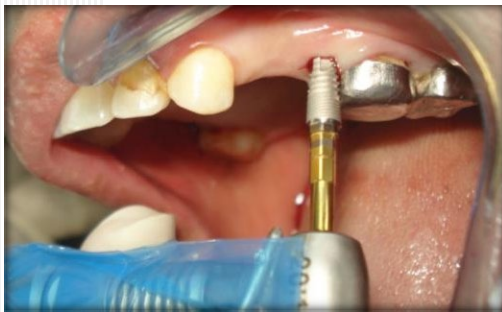

Implant used for the patients (dentium implant system)

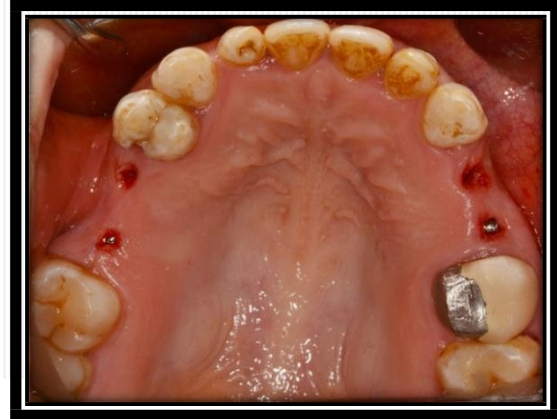



Drilling of implants via surgical guide(one side closed surgical guide and the other is closed surgical guide)



Implant placement



### Osteotomy and implant placement :

The patient had been prepared before the surgery, antibiotics had been prescribed for each one of the four patients (Clavulanic acid 1 gm and metronidazole 500 mg one tablet from each every 12 hours for 3 days one day before surgery and then 2 day after the surgery been done).

At the day of the surgery the surgical guide was checked to be passive and in place, the surgical guide was secured in place with three fixation screws ( one screw in the midline and the two other screws was placed posterior )

The osteotomy was done by drilling each implant in place by using the surgical implant drilling kit. Drilling was done by following the conventional sequence of drilling (pilot, intermediate and final drilling). During preparing of the osteotomy site for the closed surgical side a drill key or guide was used ensure the precise control over the drill direction and depth of osteotomy while for the open sleeve surgical guide the osteotomy was done without the aid of drill guide or drill key.

The open surgical sleeve side was better than the closed sleeve side during osteotomy, as it allows more for access to the coolant from the open side all the time of drilling versus the closed that the coolant is from below during the drilling and not reaching by the same enough amount.

The implants (Dentium implant system) was tightened manually and screwed in position by guided implant driver and then manually

tightening till the implant was below the surgical guide. The surgical guide was removed and manual screwing of the implant till was continued sub crest bone level.

**Post-operative:**

After one hour of the surgery each patient was immediately scanned by CBCT, DICOM file was exported to the Blue sky software the preoperative planed implant positing was super imposed with the and the actual post-operative position to measure and the degree of any apical or coronal deviation.

After 2 month of implant placement osteointegration, the implants were examined by periapical radiograph. The Second surgery stage was done, in which the the surgical guide was re-fixed in place in place then punching the mucosa over it, after then the healing collar was screwed in place for one week.

Then impression making for the implants was made by open tray impression technique. Implant supported fixed bridge was fabricated examined for fitness and passivity then screwed in place.

**Results:**

Statistical analysis was done using Real Statistics Resource Pack version 5.8 for Excel 2016. The programme is developed by Dr. and statistician Charles Zaiontz.

Two observers separately recorded the deviation of dental implants in to different sections. Inter-observer reliability was determined by interclass correlation coefficient (ICC).

Normality test was done on the mean data of observers using two different tests; Shapiro-Wilk Test, and d'Agostino-Pearson.

**T Tests:** Two Independent Samples with assumption of equal and unequal variance were done. The two tailed results were only used for more accurate outcome. The significance level was verified at  $p \leq 0.05$ . the results were considered statistically significant if p value was less than 0.05. in

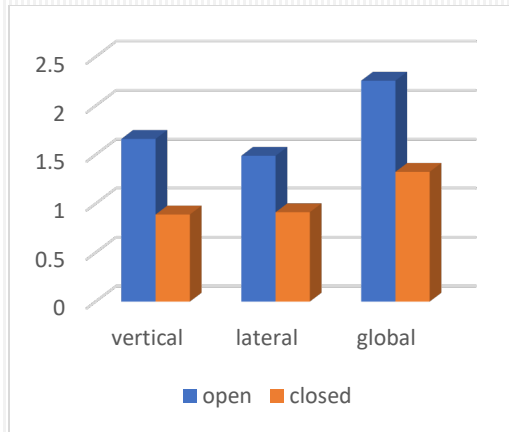
addition, 95 % confidence intervals were reported]

**mean of observers mean of open sleeves guided implant.**

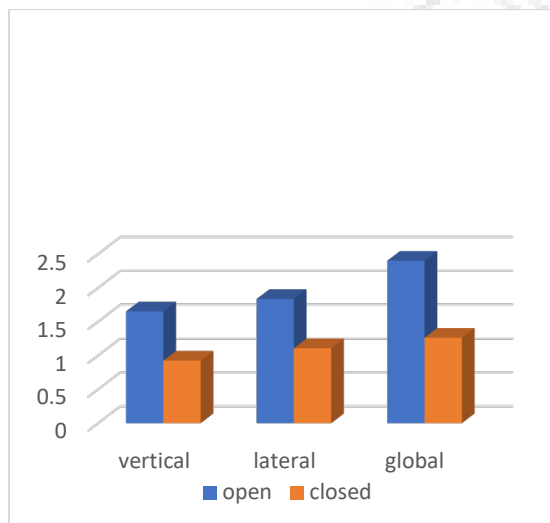
		Mean and standard deviation of implant readings from mean observers			
		mean open ring		standard deviation open ring	
		coronal	apical	coronal	apical
mesio-distal	angular	2.901428571		3.347448922	
	vertical	1.661429	1.651429	0.382042	0.679655
	lateral	1.489286	1.834286	0.958881	0.587441
	global	2.256429	2.399286	0.861335	0.923311
bucco-lingual	angular	2.477857143		1.696311826	
	vertical	1.628571	1.148571	0.831258	0.660389
	lateral	2.027857	1.489286	0.692573	0.99012
	global	2.402143	1.953571	0.822055	1.12418

**mean of observers mean on measurements of closed sleeve guided implant**

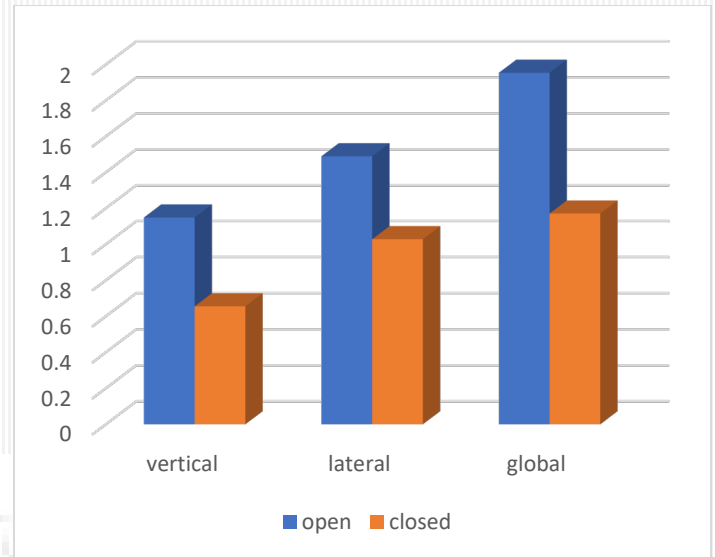
		Mean and standard deviation of implant readings from mean observers			
		mean closed ring		standard deviation closed ring	
		coronal	apical	coronal	apical
mesio-distal	angular	2.694285714		0.793963835	
	vertical	0.889286	0.925	0.458834	0.560141
	lateral	0.912857	1.107143	0.612882	0.895972
	global	1.325	1.262143	0.410934	0.813259
bucco-lingual	angular	2.012857143		1.051565726	
	vertical	0.971429	0.655	0.338941	0.509125
	lateral	1.303571	1.027857	0.916214	1.079834
	global	1.757143	1.170714	0.87935	0.995441



**mean of linear deviation at the coronal end at the mesio-distal sections**



**mean of linear deviation at the apical end at the mesio-distal sections**



**mean of linear deviation at the apical end at the bucco-lingual sections**

## Discussion

This in-vivo study was performed to evaluate split mouth technique in which computer guided surgical guide with closed sleeve in one side and open sleeve in the other side[31] [24] [32]. Diagnostic set up of artificial teeth to the ideal position was performed to improve the relation of implant position and prosthetic plane. The prosthetic information is translated to planning stage by mean of radiographic guide that show the prosthetic results prior to treatment[33] [34] [35] [36].

The radiopaque reference marker was shaped as spheres of radiopaque material such as composite resin or gutta-percha[37] [38].

Cone beam computed tomography was used as imaging modality due to that result DICOM data can be processed into interactive software (Blue Sky) to stimulate implant placement as regarding anatomical and prosthetic demands[39] [40] [41] [42].

The other benefit of CBCT is less radiation dose, no magnification and three-dimension evaluation of suspected case as

regarding it is proximity to vital structure [43] [44] [45] .

Flapless approach was used as it because less discomfort for the patients who preferred it was less postoperative complication as swelling, pain and bleeding[46] .

During preoperative and postoperative imaging by CBCT the patient would request to bite on interocclusal cotton roll to ensure separation of the two jaws from each other[47] [48].

During virtual planning of dental implant on software a safety margin of 2mm from vital structure as maxillary sinus, lingual artery and inferior alveolar canal. This 2mm safety is estimated from systematic review by Schneider et al which concluded that a mean deviation of 1.07mm at the entry point and 1.63 mm at the apex for tooth supported surgical guide [49] [50].

During planning parallelism between implant was important to gain a single prosthetic path of insertion of the future bridge.

The surgical guide was produced by rapid prototyping additive manufacturing stereolithography (SLA). Stereolithography (SLA) surgical guide improved the accuracy of implant placement as compared to conventional surgical guide and free hand implant placement[49] [50].

Oral antibiotics were taken along with antiseptic mouthwash to achieve aseptic conditions before and after the surgery to avoid any bacterial infection that may affect osseointegration.

Sufficient external irrigation was used to prevent overheating which may lead to bone necrosis that may affect osseointegration. The risk of overheating is high for flapless guided surgery, so drilling

with external irrigation in an up and down pumping motion may not lead to a significant increase the bone temperature[49] [50].

Guided implant placement through surgical guide was performed after osteotomy site preparation by surgical guide. As full guided implant site preparation and placement through surgical guide increase the accuracy. Guided implant placement was done first by hand then by ratchet wrench[50] [51].

Postoperative CBCT was done after surgery with the patient wearing the radiographic stent and biting on cotton rolls. Postoperative CBCT was done to the placed implant to compare it with the preoperative plane to detect the degree of accuracy[51] [52].

Postoperative DICOM data was imported to software to segment the postoperative implant and the radiopaque marker with it[51] [52].

Superimposition of preoperative plan with postoperative placed implants was done on BLUE sky software. This is the most common used method to detect accuracy as suspected previously by D'haese and coworkers which depend on matching of preoperative and postoperative data with the aid of radiopaque marker placed in radiographic template. This method has the ability to detect inaccuracies in coronal and apical position[51] [52].

Three clinicians were allowed to record accuracy parameter separately. Interobserver reliability then was taken to detect the degree of agreement between the observers. Shapiro-Wilk normality test was used due to its ability to analyze both parametric and non-parametric data[53] [54]



Many accuracy studies were done to test the guided implant surgeries, some authors through reviews and meta-analysis reached mean error less than 1 mm with a maximum less than 7 mm, I have found that the mean of opened sleeve template is 1.8mm and closed sleeve template 1.07mm. this clearly indicate that closed ring has slight privilege over the opened technique and this difference is statistically significant. It is worth mentioning that the mean we calculated from our study is exactly equal to the mean found by Schneider et al. 2009[53] [54] [55] [56].

However, in angular measurements our study came with the conclusion of insignificant difference as the mean difference were only 0.4 degrees.

This means that using either techniques will result in accurate drill angulation which is the prime concern in the implantation procedure.

Difference in linear measurements found in our study was found to be at the max in either apical or coronal measuring points at the vertical parameter and hence the global parameters. This might have been caused by the height of the ring not the fact that it was opened or closed.

This study was in vivo and that clearly justify our results to have slightly higher mean than studies in cadavers. Jung et al. also showed that and justified it by optimized conditions for implantation in vitro rather than in vivo[56]

## Conclusion

This study showed that there were no statistical difference in accuracy provided upon placement of the implants either with open or closed surgical guide. By taking into cautious the standardization all other factors considering gingival bio type and sleeve height.

## References:

- [1] Platzer, S., Bertha, G., Heschl, A., Wegscheider, W. A. and Lorenzoni, M. Three-Dimensional Accuracy of Guided Implant Placement: Indirect Assessment of Clinical Outcomes. *Clin. Implant Dent. Relat. Res.* 2013; 15:724-34
- [2] G. Widmann and R. J. Bale, "Accuracy in computer-aided implant surgery--a review.," *Int. J. Oral Maxillofac. Implants*, 2006 vol. 21, pp. 305–13
- [3] A. L. Rosenfeld, G. A. Mandelaris, and P. B. Tardieu, "Prosthetically directed implant placement using computer software to ensure precise placement and predictable prosthetic outcomes. Part 3: stereolithographic drilling guides that do not require bone exposure and the immediate delivery of teeth.," *Int. J. Periodontics Restorative Dent.*, 9, oct.2006 ,vol. 26, no. 5, pp. 493–9.
- [4] A. A. Iliescu, S. A. Zurac, V. Nicolae, M. G. Iliescu, and P. Perlea, "Associated lesions of peri-implant mucosa in immediate versus delayed loading of dental implants," *Rom. J. Morphol. Embryol.*, vol. 58, no. 2, pp. 487–92, 2017.
- [5] R. Zita Gomes, M. R. De Vasconcelos, I. M. Lopes Guerra, R. A. B. De Almeida, and A. C. De Campos Felino, "Implant Stability in the Posterior Maxilla: A Controlled Clinical Trial," *Biomed Res. Int.*, vol. 2017, 2017.
- [6] S. D. Ganz, "Presurgical planning with CT-derived fabrication of surgical guides," *J. Oral Maxillofac. sep 2005*; 5: pp. 59–71
- [7] A. Marco Tallarico, B. Silvio Mario Meloni, A. Luigi Canullo, E. Xhanaric, and & G. Polizzid, "Guided

- surgery for single-implant placement: A critical review : DT Science.” <https://www.dtscience.com/guided-surgery-for-single-implant-placement-a-critical-review> (accessed Jun. 10, 2018).
- [8] J. D’haese, T. Van De Velde, A. Komiyama, M. Hultin, and H. De Bruyn, “Accuracy and Complications Using Computer-Designed Stereolithographic Surgical Guides for Oral Rehabilitation by Means of Dental Implants: A Review of the Literature,” *Clin. Implant Dent. Relat. Res.*, vol. 14, no. 3, pp. 321–335, Jun. 2012.
- [9] W. J. Meer, F. S. Andriessen, D. Wismeijer, and Y. Ren, “Application of Intra-Oral Dental Scanners in the Digital Workflow of Implantology,” *PLoS One*, vol. 7, no. 8, p. 43312, 2012.
- [10] H. Israelson, J. M. Plemons, P. Watkins, and C. Sory, “Barium-coated surgical stents and computer-assisted tomography in the preoperative assessment of dental implant patients.,” *Int. J. Periodontics Restorative Dent.*, vol. 12, no. 1, pp. 52–61, 1992, Accessed: May 31, 2018.
- [11] F. Fawaz Alzoubi BDM, MA, EdD, FAGD, “Journal of Oral Implantology Surgical Guides Diplomate of the American Board of General Dentistry,” 2016.
- [12] E. M. Amet and S. D. Ganz, “Implant treatment planning using a patient acceptance prosthesis, radiographic record base, and surgical template. Part 1: Presurgical phase.,” *Implant Dent.*, vol. 6, no. 3, pp. 193–7, 1997, Accessed: May 31, 2018.
- [13] B. E. C. M. Soardi CM and N. D. Index, “Clinical and radiological 12-year follow-up of full arch maxilla prosthetic restoration supported by dental implants positioned through guide flapless surgery. *Minerva Stomatol.* 2014 2011 vol. 47, no. 3, pp. 381–390, 2011.
- [14] A. Tahmaseb, D. Wismeijer, W. Coucke, and W. Derksen, “Computer technology applications in surgical implant dentistry: a systematic review.,” *Int. J. Oral Maxillofac. Implants*, vol. 29 Suppl, no. Supplement, pp. 25–42, Jan. 2014, doi: 10.11607/jomi.2014suppl.g1.2.
- [15] Y. N. Raico Gallardo, I. R. T. da Silva-Olivio, E. Mukai, S. Morimoto, N. Sesma, and L. Cordaro, “Accuracy comparison of guided surgery for dental implants according to the tissue of support: a systematic review and meta-analysis,” *Clin. Oral Implants Res.*, vol. 28, no. 5, pp. 602–612, May 2017, doi: 10.1111/clr.12841.
- [16] M. VERCRUYSEN, R. JACOBS, N. VAN ASSCHE, and D. van STEENBERGHE, “The use of CT scan based planning for oral rehabilitation by means of implants and its transfer to the surgical field: a critical review on accuracy,” *J. Oral Rehabil.*, vol. 35, no. 6, pp. 454–474, Jun. 2008, doi: 10.1111/j.1365-2842.2007.01816.x.
- [17] H.-J. J. Nickenig, M. Wichmann, J. Hamel, K. A. Schlegel, and S. Eitner, “Evaluation of the difference in accuracy between implant placement by virtual planning data and surgical guide templates versus the conventional free-hand method – a combined in vivo – in vitro technique using cone-beam CT (Part II),” *J. Cranio-Maxillofacial Surg.*, vol. 38,

- no. 7, pp. 488–493, Oct. 2010, doi: 10.1016/j.jcms.2009.10.023.
- [18] M. S. Block and C. Chandler, “Computed Tomography–Guided Surgery: Complications Associated With Scanning, Processing, Surgery, and Prosthetics,” *J. Oral Maxillofac. Surg.*, vol. 67, no. 11, pp. 13–22, 2009, doi: 10.1016/j.joms.2009.04.082.
- [19] T. Van De Velde, A. Komiyama, M. Hultin, and H. De Bruyn, “Accuracy and Complications Using Computer-Designed Stereolithographic Surgical Guides for Oral Rehabilitation by Means of Dental Implants : A Review of the Literature,” pp. 321–335, doi: 10.1111/j.1708-8208.2010.00275.x.
- [20] S. R. Allum, “Immediately loaded full-arch provisional implant restorations using CAD/CAM and guided placement: Maxillary and mandibular case reports,” *Br. Dent. J.*, vol. 204, no. 7, pp. 377–381, 2008, doi: 10.1038/sj.bdj.2008.252.
- [21] P. Papaspyridakos, G. S. White, and K. Lal, “Flapless CAD/CAM-guided surgery for staged transition from failing dentition to complete arch implant rehabilitation: A 3-year clinical report,” *J. Prosthet. Dent.*, vol. 107, no. 3, pp. 143–150, 2012, doi: 10.1016/S0022-3913(12)00025-X.
- [22] C. H. F. Hämmerle, P. Stone, R. E. Jung, T. Kapos, and N. Brodala, “Consensus statements and recommended clinical procedures regarding computer-assisted implant dentistry.,” *Int. J. Oral Maxillofac. Implants*, vol. 24 Suppl, pp. 126–131, 2009.
- [23] A. H. Shahrabi and C. A. Hansen, “Surgical oral radiographic guide with a removable component for implant placement,” vol. 87, no. 3, pp. 330–332, 2002.
- [24] M. Kola *et al.*, “Surgical templates for dental implant positioning; current knowledge and clinical perspectives,” *Niger. J. Surg.*, vol. 21, no. 1, p. 1, 2015
- [25] C. E. 2008 Misch, “Contemporary implant dentistry.” .
- [26] C. Park, A. J. Raigrodski, J. Rosen, C. Spiekerman, and R. M. London, “Accuracy of implant placement using precision surgical guides with varying occlusogingival heights: An in vitro study,” *J. Prosthet. Dent.*, vol. 101, no. 6, pp. 372–381, 2009, Accessed: Jan. 25, 2014.
- [27] L. J. Stumpel, “Deformation of Stereolithographically Produced Surgical Guides: An Observational Case Series Report,” *Clin. Implant Dent. Relat. Res.*, vol. 14, no. 3, pp. 442–453, 2012..
- [28] M. Ramasamy, Giri, R. Raja, Subramonian, Karthik, and R. Narendrakumar, “Implant surgical guides: From the past to the present,” *J. Pharm. Bioallied Sci.*, vol. 5, no. 5, p. 98, Jun. 2013.
- [29] D. P. Sarment, P. Sukovic, and N. Clinthorne, “Accuracy of implant placement with a stereolithographic surgical guide.,” *Int. J. Oral Maxillofac. Implants*, vol. 18, no. 4, pp. 571–7, Accessed: Jun. 01, 2018.
- [30] Tallarico M, Kim YJ, Cocchi F, Martinolli M, Meloni SM. Accuracy of newly developed sleeve-designed templates for insertion of dental implants: A prospective multicenters clinical trial. *Clin Implant Dent Relat Res.* 2019 Feb;21(1):108-113
- [31] E. Barnea, I. Alt, R. Kolerman, and J. Nissan, “Accuracy of a laboratory-

- based computer implant guiding system,” *Oral Surgery, Oral Med. Oral Pathol. Oral Radiol. Endodontology*, vol. 109, no. 5, pp. e6–e10, May 2010.
- [32] K. M. D’Souza and M. A. Aras, “Types of Implant Surgical Guides in Dentistry: A Review,” *J. Oral Implantol.*, vol. 38, no. 5, pp. 643–652, Oct. 2012.
- [33] M. J. Engelman, J. A. Sorensen, and P. Moy, “Optimum placement of osseointegrated implants,” *J. Prosthet. Dent.*, vol. 59, no. 4, pp. 467–73, Apr. 1988.
- [34] D. M. Almog, E. Torrado, and S. W. Meitner, “Fabrication of imaging and surgical guides for dental implants,” *J. Prosthet. Dent.*, vol. 85, no. 5, pp. 504–508, 2001.
- [35] L. J. Stumpel, “Cast-based guided implant placement: A novel technique,” *J. Prosthet. Dent.*, vol. 100, no. 1, pp. 61–69, 2008.
- [36] C. M. Becker and D. A. Kaiser, “Surgical guide for dental implant placement,” *J. Prosthet. Dent.*, vol. 83, no. 2, pp. 248–51, Feb. 2000.
- [37] N. K. Arfai and S. Kiat-amnuay, “Radiographic and surgical guide for placement of multiple implants,” *J. Prosthet. Dent.*, vol. 97, no. 5, pp. 310–312, May 2007..
- [38] M. Z. Kola *et al.*, “Review Article Surgical Templates for Dental Implant Positioning ; Current Knowledge and Clinical Perspectives,” vol. 21, no. 1, pp. 1–5, 2015..
- [39] N. Sykaras and R. D. Woody, “Conversion of an implant radiographic template into a surgical template,” *J. Prosthodont.*, vol. 10, no. 2, pp. 108–112, 2001.
- [40] S. S. Atsu, “A surgical guide for dental implant placement in edentulous posterior regions.,” *J. Prosthet. Dent.*, vol. 96, no. 2, pp. 129–33, Aug. 2006.
- [41] C. Wulfman, A. Hadida, and C. Rignon-Bret, “Radiographic and surgical guide fabrication for implant-retained mandibular overdenture.,” *J. Prosthet. Dent.*, vol. 103, no. 1, pp. 53–57, Jan. 2010.
- [42] F. Tsuchida, T. Hosoi, M. Imanaka, and K. Kobayashi, “A technique for making a diagnostic and surgical template.,” *J. Prosthet. Dent.*, vol. 91, no. 4, pp. 395–7, Apr. 2004..
- [43] S. Nelogi, B. S. Rao, H. C. Naveen, A. Porwal, and M. Nelogi, “A Surgical Guide for Optimal Placement and Immediate Restoration of Implant,” *J. Oral Implantol.*, vol. 40, no. 5, pp. 623–626, 2014..
- [44] K. Marcelis, M. Vercruyssen, I. Naert, W. Teughels, and M. Quirynen, “Model-based guided implant insertion for solitary tooth replacement: A pilot study,” *Clin. Oral Implants Res.*, vol. 23, no. 8, pp. 999–1003, 2012.
- [45] K. C. Kopp, A. H. Koslow, and O. S. Abdo, “Predictable implant placement with a diagnostic/surgical template and advanced radiographic imaging.,” *J. Prosthet. Dent.*, vol. 89, no. 6, pp. 611–5, Jun. 2003..
- [46] C. A. M. M. Volpato, D. K. Vasconcellos, L. G. D. Garbelotto, R. Manfro, and M. Özcan, “A modified surgical template with dual function.,” *J. Prosthet. Dent.*, vol. 110, no. 3, pp. 232–233, Sep. 2013..
- [47] L. J. Stumpel, “An adjustable, cast based, fully restrictive surgical guide.,” *J. Prosthet. Dent.*, vol. 113, no. 5, pp. 366–70, May 2015..
- [48] D. Schneider, P. Marquardt, M. Zwahlen, and R. E. Jung, “A systematic review on the accuracy

- and the clinical outcome of computer-guided template-based implant dentistry,” *Clin. Oral Implants Res.*, vol. 20, no. SUPPL. 4, pp. 73–86, Sep. 2009.
- [49] A. Komiyama and M. Hultin, “Treatment outcome of immediately loaded implants installed in edentulous jaws following computer-assisted virtual treatment planning and flapless surgery,” pp. 677–685, 2008.
- [50] J. Neugebauer *et al.*, “Computer-aided manufacturing technologies for guided implant placement,” *Expert Rev. Med. Devices*, vol. 7, no. 1, pp. 113–129, Jan. 2010.
- [51] V. Nery, C. G. Schwalm Lacroix, R. Miranda, and M. G. de Oliveir, “Virtual Planning for Dental Implant Placement Using Guided Surgery,” *Implant Dent. - Most Promis. Discip. Dent.*, 2011.
- [52] M. Abboud *et al.*, “Application and success of two stereolithographic surgical guide systems for implant placement with immediate loading,” *Int. J. Oral Maxillofac. Implants*, vol. 27, no. 3, pp. 634–643, 2012.
- [53] Vercruyssen M, Jacobs R, Van Assche N, van Steenberghe D. The use of CT scan based planning for oral rehabilitation by means of implants and its transfer to the surgical field: a critical review on accuracy. *J Oral Rehabil* 2008; **35**: 454-474.
- [54]. Marcelis K, Vercruyssen M, Naert I, Teughels W, Quirynen M. Model-based guided implant insertion for solitary tooth replacement: a pilot study. *Clin Oral Implants Res* 2012; **23**: 999-1003.
- [55]. Vercruyssen M, Cox C, Coucke W, Naert I, Jacobs R, Quirynen M. A randomized clinical trial comparing guided implant surgery (bone- or mucosa-supported) with mental navigation or the use of a pilot-drill template. *J Clin Periodontol* 2014; **41**: 717-723.
- [56]. Jung RE, Schneider D, Ganeles J, Wismeijer D, Zwahlen M, Hämmerle C, Tahmaseb A. Computer technology applications in surgical implant dentistry: a systematic review. *Int J Oral Maxillofac Implants* 2009; **24**: 92-109.