

**Effect of Submucosal Injection of Sodium 2- Mercaptoethanesulfonate in Surgical Treatment of Deviated Nasal Septum**

**Ahmad Gaber Abdelraheem<sup>a</sup>, Manar Mahran Sadek<sup>a\*</sup>, Nehad Hassan Abdelrahman<sup>a</sup>, Aida A. Abdelmaksoud<sup>a</sup>**

<sup>a</sup> Otorhinolaryngology Department, Faculty of Medicine, South Valley University, Qena, Egypt

**Abstract**

**Background:** Mucoperichondrial flap elevation is the first step in septoplasty operation. MESNA was used in flap elevation to decrease the amount of bleeding, get better surgical field, decrease the operation time and lessen mucosal damage.

**Objectives:** To evaluate the effect of submucosal injection of sodium 2-mercaptoethanesulfonate (MESNA) on the operation time, intra-operative blood loss, integrity of the flap in septoplasty and post operative pain.

**Patients and methods:** It is a case control study that was conducted on 60 patients their ages ranged from 18 years to 43 years, all were underwent septoplasty operation by the same surgeon at Otorhinolaryngology Department, Qena University hospitals, Egypt.

**Results:** Results revealed that the mean time of flap elevation was  $6.7 \pm 1.8$  SD minutes in group A, but was  $10.9 \pm 2.2$  SD minutes in group B which was highly statistical significant with p-value  $< 0.001$ . As regard the mean of Intra-operative blood loss it was  $82 \pm 15.9$  SD ml. in group A, but was  $109.7 \pm 21.8$  SD ml. in group B which was highly statistical significant with p-value  $< 0.001$ .

**Conclusion:** Submucosal injection of sodium 2- mercaptoethanesulfonate (MESNA) being more advantageous method that make mucoperichondrial flap elevation is convenient and effective and preserving mucosal integrity in surgical treatment of deviated nasal septum .

**Keywords:** Mucoperichondrial flap; sodium2-mercaptoethanesulfonate; Septoplasty, , Deviated nasal septum.

**DOI:** 10.21608/svuijm.2022.124787.1288

**\*Correspondence:** [nourelhady97@gmail.com](mailto:nourelhady97@gmail.com)

**Received:** 4 March, 2022.

**Revised:** 6 March, 2022.

**Accepted:** 22 March, 2022.

**Cite this article as:** Ahmad Gaber Abdelraheem, Manar Mahran Sadek, Nehad Hassan Abdelrahman, Aida A. Abdelmaksoud. (2022). Effect of Submucosal Injection of Sodium 2- Mercaptoethanesulfonate in Surgical Treatment of Deviated Nasal Septum. *SVU-International Journal of Medical Sciences*. Vol.5, Issue 2, pp: 105-114

**Copyright:** © Abdelraheem et al. (2022) Immediate open access to its content on the principle that making research freely available to the public supports a greater global exchange of knowledge. Users have the right to Read, download, copy, distribute, print or share link to the full texts under a [Creative Commons BY-NC-SA 4.0 International License](https://creativecommons.org/licenses/by-nc-sa/4.0/).

## Introduction

Deviated nasal septum (DNS) is considered one of the most common diseases in otorhinolaryngology clinics, causing nasal obstruction which may affect the quality of life due to its rhinologic symptoms (Lee et al., 2021). Septoplasty is one of the common practiced ENT operations which is done to straighten the deviated nasal septum (Baumann and Baumann, 2007). The aim of septoplasty should achieve successful functional results with an easier mucoperichondrial flap elevation, wider, less bloody field, faster operation time and less mucosal damage (Ozturan et al., 2014).

Sodium 2-sulfanylethanesulfonate [C<sub>2</sub>H<sub>5</sub>NaO<sub>3</sub>S<sub>2</sub>] (MESNA) is a thiol compound that dissolves covalent disulfide bonds located between polypeptide chains so, it softens the connective tissue fibers between anatomical planes so it is an effective chemical softener of connective tissue (Sumiyama et al., 2008). Clinical studies were demonstrated that locally injected MESNA has loosened the connective tissue fibers in the submucosa and made the blunt surgical dissection easier, shortened the operation time, and reduced the bleeding risk by its mucolytic effect so it can facilitate mucoperichondrial flap elevation (Benassi et al., 2000 ; Denaro et al., 2008), so bleeding and mucoperichondrial perforation are minimal, the rate of complications decreases and surgical success increases (Aksoy et al., 2012).

## Patients and methods

It is a case control study that was performed at Otorhinolaryngology Department, Qena University Hospital, South Valley University, Egypt. During the period from September

2020 to December 2021 conducted on 60 patients (22 were males and 38 were females) their ages ranged from 18 years to 43 years with mean age was 25.6±7.8 SD all were underwent septoplasty operation by the same surgeon, anesthetist and the same hypotensive technique.

They were divided into two groups. Group A the studied group (30 patients) they were underwent septoplasty with submucosal MESNA injection and group B the control group (30 patients) who were underwent septoplasty with submucosal saline injection. The study was approved by the institutional Review Board of Qena faculty of Medicine-South Valley University, the Ethical approval code is SVU-MED-ENT030-1-20-9-77. Informed written consent from patients was obtained for cases and controls participate in the study after explaining the objectives and steps of the research.

### *Inclusion criteria*

- Adult age  $\geq$ 18 years old.
- Patients with deviated nasal septum causing symptoms of nasal obstruction, headache and epistaxis.
- Patients with symptoms of recurrent otitis media and recurrent rhinosinusitis.
- No septal perforation.
- No previous septoplasty.

### **Exclusion criteria:**

- Pediatric age <18 years.
- Septal perforation.
- Unfit for surgery.

- Refuse surgery.
- Previous septoplasty.
- Patients on anticoagulants therapy.
- Hypertensive patients.

**Clinical assessment of these patients included:**

**1- Physical examination.**

- General examination.
- Otorhinolaryngology examination.

**2- Investigation:**

- Pre-operative multislice CT nose and paranasal sinuses coronal, axial and sagittal cuts.
- Routine pre-operative investigations CBC, coagulation profile and random blood glucose.

**Steps**

In caudal part of the septum on both sides injection of submucosal 5 ml. of 10% (100 mg/mL) (MESNA) was done for group A until blanching of the flap and injection of submucosal 5 ml. saline for group B. Near mucocutaneous junction, a vertical incision performed to one side with scalpel number.15,. With freer elevator, elevation of mucoperichondrial flap then the elevation of mucoperiosteal flap. The Same procedure was repeated for the other side of septum until Septal osteocartilaginous structures were completely separated from mucosa .For both groups, time of septal incision and elevation of the flap were recorded by a timer .After bilateral subperichondrial and subperiosteal flap elevation were finished, timer was stopped and time was measured. Then mucosal flap

integrity was reviewed and mucosal damage status was recorded. Mucosal flap tears was recorded as the full-thickness defect formed at any surface of the mucosal flap on both sides.

**Assessment Parameters**

To compare between submucosal MESNA injection in group A and submucosal saline injection in group B .Operative and postoperative parameters were assessed.

Operative data included elevation time, and estimated intra- operative blood loss. Postoperative data included post operative pain, mucosal flap integrity.

**Operative Assessment Data**

Two operative values were used in assessment of the procedure. These included mucoperichondrial flap elevation time, and estimated intra-operative blood loss.

- 1. Elevation time:** Time calculation started from performing septal incision till bilateral subperichondrial and subperiosteal flap elevation were finished.
- 2. Estimated blood loss:** Intra-operative bleeding was recorded by measuring the amount of blood in milliliters collected in the suction container. The amount of blood included was calculated by subtracting the amount of saline used for irrigation from the total collected fluid volume.

**Post operative Assessment Data**

Two post operative values were used in assessment of the procedure. These included post operative pain, and mucosal flap integrity.

**1. Post operative pain:**

Assessed by the visual analogue scale (VAS). A score of 1 means “no pain”, while a score of 10 is “maximal pain”. Post operative pain was recorded on 48hours (after removal of nasal packing) and on the seventh post operative day (Portenoy and Tanner,2003).

**2. Mucosal integrity:**

This was assessed during the follow up visit on 48 hours and on the seventh post operative day. Mucosal integrity was reviewed and mucosal damage status was recorded.

**Statistical Analysis**

Statistical Program for Social Science (SPSS) version 20 was used in analysis of data. Mean ± standard deviation (SD) will be used for

expression of Quantitative data. Independent-samples t-test of significance used in comparing between two means and chi-square test used in comparing between non-parametric data. Also Regression analysis was used .Probability (p-value) considered significant if < 0.05.

**Results**

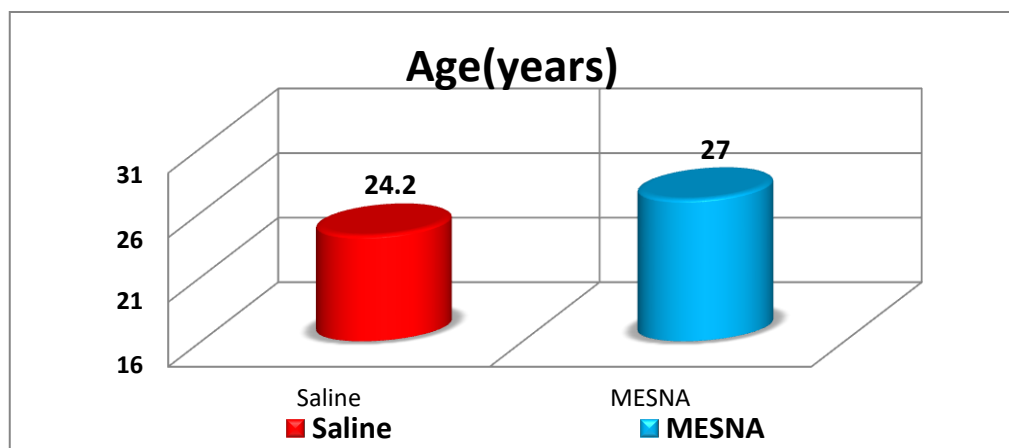
Comparative analysis between group A and group B as regard age and sex , The mean age was 27±8.9 SD years in group A and was 24.2±6.3 SD years in group B ,and this was statistically insignificant (p-value = 0.162).As regard the sex, male to female ratio was 14/16 in group A and was 8/22 in group B. This association was statistically insignificant (p-value =0.108) as shown in [Table.1 and Fig.1 & 2 ].

**Table1. Age and sex distribution between the two groups**

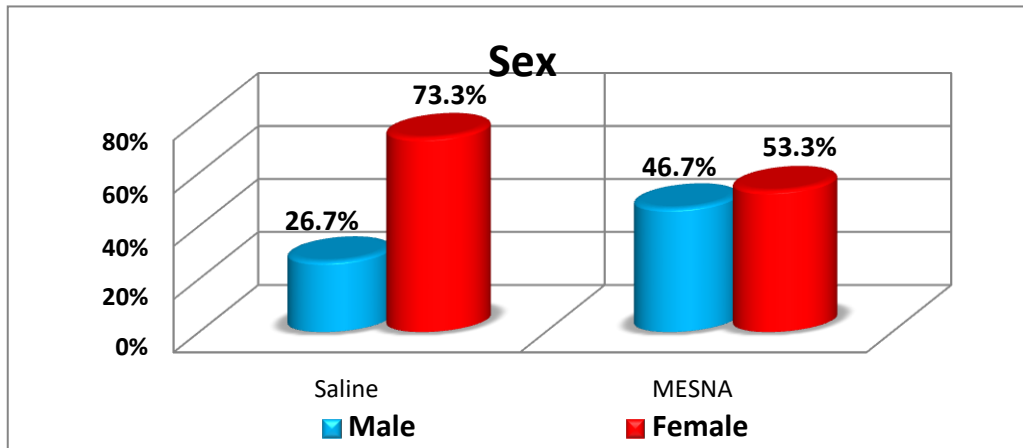
Variables		Submucosal MESNA Injection (30 cases) Group A	Submucosal Saline Injection (30 cases) Group B	P value
Age		27± 8.9SD	24.2 ±6. 3SD	.162
Sex	Males	14(46.7%)	8(26.7%)	.108
	Females	16(53.3%)	22(73.3%)	

\*Independent t-test was used to compare the mean difference between groups

\*\*Chi-square test was used to compare proportions between groups



**Fig.1. Comparison between the two groups as regard age.**



**Fig.2. Comparison between the two groups as regard sex.**

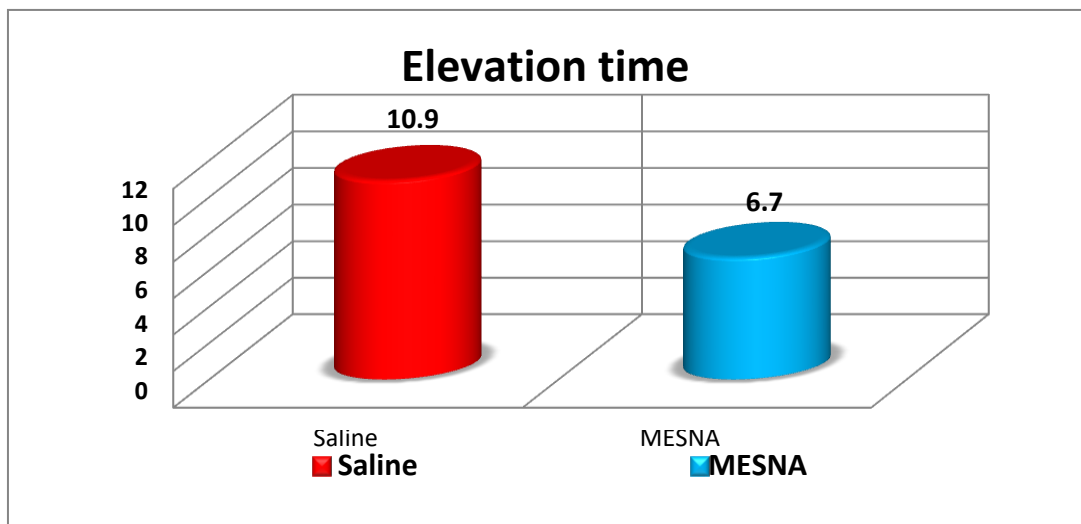
As regard the mean flap elevation time, it was 6.7±1.8 SD minutes in group A, and was 10.9±2.2 SD minutes in group B, with statistical significance relationship  $p < 0.001$ . As regard the mean of Intra-operative

blood loss, it was 82 ±15.9 SD ml. in group A, and was 109.7 ± 21.8 SD ml. in group B, with statistical significance relationship  $P < 0.001$  as shown in [Table.2 and Fig.3 & 4 ].

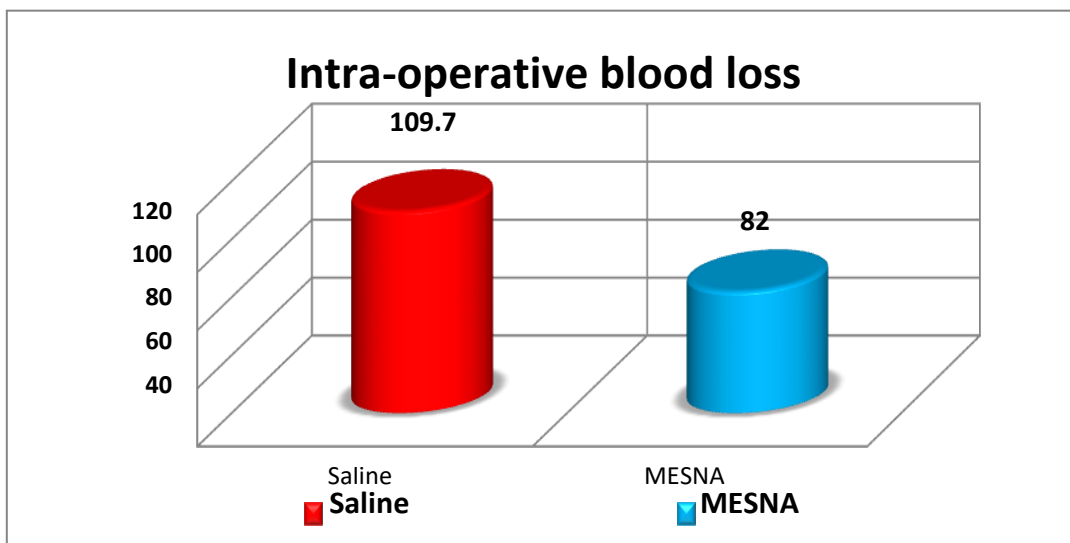
**Table 2. Data about the flap elevation time and intra-operative blood loss:**

VARIABLE	Submucosal MESNA Injection(30cases)	Submucosal Saline Injection(30cases)	P value
Flap elevation time	6.7 ± 1.8SD	10.9 ± 2.2SD	<0.001
Intra-operative blood loss	82 ±15.9SD	109.7 ±21.8SD	<0.001

\*Independent t-test test was used to compare the mean difference between groups.



**Fig.3. Comparison between the two groups as regard elevation time.**



**Fig.4. Comparison between the two groups as regard intra-operative blood loss.**

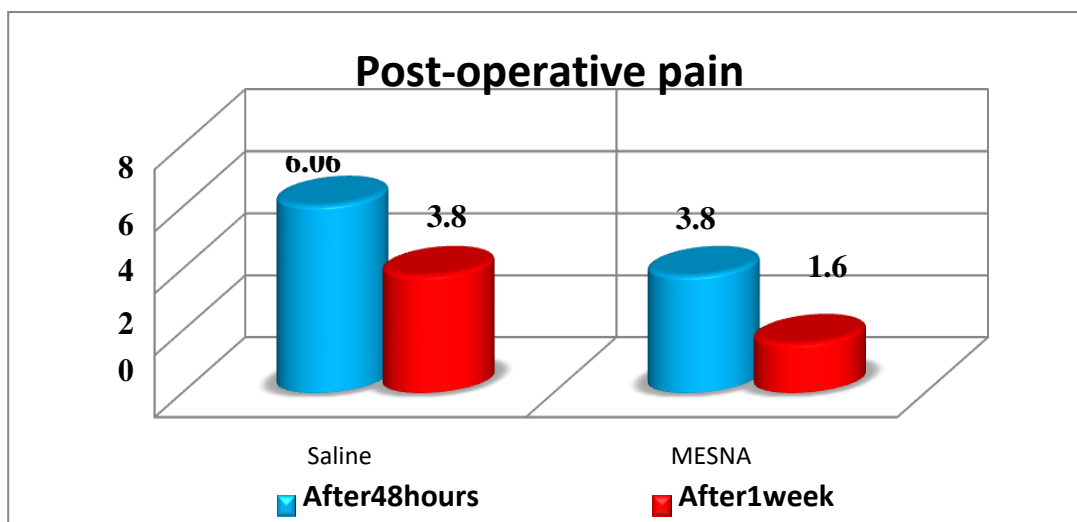
As regard post operative pain according to visual analogue scale: After 48 hour it was  $3.8 \pm 0.8$  SD in group A versus  $6.06 \pm 0.7$  SD in group B with  $p$ -value $<0.001$  which was highly significant.

After one week it was  $1.6 \pm 0.7$  SD in group A versus  $3.8 \pm 0.7$  SD in group B with  $p$ -value  $< 0.001$  which was highly significant as shown in [Table.3 and Fig.5 ].

**Table 3. Post operative pain**

Postoperative pain	Submucosal MESNA Injection(30cases)	Submucosal Saline Injection(30cases)	P value
After 48 hours (after pack removal)	$3.8 \pm 0.8$ SD	$6.06 \pm 0.7$ SD	$<0.001$
After 1 week	$1.6 \pm 0.7$ SD	$3.8 \pm 0.7$ SD	$<0.001$

\*Independent t-test was used to compare the mean difference between groups.



**Fig.5. Comparison between the two groups as regard post operative pain.**

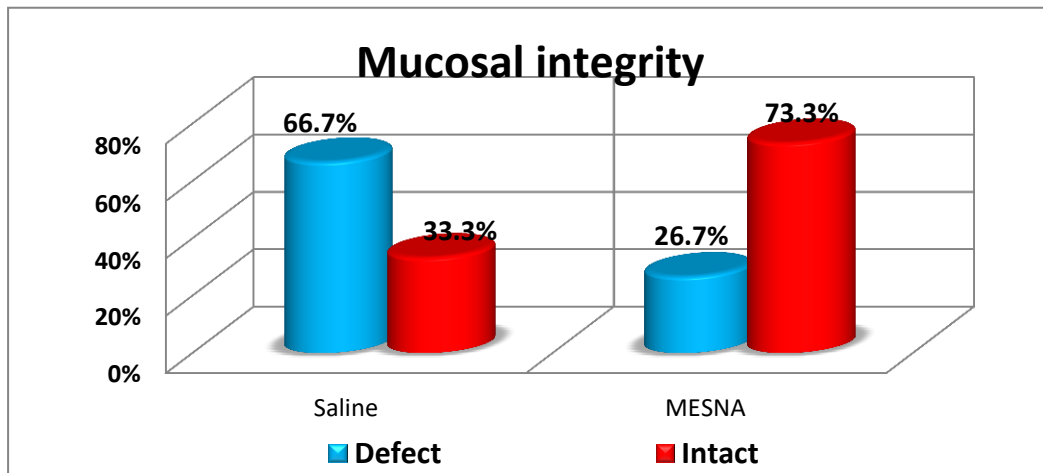
As regard mucosal integrity : in group A only 8 patients (26.7%) with defect in the mucosal flap while intact mucosal flap in 22 patients (73.3%),while in group B 20 patients (66.7%)

show mucosal flap defect and intact mucosal flap were found in 10 patients(33.3%) with p-value<0.01 which was statistically significant as shown in [Table.4 and Fig.6 ].

**Table 4 . Mucosal integrity**

Mucosal integrity	Submucosal MESNA Injection(30cases)	Submucosal Saline Injection(30cases)	P value
Mucosal flap defect	8(26.7%)	20(66.7%)	<0.001
No mucosal flap defect	22(73.3%)	10(33.3%)	<0.001

\*\*Chi-square test was used to compare proportions between groups.



**Fig.6. Comparison between the two groups as regard mucosal integrity.**

**Discussion**

One of the common complaints in otorhinolaryngology is nasal obstruction. Diagnosis of nasal obstruction includes physical examination of the septum and the other nasal anatomical subunits (Clark et al., 2018). Most common anatomical cause of nasal obstruction is a deviated nasal septum (Cantone et al., 2018).Septoplasty is performed to widen nasal passages and improve nasal air flow by providing reconstruction of the deviated parts after mucoperichondrial flap elevation (Toriumi DM 2005).

Intra-operative and post operative bleeding are important due to high vascularization of the nose. Surgeons give importance to a vascular dissection by

keeping dissection in submucoperichondrial and subperiosteal planes (Dobratz and park, 2009). MESNA is defined as a chemical dissector by solving disulfide bonds in the connective tissue particularly in the field of surgery (Benassi et al.,2000 ; Ajmal et al.,2003).

Continuous trials in septal surgery seems to support that MESNA is very useful in locating the cleavage plane, especially in cases of severe osteocartilagenous septal deviation ( Casale et al.,2010).As regard the demographic of data of the two groups we founded that, in group A the mean age was 27 ± 9.1 SD years with 14males (46.7%) and 16 females (53.3%)and in group B, the mean age was 24.2 ± 6.3 SD years with 8 males (26.7%) and 22 females

(73.3%) with no statistical significant difference regarding age and sex. These results were similar to **Eren et al (2017)** in their study where 56 patients were enrolled in the study and underwent septoplasty operation; 24 patients with submucosal MESNA injection in the studied group and 32 patients with submucosal saline injection in the control group.

The mean age of patients was  $36.3 \pm 10.8$  SD years and  $33.4 \pm 9.9$  SD years, respectively, and gender distribution was 12 males (50%) and 12 females (50%) in the studied group and 19 males (59.37%) and 13 females (40.62%) in the control group.

Our results showed that the flap elevation time in group A was  $6.7 \pm 1.8$  SD minutes and was  $10.9 \pm 2.3$  SD minutes in group B with highly statistical significant difference between the two groups. These results were in agreement with **Çınar et al. (2021)** in their study who stated that the recorded operation time of mucosal elevation was significantly higher in the saline group compared with the MESNA group. Also, we agree with **Eren et al. (2017)** in their study who stated that submucosal injection of MESNA has significantly reduced the duration of flap elevation time compared with submucosal saline injection.

In current study we founded that a high statistical significant difference in intra-operative blood loss between group A and group B, it was  $82 \pm 16.2$  SD ml. in group A compared with  $109.7 \pm 22.2$  SD ml. in group B. These results were consistent with the results of a study performed by **Çınar et al. (2021)** in their study who stated that the amount of bleeding was significantly higher in the saline group

compared to the MESNA group. According to the mucosal integrity, Group A showed that only 8 patients (26.7%) with mucosal defect versus 20 patients (66.7%) in Group B with statistically significant difference. Mucosal defect occur in group A because the cause of septal deviation in some patients is post traumatic.

Our results in agreement with **Eren et al (2017)** in their study who stated that submucosal MESNA injection has significantly reduced mucosal defect compared to submucosal saline injection. But our results disagree with **Çınar et al (2021)** in their study who stated that the injection of MESNA was not superior to normal saline in terms of mucosal defect. This may be due to they were used adrenaline in their study and stated that it is superior to both saline and MESNA due to low cost and wide spread use.

In our study, In group A the pain after 48 hour was  $3.8 \pm 0.8$  which decreased to  $1.6 \pm 0.7$  after one week with highly statistical significant and in group B it was  $6.06 \pm 0.7$  after 48 hour which decreased to  $3.8 \pm 0.7$  after one week which was highly statistical significant difference and these results showed that using MESNA is better than normal saline in nasal septal surgery.

### Conclusion

Submucosal injection of sodium 2-mercaptoethanesulfonate (MESNA) being more advantageous method that make mucoperichondrial flap elevation is convenient and effective and preserving mucosal integrity in surgical treatment of deviated nasal septum.



## References

- **Ajmal N, Riordan CL, Cardwell N, Brace SR, Nanney LB (2003).** Chemically assisted capsulectomy in the rabbit model: a new approach *Plast Reconstr Surg* ,112:1449-1454.
- **Aksoy F, Yildirim YS, Demirhan H, Oztaran O, Solakoglu S (2012).** Structural characteristics of septal cartilage and mucoperichondrium. *J LaryngolOtol*,126:38–42.
- **Baumann I, Baumann H (2007).** Anew classification of septal deviations. *Rhinology* , 45(3):220–223.
- **Benassi L, Lopopolo G, Pazzoni F, Piazza F, Ricci L, Kaihura C (2000).** Chemically assisted dissection of tissues: an interesting support in abdominal myomectomy. *J Am CollSurg*,191:65–69.
- **Cantone E, Ricciardiello F, Oliva F,Iengo M, Decorso E(2018).** Septoplasty: is it possible to identify potential “predictors” of surgical success? *Acta Otorhinolaryngo Ital*,38:528-35.
- **Casale M, Di Martino A, Salvinelli F, Trombetta M, Denaro V(2010).** MESNA for chemically assisted tissue dissection. *Expert Opinion on Investigational Drugs*, 19(6), 699–707.
- **Çınar Z, Yiğit Ö, Savran Turanoğlu F, Baykal Koca S(2021).**A clinical and histopathological comparison of saline, adrenaline and 2-mercaptoethanesulfonate (MESNA) in mucoperichondrial elevation: which is superior?. *Acta Otorhinolaryngol Ital.*, 41 (1):51-58.
- **Clark DW, Del Signore AG, Raithatha R, Senior BA (2018).** Nasal airway obstruction: Prevalence and anatomic contributors . *Ear Nose Throat J*.Jun, 97 (6):173-176.
- **Denaro V, Di Martino A, Longo UG, Costa V, Papalia R, Forriol F, et al.(2008).**Effectiveness of a mucolythic agent as a local adjuvant in revision lumbar spine surgery *Eur Spine J*,17:1752 – 1756.
- **Dobratz EJ, Park SS (2009).** Septoplasty pearls. *Otolaryngol Clin NorthAm*,42:527–537.

- **Eren SB, Yenigun A, Tugrul S, Goktas SS, Dogan R, Calim OF, et al (2017).**Effect of submucosal mesna application on mucoperichondrial elevation in septoplasty. *J Cranio fac Surg*, 28:e94-6.
- **Lee KI, In SM, Kim JY, Hong JY, Han KD, Kim JS, et al. (2021).**Association of nasal septal deviation with the incidence of anxiety, depression, and migraine: A national population-based study. *PLoS ONE* 16(11).
- **Ozturan O, Dogan R, Aksoy F, Tugrul S, Eren SB (2014).** Dorsal approach to septum in external septorhinoplasty .*Ann OtolRhinolLaryngol*,123:623–628.
- **RK Portenoy & RM Tanner (2003).** Visual Analog Scale and Verbal Pain Intensity Scale. Copyright by Oxford University Press.
- **Sumiyama K, Gostout CJ, Rajan E, Bakken TA, Knipschild MA (2008).** Chemically assisted endoscopic mechanical submucosal dissection by using mesna. *Gastrointest Endosc*, 67:534–538.
- **Toriumi DM (2005).** Structure approach in rhinoplasty. *Facial Plast Surg Clin North Am*, 13:93–113