



FACULTY OF AGRICULTURE

Minia J. of Agric. Res. & Develop.
Vol. (39), No. 2, pp. 245-254, 2019

SOME BIOLOGICAL PROPERTIES OF WHEY PROTEINS

Gehan K. Abd-Kreem ; Manal I. Abd-Elghany**;
Karima A. H. Saleh* and Ahmed S. Zahran**

* Dairy Science Dept., Faculty of Agric., Minia Univ., Minia
EGYPT.

** Dept. of Pathology, Faculty of Medicine, Minia Univ., Minia
EGYPT.

Received: 1 August (2019)

Accepted: 19 August (2019)

ABSTRACT

The biological activities of whey proteins on rats treated with 5-fluorouracil were investigated. Histopathological examination of the liver tissue sections obtained from animals that were treated with 5-fluorouracil following administration of whey proteins, showed marked improvement, with mild congested central veins and mild cloudy. Concurrent treatment with 5-fluorouracil and whey proteins caused significant ameliorative changes, where hepatic tissue sections displayed almost normal histology with only mild congestion and dilated central veins. Pronounced improvement in renal tissue was observed in obtained tissue sections from animals treated with 5-fluorouracil following administration of whey protein. No significant alterations were noticed between all treated groups in urea and creatinine concentrations. Whey proteins had no effects on serum iron concentration.

INTRODUCTION

Whey is the fluid by-product resulting from the precipitation of proteins in milk. Its composition is ~94% water (6% total solids), 4.5% lactose, 8% protein, .7% minerals. The most common protein levels in whey protein concentrates (WPC) are 35% to 80% and in whey protein isolate 90%. More than 90% of

protein in whey could be achieved by carrying out some purification steps (Kilara and Vaghela., 2018).

Whey proteins (WP) act as an antioxidant and detoxifies, due to their participation in the synthesis of glutathione (GSH) which is an intracellular antioxidant. Whey is rich in cysteine which is combined with glutamate and glycine to form

glutathione containing thiol (Sulfhydryl) group serves, as an active reducing agent in preventing oxidation and tissue damage. Carried out by direct conjugation, it detoxifies endogenous and exogenous toxins, including toxic metals, petroleum distillates, lipid peroxides, bilirubin and prostaglandins. Riboflavin, niacinamide and glutathione reductase are essential cofactors in the reduction of glutathione (Tomovska et al., 2016).

Whey protein is an alternative oral nutrition supplement that is suitable for cancer patients due to its lactose- and fat free composition, high quality of protein with excellent amino acid profiles, and high digestability (Ha and Zemel al., 2003).

It has also Zinc (Zn) and selenium (Se), these elements are key nutrients related to cell membrane protection. Zn is a cofactor of glutathione peroxidase and superoxide dismutase enzymes, both of which have the ability to scavenge free radicals and eliminate oxidants, such as hydrogen peroxide (Bumrungpert et al., 2018).

The objective of the present study was to:

1. determine the effect of oral supplementation of whey protein on the nutritional status, glutathione (GSH) levels, immunity, inflammatory status in cancer rats who are undergoing chemotherapy by 5-fluorouracil.
2. To study biochemical, histological and ultra-structural alteration in

the liver and the kidney of the treated rats with 5-fluorouracil.

MATERIALS AND METHODS

1- Whey proteins:

Cow whey protein powder was obtained from the department of dairy science faculty of agriculture Alexandria University.

2-Re constitution of whey proteins

Whey proteins were dissolved in distilled water and freshly prepared before oral administration 0.5g/kg of rat.

3- preparation of 5- fluorouracil

5-fluorouracil (Biosynth Company): was supplied in the form of ampoules of 250 mg and intraperitoneally injected at 100 mg/kg of rat.

4-Experimental conditions

Male Wistar rats aged 8–12 weeks, each weighting 120–180 g, were obtained from the Organization of Biological Products and Vaccines (Helwan Farm, Cairo, Egypt). Then they were housed in individual cages, in a temperature-controlled room at 25 ± 2 C, where a 12-hour light/dark cycle was maintained. The animals were fed with standard chow diet and water ad libitum, and acclimatized for 2 weeks before the commencement of the experiment.

All experiments in this study were performed in accordance with the international guidelines for animal research and the protocol was approved by Research Ethics Committee, at Minia University, Egypt.

5- Experimental design and treatment:

A total of thirty-five male rats were included in our study where they have been randomly allocated to one of five groups, seven animals each as following:

Group (I) Normal control (NC) group; the animals were allowed ad libitum access to water and normal food for the whole days of the experiment.

Group (II) 5-Fluorouracil-treated group (5-FU); the animals were received a single therapeutic dose of 5-FU 100 mg/ kg, which was injected intraperitoneal (i.p.).

Group (III) Post-treatment with 5-Fluorouracil following whey protein administration group: The animals were pre-treated with whey protein, which was administered orally using oral gastric tube for 25 days, then a single therapeutic dose of 5-FU 100 mg/kg was injected i.p.

Group (IV) Simultaneous treatment with 5-Fluorouracil and whey protein **group**: The animals were concurrently treated with an intraperitoneal injection of a single therapeutic dose of 5-FU 100 mg/kg and oral administration of whey protein.

Group (V) group intake of whey protein: The animals were received whey protein by oral gastric tube 0.5 g/kg of body weight.

6-Tissue sampling and examination

Rat in the all groups were sacrificed. Autopsy samples from the kidneys and livers were examined for histopathological examination using light microscopy (Olympus BH-2 microscope).

To evaluate liver function, alanine aminotransferase (ALT), aspartate aminotransferase (AST) were measured using commercial kits (BIOMED Diagnostics, Hannover, Germany) according to the manufacturer's instructions (Tietz, 1976). Iron level in blood was measured at 590 nm.

RESULTS AND DISCUSSION

1-Histopathological examination:

1-1-Histopathological of Liver

Examination of the liver tissue sections obtained from animals treated with 5-Fluorouracil, revealed focal necrosis within parenchymal cells, severe hydropic degeneration and marked congestion in the central vein as well as sinusoids (Fig.1). Histopathological examination of the liver tissue sections obtained from animals that treated with 5-Fluorouracil following administration of whey proteins, showed marked improvement, with mild congested central; portal veins and mid cloudy (Fig.2). Concurrent treatment with 5-Fluorouracil and whey protein caused significant ameliorative changes, where hepatic tissue section displayed almost normal histology with only mild congestion and dilated central vein (Fig.3).

A similar study conducted by Mansour et al., (2017) revealed that, treat of rats with whey protein isolate (WPI) prior to cyclophosphamide (CP) exerted improvement of the liver tissue depending on whey protein concentrate. This improvement in liver tissue evidenced by normal histological structure of liver sections of rats, pronounced in normalized

appearance of liver in the formation of normal hepatic cords. Also, whey protein isolate (WPI) treatment

showed improvement in hepatic architecture and central vein slightly dilated (Mansour et al., 2017).

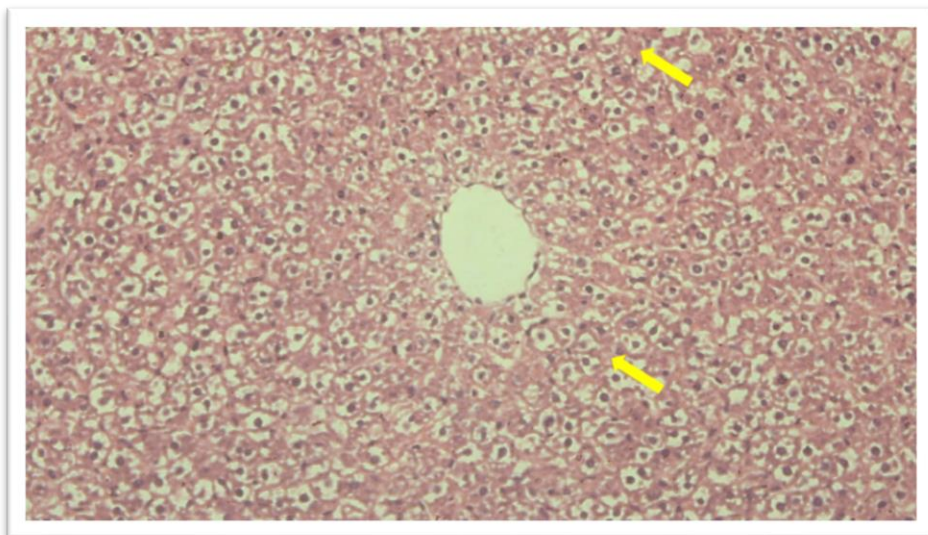


Fig (1): A photomicrograph of Histological section of liver from 5-Fluorouracil treated rats showing focal necrosis (arrow). (H & E, x400).

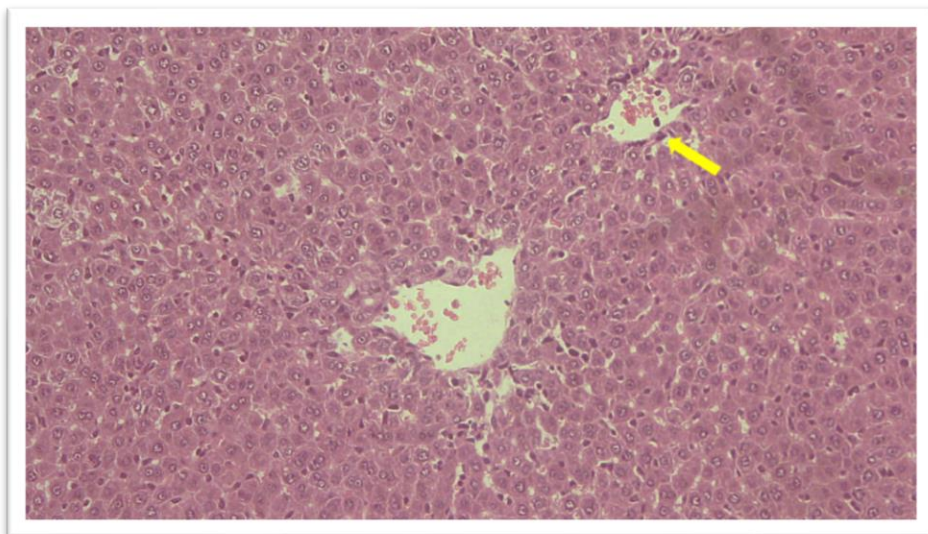


Fig (2): A photomicrograph Histological section of liver from Post-treatment with 5-Fluorouracil following whey protein oral administration showing marked improvement, with mild congested central and portal veins (arrow). (H & E, x400).

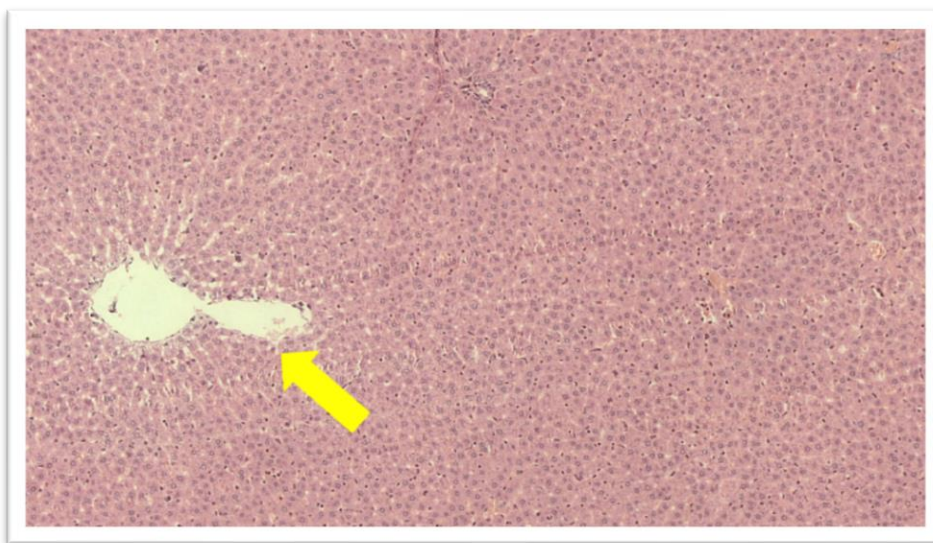


Fig (3): A photomicrograph of Histological section of liver from simultaneous treatment with 5-Flurouracil and whey protein showing normal histology with only mild congestion and dilated central vein (arrow). (H & E, x400).

1-2-Histopathological of kidney:

Treated rats with 5-Flurouracil induced severe hydropic swelling marked congestion and hemorrhage and mild to moderate focal tubular necrosis. Some tubules were distorted. The lumena of some tubules were filled with degenerate and desquamated epithelial cells (Fig.4). Examination of renal tissue sections obtained from animals that were treated with 5-Flurouracil following administration of whey protein, revealed pronounced enhancement in kidney tissue, with residual cloudy swelling, mild focal tubular necrosis and congested blood vessels (Fig. 5). Furthermore, synchronous treatment with 5-Flurouracil and whey protein showed also pronounced improvement in renal tissue, with mild cloudy swelling, mild focal

tubular necrosis and congested blood vessels (Fig. 6).

Mansour et al., (2017) found that using of whey protein isolate (WPI) led to remarkable improvement in renal tissue of rats prior to cyclophosphamide (CP) evidenced by normal histological features of glomeruli and tubules. Major findings of a study conducted by Mansour et al., (2017), concerning histopathological examination of liver and kidney tissues are in good agreement with after treatment. so, the findings in the present study may provide further confirmation of the potential mechanism through which WPI improved the histopathological picture of 5-Flurouracil -treated rat liver and kidney and this improvement may be related to its

antioxidant activity (Bounous, 2000; Pena-Ramos and Xiong, 2001).

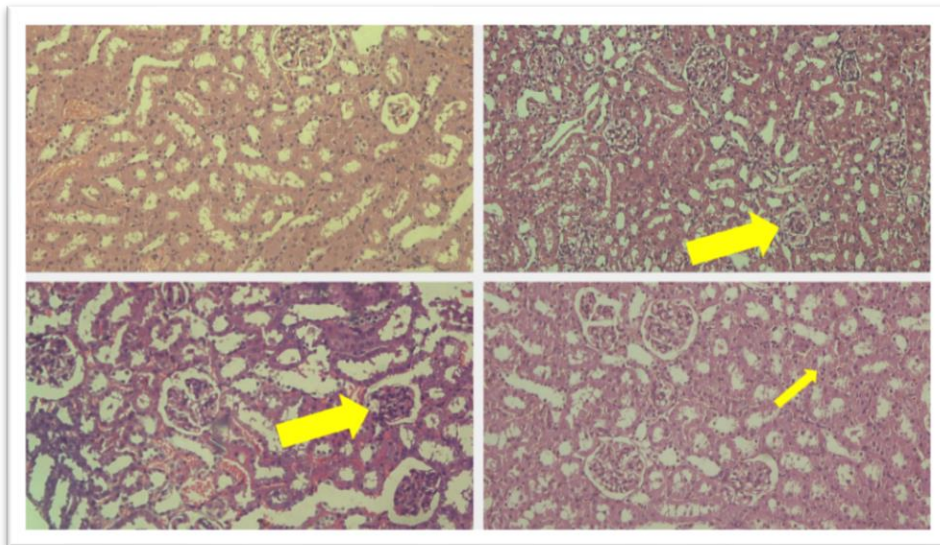


Fig (4): A photomicrograph of Histological section of kidney from 5 Fluorouracil treated rats showing severe hydropic swelling (thick arrow), marked congestion and hemorrhage and mild to moderate focal tubular necrosis (thin arrow). (H & E, x400)

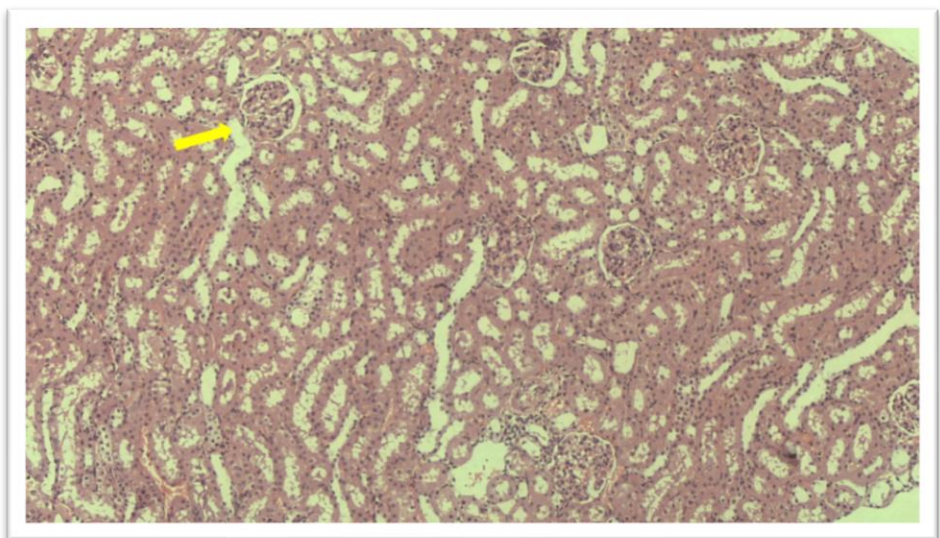


Fig (5): A photomicrograph of Histological section of kidney from Post-treatment with 5-Fluorouracil following whey protein and administration showing pronounced enhancement in its histology, with residual cloudy swelling (arrow). (H & E, x400).

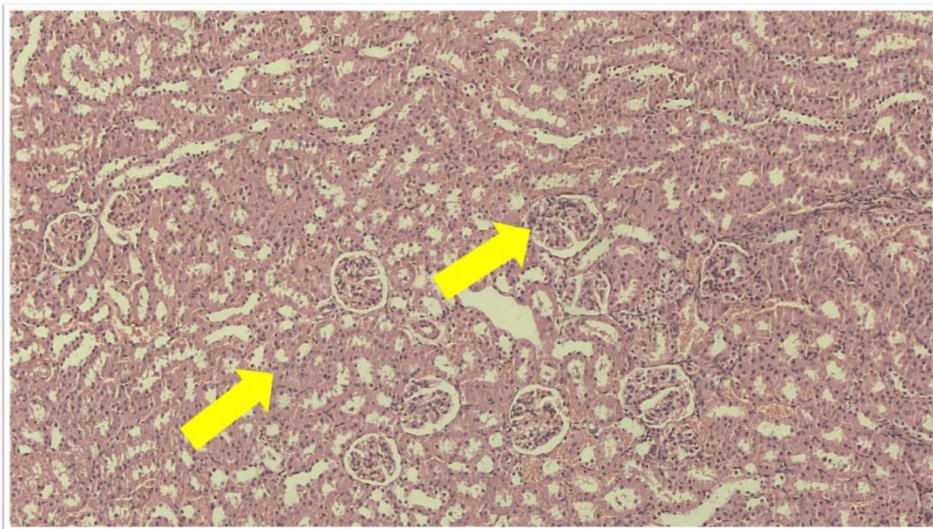


Fig (6): A photomicrograph of Histological section of kidney from simultaneous treatment with 5-Flurouracil and whey protein showing pronounced improvement in its histology, with mild cloudy swelling, mild focal tubular necrosis (arrow). (H & E, x400).

2-Effects of whey proteins and 5-Flurouracil administration on biochemical parameters.

2-1- Liver function tests

Liver function tests are groups of blood tests, which are a helpful screening tool, that give information about hepatic dysfunction. In the present study, ALT, AST activities and albumin concentration were determined in serum of all treated groups. The change in liver function tests were recorded for the rats of different groups and the results are presented in Figure (1). The ALT activity was significantly ($P < 0.05$) elevated in whey protein treated rats as compared to positive and negative normal groups by 49.36 and 42.54 % respectively (Fig. 7A). Meanwhile,

pre or post treatment of rats with whey protein significantly ($P < 0.05$) improved liver functions as compared to other treated rats.

Most increases in serum ALT and AST levels are caused by liver damage or disease. These increases maybe due to additional ALT and AST are released into blood stream (Kim et al., 2008).

Moreover, the changes of AST activity and albumin concentration (g/dl) in blood serum were recorded for the rats of different groups and the results are presented in Figure 7B, which indicated that, no significant differences were observed in AST activity and albumin concentration between control and other treatments.

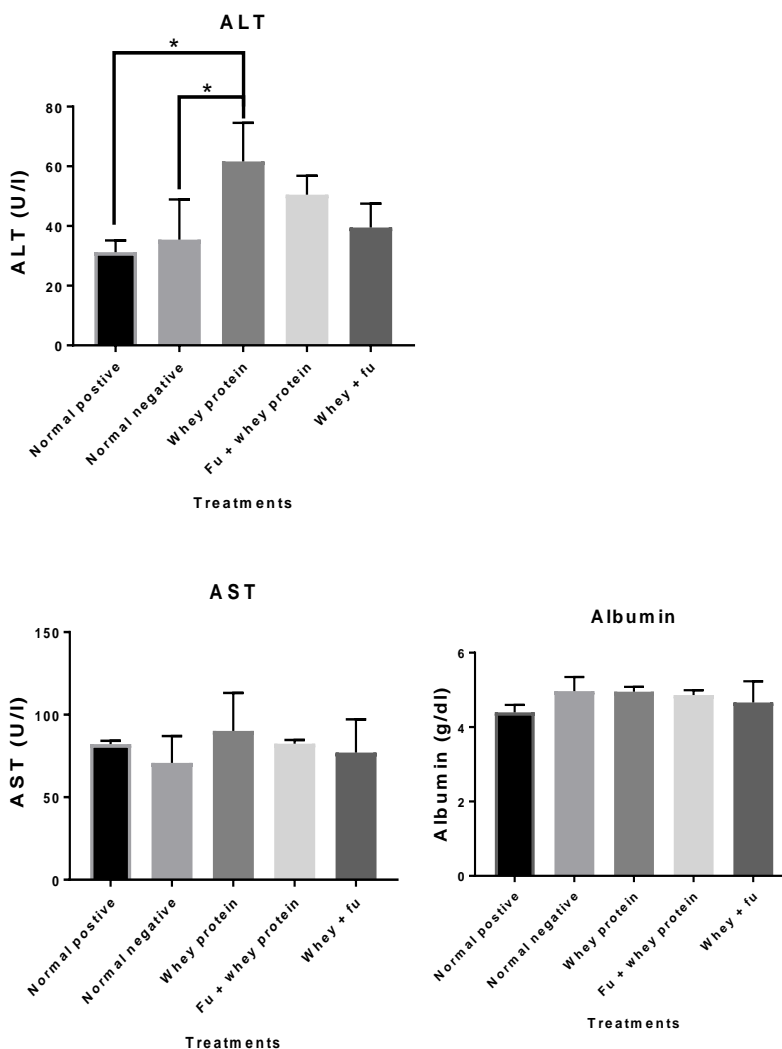


Fig (7): Biochemical changes in liver function tests in rats of different groups exposed to whey protein and 5-Flurouracil.

2-2- Kidney function tests

The change in kidney function tests were recorded for the rats of different groups and the results are presented in Figure (8). Urea and creatinine levels (mg/dl) were determined in serum of all treated groups. Urea is major end product of amino acid catabolism, produced by

liver. It is filtered out of blood by glomeruli in kidneys (Corbett, 2008). It is useful to diagnosis of acute renal failure and an increase in blood urea may be associated with kidney disease (Mitchell and Kline, 2006). Creatinine is a small component form from certain phosphate and muscle waste product (Levey et al., 1999).

As indicated in Figure 8 no significant ($P > 0.05$) alterations were

noticed between all treated groups in urea and creatinine concentrations.

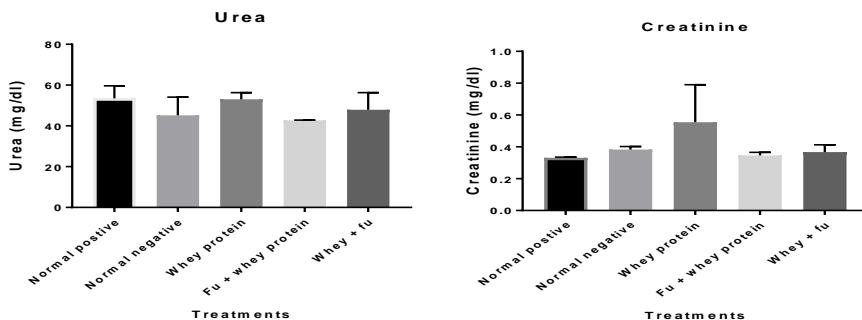


Fig (8): Biochemical changes in kidney function tests in rats of different groups exposed to whey protein and 5-Flurouracil.

2-3- Serum iron concentration

As indicated in Figure (9). no significant differences in serum iron concentration were found between whey protein and 5-Flurouracil administrative groups and control treated sample.

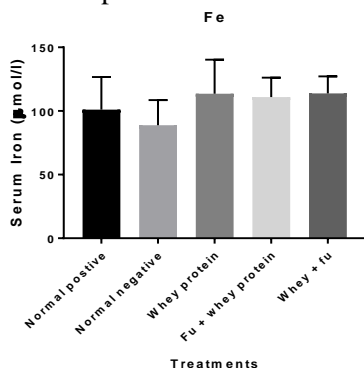


Fig (9): Mean values of serum Fe ($\mu\text{mol/l}$) concentration in rats of different groups exposed to whey protein and 5-Flurouracil.

REFERENCES

Bounous G. (2000). Whey protein concentrates (WPC) and glutathione modulation in cancer treatment. *Anticancer Res*, 20: 4785-4792.

Bumrungpert, A., Pavadhgul, P., Nunthanawanich, P., Sirikanchanarod, A., & Adulbhan, A. (2018). Whey protein supplementation improves nutritional status, glutathione levels, and immune function in cancer patients: a randomized, double-blind controlled trial. *Journal of medicinal food*, 21(6), 612-616.

Corbett J.V. (2008). *Laboratory tests and diagnostic procedures with nursing diagnoses*. 7th Ed. 90-107.

Ha, E., Zemel and M.B. (2003): Functional properties of whey, whey components, and essential amino acids: Mechanisms underlying health benefits for active people (Review). *J Nutr Biochem* 2003;14: 251-258.

Kilara, A. and Vaghela, M. N. (2018). Whey proteins. In *Proteins in Food Processing: Second Edition* (Second Edi). Yada, R.Y. p, 93-126. Woodhead, publishing. United Kingdom.

Kim W.R., Flamm S.L., Di Bisceglie A.M., Bodenheimer H.C.

- (2008). Serum activity of alanine aminotransferase (ALT) as an indicator of health and disease. *Hepatology*, 47: 1363-1370.
- Levey A.S., Bosch J.P., Lewis J.B., Greene T., Rogers N., Roth D. (1999). A more accurate method to estimate glomerular filtration rate from serum creatinine: A new prediction equation. Modification of Diet in Renal Disease Study Group. *Ann Intern Med* 130: 461– 470.
- Mansour D.F.; Salama A.A.A.; Hegazy R.R.; Omara E.A.; Nada S.A. (2017). Whey protein isolate protects against cyclophosphamide-induced acute liver and kidney damage in rats. *J. Appl. Pharmaceut. Sci.*, 7: 111-120.
- Mitchell H.R. and Kline W. (2006). Core curriculum in nephrology, Renal Function Testing. *Am J Kidney Dis*; 47: 174-183.
- Pena-Ramos E.A. and Xiong Y.L. (2001). Antioxidative activity of whey protein hydrolysates in a liposomal system. *J Dairy Sci*, 84:2577-83.
- Tietz N. W. (1976) *Fundamentals of Clinical Chemistry*, ed. N. W. Tietz, pp. 474±698. W.B. Saunders Company, Philadelphia.
- Tomovska, J., Dimitrovska, G., Presilski, S., & Velkova, K. (2016). Whey and its inhibition of liver enzymes. *Biotechnology in Animal Husbandry Biotechnological u Stocarstvu*, 32(1), 59–70.

بعض الصفات البيولوجية لبروتينات الشرش

جيهان خلف عبدالكريم*؛ منال اسماعيل عبدالغني**؛ كريمة عبدالحميد حسنين*؛ أحمد شوقي زهران*

*قسم علوم الألبان - كلية الزراعة - جامعة المنيا - المنيا - مصر

**قسم الباثولوجي - كلية الطب - جامعة المنيا - المنيا - مصر

تم دراسة بعض الخصائص البيولوجية لبروتينات الشرش علي الفئران التي تم معاملتها بمركب 5-fluorouracil. اوضحت الدراسات الهستوباثولوجيه لأنسجه الكبد للفئران التي تم معاملتها بمركب 5-fluorouracil ثم تغذيتها على بروتينات الشرش ان بروتينات الشرش ادت الى تحسينات واضحة على الوريد الكبدي الرئيسي والبابي والمحتقن جزئيا : ايضا ادت تغذيه الفئران ببروتينات الشرش بعد معاملتها بمركب 5-fluorouracil الى تحسين معنوي في انسجه الكبد في الفئران حيث اظهرت النتائج ان انسجه الكبد تكاد تكون طبيعيه مع وجود احتقان خفيف وتمدد في الوريد الرئيسي ايضا وجود تحسن ملحوظ فى انسجه الكلى التي تم فحصها في الفئران المعاملة بمركب 5-fluorouracil بينما لم يلاحظ ايه فروق بين جميع المعاملات في تركيزات كل من الكرياتينين واليوريا ايضا تغذيه الفئران المعاملة بمركب 5-fluorouracil لم تؤثر على تركيزات الحديد في السيرم.