

The diagnostic efficacy of multiplanar and 3-dimensional MDCT in Evaluation of Traumatic Maxillofacial Injuries

Original
Article

Joy Youssef Shaker^{a, c}, Gehan S. Seifeldein^a, Mohammed Hasan Osman^b and Hosameldeen Abozaid Yousef^a

^aDepartment of Diagnostic and Interventional Radiology and ^bDepartment of Maxillofacial Surgery, Faculty of Medicine, Assiut University, ^cDepartment of Radiodiagnosis, El-Mabara Health Insurance Hospital, Assiut, Egypt

ABSTRACT

Purpose: The study aimed to evaluate the diagnostic accuracy of multidetector computed tomography (MDCT) using multiplanar and three-dimensional (3D) reconstruction images in the management of patients with maxillofacial injuries.

Materials and Methods: Ninety-six patients with maxillofacial trauma were enrolled. The detected fractures were documented and tabulated into three groups. The first group the data obtained in axial images, the second group the data obtained in multiplanar reformatted images, and the third group 3D-reconstructed images.

Results: Orbital, mandibular, and maxillary fractures were the most frequent fractures occurring in 37 (50.6%), 37 (50.6%), and 33 (45.2%) cases respectively. 3D reconstructed images had the highest sensitivity in diagnosing the infraorbital fractures compared with axial, sagittal, and coronal reformatted images ($p = 0.00$, $p = 0.03$ and $p = 0.01$ respectively). Coronal reformatted images performed better than axial images in the evaluation of pterygoid plate fractures, and axial images were better in the case of anterior maxillary wall fractures in comparison to 3D reconstruction ($p = 0.01$). Sagittal reformatted images had the least sensitivity in diagnosing mandibular fracture and condylar dislocation.

Conclusion: Multiplanar reconstruction increases the effectiveness of visualization of facial fractures. 3D images provides better visualization of fracture lines and displaced bony fragments especially in the case of Le Fort fractures.

Key Words: Facial bone injury, Maxillofacial trauma, Multiplanar CT.

Received: 20 July 2021, **Accepted:** 07 September 2021.

Corresponding Author: Gehan S. Seifeldein, Department of Diagnostic and Interventional Radiology, Faculty of Medicine, Assiut University, Assiut, Egypt, **Tel.:** +0882413130, **Mobile:** +201224417605, **E-mail:** gehanseifeldein@aun.edu.eg.

ISSN: 2090-097X, April 2021, Vol. 12, No. 2

INTRODUCTION

Facial fractures are common sequelae of different mechanisms of trauma and it can be challenging not to miss any major finding, this is attributed to clinicians' inability to perform a thorough physical examination especially in polytraumatized patients, patients' inability to cooperate, and pronounced facial swelling^[1].

An exact and fast evaluation of facial bone fractures is mandatory because of the complicated anatomical structure of the facial skeleton, the diversity of possible traumatic injuries in this region, and the high risk of complications^[2].

Multidetector computed tomography (MDCT) has become the imaging standard in evaluating facial trauma. It has proven great value in determining the treatment plans in patients who would require surgical treatment for these injuries. Radiologists should be aware of the major types of facial fractures such as naso-orbito-ethmoidal, orbital, zygomaticomaxillary complex (ZMC), Le Fort, and mandibular fractures^[3].

Multiplanar (MPR) reconstructions proved to be superior to conventional 2-dimensional (2D) CT as it

allows more effective visualization of fractures, especially in fractures of the inferior orbital wall. Multiplanar and 3D reconstructions increase the diagnostic effectiveness of CT examinations by providing better spatial orientation and allow for better planning of surgery and monitoring of its results. MDCT has the advantage of increasing the patient's comfort during examination by reducing the examination time, without the need for patient repositioning in axial and coronal orientations, with good quality of image reconstructions^[4,5].

This study aimed to evaluate the diagnostic accuracy of multidetector computed tomography (MDCT) using multiplanar and three-dimensional (3D) reconstruction images in the management of patients with maxillofacial injuries.

MATERIALS AND METHODS

This cross-sectional study has been conducted for 3 months from May to July 2017 in the Assiut University Hospital Trauma Unit, tertiary care hospital, as a collaborative work between the Diagnostic Radiology Department and Maxillofacial Surgery Unit of the Surgery Department.

Inclusion Criteria: All adult patients (above 18 years) of both sexes with maxillofacial trauma who attended the Trauma Unit during these 3 months.

Exclusion Criteria: Included pediatric group < 18 years and severely polytraumatized critical patients.

This study had been approved by the local Ethical Committee of the Faculty of Medicine, under reference number IBN no. 17101310. It was conducted following the provisions of the Declaration of Helsinki. Written informed consent was obtained from participants before enrolment.

Sample size calculation:

Sample size calculation was carried out using G*Power 3 software^[6]. A minimum calculated sample of 96 patients with maxillofacial trauma was needed to detect an effect size of 0.5 in the rate of detection of facial bone injury by multiplanar vs. 3D imaging, with an error probability of 0.05 and 80 % power.

The technique of MDCT examination:

All MDCT examinations were performed on a 16-rows scanner (Hi-Speed, General Electric Medical Systems (GE), Milwaukee, Wisconsin, USA). The following technical parameters were used as a standard in all patients: tube voltage of 120 kV, amperage 200 mA, 1.25 mm collimation, and a pitch of 1.5. The tube rotation time was 0.7 sec and the table speed was 7.5 mm per tube rotation. The whole acquisition time did not exceed 30 seconds. The raw data images were reconstructed into the 'standard' algorithm and 'bone' kernel.

The digital imaging and communication (DICOM) data were transferred to a computer workstation (Advantage Workstation 4.3, GE Healthcare, Waukesha, Wisconsin, USA) for viewing and post-processing. In each case, the axial 2D images were carefully reviewed in bone window settings. MPR reconstructions in sagittal, coronal, and oblique coordinates were also performed, and 3D volume-rendered (VR) surface-shaded images were generated in each case.

The detected fractures were classified based upon the anatomical region according to horizontal and vertical buttresses according to Winegar *et al.*^[7] as follows:

- 1- The orbits, concerning its walls and margins,
- 2- The maxillary bones,
- 3- The zygomatic bones,
- 4- The nasal bones,
- 5- The para-nasal sinuses,
- 6- The mandible,
- 7- The cranial frontal bones.

Furthermore, in midface fractures involving multiple buttresses and damage to the pterygoid plates, the three subtypes of Le Fort fractures were considered^[8].

The detected fractures were documented and tabulated into three groups: the first group included the data obtained only from the evaluation of axial images without the use of MPR or 3D reconstructed images. The second group included evaluation of fractures depended upon axial and MPR reformatted images only. While the third group included the fractures evaluated based upon 3D-reconstructed images.

Statistical analysis:

The obtained imaging data were organized and analyzed using SPSS 20 (IBM, USA). Quantitative and categorical data were presented as mean \pm standard deviation) and frequency (percentage) respectively. The diagnostic yield of 2-D axial images, MPR images, and 3D reconstructed images in different maxillofacial injuries were compared using the student's test. The *p*-value was considered significant if less than 0.05.

RESULTS

Out of these screened 96 patients, 23 patients were excluded as follows: 16 cases had no facial or cranial bone fractures and 7 had skull fractures without associated facial bone fractures. The remaining 73 patients had different types of facial skeleton injuries and represented the population of this study, 60 of them were males (82 %) while 13 patients (18 %) were females. The mean age of these patients was 34.28 ± 12.73 years, ranging from 20 to 80 years.

Mode of trauma:

Table (1) show the mode of trauma in patients of the current study based on clinical history. It was noticed that the most frequent mode of injury was a motor car accident, motorbike accident, and fall from height occurring in 20 (27.3 %), 15 (20.5 %), and 12 (16.4 %) patients respectively. The mode of trauma was unknown in 6 patients (8.2 %).

Table 1: Mode of trauma in all studied patients:

	With Maxillofacial fracture (n = 73)	Without Maxillofacial fracture (n = 23)
Motor car accident	20 (27.39 %)	3 (13.04 %)
Motor bike accident	15 (20.54 %)	4 (17.3 %)
Fall from height	12 (16.43 %)	5 (21.7 %)
Fall on the ground	7 (9.58 %)	2 (8.69 %)
Heavy object trauma	7 (9.58 %)	2 (8.69 %)
Assault from other	3 (4.10 %)	0
Firearm injury	2 (2.73 %)	0
Epileptic Fits	1 (1.36 %)	0
Unknown	6 (8.21 %)	7 (30.43 %)

Frequency of maxillofacial fractures based on anatomical locations:

The frequency of maxillofacial fractures is based upon the affected part of horizontal and vertical buttresses of the facial skeleton. Orbital, mandibular, and maxillary sinus fractures were the most frequently affected parts occurring in 37 (50.6%), 37 (50.6%), and 33 (45.2%) cases respectively. The least frequent type was isolated nasal fracture detected in 3 cases (4.1%), followed by isolated paranasal sinus fracture presented in 4 cases (5.4%). Other types of fractures are summarized in Table (2) which shows the frequency of each type of maxillofacial fractures in the current study.

Table 2: Frequency of maxillofacial fractures based on anatomical location:

Location	Frequency (percentage)
Orbital Fractures	37 (50.6%)
Nasal Fractures	27 (37%)
Isolated nasal fracture	3 (4.1%)
Zygomatic Fractures	21 (28.7%)
Maxillary fracture	16 (22%)
Maxillary Sinus Fractures	33 (45.2%)
Zygomatoco-maxillary fractur	7 (9.5%)
Mandibular fractures (Isolated and combined)	37 (50.6%)
Isolated mandibular fractures	24 (33%)
Fracture dislocation of the condyle	7 (9.5%)
Cranial Bone Fractures	18 (24.6%)
Paranasal (Frontal and Sphenoid sinuses) fracture	4 (5.4%)

The diagnostic performance of different types of CT images in each type of the depicted facial fractures was as follows:

1- Orbital Fractures:

Axial images and coronal reformatted images had higher sensitivity in diagnosing fractures involving the orbital floor, infraorbital rim, and orbital walls compared to sagittal reformatted images. Medial orbital wall fractures

were better diagnosed with axial images while lateral orbital wall fractures were better diagnosed with coronal reformatted images. 3D volume-rendered images had the highest sensitivity in diagnosing infra-orbital rim fractures as represented in Table (3), (Figure 1).

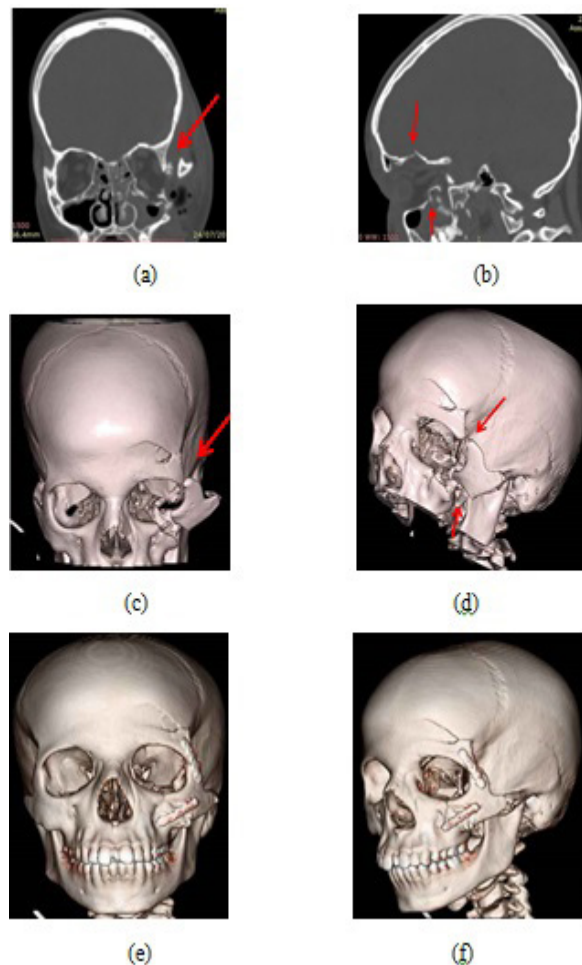


Figure 1: A 16 years old man who was hit by an object. The pre-operative images (a and b): coronal and sagittal reformatted images, and (c and d): 3D images, all showing left impure orbital blow-out trauma (fractures involving the supra-orbital margin, infra-orbital rim, the orbital floor, the medial and lateral walls), left frontal bone fracture, left tripod zygomatic fracture and left zygomatic arch fracture (red arrows). Post-operative 3D images (e and f): showing well alignment of the orbital walls.

Table 3: Number of different orbital fractures detected in different types of CT images:

	Image Type				Significance					
	Axial	Sagittal	Coronal	3D	P1	P2	P3	P4	P5	P6
Supraorbital margin	14	14	14	14	0.99	0.99	0.99	0.99	0.99	0.99
Orbital floor	24	20	24	24	0.13	0.99	0.99	0.13	0.13	0.99
Infraorbital rim	13	8	11	16	0.01	0.11	0.00	0.91	0.03	0.01
Medial orbital wall	18	6	18	14	0.01	0.99	0.13	0.00	0.00	0.23
Lateral orbital wall	21	11	22	21	0.01	0.34	0.99	0.00	0.00	0.45

P value was significant if < 0.05

P1: compared between axial and sagittal constructions

P2: compared between axial and coronal constructions

P3: compared between axial and 3D constructions

P4: compared between sagittal and coronal constructions

P5: compared between sagittal and 3D constructions

P6: compared between coronal and 3D constructions

2- Zygomatic and zygomatico-maxillary fractures:

It was noticed that both axial and 3D reconstructed images had equal sensitivity in the detection of these types of fractures. Table (4) (Figure 1).

3- Maxillary Fractures:

Table (5) shows the evaluation of fractures involving the lateral and medial maxillary walls. Axial, coronal, and 3D reconstruction images had better sensitivity in comparison to sagittal reformatted images ($P < 0.05$). Coronal reconstructed images were better than axial images in the detection of pterygoid plate fractures, with high statistical significance ($p = 0.01$). Also, axial images

were better than 3D reconstruction in the evaluation of anterior maxillary wall fractures ($p = 0.01$).

Frequency of Le Fort Fractures:

(Figure 2) Shows the frequency of Le Fort fractures in the examined patients.

Six patients had Le Fort I fracture 4 of them were bilateral. Five cases had Le Fort II fractures, and 3 of them were bilateral. Two cases had Le Fort III fractures, and 2 cases had combined types of Le Fort fractures on both sides. (Figure 3, Figure 4 and Figure 5). The pan-facial fracture was depicted in only one case. (Figure 6).

Table 4: Number of zygomatic and zygomaticomaxillary fractures detected in different types of CT images:

	Image Type				Significance					
	Axial	Sagittal	Coronal	3D	P1	P2	P3	P4	P5	P6
Zygomatico-maxillary	7	3	5	7	0.08	0.11	0.99	0.23	0.08	0.11
Zygoma	21	12	21	21	0.34	0.99	0.99	0.06	0.34	0.34

P value was significant if < 0.05 .

P1: compared between axial and sagittal constructions.

P2: compared between axial and coronal constructions.

P3: compared between axial and 3D constructions.

P4: compared between sagittal and coronal constructions.

P5: compared between sagittal and 3D constructions.

P6: compared between coronal and 3D constructions.

Table 5: Number of maxillary fractures detected in different types of images:

	Type of Image				Significance					
	Axial	Sagittal	Coronal	3D	P1	P2	P3	P4	P5	P6
Medial wall	22	4	22	20	0.01	0.99	0.33	0.01	0.01	0.44
Lateral wall	29	7	29	27	0.01	0.99	0.41	0.01	0.01	0.34
Anterior wall	14	5	7	6	0.00	0.03	0.01	0.67	0.97	0.09
Pterygoid plate	12	6	16	5	0.01	0.01	0.02	0.00	0.78	0.01

P value was significant if < 0.05 .

P1: compared between axial and sagittal constructions.

P2: compared between axial and coronal constructions.

P3: compared between axial and 3D constructions.

P4: compared between sagittal and coronal constructions.

P5: compared between sagittal and 3D constructions.

P6: compared between coronal and 3D constructions.

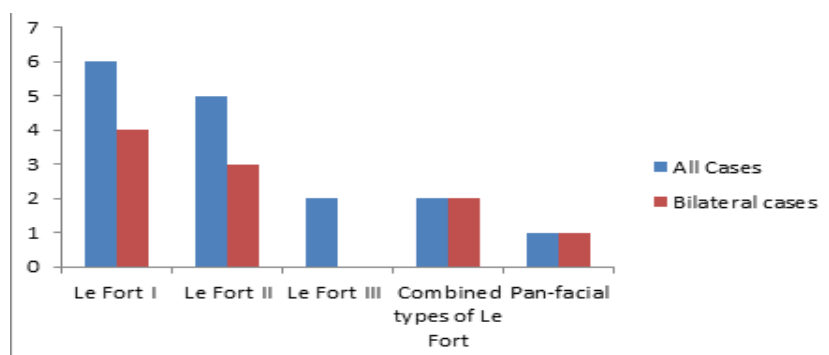


Figure 2: Frequency of Le Fort fractures in the examined patients.

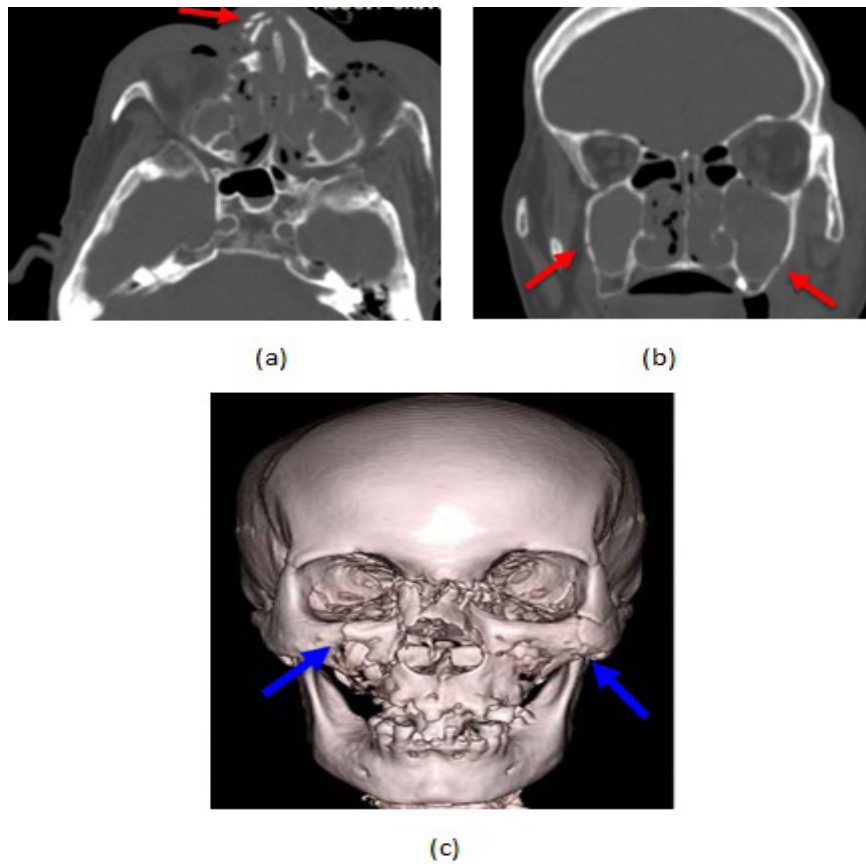


Figure 3: A 60 years old female, Victim of an assault; (a): axial 2D-image shows bilateral comminuted nasal bone fractures with nasal septum fracture (red arrow), (b): coronal multi-formatted image shows bilateral fracture of the lateral walls of the maxillary sinuses which show haemosinus (red arrows), (c): 3D-volume rendered surface shaded image shows bilateral infra-orbital rim fractures (blue arrows).

Diagnosis: Le Fort II fracture with type "3" nasal fracture.

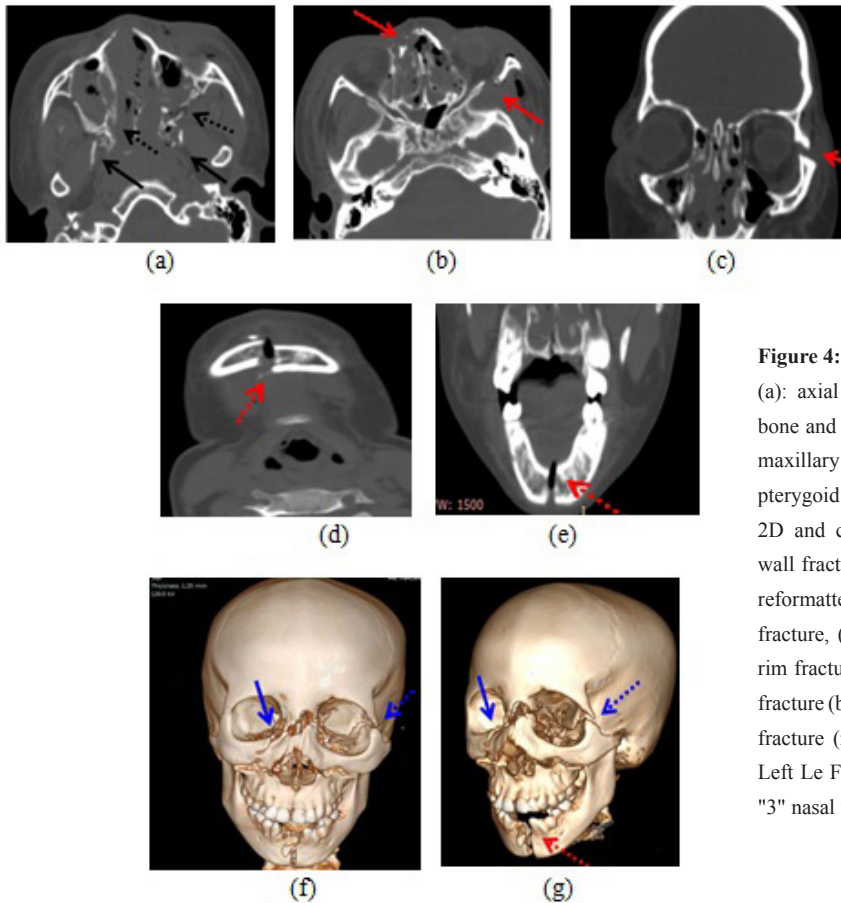


Figure 4: An 18 years old lady who had motor car accident; (a): axial 2D image showing bilateral comminuted nasal bone and nasal septum fractures with bilateral comminuted maxillary sinus fractures (black dotted arrows) and bilateral pterygoid plate fractures (black arrows), (b and c): axial 2D and coronal reformatted images showing left orbital wall fracture (red arrows), (d and e): axial 2D and coronal reformatted images showing symphyseal mandibular fracture, (f and g): 3D images showing right infra orbital rim fracture (blue arrows) and left frontozygomatic suture fracture (blue dotted arrows) and the symphyseal mandibular fracture (red dotted arrows). Diagnosis: Right Le Fort II, Left Le Fort III, Symphyseal mandibular fracture and type "3" nasal fracture.

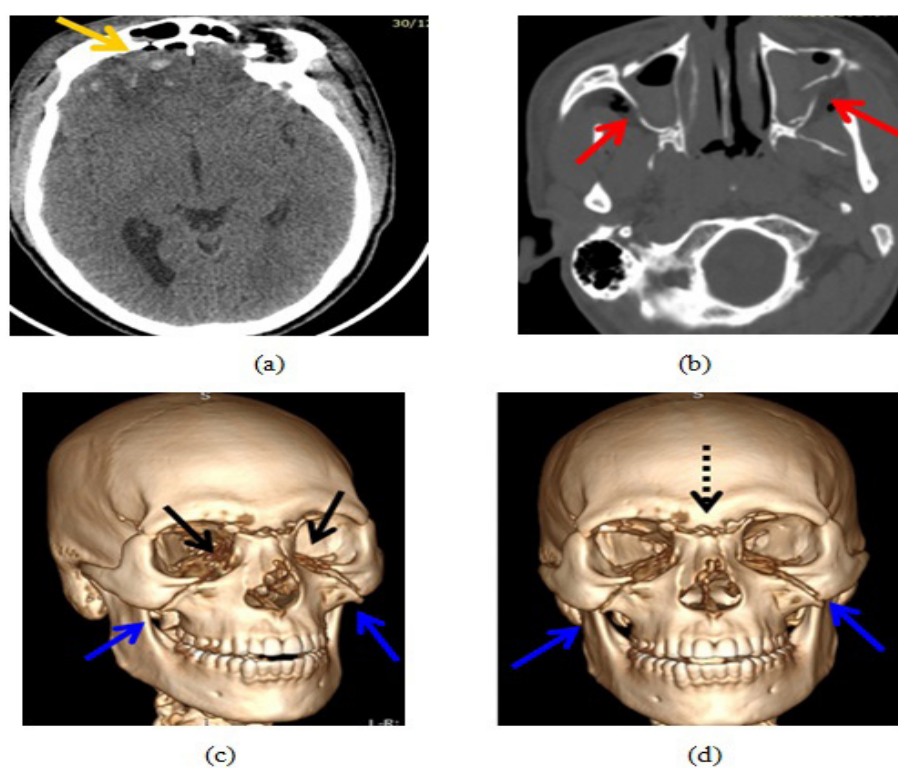


Figure 5: A 20 years old man who had motor bike accident; (a & b): 2D axial soft window and bone window images showing right frontal hemorrhagic brain contusion (yellow arrows), frontal sinus fracture with bilateral maxillary sinus fractures (red arrows); (c & d): 3D images showing bilateral orbital fractures involving the orbital walls and infraorbital rim on both sides (black arrows), with bilateral nasal bone fracture extending to naision (black dotted arrows), and bilateral zygomatico-maxillary fractures (blue arrows).

Diagnosis: Bilateral Le Fort II, Frontal sinus fracture with right frontal cerebral hemorrhagic contusion and type "3" nasal fracture.

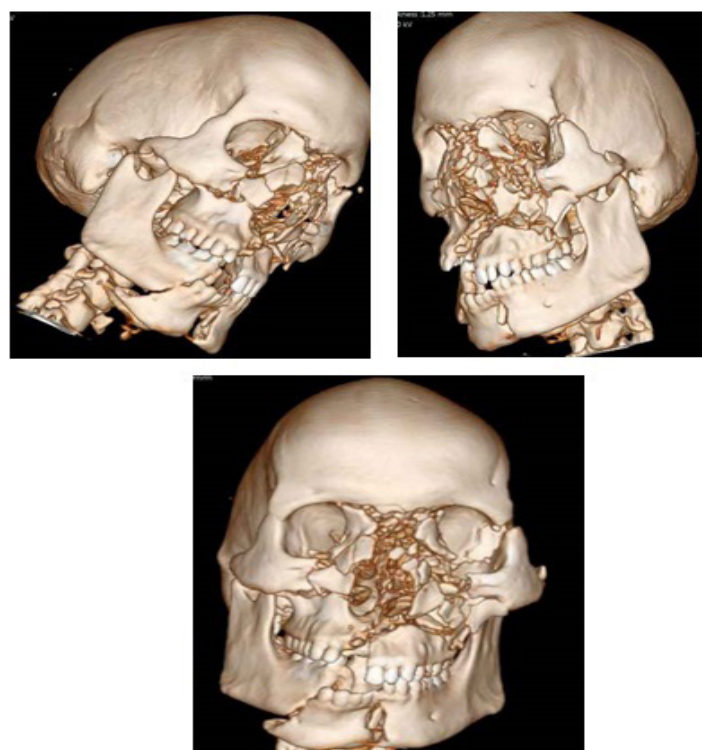

Figure 6: A 67 years old man who had motor car accident. 3D volume-rendered images show bilateral orbital wall fractures, bilateral nasal bones and nasal septum fractures, maxillary bone fractures extending to the alveolar margin, fracture of the left zygoma and symphyseal and right body mandibular fractures
Diagnosis: pan-facial fractures

4- Mandibular Fractures:

Axial, coronal, and 3D reformatted images had better sensitivity in diagnosing symphyseal, para-symphyseal, and mandibular body fractures, as well as in diagnosing dislocation of the mandibular condyle in comparison to

sagittal reformatted images ($p < 0.05$). On the other hand, all types of images had equal sensitivity in diagnosing fractures involving the angle, ramus, and condyle and coronoid process of the mandible as shown in Table (6). (Figure 3).

Table 6: Number of mandibular fractures detected in different types of CT images:

	Type of CT Images				Significance					
	Axial	Sagittal	Coronal	3D	P1	P2	P3	P4	P5	P6
Symphysis	6	1	6	6	0.02	0.99	0.99	0.02	0.02	0.99
Para-symphysis	12	8	10	12	0.03	0.76	0.94	0.56	0.02	0.64
Body	17	4	17	17	0.04	0.94	0.94	0.03	0.03	0.93
Angle	8	8	8	8	0.95	0.95	0.95	0.95	0.95	0.95
Ramus	8	8	8	8	0.95	0.95	0.95	0.95	0.95	0.95
Condyle	8	8	8	8	0.95	0.95	0.95	0.95	0.95	0.95
Coronoid process	1	1	1	1	0.91	0.91	0.91	0.91	0.91	0.91
Condyle Dislocation	9	3	7	7	0.02	0.57	0.57	0.01	0.01	0.66

P value was significant if < 0.05 .

P1: compared between axial and sagittal constructions.

P2: compared between axial and coronal constructions.

P3: compared between axial and 3D constructions.

P4: compared between sagittal and coronal constructions.

P5: compared between sagittal and 3D constructions.

P6: compared between coronal and 3D constructions.

Associated Signs in the Current Study:

Heamosinus, facial edema, and pneumocephalus were the most frequent signs, present in 23, 18, and 7 cases respectively. (Figure 3, Figure 4 and Figure 5). Other signs are summarized in (Figure 7). Sagittal, coronal, and axial images had the same sensitivity in diagnosing the associated signs in the current study.

DISCUSSION

MDCT has revolutionized the assessment of facial trauma especially with the complex nature of its fractures. This is attributed to its high sensitivity in the depiction and accuracy of classification of its patterns at a very short time, with the ability to predict the complications associated with each specific type and location of fractures. MDCT of the face, head, and neck are now routine examinations especially in poly-traumatized patients^[3,9].

In this study, the orbital fractures were the most frequently encountered fractures, detected in 37 patients (50.6 %). The orbital fractures were classified into the supraorbital margin, orbital floor, infra-orbital rim, medial orbital wall, and lateral orbital wall fractures. Orbital floor fracture presented the highest frequency among orbital

fractures detected in 24 cases (64.8 %), including 5 cases showing bilateral orbital floor fracture; followed by lateral orbital wall fractures seen in 21 cases (56.7 %) including 3 cases with bilateral lateral orbital wall fractures.

Our results were similar to those of Prasad *et al.*^[10] who found that orbital fractures were present in 28 % of the cases in their series. The lateral orbital wall was the most commonly fractured (50 %) followed by the medial wall (28.6 %) and roof (14.3 %).

In every case in this study, the axial, multi-planar reformatted, and 3D-reconstructed images were all carefully revised. The reformatted multi-planar images were of high quality and had been reliable for both diagnostic and surgical reconstructive purposes. The 3D-volume rendered images had the highest reliability in the diagnosis of orbital floor fractures ($P = 0.00$). The medial orbital wall fractures were better diagnosed by axial images ($P = 0.01$), but 3D-reconstructed images had the least detection rate in the diagnosis of medial orbital wall fractures ($p > 0.05$). Coronal reformatted images were better in diagnosing lateral orbital wall fractures, but they had statistically insignificant differences ($p > 0.05$).

These findings agree with those of Myga-Porosilo, Jolanta, *et al.*^[2] who stated that 3D-reconstructions were useless in the evaluation of fractures involving the medial orbital wall. Also, Patil *et al.*^[11] found that 3D- images were inferior in the assessment of medial orbital wall fractures. They stated that coronal reformatted images were better in detecting orbital floor and orbital roof fractures.

Regarding the zygomaticomaxillary fractures in this study, zygomatic bone fractures were seen in 21 out of 73 cases (28.7 %). The zygomaticomaxillary suture fracture was detected in 7 cases (9.5 %).

It was in accordance with Wahab *et al.*^[12] who found that the most common complex type of zygomatic fractures was the zygomaticomaxillary complex fracture accounting for (23.3 %) of cases. While Hwang and You^[13] encountered complex zygomaticomaxillary fractures in 14 % of their cases.

In this study, it was noticed that both axial and 3D images had equal efficacy in detecting zygomatic and zygomaticomaxillary fractures. This is in agreement with Wahab *et al.*^[12]. Also, Myga-Porosilo, Jolanta, *et al.*^[2] found that the highest sensitivity of 3D images was observed for fractures in the maxillary zygomatic arches (92 %). However it was noticed that 3D reconstruction images were more accurate in assessing the fracture lines as regards their extent, localization, and displacement, this is in agreement with Prasad, *et al.*^[10] as well as Umamaheshwari *et al.*^[14].

This means that comminuted fractures of the mid-third of the face and the zygomatic fractures are better studied with 3D CT^[15] as the multiplanar images give more detailed information helping the clinicians to identify the fracture with better localization of the bone fragments and their direction of fragments displacement. The combination of CT and 3D VR technique allows improvements in imaging interpretation in a better manner.

Classic Le Fort fractures of the skull are trans-facial fractures of the mid-face, involving the maxilla and surrounding structures in either horizontal, pyramidal, or transverse directions^[16]. It generally accounts for 10 - 20 % of all facial fractures. Originally, in 1901, René Le Fort coined the term "pillars of resistance" representing the strongest areas of the facial skeleton where the described fracture patterns occurred between those pillars of resistance. Le Fort described three types of fractures; common to all is the fracture of the pterygoid processes, and besides, each of them has a unique component^[17].

In this study, the maxillary bone fractures were seen in 16 patients (22 %) which were further sub-classified into 6 cases with Le Fort I (37.5 %), 4 of them had bilateral fractures; 5 cases with Le Fort II (31.2 %); 3 of them were bilateral, and 2 cases with Le Fort III (12.5 %). Still, two other cases (12.5 %) had combined types of Le Fort (I and

II or II and III). Only one case had pan-facial fractures (6.25 %).

Hopper *et al.*^[3] reported that any combination of Le Fort type I, type II, and type III patterns can occur. Rhea and Novelline^[18] reported that several rules should be considered while diagnosing these cases. First, fractures in multiple Le Fort planes may be located on the same side, for example, Le Fort type II and type III can occur on the same side. Second, Le Fort fractures are not the same on both sides. For example, Le Fort type I may occur on one side and Le Fort type II may occur on the opposite side.

The axial, coronal, and 3D reformatted images in this study had better sensitivity in comparison to sagittal reformatted images ($p < 0.05$) for evaluation of fractures of the lateral maxillary wall. Axial images had a better detection rate of anterior maxillary wall fractures in comparison to 3D reconstruction ($P = 0.01$). In dentoalveolar fractures, all types of images had comparable sensitivities ($p > 0.05$).

These findings are in agreement with those of Myga-Porosilo, Joltana, *et al.*^[2] who found that the axial images had the highest sensitivity for detection of fractures involving the anterior and lateral walls of the maxillary sinus.

In this study, coronal multi-planar reformatted images were better than axial images in the detection of pterygoid plate fractures. This is in agreement with Prasad *et al.*^[10] who stated that pterygoid plate fractures were missed by 3D images.

It was observed in this study that the multiplanar MDCT in a patient with facial trauma has an essential role not only in the evaluation of the location of fracture fissures but also it gives detailed data regarding the evaluation of the location of free dislocated bone chips.

Myga-Porosilo, Jolanta, *et al.*^[2] stated that 3D imaging is the most accurate in detecting bone chips especially in cases with fractures involving the anterior wall of the frontal or maxillary sinuses, also in condylar process, and body of the mandible, zygomatic arch, and nasal bones. On the other hand, they found that 3D reconstructions are less useful than 2D reconstructions in the imaging of thin bones.

In this study, mandibular fractures were classified according to the anatomical site into symphyseal, para-symphyseal, body, angle, ramus, condyle, and coronoid process fractures. Twenty-four cases (64.8 %) with isolated mandibular fractures were encountered in this study. Mandibular body fractures had the highest frequency found in 17 cases (45.9 %) followed by para-symphyseal fractures in 12 cases (32.4 %), while the least frequent fracture was the coronoid process fracture.

In addition, axial, coronal reformatted, and 3D images had better sensitivity in the diagnosis of symphyseal, para-symphyseal, and mandibular body fractures in comparison

to sagittal reformatted images ($p < 0.05$). Multi-planar and 3D-reconstructed images help to interpret mandibular fractures, especially the fracture location, the degree of dislocation, type of fracture, and the relationship between multiple fractures^[19]. Myga-Porosilo *et al.*^[2] stated that the highest sensitivity of 3D volume-rendered images was observed in fractures of the body and condyles of the mandible (90 %).

Iqbal *et al.*^[20] stated that haemosinus is the most common associated injury seen in 22 (31.4%) patients with facial fractures. It is consistent with our findings as haemosinus found in 23 (31.5%) cases. Lambert *et al.* found that a clear sinus sign is a highly reliable exclusion criterion of fractures involving the walls of paranasal sinuses. Brain contusions and extradural hemorrhage were the next common associated findings with facial fractures^[21].

There are limitations in this study, related to the relatively short period and small sample size.

CONCLUSION

The complex anatomy of the facial skeleton requires multiplanar imaging techniques for proper evaluation. The main purpose of diagnostic imaging is to detect and localize the number, location, and extent of facial fractures and associated soft tissue injuries. Through careful evaluation of axial, multiplanar reformatted, and 3D volume-rendered images improves the diagnostic accuracy of MDCT, especially in complex facial fractures. Three-dimensional reconstruction represents a good complementary technique for both diagnosis and surgical planning and follow-up.

Abbreviations:

DICOM: The digital imaging and communication,
MDCT: Multidetector computed tomography,
VR: Volume rendered, **ZMC:** Zygomaticomaxillary complex, **3 D:** Three dimensional.

CONFLICT OF INTEREST

The authors declare no conflict of interest.

REFERENCES

- Hopper, R. A., Salemy, S., & Sze, R. W. Diagnosis of midface fractures with CT: what the surgeon needs to know. *Radiographics* : a review publication of the Radiological Society of North America, Inc, 2006, 26(3), 783–793. <https://doi.org/10.1148/rg.263045710>.
- Schueller, G., Scaglione, M., Linsenmaier, U., Schueller-Weidekamm, C., Andreoli, C., De Vargas Macciucca, M., & Gualdi, G. The key role of the radiologist in the management of polytrauma patients: indications for MDCT imaging in emergency radiology. *La Radiologia medica*, 2015, 120(7), 641–654. <https://doi.org/10.1007/s115470500--015-x>.
- Lo Casto, A., Priolo, G. D., Garufi, A., Purpura, P., Salerno, S., La Tona, G., & Coppolino, F. Imaging evaluation of facial complex strut fractures. *Seminars in ultrasound, CT, and MR*, 2012,33(5), 396–409. <https://doi.org/10.1053/j.sult.2012.06.003>.
- Whitman, D. H., Berry, R. L., & Green, D. M. Platelet gel: an autologous alternative to fibrin glue with applications in oral and maxillofacial surgery. *Journal of oral and maxillofacial surgery: official journal of the American Association of Oral and Maxillofacial Surgeons*, 1997, 55 (11), 1294 – 1299. [https://doi.org/10.1016/s0278-2391\(97\)90187-7](https://doi.org/10.1016/s0278-2391(97)90187-7).
- Myga-Porosilo, J., Skrzewski, S., Sraga, W., Borowiak, H., Jackowska, Z., & Kluczevska, E. CT Imaging of facial trauma. Role of different types of reconstruction. Part I - bones. *Polish journal of radiology*, 2011, 76 (1), 41 – 51.
- Faul, F., Erdfelder, E., Lang, A. G., & Buchner, AG*Power 3: a flexible statistical power analysis program for the social, behavioral, and biomedical sciences. *Behavior research methods*, 2007, 39 (2), 175 – 191. <https://doi.org/10.3758/bf03193146>.
- Winegar BA, Murillo H, Tantiwongkosi B. Spectrum of critical imaging findings in complex facial skeletal trauma. *Radiographics*. 2013, 33 (1): 3 – 19.
- Gómez Roselló E, Quiles Granado AM, Artajona Garcia M, Juanpere Martí S, Laguillo Sala G, Beltrán Mármol B, Pedraza Gutiérrez S. Facial fractures: classification and highlights for a useful report. *Insights Imaging*. 2020 ,11(1):49. doi: 10.1186/s1324400847--020-w. PMID: 32193796; PMCID: PMC7082488.
- Echo, A., Troy, J. S., and Hollier, L. H., Jr Frontal sinus fractures. *Seminars in plastic surgery*, 2010, 24(4), 375–382. <https://doi.org/10.1055/s-0030-1269766>.
- Prasad, V.N., Khanal, A. Computed Tomography evaluation of maxillofacial injuries, *Journal of College of Medical Sciences-Nepal*, 2016, 12 (4), pp. 131 - 136.
- Patil, S., Melkundi, S. S. and Santosh.. Maxillofacial and orbital injuries evaluation by

- three dimensional MDCT. *Journal of Evolution of Medical and Dental Sciences*, 2015, 4 (72), 12470+.
12. Wahab, M. , Ibraheim, M. , & Osman, N. The role of multi detector computerized tomography in evaluation of maxillofacial fractures. *The Egyptian Journal of Radiology and Nuclear Medicine*, 2013, 45 (1). doi: 10.1016/j.ejrn.2013.11.003K.
 13. Hwang, K., & You, S. H. Analysis of facial bone fractures: An 11-year study of 2,094 patients. *Indian journal of plastic surgery : official publication of the Association of Plastic Surgeons of India*, 43(1), 2010, 42–48. <https://doi.org/10.4103-0970/0358.63959>.
 14. Umamaheshwari K Basavaraju, Sreeshma Shaji, Nanjaraj Chakenahalli Puttaraj, Rajendra Kumar Narsipur Lingaiah, Supraja Moorthy, Sadananda Billal. Role of MDCT with multiplanar and 3-D Reconstruction in evaluation of maxillofacial fractures. *International Journal of Contemporary Medicine Surgery and Radiology*. 2021, 6 (2): B25 - B31.
 15. Hessel A, Roebuck JC, Periere KD, Poole 3D computed tomography reconstruction alter management decisions of facial fractures. *Otolaryngol Head Neck Surg*. 2004, 131: 243.
 16. Allsop D., Kennett K. Skull and Facial Bone Trauma. In: Nahum A.M., Melvin J.W. (eds) *Accidental Injury*. Springer, New York, NY. 2002 https://doi.org/10.100712_1-21787-387-0-978/.
 17. ELFikey I, El Sammak D. A. E. A., El Sammak A, and Abdelhady M. Diagnostic performance of multi-slice computed tomography using 2D and 3D images in the assessment of Le Fort fractures,” *Egypt. J. Radiol. Nucl. Med.*, vol. 2017, 48 (2), 415 – 424.
 18. Rhea, J. T., and Novelline, R. A. How to simplify the CT diagnosis of Le Fort fractures. *AJR. American journal of roentgenology*, 2005, 184 (5), 1700 – 1705. <https://doi.org/10.2214/ajr.184.5.01841700>.
 19. Ogura, I., Kaneda, T., Mori, S., Sekiya, K., Ogawa, H., & Tsukioka, T. Characterization of mandibular fractures using 64-slice multidetector CT. *Dento maxillo facial radiology*, 2012, 41 (5), 392 – 395. <https://doi.org/10.1259/dmfr/67127210>.
 20. Iqbal, A., Yasin, A., Javeed, M., Rana, T., Khan, B., and Yasin, A. The Role of MDCT and 3D computed tomography in the assessment of maxillofacial fractures and their types: a tertiary care hospital experience. *Journal of Fatima Jinnah Medical University* , 2020, 14 (03), 119 - 123. <https://doi.org/10.37018/dvdu4414>.
 21. Lambert, D. M., Mirvis, S. E., Shanmuganathan, K., and Tilghman, D. L. Computed tomography exclusion of osseous paranasal sinus injury in blunt trauma patients: the "clear sinus" sign. *Journal of oral and maxillofacial surgery : official journal of the American Association of Oral and Maxillofacial Surgeons*, 1997, 55(11), 1207–1211. [https://doi.org/10.1016/s02781-90167\(97\)2391-](https://doi.org/10.1016/s02781-90167(97)2391-).
 22. Ludi EK, Rohatgi S, Zygmunt ME, Khosa F, Hanna TN, Do radiologists and surgeons speak the same language? A retrospective review of facial trauma. *AJR Am J Roentgenol* 2016 207 (5): 1070 – 1076.
 23. Myga-Porosił, J., Skrzewski, S., Sraga, W., Borowiak, H., Jackowska, Z., and Kluczevska, E. CT Imaging of facial trauma. Role of different types of reconstruction. Part I - bones. *Polish journal of radiology*, 2011, 76 (1), 41 – 51.
 24. Hopper, R. A., Salemy, S., and Sze, R. W. Diagnosis of midface fractures with CT: what the surgeon needs to know. *Radiographics : a review publication of the Radiological Society of North America, Inc*, 2006, 26 (3), 783 – 793. <https://doi.org/10.1148/rg.263045710>.
 25. B. A. Winegar, H. Murillo, and B. Tantiwongkosi, “Spectrum of Critical Imaging Findings in Complex Facial Skeletal Trauma,” *RadioGraphics*, vol. 33, no. 1, pp. 3–19, 2013.
 26. Faul, F., Erdfelder, E., Lang, A. G., and Buchner, AG*Power 3: a flexible statistical power analysis program for the social, behavioral, and biomedical sciences. *Behavior research methods*, 2007, 39 (2), 175 – 191. <https://doi.org/10.3758/bf03193146>.
 27. Echo, A., Troy, J. S., and Hollier, L. H., Jr Frontal sinus fractures. *Seminars in plastic surgery*, 2010, 24 (4), 375 – 382. <https://doi.org/10.1055/s-00301269766->.
 28. Prasad, V.N., Khanal, A. Computed Tomography evaluation of maxillofacial injuries, *Journal of College of Medical Sciences-Nepal*, 2016, 12 (4), pp. 131 - 136.
 29. Patil, S., Melkundi, S. S., & Santosh.. Maxillofacial and orbital injuries evaluation by three dimensional MDCT. *Journal of Evolution of Medical and Dental Sciences*, 2015, 4 (72), 12470+.

30. Wahab, M. , Ibraheim, M. , and Osman, N. The role of multi detector computerized tomography in evaluation of maxillofacial fractures. *The Egyptian Journal of Radiology and Nuclear Medicine*, 2013, 45 (1). doi: 10.1016/j.ejrn.2013.11.003K.
31. Hwang, K., and You, S. H. Analysis of facial bone fractures: An 11-year study of 2,094 patients. *Indian journal of plastic surgery : official publication of the Association of Plastic Surgeons of India*, 43 (1), 2010, 42 – 48. <https://doi.org/10.41030358.63959-0970/>.
32. Umamaheshwari K Basavaraju, Sreeshma Shaji, Nanjaraj Chakenahalli Puttaraj, Rajendra Kumar Narsipur Lingaiah, Supraja Moorthy, Sadananda Billal. Role of MDCT with multiplanar and 3-D Reconstruction in evaluation of maxillofacial fractures. *International Journal of Contemporary Medicine Surgery and Radiology*. 2021, 6 (2): B25 - B31.
33. Hessel A, Roebuck JC, Periere KD, Poole 3D computed tomography reconstruction alter management decisions of facial fractures. *Otolaryngol Head Neck Surg*. 2004, 131: 243.
34. Allsop D., Kennett K. Skull and Facial Bone Trauma. In: Nahum A.M., Melvin J.W. (eds) *Accidental Injury*. Springer, New York, NY. 2002 https://doi.org/10.100712_1-21787-387-0-978/.
35. ELFikey I, El Sammak D. A. E. A., El Sammak A, and Abdelhady M. Diagnostic performance of multi-slice computed tomography using 2D and 3D images in the assessment of Le Fort fractures,” *Egypt. J. Radiol. Nucl. Med.*, vol. 2017, 48 (2), 415 – 424.
36. Rhea, J. T., and Novelline, R. A. How to simplify the CT diagnosis of Le Fort fractures. *AJR. American journal of roentgenology*, 2005, 184 (5), 1700 – 1705. <https://doi.org/10.2214/ajr.184.5.01841700>.
37. Ogura, I., Kaneda, T., Mori, S., Sekiya, K., Ogawa, H., and Tsukioka, T. Characterization of mandibular fractures using 64-slice multidetector CT. *Dento maxillo facial radiology*, 2012, 41 (5), 392 – 395. <https://doi.org/10.1259/dmfr/67127210>.
38. Iqbal, A., Yasin, A., Javeed, M., Rana, T., Khan, B., and Yasin, A. The Role of MDCT and 3D computed tomography in the assessment of maxillofacial fractures and their types: a tertiary care hospital experience. *Journal of Fatima Jinnah Medical University*, 2020, 14 (03), 119 - 123. <https://doi.org/10.37018/dvdu4414>.
39. Lambert, D. M., Mirvis, S. E., Shanmuganathan, K., and Tilghman, D. L. Computed tomography exclusion of osseous paranasal sinus injury in blunt trauma patients: the "clear sinus" sign. *Journal of oral and maxillofacial surgery: official journal of the American Association of Oral and Maxillofacial Surgeons*, 1997, 55(11), 1207– 1211. [https://doi.org/10.1016/s02781-90167\(97\)2391-](https://doi.org/10.1016/s02781-90167(97)2391-).