

## Use of Preputial Autograft for Staged Repair of Primary Proximal Hypospadias with Ventral Curvature

Islam Abdel Aziz Ahmed Eltanahy <sup>1</sup>\*M.B.B.Ch; Ashraf Hamed Seddik <sup>1</sup>MD;  
Yasser Ashour Mohammed <sup>1</sup>MD; Sobhy Resk Teama <sup>2</sup>MD

### \*Corresponding Author:

Islam Abdel Aziz Ahmed Eltanahy  
[eslameltanahy@yahoo.com](mailto:eslameltanahy@yahoo.com)

Received for publication November 14, 2021; Accepted March 24, 2022;  
Published online March 24, 2022.

**Copyright** The Authors published by Al-Azhar University, Faculty of Medicine, Cairo, Egypt. Users have the right to read, download, copy, distribute, print, search, or link to the full texts of articles under the following conditions: Creative Commons Attribution-Share Alike 4.0 International Public License (CC BY-SA 4.0).

doi: 10.21608/aimj.2022.105653.1655

<sup>1</sup>Pediatric Surgery Department, Faculty of Medicine, Al-Azhar University, Cairo, Egypt.

<sup>2</sup>General Surgery Department, Faculty of Medicine, Al-Azhar University, Cairo, Egypt.

### ABSTRACT

**Background:** proximal hypospadias with sever ventral curvature is a challenging condition. Some surgeons prefer one-stage repair because it reduces operative trauma, allows the use of unscarred skin with better vascularity, and shortness hospital stay. However, others prefer two-stage repair to prevent complications like urethrocutaneous fistula, urethral strictures or recurrence and avoid utilization of proximal hairing penile skin, and each group have their arguments. The goal of this research is.

**Aim of The Work:** To assess the outcomes of a two-stage repair using a free preputial graft in individuals who have primary proximal hypospadias with a ventral curvature (VC) of 30° or more.

**Patients and Methods:** This research is a prospective case series study that took place during the period from December 2020 to December 2021 in the department of pediatric surgery, Al-Azhar university hospitals after approval by the Al Azhar Faculty of Medicine Ethical Review Committee. The research included 15 patients presented to the outpatient clinics with primary proximal hypospadias with ventral curvature whom fulfilled the required Criteria this patient submitted for staged tubularized preputial graft (STAG) repair.

**Results:** In our study (n=15), as regard the first stage only contraction occurred in 2 cases (13.3%), and the second stage urethrocutaneous fistula in 1cases (6.7%), Glans dehiscence in 1 case (6.7%), 1 case (6.7%) of urethral stricture. the overall complications in the second stage was in 3 cases about (20%), after management of all complications all patient have excellent function and cosmetic results.

**Conclusion:** STAG technique seems to be one of the preferable options for primary proximal hypospadias repair and it is reliable, effective, low complication rate, and has improved urinary function as well as good cosmetic outcomes.

**Keywords:** Preputial Autograft; Proximal Hypospadias.

**Disclosure:** The authors have no financial interest to declare in relation to the content of this article. The Article Processing Charge was paid for by the authors.

**Authorship:** All authors have a substantial contribution to the article.

### INTRODUCTION

Hypospadias is the second most frequent birth defect, is characterized by a halt in the normal development of the urethra, foreskin, and penis ventral part, with a prevalence rate of 1:300 male children<sup>1</sup>.

In most cases, the underlying etiology of non-syndromic hypospadias is unknown.<sup>2</sup> Many reasons can exist depending on information, normal penis creation, and the assumption that hypospadias reflects halted development.<sup>2</sup>

Proximal hypospadias with severe ventral curvature is a challenging condition.<sup>3</sup> Some surgeons prefer one-stage repair because it reduces operative trauma, allows the use of unscarred skin with better vascularity, and shortens hospital stay. However, others prefer two-stage repair to prevent complications like urethrocutaneous fistula, urethral strictures, or recurrence. Each group has their own arguments.<sup>3,4</sup> Regarding another study, a systematic assessment of 20 years of publications on severe

primary hypospadias therapy revealed that a phased approach resulted in reduced complication rates.<sup>5</sup>

After the urethral plate is transected, preputial, buccal, bladder mucosa, and skin grafts or Byars flaps could be used to do a two-stage urethroplasty.<sup>2</sup>

Some authors believed that using an inner preputial graft following transection of the urethral Plate in proximal hypospadias with moderate to severe chordee had an excellent technical result, functionally mimicked normal urethral function, and might be deemed an optimal alternative for uorethroplasty replacement.<sup>6</sup>

The present study will report on the results of a single-center experience using a two-stage repair using a free preputial graft for proximal primary hypospadias who had a ventral curvature of 30 degrees or more, with short-term follow-up.

### PATIENTS AND METHODS

It is a prospective case series study performed at the paediatric surgery departments of Al-Hussain and

Sayed Galal university hospitals, and it included 15 cases having primary proximal hypospadias with moderate to severe ventral curvature between December 2020 and December 2021, all patients managed by staged tubularized preputial graft(STAG) repair.

**Inclusion criteria:** Male patients, aged between 9 months to 14 years suffering from Primary proximal hypospadias with moderate to severe Ventral curvature.

**Exclusion criteria:** Distal and mid-shaft hypospadias, redo or crippled cases. Circumcised cases, cases with insufficient prepuce, and cases with mild chordee.

The study's protocol was approved by Al-Azhar University's Ethical Research Committee, and written informed consent was acquired from the parents or caregivers after full details of the surgical procedures and all possible complications were provided. Complication rates, clinical urine flow, and acceptable cosmetic outcomes derived by the parents' questioner HOPE score at follow-up visits were the major result measurements.

**Statistical analysis:** - The data will be given in the form of a mean, standard deviation, quantity, and percentage. For qualitative data, use the Chi-squared test (X<sup>2</sup>). P 0.05 will be used as the significance level. For statistical analysis, IBM SPSS Statistics for Windows, Version 23.0 will be used. Armonk, NY: IBM Corp.

#### **Surgical procedure:**

##### **First stage:**

Degloving of the penis 2-Release of penile chordee (Orthoplasty)

#### **Graft harvest & Fixation**

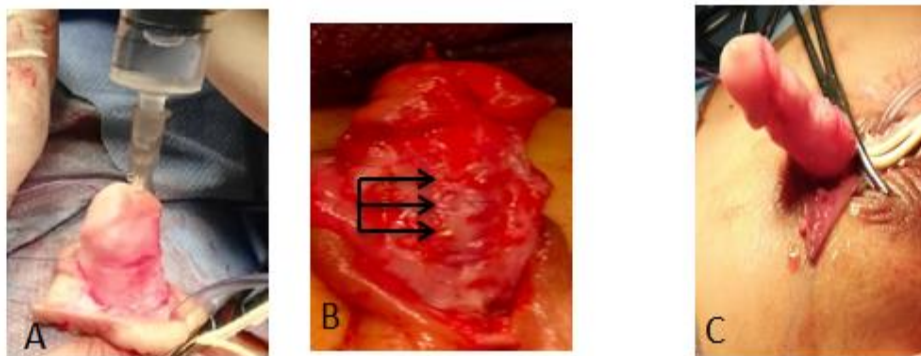
##### **Second stage**

Neo urethra tubularization (urethroplasty) 2-Tunica vaginalis flap

Glansplasty 4-Scrotopalsty 5-Penile skin closure

##### **First stage:**

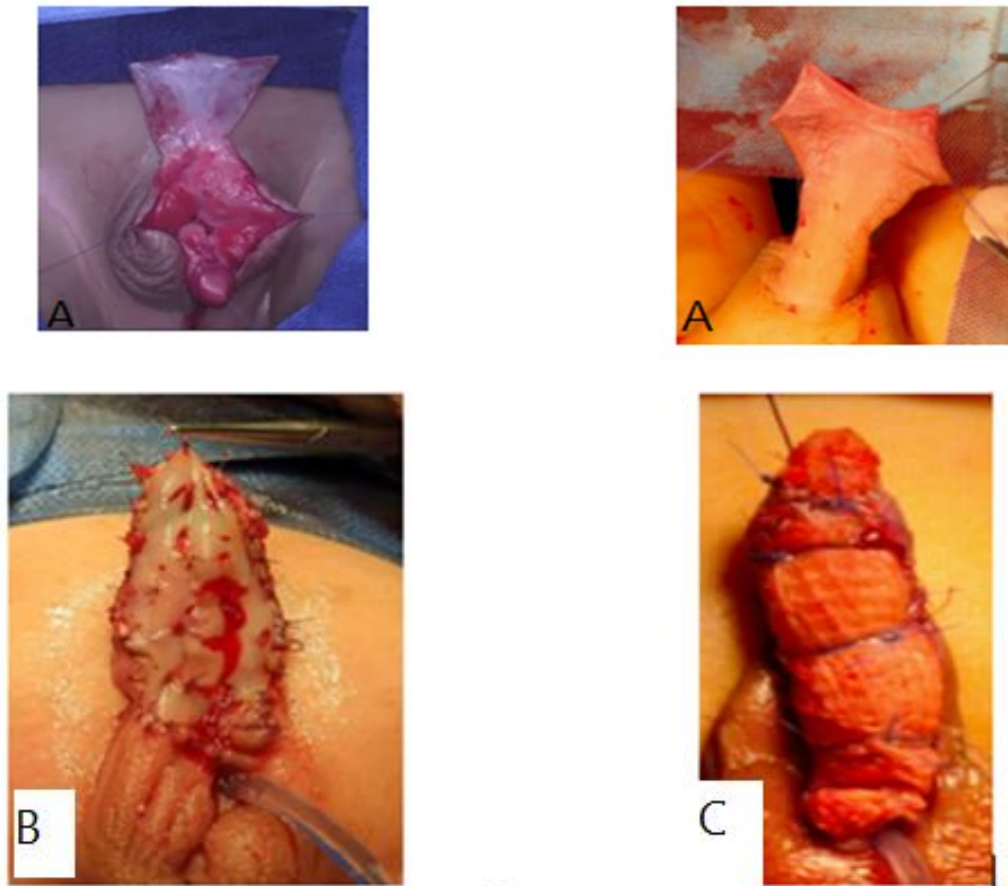
The penis has been degloved to the penopubic junction dorsally as well as the penoscrotal angle ventrally after sterilization, draping traction suture placement at the glans, and catheterization. To preserve prepuce for the graft, a circumferential incision has been made around 3 mm below the corona. An artificial erection was achieved, and the UP has been transected with the underlying dysgenetic fascia. The plate and original meatus were then dissected proximally in order to correct the VC. The erection was artificially induced once more. Three transverse ventral corporotomies were used to straighten persistent VC measured by goniometer. (**Fig. 1**). A longitudinal midline incision was made and advanced laterally to create generous glannular wings. The ventral urethral opening has been spatulated. At 12,2 and 10 o'clock, 6-zero polyglactin sutures were used to suture the dorsal edges of such proximal meatotomy to the corpora.. To liberate the penile and scrotal skin, the skin at the penoscrotal junction has been incised from 6 o'clock to roughly 2 and 10 o'clock. The skin flaps on the scrotum were approximated and fixed on the ventral side to reduce penoscrotal transposition, and after that, penoscrotal or scrotal skin next to the proximal meatus was sutured to the aperture at 5, 6, and 7 o'clock using 6-zero polyglactin suture. The incision in the scrotum was then formally closed.



**Fig (1):** a) Erection test b) Three ventral corporotomies c) Complete release of chordee.

**Graft Harvest and fixation:** The prepuce corners were held together by stay sutures. Inner Preputial skin was dissected and elevated away from underlying dartos fascia (**Fig. 2**). The graft's largest distal section was first sutured to the glannular wings, using interrupted sutures along the future meatus. The graft's proximal end has been incised so that it extends on both sides of the native urethra . About 5 mm apart, interrupted 6-zero polyglactin sutures were used to fix the graft to the underlying corpora. Following that, the graft has been

anchored to the shaft skin on both sides with interrupted 6-zero polyglactin... Grafts were broader than the corporal bodies, and no effort has been made to suture them to underlying structures lateral to the corpora in order to facilitate dissection in the second stage .then fenestration of the graft to prevent hematoma formation . Rolled Vaseline gauze has been secured tightly over the graft with a tie-over bandage after an 8Fr Foleys catheter has been inserted. (**Fig. 2**).



**Fig (2):** (a) Graft harvest (b) fenestration of graft (c) tie over.

Dressing was accomplished, using Sofra-Tulle with local gentamycin ointment applied around the penis (**Fig. 3**) followed by application of Sandwich dressing.



**Fig (3):** Sandwich dressing.

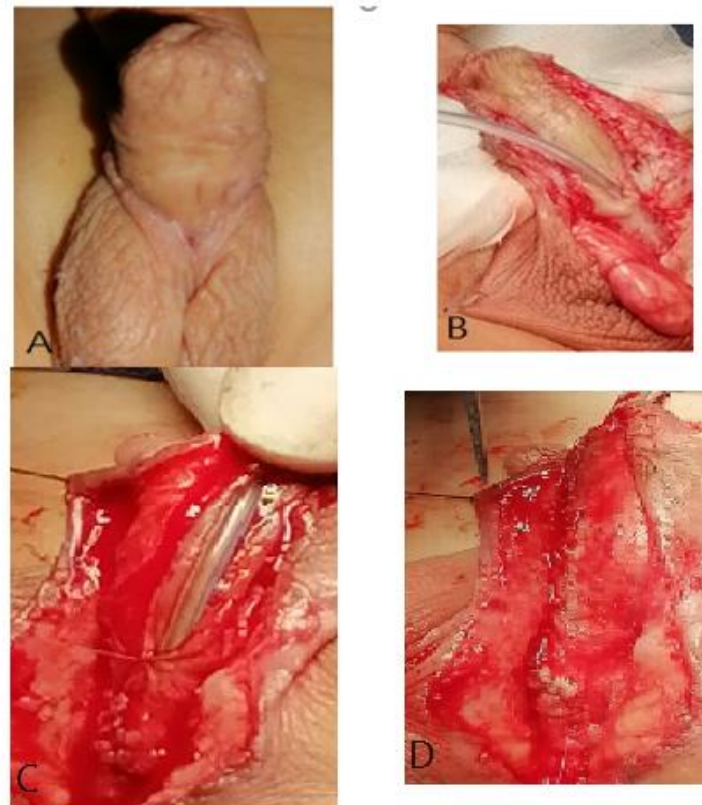
Postoperatively. Seven days after surgery, the catheter and bandage have been removed. There was no consistent recommendation for graft therapy after that. Six months later, surgery has been scheduled for the second time. Parent comments and direct erection observation prior to the second phase verified penile straightening.

### Second Stage

#### Urethroplasty:

After the six-month graft has completed its healing (**Fig. 4 A**), U-shaped incisions have been performed down the edge of the neo urethral plate on either side and into the proximal native urethra 2mm below (**Fig. 4 B**). Urethroplasty was performed after dissecting the gans wings laterally. All of the grafts were wider than 10 mm and varied in length. An 8Fr stent has been placed, and a 2-layer urethral plate tabularization procedure was carried out. The first layer was interrupted with 6-zero polyglactin sutures (**Fig. 4 C**). And then s second layer running 6-zero polydioxanone sutures (**Fig. 4 D**).



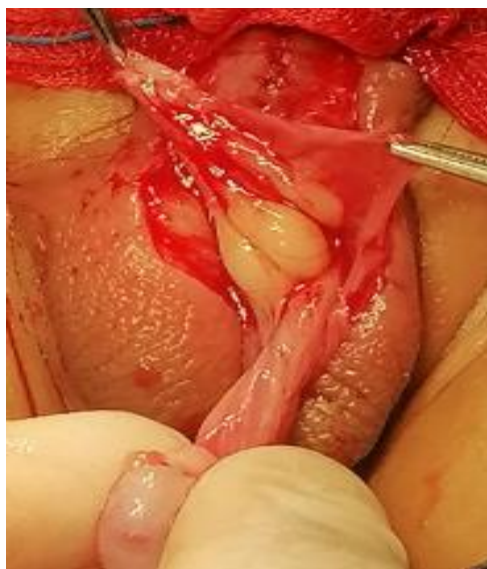

**Fig 4):** (A) Shape of the graft after six months. (B) U shaped incision.

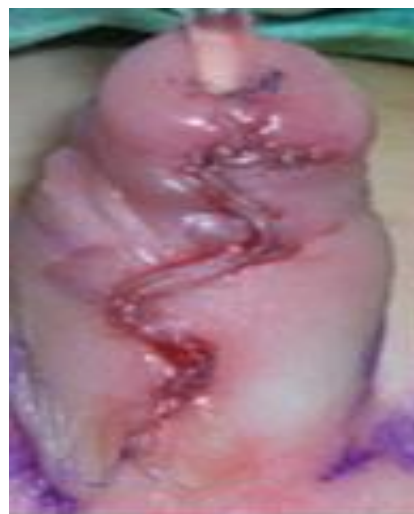(C)first interrupted layer. (D) second continues layer.

A tunica vaginalis flap has been taken and dissected close to the external ring. The testicle has been sutured and the hemi-scrotal compartment has been repaired. The whole neourethra was then coated in TV flap.

Three interrupted vertical mattress 6-zero polyglactin stitches were used to approximate glannular wings above the neo urethra. The first has been positioned in the middle of the glans wings, and the last near the corona. To decrease transposition and avoid secondary concealed penis, the scrotal wall at 3 and 9 o'clock has been sutured to the corpora on either side of the neourethra. Interrupted sutures have been used to seal the penile shaft skin in the midline median raphe. Drainage through the catheter lasted 10days.



**Fig (5):** Tunica vaginalis flap.



**Fig (6):** Skin closure.

Dressing was accomplished, as first stage.

Post-operative broad spectrum intravenous antibiotic was used for all patients in the form of third generation cephalosporin injections for 1 week, The dressing was removed after 48 hours or if there was soaking with urine or blood, and reapplied again till catheter removal, The catheter was removed in 10<sup>th</sup> postoperative day.

All of the operations have been performed by the same surgical team, and patients have been monitored for 3-6 months postoperatively, during which the functional and cosmetic results have been evaluated during follow-up visits by direct vision of single and good stream voiding without strain from neomeatus, follow-up has been conducted in outpatient clinic visits. These visits have been intended to occur within the first week of surgery, followed by a visit every two weeks for the first month, then every two weeks for the next 3 months, The postoperative functional assessment was carried out by medical personnel and parents through direct vision of voiding and calibration of neomeatus and urethra after 1 month using appropriate catheter, and presence of complications in the form of, Urethrocutaneous fistula, Meatal stenosis, Glannular dehiscence, Urethral diverticulum.

Cosmetic assessment was also carried out by using (HOPE SCORE), cooperation between medical personnel and parents through assessing of following items: Position of neo meatus. Either in the tip of glans penis or elsewhere, Shape of neo meatus. Either vertical slit like or rounded, Shape of the glans penis. Either conical shaped or others, Shape of penile skin, Presence of penile rotation.

**RESULTS**

The current research involved 15 children, the average age being 2.5 years ranged between .9 months to 14 years all patients underwent two stages hypospadias repair using preputial graft, the mean length of new urethral plate after grafting was 32±1.7 mm. and mean width was 12±1.2 mm.

The overall complications in 1<sup>st</sup> stage was in 2 cases in the form of (2 cases of graft contraction 13.3%), Table (1), the cases of graft contraction were mildly affect the length and width of graft were safely fit for second stage.

The overall complications of 2<sup>nd</sup> stage urethroplasty were 3cases about 20% (1 case of urethrocutaneous fistula, 1 cases of glannular dehiscence and 1 case of urethral stricture Table (2).

During follow up period (3-6) months, one of the cases of urethrocutaneous fistula closed spontaneously with silver nitrate application, the case of glannular dehiscence underwent second repair glnnuoplasty, and the case of urethral stricture initially respond to urethral dilatation. After management of complications all patients have good urine flow without dripping or staining, and excellent cosmetic results.

The cosmetic results were measured by patient questioner at the follow up period by three independent persons (surgeon, nurse and caregiver). So the cosmetic result obtained by this questioner was promising and very satisfied.

1st stage complications		Total no.=15
Rejection	No	15 (100.0%)
	Yes	0 (0.0%)
Hematoma	No	15 (100.0%)
	Yes	0 (0.0%)
Infection	No	15 (100%)
	Yes	0 (0.0%)
Contraction	No	13 (86.7%)
	Yes	2 (13.3%)

**Table 1:** Descriptive data for 1<sup>st</sup> stage complications.

Second stage complications		Total no.=15
Urethrocutaneous fistula	No	14 (93.3%)
	Yes	1 (6.65%)
Glans dehiscence	No	14 (93.3%)
	Yes	1 (6.65%)
Stricture	No	14 (93.3%)
	Yes	1 (6.65%)

**Table 2:** Descriptive data for second stage complications.

**DISCUSSION**

As regards recipient and donor characteristics, the mean age of the recipient was 41.62 ± 7.842, while the mean age of the donor was 44.33 ± 6.249. In addition, M.F ratio was approximately 2:1 in the recipient and approximately 1.5:1 in the donor.

While, El-Mekresh et al.<sup>6</sup> conducted their study on 1200 successive living-donor kidney transplants, 892

man and 308 women (mean age 29.8 years, range 5±62; donors 34.9 years, range 17±69).

Urological complications occurred in 26.3% of cases (15% with early onset and 12.9% with late onset).As regards early onset complications: Bacterial infection occurred in 21 patients (8.8% of cases) , all improved on antibiotics, perinephric hematoma occurred in 4 patients (1.7% of cases),all improved on conservative treatment in the form of antibiotics and bed rest, Urinary retention occurred in 3 patients (1.3% of

cases), two of them were due to clot retention that was evacuated by catheter irrigation, in one patient while needed cystoscopic evacuation in the other, in the third patient retention was caused by BPH and the patient needed later TURP. Urinary leakage occurred in 4 patients, all improved by prolonged catheter drainage. Ureteric obstruction occurred in 4 patients (1.7%) caused by edema or clot retention and resolved spontaneously in few days.

As regards late onset complications: Lymphocele occurred in 27 patients (7.9% of cases), 19 cases were asymptomatic and resolved spontaneously within 6 weeks, 8 patients had hydronephrosis by ultrasound that was confirmed by CT, 5 of them improved by US guided drainage, while 3 patients needed open marsupialization. Vesicoureteric reflux occurred in 4 patients (1.7%) all were stable on conservative treatment in the form of antibiotics with maintenance therapy. ED occurred in 5 patients 2 patients improved on type 5 phosphodiesterase inhibitors while 3 patients discontinued treatment. Ureteric stricture occurred in 3 patients, nephrostomy tube was fixed, in 2 patients antegrade pyelogram showed vesicoureteric junction stricture that needed ureteroneocystostomy, while in the third patient antegrade pyelogram showed pelviureteric junction obstruction that needed endoscopic dilatation.

Slagt et al.<sup>7</sup> demonstrated that, urological complications included, urinary tract infections (23%), surgical site infections (8.8%) Primary non-function (9%) and lymphoceles (3%).

In addition, Alberts et al.<sup>10</sup> demonstrated that urological complications happened in 12.3% of cases. In 5.2% of cases surgical revision was vital. Surgical intervention included ureteroneocystostomy (71.7%), ureteropyelostomy reconstruction (16.7%) and other techniques (11.7%).

Moreover, El-Mekresh et al.<sup>6</sup> revealed that complications were detected in 8% of cases, urinary leaks happened in 3.1% of cases, ureteric strictures in 1.9% and lymphoceles leading to ureteric obstruction in 1.4%, Percutaneous needle biopsy was intricated by haematuria and clot anuria in 0.5% of cases. Late problems involved stones (0.9%), bladder tumors (0.3%) and haemorrhagic cystitis (0.17%).

Furthermore, Shokeir et al.<sup>11</sup> displayed that 14% cases encountered urological problems. These problems involved ureteric stricture (4.4%), urinary leakage (4%), intricated lymphocele (3.2%), hematoma requiring surgical intervention (0.8%), wound dehiscence (0.4%) and stone ureter (0.4%).

In terms of lymphoceles, Presser et al.<sup>12</sup> reported symptomatic lymphoceles needing intervention in 2.7% of cases.

Such wide variation in the incidence of urological complications among studies could be explained by several reasons. The first cause was the method of reporting; some authors did not include lymphoceles as a urological complication which was reported to be the most common late complication in the current study and others ignored the UTI which was reported

to be the most common early complication in the current study.

Furthermore, the complication rate was slightly higher in patients who received kidneys from living donors than in those who received organs from cadavers; this is presumably a result of more extensive hilar dissection required during harvesting from the living donor, with the attendant risks of injury to the blood supply of the ureter. This may be another cause for higher frequency in the current study compared to the other researches.

The current study revealed that, the mean Graft survival period was  $37.05 \pm 17.448$  (median was 37 months) and ranging from 6 months to 70 months.

This came in accordance with Slagt et al.<sup>7</sup> who demonstrated that, the mean graft survival was 4.02 years with a standard deviation of 3.47. Minimum graft survival was 0 day due to primary non function and maximum was 12.1 years.

As regards graft survival, the current study demonstrated that there was a statistically significant difference among complicated and non-complicated cases ( $P < 0.05$ ).

This came in agreement with Choate et al.<sup>3</sup> who demonstrated that, urological complications can have considerable effect on graft function and survival. Another research by Arpali et al.<sup>5</sup> found that ureteral stenosis was the only urological complication to have a potent passive association with long-term graft survival. On the other hand, Slagt et al.<sup>7</sup> demonstrated no variation in long term graft survival among the inhabitants with and without urological complications which is confirmed by another investigations van Roijen et al., Dinckan et al., and Alberts et al.<sup>8,9,10</sup>

Moreover, Shokeir et al.<sup>11</sup> demonstrated that graft survival was not influenced by the incidence of operating complications.

The current study demonstrated that recipient age, donor age, female Recipient, female donor, DM, HTN, CIN, lupus nephritis, double graft artery, double graft vein and duration were non-significant predictors for occurrence of urological complications ( $P > 0.05$ ).

In agreement Streeter et al.<sup>13</sup> and Dinckan et al.<sup>9</sup> demonstrated that, potent risk factors for urological problems involving age, extended cold ischemia and Diabetes Mellitus were recorded not to perform an essential function in the incidence of urological problems.

On the contrary, Slagt et al.<sup>7</sup> demonstrated in their Univariate analysis that, there was an increase in the number of man donors ( $p = 0.041$ ), man beneficiaries ( $p = 0.002$ ), pre-emptively transplanted beneficiaries ( $p = 0.007$ ), and arterial reconstructions ( $p = 0.004$ ) in the group with urological problems. In addition, low urological problems existed in beneficiaries on hemodialysis ( $p = 0.005$ ). Further total operative interventions ( $p < 0.001$ ), surgical site infections ( $p = 0.042$ ), urinary tract infections ( $p < 0.001$ ) and lymphoceles ( $p < 0.001$ ) existed in the group with urological problems. Variables analysis cleared that

man beneficiaries ( $p=0.010$ ) and arterial rebuilding ( $p=0.019$ ) were independent risk factors.

In addition, El-Mekresh et al.<sup>6</sup> revealed that, the age of the beneficiaries (< 10 years), procedure of establishing urinary continuity and a high dose of steroids had an independent effective influence on the occurrence of urological problems. Nevertheless, their improvement did not affect graft or patient survival.

Moreover, Shokeir et al.<sup>11</sup> reported in their univariate analysis that, factors which significantly influenced the existence of operative problems were beneficiary's age, lower urinary tract abnormalities, the type of primary urinary continuity, the time to diuresis, and height and weight of the client. On multivariate analysis, the type of primary urinary continuity was the only factor that assisted statistical significance.

Limitations of the current study included retrospective analysis of data and constant technique of ureteroneocystostomy (extravesical litch gregoire technique with placement of ureteric stents)

### CONCLUSION

STAG technique seems to be a one of preferable option for primary proximal hypospadias repair and it is reliable, effective, low complication rate, better urinary function and good cosmetic results.

### REFERENCES

- Kong X, Luo J, Xiang H, Wang S, Shen L, Long C, Liu F, Lin T, He D, Liu X, Wei GH. Expression of Mafb is down-regulated in the foreskin of children with hypospadias. *J Pediatr Urol.* 2021; 33268316. Warren T. Snodgrass, MD. Hypospadias, *camble Walsh urology*, 2012:3503:130
- Duckett JW. Transverse preputial island flap technique for repair of severe hypospadias. *Urol Clin North Am.* 1980;7: 423e31.
- Giannantoni A. Hypospadias classification and repair: the riddle of the sphinx. *Eur Urol.* 2011;60:1190e1. Rev Urol. 2015.
- Snodgrass W, Bush N. 234 Age and Pubertal Status are not Independent Risk Factors for Urethral Complications Following Hypospadias Repair. *The Journal of Urology.* 2012;187(4s):e96-7.
- Snodgrass W, Bush N. Staged tubularized autograft repair for primary proximal hypospadias with 30-degree or greater ventral curvature. *The Journal of urology.* 2017;198(3):680-6.
- Steven L, Cherian A, Yankovic F, Mathur A, Kulkarni M, Cuckow P. Current practice in paediatric hypospadias surgery; a specialist survey. *Journal of pediatric urology.* 2013;9(6):1126-30.
- Springer, A., Krois, W., & Horcher, E. (2011). Trends in hypospadias surgery: results of a worldwide survey. *European urology*, 60(6), 1184-9.
- Al-Adl AM, Aal AM, El-Karamany TM, Nouredin YA. Two-stage repair of proximal hypospadias with moderate to severe chordee using inner preputial skin graft: prospective evaluation of functional and cosmetic outcomes. *World journal of urology.* 2020;1-7.
- Pfistermüller KL, Manoharan S, Desai D, Cuckow PM. Two-stage hypospadias repair with a free graft for severe primary and revision hypospadias: a single surgeon's experience with long-term follow-up. *Journal of pediatric urology.* 2017;13(1):35-e1.
- Castagnetti M, El-Ghoneimi A. Surgical management of primary severe hypospadias in children: systematic 20-year review. *The Journal of urology.* 2010;184(4):1469-75.
- Faure A, Bouty A, Nyo YL, O'Brien M, Heloury Y. Two-stage graft urethroplasty for proximal and complicated hypospadias in children: A retrospective study. *J Pediatr Urol.* 2016; 12(5): 286.e1-286.e7.
- Fahmy O, Khairul-Asri MG, Schwentner C, Schubert T, Stenzl A, Zahran MH, Gakis G. Algorithm for optimal urethral coverage in hypospadias and fistula repair: a systematic review. *European urology.* 2016;70(2):293-8.
- Hayashi, Yutaro, and Yoshiyuki Kojima. "Current concepts in hypospadias surgery." *International journal of urology* 2008; 15.8 .651-664.
- Gershbaum MD, Stock JA, Hanna MK. A case for 2-stage repair of perineoscrotal hypospadias with severe chordee. *The Journal of urology.* 2002;168(4 Part 2):1727-9.