

Evaluation Of Intralesional Injection Of Botulinum Toxin Type A, Methotrexate, And Verapamil In Treatment Of Keloids: A Preliminary Study

Mohamed Ahmed Galal Reihan,¹ M.B.B.Ch Moustafa Sayed Ahmed Meky,¹ MD,
Mohamed Mahmoud Fareed,¹ MD.

* Corresponding Author:

Mohamed Ahmed Galal Reihan
doc.moh.rehan@gmail.com

Received for publication November 19, 2021; Accepted March 24, 2022;
Published online March 24, 2022.

Copyright The Authors published by Al-Azhar University, Faculty of Medicine, Cairo, Egypt. Users have the right to read, download, copy, distribute, print, search, or link to the full texts of articles under the following conditions: Creative Commons Attribution-Share Alike 4.0 International Public License (CC BY-SA 4.0).

doi: 10.21608/aimj.2022.106057.1660

¹Plastic Surgery Department, Faculty of Medicine, Al-Azhar University, Cairo, Egypt.

ABSTRACT

Background: Keloids are due to overgrowth of dermal collagen following trauma to the skin that usually cause major physical, psychological and cosmetic problems. Intralesional injection treatments show promising results and many agents have been used as single treatments or in combination to get the best result.

Aim of the study: To evaluate the clinical outcome of the three injectable drugs (botulinum toxin type A, methotrexate, and verapamil) in treatment of keloids.

Patients and Methods: This is a prospective comparative non-randomized clinical study including 20 patients with 30 keloid lesions divided into 3 groups A, B and C including 10 lesions each. Group A received intralesional injection of Botulinum toxin Type A (BTX-A) 2 U/cm², Group B was treated with Methotrexate (MTX) 1 mg/cm² and group C with Verapamil 0.125 mg/cm².

Results: The percentage of improvement of VSS was better in group A than group C which was statistically significant ($p=0.01$). Also, group B was better than group C in the percentage of improvement of VSS which was statistically significant ($p<0.01$), while, there was no statistically significant difference in the percentage of improvement between group A and group B ($p=0.233$).

Conclusion: This study supports the efficacy of the 3 mentioned drugs in treatment of keloids with better results obtained from intralesional injection of Botulinum Toxin A and Methotrexate than Verapamil.

Keywords: Keloid; Botulinum Toxin; Methotrexate; Verapamil

Disclosure: The authors have no financial interest to declare in relation to the content of this article. The Article Processing Charge was paid for by the authors.

Authorship: All authors have a substantial contribution to the article.

INTRODUCTION

Keloids are fibro-proliferative dermal conditions that can lead to pruritus, discomfort, and disfigurement. Keloids spread wider than the range of the original injury and have a persistent and long development against hypertrophic scars that are confined to the injury and can partially regress after rapid growth.¹

An unresolved concern remains the treatment of keloids. Intralesional injection, pressure therapy, radiation, excision, and sometimes combining some of the previously listed treatments have been identified in many therapeutic modalities.²

Treatment by intralesional injections have shown some good outcomes over in the form of improvement in keloid appearance and psychological well-being, but there is yet no definite protocol according to which intralesional agents are best for treatment of keloid.³

In recent years, some physicians are using BTX-A as a modality for prevention and treatment of keloids as

it decreases itching, discomfort, improves the texture, and decrease the size of keloids.⁴

Methotrexate (MTX) has been reported a few times in the literature as an alternative therapy for keloids. It affects the synthesis of thymidylate synthase which decreases the nucleotides that form DNA and RNA, affecting repair of nucleic acids which suppresses cell proliferation. Keloids are affected the most because of the increased cell growth rate.⁵

Verapamil has also been successfully applied for keloid therapy. Calcium channel blockers have been proven to reduce production of extracellular matrix in scars. Also, they modify fibroblast morphology by depolymerizing actin filaments due to increased secretion of pro-collagenase.⁶

MATERIALS AND METHODS

This is a prospective comparative non-randomized clinical study conducted at Al Azhar University hospitals including 20 patients with 30 keloid lesions. Patients below age of 15 and above age of 50,

patients receiving other treatment for keloid, pregnant, lactating females and patients with lesions more than 20 cm² were excluded from the study. Ethical approval was gained from the ethics unit of the Faculty of Medicine, Al-Azhar University, Cairo and informed agreements were gained from the included participants.

Lesions were divided to three treatment groups A, B and C including ten lesions each. Group (A) received four sessions of intralesional injection with BTX-A 2 U/cm² with a maximum total dose of 50 U/session separated by 2 months interval. Group (B) received 6 sessions of intralesional injection with Methotrexate (MTX) 1 mg/cm² with a maximum total dose of 20 mg/session separated by 1 month interval. Group (C) received 6 sessions of intralesional injection with Verapamil 0.125 mg/cm² with a maximum total dose of 2.5 mg/session with 1 month interval. Follow up was done for 1 month after the last session and assessment was done clinically, photographically and statistically according to improvement of Vancouver scar scale (VSS).

RESULTS

The study included 20 patients, 11 females (55%) and 9 males (45%), aging from 16-45 years with Mean age of 22.80 ± 8.50 years. Lesion sizes ranged from 5.0-20.0 cm² with the mean size of 11.0 ± 5.04 cm². Scar age ranged from 4.0-12.0 months with a mean of 7.90 ± 2.81 months. (table 1).

Regarding the total VSS, a statistically significant difference between before and after treatment in

	No.	%
Lesion size (cm²)		
Min. – Max	5.0 – 20.0	
Mean ± SD.	11.0 ± 5.04	
Median (IQR)	10.0 (6.0 – 15.0)	
Scar age (months)		
Min. – Max	4.0 – 12.0	
Mean ± SD.	7.90 ± 2.81	
Median (IQR)	7.50 (5.0 – 10.0)	

Table 1: Distribution of the studied lesions regarding characteristics (n = 30)

Total Vancouver scar scale	Treatment			F	P
	Group A (BTX-A) (n = 10)	Group B (MTX) (n = 10)	Group C (Verapamil) (n = 10)		
Pre-treatment					
Min. – Max.	5.0 – 11.0	5.0 – 11.0	5.0 – 11.0	0.247	0.783
Mean ± SD.	7.60 ± 2.12	8.10 ± 2.02	8.20 ± 1.99		
Median (IQR)	7.50 (6.0 – 9.0)	8.50 (6.0 – 10.0)	9.0 (7.0 – 9.0)		
Post-treatment					
Min. – Max.	2.0 – 6.0	1.0 – 5.0	4.0 – 8.0	8.952*	0.01*
Mean ± SD.	3.90 ± 1.52	3.30 ± 1.34	5.90 ± 1.45		
Median (IQR)	4.0 (2.0 – 5.0)	3.50 (2.0 – 4.0)	6.0 (5.0 – 7.0)		
Sig. between groups.	p ₁ = 0.625, p ₂ = 0.012*, p ₃ = 0.01*				
t ₀ (p)	12.333* (<0.01*)	7.856* (<0.01*)	7.667* (<0.01*)		

Table 2: Comparison between the treatment groups regarding total Vancouver scar scale

group A (p<0.01), group B (p<0.01) and group C (p<0.01). In the post treatment period, there was a statistically significant difference between Group A and C (p₂=0.012) and between Group B and C (p₃=0.01), while no statistically significant difference between group A and B was noticed (p₁=0.625). (Table 2).

Improvement of keloid scars after treatment was noticed clinically as well as statistically by calculating the percentage of improvement of the total VSS in all groups by varying degrees with better improvement in both group A and group B than group C. Good improvement after treatment was noticed in group A treated with BTX-A (figure1) with a mean improvement percentage of (49.83 ± 10.48). Group B treated with MTX also showed good improvement after treatment (figure2) with a mean percentage of (58.73 ± 15.75). While, group C treated with Verapamil showed a slightly less improvement (figure3) with a mean percentage of (27.45 ± 8.10).

The percentage of improvement of VSS was better in group A than group C which was statistically significant (p₂=0.01). Also, group B was better than group C in the percentage of improvement of VSS which was statistically significant (p₃<0.01), while there was no statistical difference in the percentage of improvement between group A and group B (p₁=0.233). (Table 3)

Total Vancouver scar scale	Treatment			F	P
	Group A (BTX-A) (n = 10)	Group B (MTX) (n = 10)	Group C (Verapamil) (n = 10)		
Improvement					
Min. – Max.	2.0 – 5.0	3.0 – 8.0	1.0 – 4.0	8.512*	0.01*
Mean ± SD.	3.70 ± 0.95	4.80 ± 1.93	2.30 ± 0.95		
Medan (IQR)	4.0 (3.0 – 4.0)	4.50 (3.0 – 7.0)	2.0 (2.0 – 3.0)		
Sig. between groups.	p ₁ = 0.185, p ₂ = 0.072, p ₃ = 0.01*				
% Improvement					
Min. – Max.	33.33 – 66.67	37.50 – 80.0	20.0 – 44.44	18.405*	<0.01*
Mean ± SD.	49.83 ± 10.48	58.73 ± 15.75	27.45 ± 8.10		
Medan (IQR)	47.73 (42.86 – 60.0)	52.78 (50.0 – 77.78)	24.75 (22.22 – 30.0)		
Sig. between groups.	p ₁ = 0.233, p ₂ = 0.01*, p ₃ < 0.01*				

Table 3: Comparison between the treatment groups regarding improvement in total Vancouver scar scale

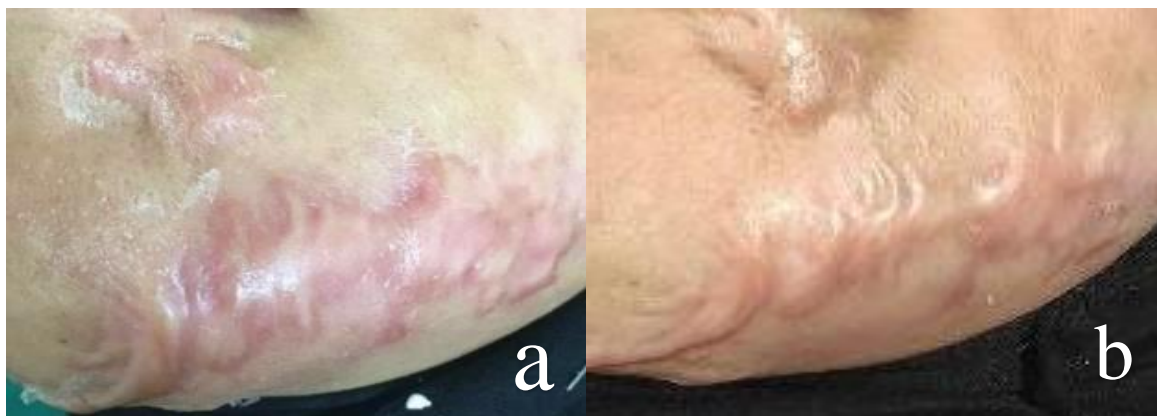


Fig. 1: before (a) and 1 month after (b) treatment with BTX-A for 4 sessions.

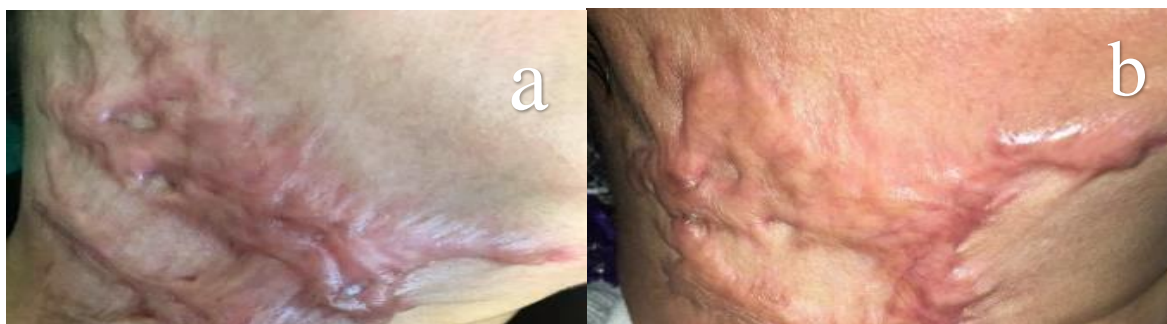

Fig. 2: before (a) and 1 month after (b) treatment with MTX for 6 sessions.

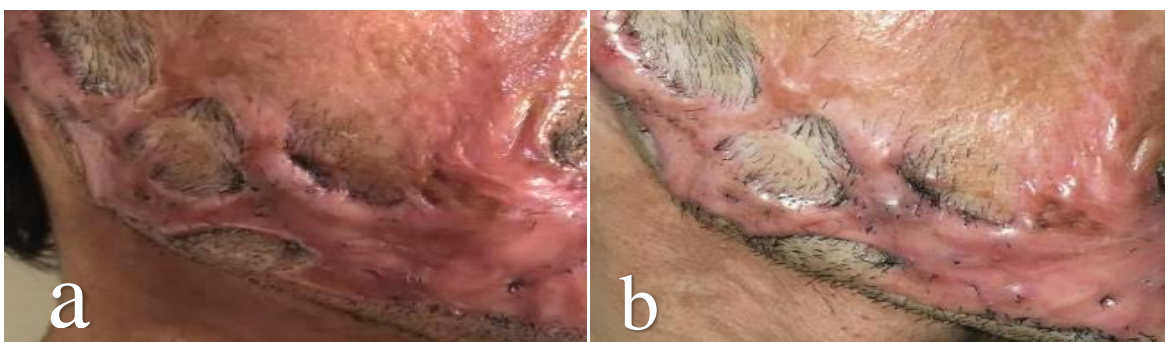

Fig. 3: before (a) and 1 month after (b) treatment with Verapamil for 6 session

DISCUSSION

Keloid is a benign proliferating tumour of the dermal connective tissue that occurs in genetically susceptible individuals as a result of an excessive tissue reaction to cutaneous trauma and does not disappear spontaneously.⁷

Keloid is a common yet difficult-to-treat condition. Keloids have been treated with a variety of methods, however there is no definitive treatment that eliminates keloids.⁸

This is the first study to compare the efficacy between intralesional injection Botulinum toxin type A (BTX-A), Methotrexate (MTX) and Verapamil in management of keloids.

Twenty patients aging from 16-45 years with thirty keloid lesions were included in this study. Ten lesions were treated with BTX-A every 2 months for four sessions, ten lesions were treated with MTX monthly for six sessions and ten lesions were treated with Verapamil monthly for six sessions. Lesions treated with BTX-A showed (49.83 ± 10.48) percent improvement and lesions treated with MTX showed (58.73 ± 15.75) percent improvement. While, Verapamil treated lesions only showed (27.45 ± 8.10) percent improvement after treatment.

In a prior study by Ghonaim⁹, IL BTX-A was administered at one-month intervals (dosage of 2.5 U/cm³) for 3 months, and good results was observed in 48 percent of scars which is agreement with our results.⁹

Other study conducted by Zhibo *et al.*¹⁰, twelve patients with single or multiple keloids were given BTX-A every three months for nine months. After one year of follow-up, excellent results were seen in three patients, good results in five patients, while in four patients, fair results were noticed.¹⁰

Al-Khateeb *et al.*¹¹ made a study on 40 patients with of hypertrophic scars comparing intralesional injection of TAC and Methotrexate. His results suggested good improvement in both treatment modalities with TAC being more effective than Methotrexate.¹¹

A study by Sharquie *et al.*¹² who combined Methotrexate and TAC in treatment of keloids with or without surgical debulking and the result of the intralesional injection treatment without debulking was about 50 percent improvement.¹²

A study carried out by Abedini *et al.*¹ showed that verapamil had very low effects on VSS scores (7.33%) percent compared to triamcinolone (68.81%).¹

Saki *et al.*¹³, in A study comparing the effect of intralesional triamcinolone and verapamil, combined with cryotherapy on scar improvement, showed that both groups had a decrease in height and texture, but better results was obtained with TAC.¹³

CONCLUSION

Treatment of keloids is difficult, and no standard treatment has been established yet. our study supports the effect of intralesional BTX-A, MTX and Verapamil in treatment of keloids with better results obtained from Botulinum Toxin A and Methotrexate than Verapamil. More studies including larger groups and longer follow up periods are required to fully understand the effect of the three mentioned drugs in treatment of keloids.

REFERENCES

1. Abedini R, Sasani P, Mahmoudi HR, Nasimi M, Teymourpour A, Shadlou Z. Comparison of intralesional verapamil versus intralesional corticosteroids in treatment of keloids and hypertrophic scars: A randomized controlled trial. *Burns*. 2018;44(6):1482-8.
2. Kant SB, van den Kerckhove E, Colla C, Tuinder S, van der Hulst RRWJ, Piatkowski de Grzymala AA. A new treatment of hypertrophic and keloid scars with combined triamcinolone and verapamil: a retrospective study. *Eur J Plast Surg*. 2018;41(1):69-80.
3. Trislina, PA, Lazzeri, D, Su, W, Xi, W, Zheng, Z, Ke, L, Min, P, Feng, S, Zhang, YX, and Persichetti, P. Recent developments in the use of intralesional injections keloid treatment. *Archives of plastic surgery*.2014;41(6): 620-9.
4. Kasyanju Carrero LM, Ma WW, Liu HF, Yin XF, Zhou BR. Botulinum toxin type A for the treatment and prevention of hypertrophic scars and keloids: Updated review. *J Cosmet Dermatol*. 2019;18(1):10-15.
5. Oliveira, TG, Vasconcelos, RCF, Odo, L, and Odo, MEY. Hypertrophic scars and keloids: Treatment with surgery and methotrexate injections: A pilot study. *Surgical and Cosmetic Dermatology*.2014;6:233-7.
6. Khattab FM, Nasr M, Khashaba SA, Bessar H. Combination of pulsed dye laser and verapamil in comparison with verapamil alone in the treatment of keloid. *J Dermatolog Treat*. 2020;31(2):186-90.
7. Butler PD, Longaker MT, Yang GP. Current progress in keloid research and treatment. *J Am Coll Surg*. 2008;206(4):731-41.
8. Kontochristopoulos G, Stefanaki C, Panagiotopoulos A, et al. Intralesional 5-fluorouracil in the treatment of keloids: an open clinical and histopathologic study. *J Am Acad Dermatol*. 2005;52(3 Pt 1):474-9.
9. Ghonaim N. Comparative study of the 80% trichloroacetic acid multiple puncture technique versus botulinum toxin type A in the treatment of keloid scars. *Egypt J Dermatol Venereol*.2013;33:22.

10. Zhibo X, Miaobo Z. Intralesional botulinum toxin type A injection as a new treatment measure for keloids. *Plast Reconstr Surg.* 2009;124(5):275e-7e.
11. Reda Saleh Al-Khateeb, S., Mohamed Zaki, A., Mahmoud El-Rewiny, E. COMPARISON OF INTRALESIONAL METHOTREXATE WITH TRIAMCINOLONE ACETONIDE IN TREATMENT OF HYPERTROPHIC SCARS. *Al-Azhar Medical Journal*, 2021; 50(3): 2309-16.
12. Sharquie KE, Nuaimi AA, and Al-kadhi MR. Debulking of Keloid Combined with Intralesional Injection of Methotrexate and Triamcinolone versus Intralesional Injection of Methotrexate and Triamcinolone. *J Clin Dermatol Ther.* 2014;1(3):8-21.
13. Saki N, Mokhtari R, Nozari F. Comparing the Efficacy of Intralesional Triamcinolone Acetonide With Verapamil in Treatment of Keloids: A Randomized Controlled Trial. *Dermatol Pract Concept.* 2019;9(1):4-9.