



Regenerative Potentiality of Concentrated Growth Factors with Partially and Completely Amputated Pulp Tissue (Histological Study)

Abeer Ezzat,^{1*} Heba A. Adawy,² Mena F. Abd Allah³

Codex : 01/22.04

azhardentj@azhar.edu.eg

http://adjg.journals.ekb.eg

DOI: 10.21608/adjg.2022.76009.1376

Oral Medicine & Surgical Sciences
(Oral Medicine, Oral & Maxillofacial
Surgery, Oral Pathology, Oral Biology)

ABSTRACT

Purpose: This study aimed to investigate the effect of concentrated growth factors (CGF) with partially and completely amputated pulp tissue on the histologic outcome of dentin-pulp complex regeneration in immature dogs' teeth with non-infected pulp and apical tissue. **Materials and Methods:** In this study fifty six immature teeth in four mongrel dogs were involved and simple randomization design was used. The teeth were divided into four groups; group (I): the teeth were left with no treatment (negative control), group (II): the teeth underwent complete pulp extirpation where blood clots filled the root canals (positive control), group (III): the root canals were packed with CGF after complete pulp extirpation and group (IV): the pulp was partially removed leaving the last 1–4mm and the root canals were packed with CGF. The animals were euthanized at 1 and 3 months and samples were processed for histological analysis. **Results:** The best results appeared in CGF treated groups, where the immature roots continued their development in a way simulating the normal and this was represented histologically in closure of the root apex, increasing the root canal wall thickness and ingrowth of soft tissue into the root canals. However, the pulp architecture and pulp-dentin relation appeared better when the pulp was partially removed. **Conclusion:** Dentin-pulp regeneration of the immature teeth can be promoted by CGF with faster root development and better pulp architecture when the apical 1–4mm of the pulp tissues are left.

KEYWORDS

Regeneration,
Concentrated Growth Factors,
Partially Amputated Pulp Tissue.

- Paper extracted from doctor thesis entitled. Regenerative Potentiality of Concentrated Growth Factors alone and with Partially Amputated Pulp Tissue
- 1. Assistant Lecturer of Oral and Dental Biology, Faculty of Dental Medicine for Girls, Al-Azhar University, Cairo, Egypt
- 2. Professor and Head of Oral and Dental Biology Department, Faculty of Dental Medicine for Girls, Al-Azhar University, Cairo, Egypt
- 3. Lecturer of Oral and Dental Biology, Faculty of Dental Medicine for Girls, Al-Azhar University, Cairo, Egypt

* Corresponding author email: drabeer84@yahoo.com

INTRODUCTION

The pulp tissue is a unique connective tissue with initiative, nutritive, formative, protective and reparative functions. Having a limited ability to expand, as it is surrounded by hard tissue leads to pulp necrosis when inflammation occurs which requires removal of the pulp during endodontic treatment. When the dental pulp is lost, the tooth becomes brittle and liable to fracture affecting quality the patient's life ⁽¹⁾.

Dentin-pulp regeneration has been broadly applied in dentistry and has been proven to stimulate continuous formation of roots of necrotic developing teeth. Various different methods have been developed with the purpose of promoting the regeneration of soft and hard tissues, such as the use of biomaterials ⁽²⁾.

Blood concentrates are promising relevant products offering an alternative source of minimally invasive autologous regeneration. Concentrated growth factors (CGF) are an advanced third generation of platelet concentrates composed of 100% autologous fibrin and rich in proteins and growth factors from autologous leucocytes and platelets. Preparation of CGF appears simpler than that of platelet-rich plasma (PRP), or platelet-rich fibrin (PRF) and also it does not need any additives ⁽³⁾. Moreover, there were other studies that have evaluated the effect of CGF on histologic outcome of dentin-pulp regeneration ^(4,5). Accordingly, as well this study had used histologic analysis as an aid measure for root completion.

Therefore, the purpose of this paper was to demystify various hypotheses as well as investigate the effect of CGF with partially and completely amputated pulp tissue on the histologic outcome of dentin-pulp regeneration in immature teeth.

MATERIAL AND METHODS

Animals

A total of 4 mongrel dogs aged 6-8 months were selected for the study. The dogs were of both sexes and were clinically normal. Animals were

quarantined in separate cages with good ventilation, normal humidity and fed soft food to avoid fracture of teeth after root canal treatment in the department of Veterinary Surgery, the Veterinary Hospital in El Abbasia. Animals were examined and kept under observation for 2 weeks before being used as experimental animals. This study was approved by the Research Ethics Committee (REC) of the Faculty of Dental Medicine for Girls, Al-Azhar University with code (REC-B1-19-02). This study involved 56 teeth in 4 dogs (i.e.14 teeth in each dog). In each dog the teeth (anterior, premolars and molars) were randomly divided into four groups; group (I): the teeth were left with no treatment (negative control) (N= 2), group (II): the teeth underwent complete pulp extirpation where blood clots filled the root canals (positive control) (N= 4), group (III): the root canals were packed with CGF after complete pulp extirpation (N= 4) and group (IV): the pulp was partially removed leaving the last 1-4mm and the root canals were packed with CGF (N= 4). Therefore, in 4 dogs group (I) involved 8 teeth, group (II) involved 16 teeth, group (III) involved 16 teeth and group (IV) involved 16 teeth.

Preparation of CGF

10 mL of venous blood was collected from each dog in sterile Vacuette tubes without anticoagulant solutions that was sufficient to produce an amount of CGF for 14 teeth (i.e. 40 mL of venous blood from 4 dogs were sufficient to produce an amount of CGF for 56 teeth). The tubes were immediately centrifuged by MEDIFUGE™ device (Silfradent, Sofia, Italy) with a special program of centrifugation, including: 30sec -acceleration, 2min - 2700 rpm, 4min - 2400 rpm, 4min - 2700 rpm, 3min - 3000 rpm, 36sec - deceleration and stop. This resulted in 4 different phases which were superior liquid phase (Serum), interim phase (Fibrin buffy coat), liquid phase (Growth factors), and lower phase (Red blood) ⁽⁶⁾. (Fig. 1)

The CGF glue which is rich in growth factors was taken carefully from the test tubes with tweezers and the two phases were cut off with

microsurgical scissors where the center and bottom layers connected. When the CGF glue was separated out, a quantity of growth factors were located on the interface between the CGF glue layer and the erythrocyte layer. Therefore, a certain amount of erythrocytes was retained when doing the separation to ensure the content of the growth factors. The CGF glue was pressed between two gauzes, thereby squeezing out the liquid elements within it and obtaining the CGF membrane. Then, obtained CGF was minced into pieces of 1~2 mm⁽⁷⁾.




Figure (1) Four blood phases obtained by centrifuge process; phase (1): Serum, phase (2): Fibrin buffy coat, phase (3): Growth factors, and phase (4): Red blood.

Procedures

All experimental procedures were conducted under a clean protocol with the use of sterile materials and equipment. General anesthesia was administered after fasting the dogs for 12 hours. The dogs were premedicated by using atropine sulphate (0.1 mg/kg) injected subcutaneously and Xylazine HCL (1 mg/kg) injected intramuscularly 15 minutes before the initiation of the procedure. The anesthesia was induced by using Ketamine HCL injected intravenous through the cannula in the cephalic vein at a dose of 5 mg/kg by weight. The anesthesia was maintained by using Thiopental Sodium 2.5 mg/kg at a dose of 3 mg/kg by weight injected intravenously as incremental doses⁽⁸⁾.

All teeth were examined radiographically to confirm incomplete root formation and to establish base line working length for further comparison. Endodontic access cavity was done in all experimental teeth using size #2 round carbide bur and stone bur in conventional speed hand piece mounted on low speed electric micro motor. To avoid teeth impairment from heat during preparation, the teeth and cutting instruments were irrigated with sterile normal saline solution. The pulp tissue in group II was completely extirpated with sterile barbed broaches. This procedure resulted in filling of the canal with fresh blood from the periapical tissues and formation of a blood clot which filled the coronal 2-3mm of the canal space. The root canals were packed with CGF in both group III and group IV but complete pulp extirpation was done in group III, while the last 1-4mm of pulp tissues were left in the root canals in group IV. No over instrumentation beyond the apical end was performed in any of these specimens to induce bleeding from periapical tissues. No root irrigation was done after the removal of the pulp^(2,5).

All of teeth in experimental groups were then closed by MTA which was mixed according to the manufacturer instructions and inserted into the canal by hand plugger to form MTA orifice plug. Glass ionomer filling was used to seal the remaining part of the access cavity⁽⁹⁾.

Sample collection

After 1 and 3 months all animals were euthanized using anesthetic overdose (pentobarbital sodium and phenytoin sodium) and postoperative radiographs were taken. Jaws were separated and bone segments including the control and experimental teeth were resected. They were prepared for light microscopic examination using hematoxylin-eosin staining (H&E). Therefore, in this study root length evaluation was done based on histologic point of view after 1 and 3 months in all animals.

Sample preparation for histological examination

Teeth and surrounding periapical tissues were fixed using 10% buffered formalin solution for at least 48 hours. The samples were demineralized using solutions (25% formic acid and 10% trisodium citrate) for 6 months. After decalcification, samples were dehydrated by passing them through increasing concentrations of ethyl alcohol (from 70 to 100%). Finally, once the water has been replaced by 100% alcohol, the alcohol was replaced with xylene, which is miscible with alcohol. After dehydration, samples were embedded in paraffin blocks and sectioned in bucco-lingual sections of 6µm thickness by microtome. The obtained sections were stained using hematoxylin and eosin (H&E) stain and were examined by light microscope ⁽⁵⁾.

RESULTS

Histological Results:

Group I (At one and three months):

In this group the dentin and pulp form a single unit where they appear closely interconnected to each other. This normal pulp from naturally developing teeth appeared formed of regularly arranged connective tissues with abundant fibroblasts, an extracellular matrix, numerous blood capillaries and a characteristic odontoblast layer situated at the interface of pulp and dentin and arranged in a palisade-like pattern. Thick canal walls, narrowing of root

canals and signs of physiologic apical closure were more obvious at 3 months than at 1 month. (Fig. 2: A&B)

The experimental groups (Group II, III & IV):

At one month:

Group II showed vital soft tissue only in the apical part of the root and there was no evidence of thickening of the root canal walls. Apical closure if present was limited and accompanied by formation of bone like tissue. (Fig. 3-C)

Group III showed a physiologic apical narrowing with apical deltas and regenerated pulp like tissues were observed within the root canals. Besides, abundant large dilated blood vessels engorged with blood were more obvious than group IV and extended from apical foramen to full length of pulp like tissue. Few odontoblast-like cells without polarity were observed. (Fig. 3-D)

Group IV showed hard tissue formation and signs of apical closure which was more obvious than group III. The canals of these teeth were packed with well-organized vascularized pulp tissues, showing considerable numbers of fibroblasts, an extracellular matrix, some newly formed capillaries and blood vessels engorged with blood that extend from amputated pulp to the level of the MTA. Although, a layer of odontoblast-like cells exhibited little of the polarized pattern possessed by normal odontoblast layer. (Fig. 3- E)

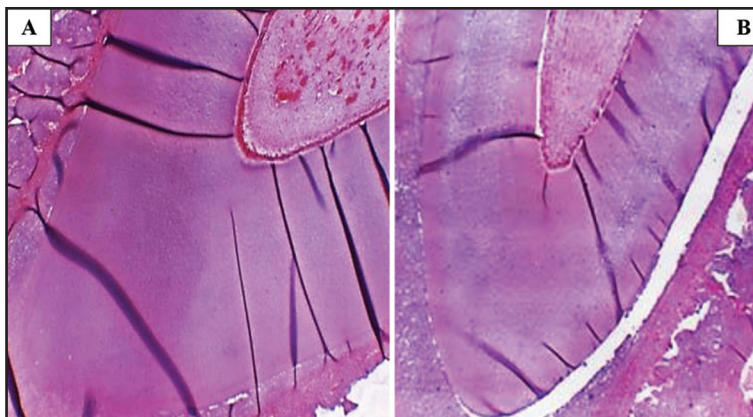


Figure (2) Photomicrographs of the apical third of the root in group I (negative control) after 1 month (A), and 3 months (B) showing normal architecture of pulp tissue, normal odontoblast cells, normal dentin and signs of apical closure (H&E, X40).

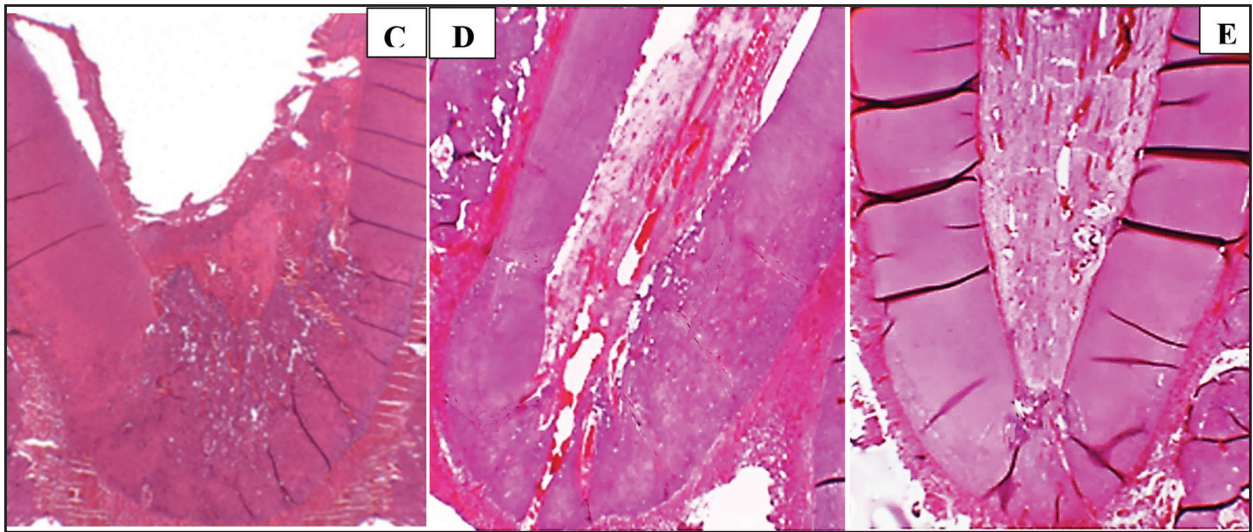


Figure (3) Photomicrographs of the apical third of roots at one month: (C) group II, (D) group III and (E) group IV (H&E, X40).

At three months:

In group II, the apical foramen had not yet closed and no evidence of root canal wall thickening. In middle third and small apical area of the canal, the newborn pulp like tissue was observed. This connective tissue appeared, as compared with group III and IV, separated from the dentinal walls, more irregular, loosely arranged and contained newly formed blood vessels and fibroblasts. Nonetheless, few odontoblast-like cells surrounding pulp like tissue were observed. (Fig. 4-F)

In both group III and group IV, the histological

results revealed complete closure of the apices by calcified tissues, root canal walls thickening through formation of considerable thickness of dentin like mineralized tissue between the wall of the canal and the regenerated pulp and the dentinal tubules extended processes tightly connected to the regenerated dentin without gaps with obvious incremental lines. The pulp in group III appeared compact in the center and the loose at periphery with odontoblast-like cells showing some vacuolations, while in group IV the pulp appeared more compact with well-organized odontoblast-like cells and thick well-formed layer of predentin. (Fig. 4: G&H)

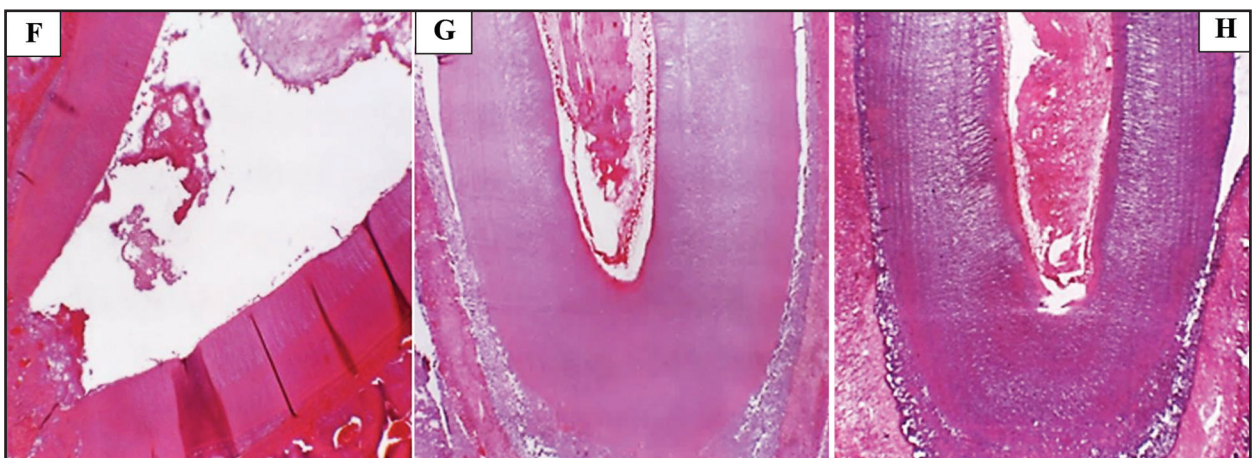


Figure (4) Photomicrographs of the apical third of roots after three months: (F) group II, (G) group III and (H) Group IV (H&E, X40).

DISCUSSION

In order to investigate a new dental treatment modality, experimental animals with teeth that mimic human teeth in anatomy, physiology, histology and pathology are used. For this reason, dogs are considered as an ideal animal model in the dental field as their biological processes like apical repair occur in a way simulating that of human, beside their availability and their low cost^(10,11). Also, dogs' teeth are characterized by their relatively large size, easy accessibility and availability for x-ray follow up. Moreover the growth rate of dogs is about six times that of human, so the repair process occurs faster which is more advantageous for research purpose. The age of the used experimental dogs was between 6-8 months where the dogs can tolerate general anesthesia for several times and their teeth are permanent with immature developing roots^(8,11).

Complete root formation occurs after eruption of human teeth with a considerable period of time which makes the teeth susceptible to pulp necrosis and apical periodontitis in response to trauma or caries. Such conditions prevent further root development and result in thin weak dentinal walls liable to fracture. As the pulp of such teeth becomes necrotic and accompanied by inflammation of adjacent supporting tissues, hence comes the need for regenerative endodontic procedures (REPs) to form new tissue inside the root canal and to complete root formation to strengthen such teeth⁽¹²⁾.

The healing process (repair or regeneration) in the root canal starts with blood clot formation which is highly rich in stem cells. During REPs, the blood clot has two crucial roles; one of them is related to its content of growth factors which are released gradually recruiting stem cells to the area and inducing their proliferation and differentiation. The second role represents its supporting action where it acts as three dimensional physical scaffold^(13,14).

Interestingly, REPs in developing teeth with apical periodontitis and non-vital pulp have demonstrated various patterns of healing when

examined histologically and radiographically. Preceding studies on the experimental animals have revealed connective tissue which either form soft tissues like pulp or periodontal ligament or form hard tissues like bone or cementum inside the root canals⁽¹⁴⁾.

Sometimes, remnants of healthy pulp and periodontal tissue exist apically in endodontically infected teeth preserving the regenerative power in the immature root canals as the epithelial root sheath of Hertwig (HERS) and dental papilla are intact^(2,12,14). Migration of cells from the intact pulp occurs resulting in formation of the amputated portion of the pulp again^(6,10,14).

The choice of CGF was attributed to its autologous nature to overcome the immune obstacles. It has a 3D architecture conducive with stem cell proliferation and differentiation and contains bioactive signaling molecules⁽⁵⁾. Concentrated growth factors (CGF) are advanced third generation of autologous plasma extracts which contain abundant erythrocytes, leucocytes and platelets⁽¹⁵⁾.

Diverse group of growth factors as PDGF, TGF- β 1, EGF, BDGF, IFG-I, FGF and VEGF are concentrated within CGF. Also, CGF contains Chemokine receptor 4 (CXCR4) that induce cell proliferation, chemotaxis and formation of new blood vessels. Other results showed that CGF layers have great amount of CD34-positive cells than in RBC layers, which have been proven to play a significant role in formation of new blood vessels and vascular maintenance^(16,17).

After application of CGF, the strong fibrin gel does not dissolve quickly and it is slowly remodeled in analogous way to a normal blood clot⁽¹⁵⁾. In comparison with the other platelet preparations, CGF possesses superior viscosity and superior adhesive strength. This is attributed to alternated and controlled centrifugation speed during preparation process of CGF that makes the formation of fibrin from fibrinogen and its polymerization more effective than using a single centrifugation speed. Furthermore, the differential centrifugation steps

can lead to continuous platelets' collision and rupture which make the discharge of growth factors in a somewhat slow rate. Therefore, this permits isolation of fibrin network which is thicker, larger and containing more growth factors than the other platelet preparations^(18,19).

Moreover, the fibrin blocks are of higher cohesion because of the great amount of factor XIII, thrombin and fibrinogen. Thrombin activates factor XIIIa where the fibrin matrix is stabilized and protected from plasmin disintegration by the aid of this factor. Subsequently, growth factors are protected from proteolysis and their activity duration is prolonged by increased stability and tensile strength of the stiff fibrin matrix. The prolonged time of growth factors' activity produces synergy of growth factor and promotes cell proliferation and differentiation. It was revealed that the discharge of CGF was preserved up to 14 days with the highest level on the fifth day. TGF- β 1 is released from CGF over a persistent duration of time for at least 13 days which is important for odontoblast differentiation and dentin matrix secretion⁽¹⁸⁻²⁰⁾.

Angiogenesis has a major function during repair of tissue and homeostasis, hence it is the source of oxygen, nutrition and great metabolic supplies for the maintenance and ingrowth of the new tissues⁽²¹⁾. Concentrated growth factors (CGF) are normal reservoir of VEGF and various additional pro-angiogenic factors. As estimated before, VEGF can promote differentiation of stem cells of dental pulp into endothelial cells owing to their extremely angiogenic effect⁽²²⁾. Other studies have reported the CGF biological effects on the stem cells of apical papilla, and it was found that CGF can promote the migration, proliferation and differentiation of the stem cells of apical papilla^(6,23).

Collectively, histologic analysis has revealed better dentin-pulp regeneration in the CGF and partially amputated pulp group as compared with the CGF group, with thicker dentin and a better architecture of dental pulp and odontoblast-like cells.

CONCLUSION

Regeneration of dentin-pulp complex in immature developing teeth with irreversible pulpitis is highly possible, if intact healthy pulp remnants are kept. In such conditions, care should be taken during induction of bleeding to avoid disturbing the existing pulp remnants and to avoid apical papilla separation. Additionally, CGF can enhance the persistent development of the immature dogs' teeth. Consequently, effective combination of bio-scaffold, chemotactic factors and growth factors, CGF can act as a golden biomaterial, because of its powerful regulatory criteria that enhance the regeneration of dental pulp during dental treatment.

DECLARATION

No fund was received for this study.

No conflicts of interest.

RECOMMENDATION

Additional investigations are required to characterize the suitable efficient procedure associated with the pretreatment condition of the periapical tissues and dental pulp.

ACKNOWLEDGMENTS

First I have to thank Allah for supporting me throughout my life. I would like to express my grateful thanks to Dr Somia, assistant Lecturer of Oral and Dental Biology, Faculty of Dental Medicine for Girls, Al-Azhar University, Cairo, Egypt, for helping me complete the lab work.

REFERENCES

1. Morotomi T., Washio A., Kitamura C. Current and future options for dental pulp therapy. *Jpn Dent Sci Rev.* 2019; 55: 5-11.
2. Torabinejad M., Alexander A., Vahdati S. A., Grandhi A., Baylink D., Shabahang S. Effect of Residual Dental Pulp Tissue on Regeneration of Dentin-pulp Complex: An In Vivo Investigation. *J Endod.* 2018; 44:1796-801.

3. Ngah N. A., Ratnayake J., Cooper P. R., Dias G. J., Tong D. C., Mohd Noor S.N.F., et al. Potential of Lyophilized Platelet Concentrates for Craniofacial Tissue Regenerative Therapies. *Molecules*. 2021; 26: 1-12.
4. Xu F., Qiao L., Zhao Y., Chen W., Hong S., Pan J., et al. The potential application of concentrated growth factor in pulp regeneration: an in vitro and in vivo study. *Stem Cell Res Ther*. 2019; 10: 1-16.
5. Jang J. H., Moon J. H., Kim S. G., Kim S. Y. Pulp regeneration with hemostatic matrices as a scaffold in an immature tooth minipig model. *Sci Rep*. 2020; 10: 1-11.
6. Qiao J., Duan J., Zhang Y., Chu Y., Sun C. The effect of concentrated growth factors in the treatment of periodontal intrabony defects. *Future Sci OA*, 2016; 2-4.
7. Nityasri A. S., Pradeep K. Y. Role of CGF (Concentrated Growth Factor) in periodontal regeneration. *J Dent Health Oral Disord Ther*. 2018; 9: 350-2.
8. El Halaby H. M., Abu Seida A. M., Fawzy M. I., Farid M. H., Bastawy H. A. Evaluation of the regenerative potential of dentin conditioning and naturally derived scaffold for necrotic immature permanent teeth in a dog model. *Int J Exp Pathol*. 2020; 101: 264-76.
9. Widbiller M., Schmalz G. Endodontic regeneration: hard shell, soft core. *Odontology*. 2020; 109: 303-12.
10. Kaushik S. N., Kim B., Walma A. M. C., Choi S. C., Wu H., Mao J. J., et al. Biomimetic microenvironments for regenerative endodontics. *Biomater Res*. 2016; 20: 1-12.
11. Iohara K., Murakami M., Nakata K., Nakashima M. Age dependent decline in dental pulp regeneration after pulpectomy in dogs. *Exp Gerontol*. 2014; 52:39-45.
12. Edanami N., Yoshiba K., Shirakashi M., Belal R. S. I., Yoshiba N., Ohkura N., et al. Impact of remnant healthy pulp and apical tissue on outcomes after simulated regenerative endodontic procedure in rat molars. *Sci Rep*. 2020; 10: 1-10.
13. Guo S., Dipietro L.A. Factors affecting wound healing. *J Dent Res*. 2010; 89: 219-29.
14. Digka A., Sakka D., Lyroudia K. Histological assessment of human regenerative endodontic procedures (REP) of immature permanent teeth with necrotic pulp/apical periodontitis: a systematic review. *Aust Endod J*. 2020; 46: 140-53.
15. Hong S., Li L., Cai W., Jiang B. The potential application of concentrated growth factor in regenerative endodontics. *Int Endod J*. 2019; 52: 646-55.
16. Banu Ö. K. The Use of Concentrated Growth Factor in Dentistry. *Acta Sci Den Sci*. 2018; 2: 92-3.
17. Rodella L. F., Favero G., Boninsegna R., Buffoli B., Labanca M., Scari G., et al. Growth factors, CD34 positive cells, and fibrin network analysis in concentrated growth factors fraction. *Microsc. Res. Tech*. 2011; 74:772-7.
18. Bonazza V., Borsani E., Buffoli B., Castrezzati S., Rezzani R., Rodella L.F. How the different material and shape of the blood collection tube influences the Concentrated Growth Factors production. *Microsc. Res. Tech*. 2016; 79:1173-8.
19. Isoke K., Watanebe T., Kawabata H., Kitamura Y., Okudera T., Okudera H., et al. Mechanical and degradation properties of advanced platelet-rich fibrin (A-PRF), concentrated growth factors (CGF), and platelet-poor plasma-derived fibrin (PPTF). *Intl J Implant Dent*. 2017; 3: 1-6.
20. Kshirsagar J. T., Rubine S. Innovation in regeneration–Concentrated growth factor. *Intl J Appl Dent Sci*. 2017; 3: 206-8.
21. Austah O., Joon R., Fath W. M., Chrepa V., Diogenes A., Ezeldeen M., et al. Comprehensive characterization of 2 immature teeth treated with regenerative endodontic procedures. *J Endod*. 2018; 44: 1802-11.
22. Jin R., Song G., Chai J., Gou X., Yuan G., Chen Z. Effects of concentrated growth factor on proliferation, migration, and differentiation of human dental pulp stem cells in vitro. *J Tissue Eng*. 2018; 9: 1-10.
23. Hong S., Chen W., Jiang B. A comparative evaluation of concentrated growth factor and platelet-rich fibrin on the proliferation, migration, and differentiation of human stem cells of the apical papilla. *J Endod*. 2018; 44: 977-83.