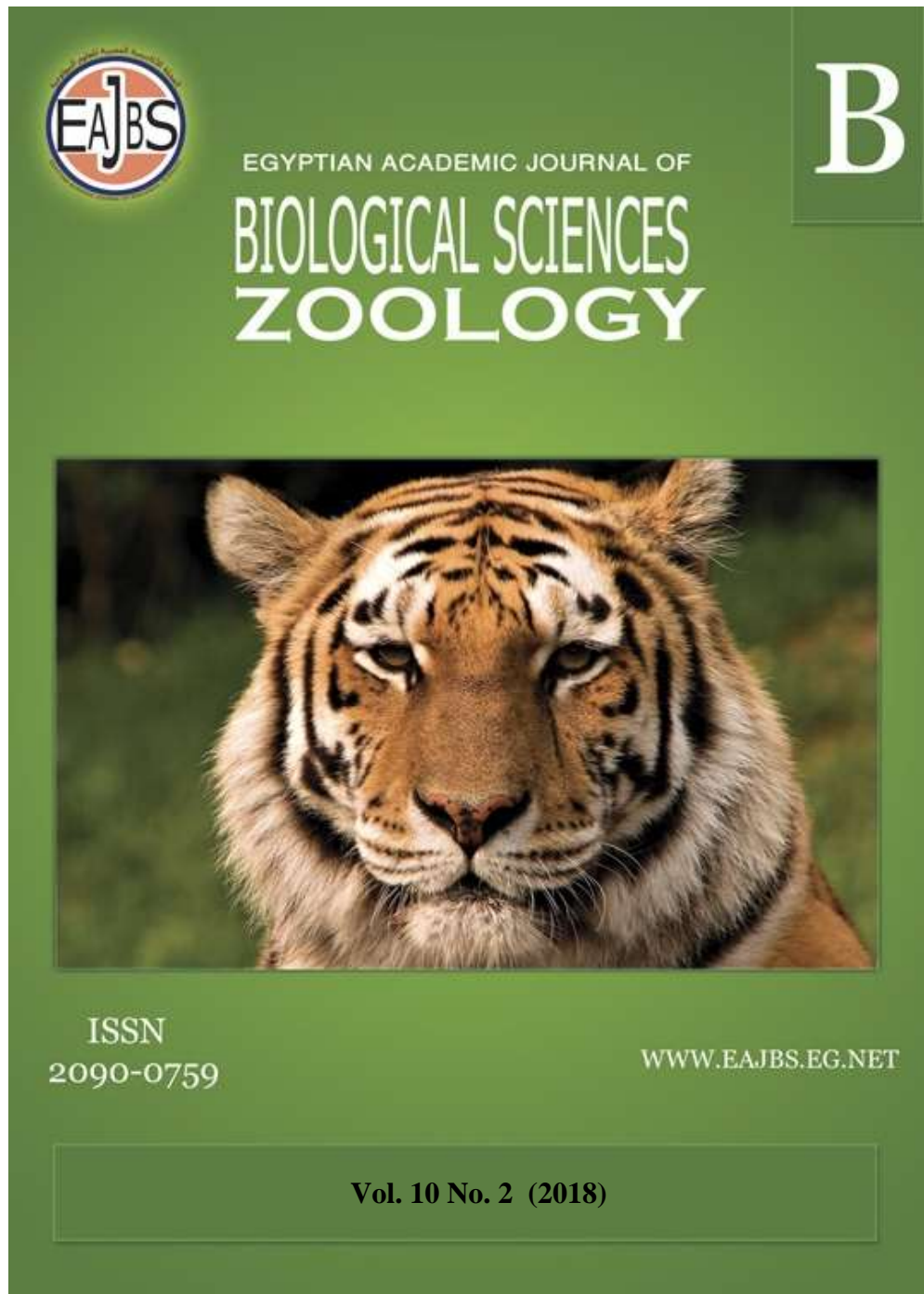


**Provided for non-commercial research and education use.  
Not for reproduction, distribution or commercial use.**



Egyptian Academic Journal of Biological Sciences is the official English language journal of the Egyptian Society of Biological Sciences, Department of Entomology, Faculty of Sciences Ain Shams University.

The Journal publishes original research papers and reviews from any zoological discipline or from directly allied fields in ecology, behavioral biology, physiology & biochemistry.

[www.eajbs.eg.net](http://www.eajbs.eg.net)



**Effects of Fullerene C<sub>60</sub> and Fruit Extract of *Balanites aegyptiaca* Plant on the Nephrotoxicity and Hematotoxicity Induced by Doxorubicin in Diabetic Male Albino Rats.**

**Abd EL-Raheim A. EL-Shater; Muhammad M. M. A. Salman; Naglaa R. A. Kasem and Mariam A. Fawy**

Zoology Department, Faculty of Science; South Valley University, Qena

E.Mail: [salman2\\_2014@yahoo.com](mailto:salman2_2014@yahoo.com)

**ARTICLE INFO**

Article History

Received:29/9/2018

Accepted:19/10/2018

**Keywords:**

Diabetic rats,  
Doxorubicin,  
Fullerene and  
*Balanites aegyptiaca*.

**ABSTRACT**

There was a relationship between hyperglycemia and pharmacokinetic of toxicity of doxorubicin that leads to increasing oxidative stress on cells. This study was aimed to detect the curative effect of some antioxidants drugs (fullerene C<sub>60</sub> and mesocarp fruit extract of *Balanites aegyptiaca*) on the hematological and biochemical of kidney function parameters after induced by diabetes and toxicity with doxorubicin on the rats. nine groups of adult male albino rats were established (n= 8). The first group (Gp. 1) was served as a normal group. Gp. 2 was injected intraperitoneal (i.p.) with streptozotocin at a single dose (45 mg/kg body weight). Diabetic rats (Gp. 3) were injected intraperitoneal (i.p.) with doxorubicin at the dose (5mg/kg body weight) for three days. Diabetic rats (Gp. 4) was given orally fullerene C<sub>60</sub> daily at the dose (4 mg/kg body weight). Diabetic rats (Gp. 5) treated orally by mesocarp fruit extract of *Balanites aegyptiaca* at dose (1.5ml/kg. body weight). Diabetic rats (Gp. 6) treated orally with fullerene C<sub>60</sub> plus mesocarp fruit extract of *Balanites aegyptiaca*. Diabetic rats (Gp. 7) intoxicated DOX treated orally with fullerene C<sub>60</sub>. Diabetic rats (Gp. 8) intoxicated DOX treated orally with mesocarp fruit extract of *Balanites aegyptiaca*. Diabetic rats (Gp. 9) treated orally with fullerene C<sub>60</sub> plus mesocarp fruit extract of *Balanites aegyptiaca*. Whole blood and serum were collected for hematological and biochemical of kidney functions examinations, respectively. Diabetes induces, hematotoxicity was determined by a highly significant decrease in red blood cells (RBCs), white blood cells (WBCs), blood Platelets (PLTs), haemoglobin (Hb) and PCV value, as well as nephropathy was determined by a highly significant increase in creatinine, urea and uric acid. diabetic rats intoxicated DOX showed the reduction in hematological parameters, also, there were a highly significant increase in kidney function parameters. Fullerene C<sub>60</sub> and mesocarp fruit extract of *Balanites aegyptiaca* meliorated hematological and kidney functions indices. It could be concluded that Fullerene C<sub>60</sub> and *Balanites aegyptiaca*, clarified a modulatory role against the cellular damage produced by oxidative stress.

## INTRODUCTION

Diabetes mellitus is a major endocrine and a metabolic disorder with multiple etiologies, characterized by chronic hyperglycemia with disturbances of carbohydrate, fat and protein metabolism resulting from defects in insulin secretion, insulin function or both (Seyed-Mostafaet *al.*, 2012).

Nephropathy is one of the major complications of both type 1 and types 2 diabetes mellitus, and the morbidity and mortality due to diabetic nephropathy (DN) continue to increase in industrialized nations (Balakumaret *al.*, 2009).

Konsueet *al.* (2017) demonstrated that STZ- induced diabetes cause abnormality of hematological indices in form of increasing RBCs count, Hb concentration and PCV while decrease WBCs count and platelets but Mahmoud (2013) reported that STZ- induced diabetes cause anemia in form of decreasing RBCs count, Hb concentration and PCV while increase WBCs. It was reported that diabetes can change hematological parameters and the immune system in diabetes mellitus (Mansi and Lahham, 2008 and Nasirianet *al.*, 2017).

Doxorubicin (DOX) is an anthracycline antibiotic, although, a total chemical synthesis is now possible. DOX has demonstrated high antitumor efficacy. However, the use of DOX has been limited largely due to possible diverse cardiac, renal, hematological and testicular toxicities (Radwanet *al.*, 2012).

The use of DOX has been limited largely due to possible diverse cardiac, renal, haematological and testicular toxicities (Radwan *et al.*, 2012). DOX induces rat nephropathy, which is characterized by massive proteinuria, hypoalbuminemia and dyslipidemia (Radwan *et al.*, 2012).

Nanoscience is one of the most important research and development frontiers in modern science. Nanotechnology is now widely used throughout the pharmaceutical industry, medicine, electronics, robotics, and tissue engineering. The use of nanoparticle (NP) materials offers many advantages due to their unique size and physical properties (Farajiet *al.*, 2010).

Fullerene (C<sub>60</sub>), the third carbon allotrope, is similar in structure to graphene but rolled up to form hollow spheres with closed structure (Aschberger *et al.*, 2010). Fullerene autonomous cytostatic, immunosuppressant and antioxidant properties (Boushehri *et al.*, 2010). Fullerene C<sub>60</sub> is known to be able to inactivate hydroxyl radicals by attaching to double bonds (Andrievskiyet *al.*, 2009). However, this mechanism cannot explain sufficient (near two times) increase in the life span of rats. Such kind of antioxidative activity is also attributed to natural phenolic antioxidants that do not possess high senescence retarding activity (Banks *et al.*, 2010).

Most important fields of traditional medicine. The study on the medicinal plants is essential to promote the proper use of herbal medicine in order to determine their potential as a source for the new drugs (Parekh and Chanda, 2007). *Balanites aegyptiaca* is commonly known as nanjunda. It has been used in a variety of folk medicine in India and Asia. Various parts of the plant are used in Ayurvedic and other folk medicine for the treatment of various ailments such as syphilis, jaundice, liver and spleen problem, epilepsy and yellow fever and the plant also has insecticidal, antihelminthic, antifeedant, molluscicidal and contraceptive activities (Suky et *al.*, 2011).

Mesocarp fruit extract of *Balanites aegyptiaca* is used as complementary natural ant diabetic agent to prevent diabetic complications. mesocarp fruit extract of *Balanites aegyptiaca* also has beneficial effects on other

target tissues as kidney, and shows beneficial effects of mediators of large vessel damage, this concept appears attractive for the prevention or delay of diabetic nephropathy (Qusti *et al.*, 2015).

## MATERIALS AND METHODS

### Experimental Animals:

White albino rats (*Rattus norvegicus*) from order Rodentia and family Muridae were used in the present study. Experiments were carried out on 72 male albino rats at age (10-12 weeks) and weight about (250-280 g.), that were obtained from the animal house of the Egyptian Organization for Biological Products and Vaccines (VACSERA), Helwan, Cairo, Egypt. The animals were housed in the animal house of the Faculty of Science, South Valley University, Qena, Egypt; rats were divided into nine groups (8 rats/group).

Adult rats were kept under observation for 2 weeks before experimentation to exclude any undercurrent infection and to acclimatize the animals to the new conditions. The selected animals were marked, housed in controlled suitable cages with the separate bottom and kept at room temperature (23±2°C), and 12h. light/dark period, and fed on a balanced stable commercial diet. For drinking tap water was provided *ad libitum*.

### Streptozotocin:

Streptozotocin (STZ) was purchased from Sigma-Aldrich Chemie GmbH, Germany. It induces diabetes in experimental animals. It injected intraperitoneally (i.p.) at a dose of 45 mg/kg b.wt. (single dose) (Aref *et al.*, 2013).

### Doxorubicin:

Doxorubicin (DOX) is an anticancer drug and was purchased from EbewePharma co. Austria (Doxorubicin -injection 15 mg) according to Ahmed *et al.* (2014) and AL-Sadoon and Salama (2012).

Fullerene C<sub>60</sub> (purity 99.9%) was obtained from Lydow Group Limited Research Corporation (China) and used without further purification.

Virgin olive oil is obtained from a Colavita Extra Virgin Olive Oil Company which extracted from Olives harvested and pressed in Italy.

### C<sub>60</sub>-olive oil solution preparation:

After sourcing the high purity C<sub>60</sub>, we prepared C<sub>60</sub>-olive oil solution according to Batti *et al.* (2012). Fifty mg of C<sub>60</sub> was dissolved in 10 ml of olive oil by stirring for 2 weeks at ambient temperature in the dark. The resulting mixture was centrifuged at 5.000 g. for 1h. and the supernatant was filtered through a Millipore filter with 0.25 mm porosity.

### *Balanites aegyptiaca*:

Fruits of *Balanites aegyptiaca* were collected from South Valley University, Qena, Egyptian February 2017. They were taxonomically identified by the Department of Botany, Faculty of Science, South Valley University of Qena, Egypt.

### Preparation of *Balanites aegyptiaca* Extract:

Collected fruits of *Balanites aegyptiaca* were properly washed in water, rinsed using distilled water and the coat epicarp was gently removed by hand while a cleaned, the dried knife was used to peel the mesocarp of the fruit. Cleaned mesocarp (fleshy outer part) was separated from the hard inner shell containing the seed. Mesocarp was air dried at room temperature in the laboratory and was powdered using the coffee mill. This was thereafter placed in a dry plastic container and later put inside the refrigerator until required for use. 100 g. powdered was extracted using

200ml distilled water; it was stirred continuously for 10 mins and filtered. The filtrate was concentrated at 60°C to obtain thick brown viscous semi-solid (Mariam *et al.*, 2013). It administered orally Fruit Mesocarp extract of *Balanites aegyptiaca* daily 1.5 g/kg b.wt. for 60 days (Gad *et al.*, 2016).

#### **Experimental Design:**

The animals were randomly assigned into 9 groups (8 rats for each group). The first eight rats were separated for group 1, which were treated orally by olive oil at a dose (0.8 ml/kg.b.wt.) and used as a normal group. All remaining animals were injected with a single dose of streptozotocin (45 mg/kg b.wt) and divided into eight groups (gps. 2, 3, 4, 5, 6, 7 & 8). Group 2,

rats were injected intraperitoneal (i.p.) with a single dose of streptozotocin (45 mg/kg b.wt) and used as a diabetic group. Group 3, diabetic rats were injected intraperitoneal (i.p.) with doxorubicin at a dose of (5 mg/kg b. wt.) for three days. Group 4, diabetic rats were orally administered with fullerene C<sub>60</sub> (4 mg/kg b. wt.). Group 5, diabetic rats were orally administered with mesocarp fruit extract of *Balanites aegyptiaca* (1.5 g/kg b.wt.). Group 6, diabetic rats were orally administered with fullerene C<sub>60</sub> and mesocarp fruit extract of *Balanites aegyptiaca*. Group 7, diabetic rats intoxicated with DOX were orally administered with fullerene C<sub>60</sub> (4 mg./kg b. wt.). Group 8, diabetic rats intoxicated with DOX were orally administered with mesocarp fruit extract of *Balanites aegyptiaca* (1.5 g/kg b.wt.). Group 9, diabetic rats intoxicated with DOX were orally administered with fullerene C<sub>60</sub> and mesocarp fruit extract of *Balanites aegyptiaca*. Gps 3, 4, 5, 6, 7 & 8 were treated with drugs after induced diabetes by STZ with 10 days, daily and the experiment was continuous for 60 days. All animals were sacrificed at the end of the experiment.

#### **Blood Collection:**

The blood was collected from all animals and divided into two portions, one portion was taken in EDTA containing tubes and used for hematological examination. The other portion of blood was left in clean tubes at room temperature to clot, after an hour, then serum was separated by centrifugation for 30 minutes at 3000 rpm. The sera were collected in labeled Eppendorf's tubes and stored at -20 °C until used for biochemical analysis. A part of the right lobe of the liver was dissected and washed with the physiological saline solution, dried, weighed and homogenized in phosphate buffer (pH 7.4) and kept frozen until used for biochemical assays.

#### **Hematological Analysis:**

The hematological evaluation consisted of erythrocytes (RBCs), white blood cells (WBCs), platelets (PLT) counts and Hb content, the determination by Automated Hematology Analyzer (Diff3) Mek6410/Mek-6420.

#### **Biochemical Analysis:**

Urea was determined by the enzymatic colorimetric method which described by Vassault *et al.* (1986). Creatinine was determined by the kinetic method which described by Bartels and Bohmer (1972). Uric Acid was determined by the enzymatic colorimetric method which described by Barham and Trinder (1972).

#### **Statistical Analysis:**

The results are expressed as mean ± S.E. The means comparisons were made by using one-way analysis of variance (ANOVA) using Graph Pad Prism 03n software. Statistical significance was set at p < 0.05.

## RESULTS

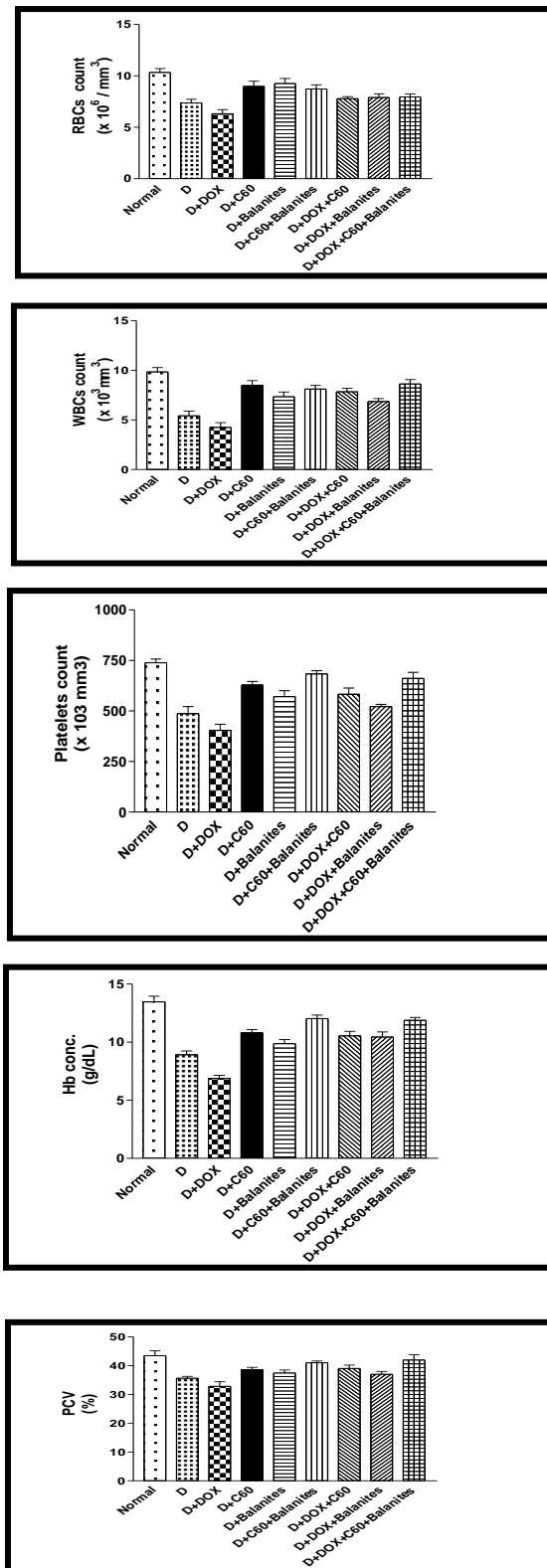
### Hematological Indices:

Rats treated with STZ resulted in a highly significant decrease in RBCs count, WBCs count, platelets count, Hb concentration and PCV value at ( $p < 0.01$ ) when compared with the normal rats. Diabetic rats intoxicated with DOX showed a highly significant decrease in RBCs count, WBCs count, platelets count, Hb concentration and PCV value at ( $p < 0.01$ ) when compared with the diabetic rats and normal rats. These results were recorded in Figure (1). Diabetic rats treated with fullerene C<sub>60</sub>, mesocarp fruit extract of *Balanites aegyptiaca* and (fullerene C<sub>60</sub> + mesocarp fruit extract of *Balanites aegyptiaca*) there was improvement ( $p < 0.01$ ) in RBCs count, WBCs count, platelets count, Hb concentration and PCV value when compared with diabetic rats (gp 2) but it was not reach to normal animals (gp 1). Diabetic rats intoxicated with DOX treated with fullerene C<sub>60</sub>, mesocarp fruit extract of *Balanites aegyptiaca* and (fullerene C<sub>60</sub> + mesocarp fruit extract of *Balanites aegyptiaca*) for 60 days show enhancement at ( $p < 0.01$ ) in RBCs count, WBCs count, platelets count, Hb concentration and PCV value when compared with diabetic (gp 2) and diabetic rats intoxicated with DOX (gp3).

### Effect on Biochemical Parameters:

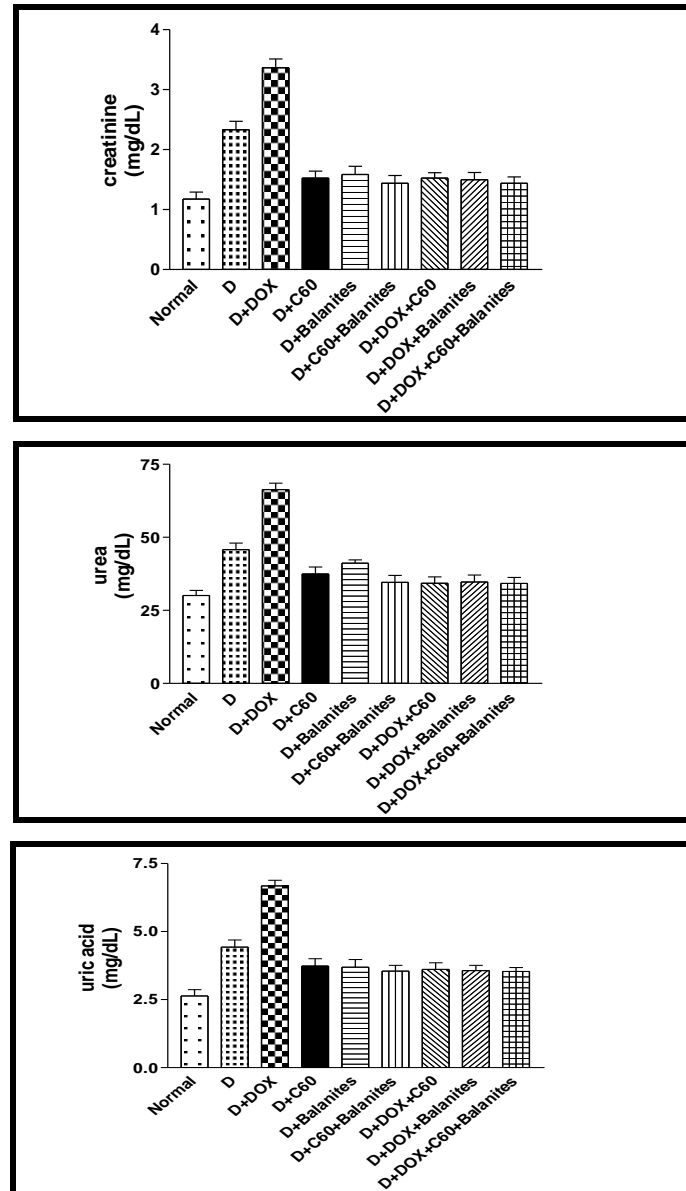
#### Kidney Function:

As shown in Figure (2) creatinine, urea and uric acid in serum of rats treated with STZ (gp 2) resulted in a highly significant increase at ( $p < 0.01$ ) when compared with the normal rats. diabetic rats intoxicated with DOX (gp 3) showed a highly significant increase at ( $p < 0.01$ ) in comparison with diabetic rats. Diabetic rat treated with fullerene C<sub>60</sub>, mesocarp fruit extract of *Balanites aegyptiaca* and (fullerene C<sub>60</sub> + mesocarp fruit extract of *Balanites aegyptiaca*) indicated revealed a highly significant decrease at ( $p < 0.01$ ) in serum creatinine, urea and uric acid levels compared to diabetic rats (gp 2). As well as, diabetic rats intoxicated with DOX (gp 3) treated with fullerene C<sub>60</sub>, mesocarp fruit extract of *Balanites aegyptiaca* and (fullerene C<sub>60</sub> + mesocarp fruit extract of *Balanites aegyptiaca*) revealed a highly significant decrease at ( $p < 0.01$ ) in serum creatinine, urea and uric acid levels comparing with diabetic rats (gp 2) and diabetic rats intoxicated with DOX (gp 3).



D: diabetic, DOX: doxorubicin and C<sub>60</sub>: fullerene

Fig. (1): Effect of oral administration of Fullerene C<sub>60</sub> (4 mg/kg b.wt.), mesocarp fruit extract of *Balanites aegyptiaca* (1.5 g/kg b.wt.) and (Fullerene + mesocarp fruit extract of *Balanites aegyptiaca*) daily for 60 days on haematological parameters (RBCs count  $\times 10^6 / \text{mm}^3$ , WBCs count  $\times 10^3 / \text{mm}^3$ , Platelets count  $\times 10^3 / \text{mm}^3$ , Hb content (g/dL) and PCV % value) of diabetic males Albino rats (induced by single dose of STZ 45 mg/kg b.wt.) and diabetic rats intoxicated with DOX (15 mg/kg b.wt.).



D: diabetic, DOX: doxorubicin and C<sub>60</sub>: fullerene.

**Fig. (2):** Effect of oral administration of Fullerene C<sub>60</sub> (4 mg/kg b.wt.), mesocarp fruit extract of *Balanites aegyptiaca* (1.5 g/kg b.wt.) and (Fullerene + mesocarp fruit extract of *Balanites aegyptiaca*) daily for 60 days on creatinine, urea and uric acid (mg/dL) of diabetic males Albino rats (induced by single dose of STZ 45 mg/kg b.wt.) and diabetic rats intoxicated with DOX (15 mg/kg b.wt.).

## DISCUSSION

Chronic hyperglycemia is associated with long term damage, dysfunction and failure of various body organs by the involvement of micro and macro-vasculature (Asadet *al.*, 2011). Hyperglycemia generates more reactive oxygen species (ROS) and promotes oxidative stress, which is known to play a crucial role in the pathogenesis of DM (Alhaideret *al.*, 2011).



Data of the present study have indicated that diabetic rats resulted in disorders in the haematological constituents as manifested by a highly significant decrease in the number of RBCs, WBCs, PLTs, remarkable fall in haemoglobin content (Hb) and highly significant drop in PCV value, which may be due to alteration in bone marrow as well as haemopoietic system of the animals. Similar observations were obtained by Erukainure *et al.* (2013) who reported that The decreased levels of WBC and platelet in diabetic rats indicate a suppression of the immune system. The decreased immunity can contribute to the various complications associated with diabetes. Also, high levels of free radicals, during diabetes, cause damage to cellular proteins, membrane lipids and nucleic acids, and cell death (Oyedemi *et al.*, 2011). It has been indicated that anemia has failed erythropoietin production that fails in the kidneys and raises non-enzymatic glycosylation of membrane proteins of red blood cells. Based on the findings, changes in RBC, Hb content and PCV levels in diabetic rats are the cause of anemia (Shenoy and Goyal 2002 and Nasirian *et al.*, 2017).

Besides that, the present recorded results in this study showing a decrease in RBCs, WBCs and PLTs value in diabetic rats intoxicated with DOX. Ali *et al.* (2015) demonstrated that DOX induced reduction in RBCs, WBCs, PLTs, hemoglobin content (Hb) and PCV value. It is noticeable doxorubicin in the rats induced a marked leukopenia and thrombocytopenia may be attributed to the destructive effects of DOX on peripheral blood cells and bone marrow (Al-Shabanah *et al.*, 1998 and Buyukokuroglu *et al.*, 2007). Kim *et al.* (2009) reported that DOX can induce platelet lysis directly through the sequential mechanisms of oxidative stress. The developed anemia in DOX-treated rats could be explained by hematopoiesis and hemoglobin synthesis reduction and probably due to a severe hemolysis in response to antioxidant system imbalance. It was proven that free radicals interact with cell membranes and thereby induce cell leakage and lyses (AL-Sadoon and Salama, 2012).

The present study demonstrated that, the nanosphere of fullerene C<sub>60</sub> administrated to diabetic rats and diabetic rats toxicated with DOX, caused haemological changes in blood of rats, which characterized by a pronounced improvement of total number of RBC, WBCs and PLT, remarkable improvement in haemoglobin contents (Hb) and significant increase in PCV value. This improvement may be attributed to the fullerene C<sub>60</sub> reacting with both; the drug and the membrane proteins of the erythrocytes. Therefore it may be diminish the complication of diabetes and the side effects of DOX (Grebowski *et al.*, 2013). The antioxidant activity of fullerene C<sub>60</sub> may be due to inhibition of lipid peroxidation by scavenging free radicals where hematological parameters were alleviated.

Moreover, it is clear that there is an increase in the RBCs, WBCs, Hb content and PCV value count after mesocarp fruit extract of *Balanites aegyptiaca* treatment at the end of the experimental period. Mariam *et al.* (2013) observed that improvement of WBCs and PLTs due to its antioxidant activity. The antioxidant activity of mesocarp fruit extract of mesocarp fruit extract of *Balanites aegyptiaca* may be due to inhibition of lipid peroxidation by scavenging free radicals and stabilization of red blood cell membranes where RBCs and related parameters were alleviated. In another view, flavonoids of mesocarp fruit extract of *Balanites aegyptiaca* can stimulate the formation or secretion of erythropoietin, which stimulates stem cells in the bone marrow to produce red blood cells (Ohlsson and Aher, 2012).

It worthily mentions that diabetic nephropathy is one of the most complications of diabetes. It includes hyperfiltration and renal hypertrophy (Bankir, 2001 and Abdou and Mohamed, 2016). The levels of non-protein nitrogenous

substances are always used as significant markers for the assessment renal dysfunction characterized by proteinuria. The results showed an increase in urea, creatinine and uric acid due to STZ-induced metabolic disturbances as well as renal dysfunction. Another possibility, the increase of these parameters may be attributed to protein catabolism and glomerular injury (Gayathri and Kannabiran, 2010 and Abdou and Mohamed, 2016).

Also, DOX-produced renal injury was evidenced by an elevation in serum urea and creatinine. DOX induced nephrotoxicity due to free radical formation and generation of oxidative stress. These results might be attributed to the induction of oxidative stress and inflammation cascade resulting in an increase in glomerular filtration rate, structural integrity derangement in the renal cells and kidney dysfunction (Wang *et al.*, 2000 and El-Sayed *et al.*, 2017).

The recorded results when comparing the levels of urea, creatinine and uric acid in the groups treated with fullerene C<sub>60</sub> with their diabetic rats and diabetic rats intoxicated DOX. Additionally, the fullerene C<sub>60</sub> has the ability to aggregate in serum and it is mainly distributed to liver and kidney (Nielsen *et al.*, 2008) and they act as the free radical scavenger and protect the cells from damage which lead to return kidney function parameter to the normal value.

In regard to mesocarp fruit extract of *Balanites aegyptiaca* treatment animals, when compared with diabetic rats and diabetic rats intoxicated with DOX the enhancement take place. The preventive of mesocarp fruit extract of *Balanites aegyptiaca* effects on diabetic rats and diabetic rats intoxicated with DOX, side effects have been attributed to the ability of mesocarp fruit extract of *Balanites aegyptiaca* preventing the decline of the renal antioxidant status or due to have antioxidant- and radical scavenging- activity of mesocarp fruit extract of *Balanites aegyptiaca* has beneficial effects of mediators of large vessel damage so it has ability to the prevention or delay of diabetic nephropathy (Qusti *et al.*, 2015). *Balanites aegyptiaca* fruits as herbal tea showed enhanced the renal function where it induced a reduction in the creatinine and urea (Ghanem *et al.*, 2016).

### Conclusion:

It could be concluded that, mesocarp fruit extract of *Balanites aegyptiaca* and fullerene C<sub>60</sub> could be used as a powerful antioxidant against diabetes related complication and the side effects of doxorubicin.

## REFERENCES

- Abdou, H. M. and Mohamed, N. A. (2016): *Centella asiatica* ameliorates diabetic complications and oxidative stress in streptozotocin-induced diabetes mellitus in male rats. *Int. J. Pharmacol. Sci. Rev. Res.*, 36(2): 61-70.
- Ahmed, I. A.; Mohammed, A. I. A. and Khaleel, K. J. (2014): Ameliorating the anticancer drug” Adriamycin” acute cardiotoxicity by rosuvastatin and telmisartan in rats. *Iraqi J. Cancer Med. Gen.*, 7(2): 146 -153.
- Alhaider, A. A.;Korashy, H. M.;Sayed-Ahmed, M. M.;Mobark, M.; Kfoury, H. and Mansour, M. A. (2011): Metformin attenuates streptozotocin-induced diabetic nephropathy in rats through modulation of oxidative stress genes expression. *Chem. Biol. Interact.*, 192(3): 233-242.
- Ali, M.; Choudhury, S.; Kumari, L.; Akhter, M. S.; Rizvi, T. F.; Kumar, R. and Kumar, A. (2015): Therapeutic study of saffron against doxorubicin toxicity in the management of cancer chemotherapy. *Int. J. Adv. Res.*, 3(9): 874 - 878.

- Al-Sadoon, M. K. and Salama, S. F. (2012): Physiological effects of low doses of *Cerastes cerastes* crude venom and its influence on doxorubicin treated rats. *J. Radiat. Res. Appl. Sci.*, 5: 871-85.
- Al-Shabanah, O.; Mansour, M.; El-Kashef, H. and Al-Bekairi, A. (1998): Captopril ameliorates myocardial and hematological toxicities induced by adriamycin. *Biochem. Mol. Biol. Int.*, 45(2): 419-427.
- Andrievsky, G. V.; Bruskov, V. I.; Tykhomyrov, A. A. and Gudkov, S. V. (2009): Peculiarities of the antioxidant and radioprotective effects of hydrated C<sub>60</sub> fullerene nanostructures *in vitro* and *in vivo*. *Free Radic. Biol. Med.*, 47(6): 786-793.
- Aref, A. B. M.; Ahmed, O. M.; Ali, L. A. and Semmler, M. (2013): Maternal rat diabetes mellitus deleteriously affects insulin sensitivity and Beta-cell function in the offspring. *J. Diabetes Res.*, 2013:1-10.
- Asad, M.; Aslam, M.; Munir, T. A. and Nadeem, A. (2011): Effect of *Acacia nilotica* leaves extract on hyperglycaemia, lipid profile and platelet aggregation in streptozotocin induced diabetic rats. *J. Ayub. Med. Coll. Abbottabad.*, 23(2): 3-7.
- Aschberger, K.; Johnston, H. J.; Stone, V.; Aitken, R. J.; Tran, C. L.; Hankin, S. M.; Christensen, F. M. and Peters, S. A. (2010): Review of fullerene toxicity and exposure - appraisal of a human health risk assessment, based on open literature. *Regul. Toxicol. Pharmacol.*, 58(3): 455 - 473.
- Balakumar, P.; Arora, M. K.; Ganti, S. S.; Reddy, J. and Singh, M. (2009): Recent advances in pharmacotherapy for diabetic nephropathy: current perspectives and future directions. *Pharmacol. Res.*, 60(1): 24 - 32.
- Bankir, L. (2001): Antidiuretic action of vasopressin: quantitative aspects and interaction between V1a and V2 receptor-mediated effects. *Cardiovasc. Res.*, 51(3): 372 - 390.
- Banks, R.; Speakman, J. R. and Selman, C. (2010): Vitamin E supplementation and mammalian lifespan. *Mol. Nutr. Food Res.*, 54(5): 719 - 725.
- Barham, D. and Trinder, P. (1972): An improved colour reagent for the determination of blood glucose by the oxidase system. *Analyst.*, 97(1151): 142-145.
- Bartels, H. and Bohmer, M. (1972): Serum creatinine determination without protein precipitation. *Clin. Chim. Acta.*, 37: 193-197.
- Batti, T.; Bourasset, F.; Gharbi, N.; Njim, L.; Abderrabba, M.; Kerkeni, A.; Szwarc, H. and Moussa, F. (2012): The prolongation of the lifespan of rats by repeated oral administration of [60]fullerene. *Biomaterials.*, 33(19): 4936 - 4946.
- Boushehri, S. V. S.; Ostad, S. N.; Sarkar, S.; Kuznetsov, D. A.; Buchachenko, A. L.; Orlova, M. A. and Rezayat, S. M. (2010): The C<sub>60</sub>-fullerene porphyrin adducts for prevention of the doxorubicin-induced acute cardiotoxicity in rat myocardial cells. *Acta Med. Iran.*, 48(5): 342 - 350.
- Buyukokuroglu, M. E.; Taysi, S.; Buyukavci, M.; Memisogullari, R.; Ozabacigil, F. and Bakan, E. (2007): Dantrolene: in doxorubicin toxicity. *Asian J. Chem.*, 19(5): 4035-4042.
- El-Sayed, E. S. M.; Mansour, A. M. and El-Sawy, W. S. (2017): Protective effect of proanthocyanidins against doxorubicin-induced nephrotoxicity in rats. *J. Biochem. Mol. Toxicol.*, 31(11): 21965-21971.
- Erukainure, O. L.; Ebuehi, O. A.; Adeboyejo, F. O.; Aliyu, M. and Elemo, G. N. (2013): Hematological and biochemical changes in diabetic rats fed with fiber-enriched cake. *J. Acute Med.*, 3(2): 39-44.

- Faraji, M.; Yamini, Y. and Rezaee, M. (2010): Magnetic nanoparticles: synthesis, stabilization, functionalization, characterization and applications. J. Iran. Chem. Soc., 7(1): 1-37.
- Gad, M. Z.; El-Sawalhi, M. M.; Ismail, M. F. and El-Tanbouly, N. D. (2006): Biochemical study of the anti-diabetic action of the Egyptian plants *Fenugreek* and *Balanites*. Mol. Cell. Biochem., 281(1-2): 173 - 183.
- Gayathri, M. and Kannabiran, K. (2010): 2-Hydroxy 4-methoxy benzoic acid isolated from roots of *Hemides musindicus* ameliorates liver, kidney and pancreas injury due to streptozotocin induced diabetes in rats, Indian J. Exp. Biol., 48(2):159 - 64.
- Ghanem, K. Z.; Ghanem, H. Z.; Ramadan, M. M. and Mabrok, H. B. (2016): The effect of herbal tea from *Balanites aegyptiaca* fruits on streptozotocin-induced diabetes mellitus in rats. Int. J. Pharm.Tech. Res., 9(10): 8-15.
- Grebowski, J.; Krokosz, A. and Puchala, M. (2013): Fullerenol C<sub>60</sub> (OH)<sub>36</sub> could associate to band 3 protein of human erythrocyte membranes. Biochim. Biophys. Acta., 1828(9): 2007-2014.
- Kim, E. J.; Lim, K. M.; Kim, K. Y.; Bae, O. N.; Noh, J. Y.; Chung, S. M.; Yun, Y. P. and Chung, J. H. (2009): Doxorubicin-induced platelet cytotoxicity: a new contributory factor for doxorubicin-mediated thrombocytopenia. J. Thromb. Haemost., 7(7): 1172-1183.
- Konsue, A.; Picheansoonthon, C. and Talubmook, C. (2017): Fasting blood glucose levels and hematological values in normal and streptozotocin-induced diabetic rats of *Mimosa pudica* L. Extracts. Pharmacogn. J., 9(3): 315 - 322.
- Mansi, k. and Lahham, J. (2008): Effects of *Artemisia sieberibesser* on heart rate and some hematological values in normal and alloxan-induced diabetic rats. J. Basic Appl., 2: 57- 62.
- Mariam, S.; Nwozo, S. O. and Oyelola, O. B. (2013): Aqueous Extract of *Balanitesaegyptiaca* Del Fruit Mesocarp Protects against CCl<sub>4</sub>-Induced Liver Damage in Rats. Br. J. Pharm. Res., 3(4): 917- 928.
- Nasirian, F.;Mesbahzadeh, B.;Maleki, S. A.;Mogharnasi, M. and Kor, N. M. (2017): The effects of oral supplementation of *spirulina platensis* microalgae on hematological parameters in streptozotocin-induced diabetic rats. Am. J. Transl. Res., 9(12): 5238 - 5244.
- Nielsen, G. D.; Roursgaard, M.; Jensen, K. A.; Poulsen, S. S. and Larsen, S. T. (2008): *In vivo* biology and toxicology of fullerenes and their derivatives. In Basic Clin. Pharm-acol. Toxicol., 103(3): 197 - 208.
- Ohlsson, A. and Aher, S. M. (2012): Early erythropoietin for preventing red blood cell transfusion in preterm and/or low birth weight infants. Cochrane Database Syst. Rev., 9: 1-2.
- Oyedemi, S. O.; Yakubu, M. T. and Afolayan, A. J. (2011): Antidiabetic activities of aqueous leaves extract of *Leonotisleonurus* in streptozotocin induced diabetic rats. J. Med. Plant Res., 5(1): 119 -125.
- Parekh, J. and Chanda, S. (2007): *In vitro* screening of antibacterial activity of aqueous and alcoholic extracts of various Indian plant species against selected pathogens from Enterobacteriaceae. Afr. J. Microbiol. Res., 1: 92-99.
- Qusti, S. Y.; Sharahili, R. Y. and Moselhy, S. S. (2015): Role of *Balanites aegyptiaca* in attenuation of diabetic nephropathy. Int. J. Life Sci. Res., 3 (4): 8 -14.
- Radwan, R. R.; Shaban, E. A.; Kenawy, S. A. and Salem, H. A. (2012): Protection by low-dose  $\gamma$  radiation on doxorubicin-induced nephropathy in rats pretreated

- with curcumin, green tea, garlic or l-carnitine. Bulletin Fac. Pharm., Cairo University, 50(2): 133-140.
- Seyed-Mostafa, H. Z.; Javad, H.; Mehdi, M.; Hassanshahi, G.; Hashemi, B., and Seyed-Mohammad, H. Z. (2012): The effects of Persian shallot extract on the levels of some blood biochemical parameters in streptozotocin-induced diabetic rats. Afr. J. Agr. Res., 7(22): 3308-3313.
- Shenoy, A. G. and Goyal, R. K. (2002): Improvement of insulin sensitivity by perindopril in spontaneously hypertensive and streptozotocin-diabetic rats. Indian J. Pharmacol., 34(3): 156 -164.
- Suky, T. M. G.; Parthipan, B.; Kingston, C.; Mohan, V. R. and Soris, P. T. (2011): Hepatoprotective and antioxidant effect of *Balanites aegyptiaca* (L.) del against CCl<sub>4</sub> induced hepatotoxicity in rats. Int. J. Pharm. Sci. Res., 2(4), 887-892.
- Vassault, A.; Grafmeyer, D. and Naudin (1986): Protocole de validation de techniques. Document B, Stade 3 Ann. Biol. Clin., 44- 686.
- Wang, Y.; Wang, Y. P.; Tay, Y. C. and Harris, D. C. (2000): Progressive adriamycin nephropathy in mice: sequence of histologic and immunohistochemical events. Kidney Int., 58(4): 1797-1804.

### ARABIC SUMMERY

التأثير التحسيني للفوليرين (الكربون الستيني) ومستخلص لب ثمرة نبات الهيلج المصري علي التسمم الكلوي والدموي المستحدثة بواسطة الدوكسوروبيسين علي ذكور الجرذان البيضاء المصابة بداء السكري.

عبد الرحيم علي الشاطر، محمد محمود علي سالماني، نجلاء رشاد عطا الله قاسم، مريم ابوبكر فاوي محمود  
قسم علم الحيوان - كلية العلوم - جامعة جنوب الوادي

تهدف تلك الدراسة إلي دراسة الأثر العلاجي لبعض مضادات الأكسدة (الفوليرين ومستخلص ثمرة لب الهيلج الصحراوي) علي المكونات الخلوية للدم والقياسات البيوكيميائية في ذكور الجرذان البيضاء. ولذا فقد تم تقسيم الحيوانات الي تسع مجموعات من ذكور الجرذان البيضاء (8 فأر لكل مجموعة). المجموعة 1: تم اعطاء الجرذان زيت الزيتون البكر من خلال الفم بجرعة 0,8 ملي جرام كمجموعة طبيعية. المجموعة 2: حقنت في الغشاء البريتوني بعقار سترتوزوتوسين عند جرعة (45 مجم/كجم) من وزن الجسم لمرة واحدة لاستحداث داء السكري. أما المجموعة 3: حقنت الجرذان المصابة بداء السكري في الغشاء البريتوني بعقار بجرعة (5مجم/كجم من وزن الجسم) لمدة 3أيام اما المجموعة 4: تم معالجة الفئران المصابة بداء السكري بالفوليرين من خلال الفم (4مجم/كجم من وزن الجسم). المجموعة 5: تم اعطاء الجرذان المصابة بداء السكر بمستخلص لب ثمرة الهيلج الصحراوي من خلال الفم (1,5مجم/كجم من وزن الجسم). المجموعة 6: تم اعطاء الجرذان المصابة بداء السكري بالفوليرين + مستخلص لب ثمرة الهيلج الصحراوي. المجموعة 7: تم معالجة الجرذان المصابة بداء السكري وتم تسميمها بالدوكسوروبيسين بالفوليرين. المجموعة 8: تم معالجة الجرذان المصابة بداء السكري وتم تسميمها بالدوكسوروبيسين بمستخلص لب ثمرة الهيلج الصحراوي. المجموعة 9: تم معالجة الجرذان المصابة بداء السكري وتم تسميمها بالدوكسوروبيسين بالفوليرين + بمستخلص لب ثمرة الهيلج الصحراوي.

ولقد أظهرت نتائج التحاليل الإحصائية أن المجموعة المصابة بداء السكري و المصابة بداء السكري وتم تسميمها بالدوكسوروبيسين نقصا معنويا ملحوظ في عدد كريات الدم الحمراء و عدد كريات الدم البيضاء والصفائح الدموية وتركيز الهيموجلوبين وحجم خلايا الدم الحمراء المتجمعة (PCV). وكذلك زيادة معنوية ملحوظة في تركيز كلا من الكرياتينين واليوريا وحمض البوليك. ومن تلك النتائج نستطيع أن نستنتج أن كلا من الفوليرين و مستخلص لب ثمرة الهيلج الصحراوي لهم دور تحسيني ضد تلف الخلايا الناتج من الشوارد الحرة.