

CONE-BEAM COMPUTED TOMOGRAPHY EVALUATION OF MAXILLARY SINUS VOLUME IN PATIENTS WITH UNILATERALLY MAXILLARY IMPACTED CANINES

Shaimaa Mohamed Elmarhoumy* , Wael Safwat** and Mohammed Ellaithy***

ABSTRACT

Aim: Evaluate the volume of the maxillary sinus in subjects with unilaterally impacted maxillary canine using cone beam computed tomography (CBCT) and compare the sinus volume in subjects with unilateral buccal or palatal maxillary canine impaction.

Materials and Methods: CBCT scans of 40 subjects with unilaterally impacted maxillary canines (20 with unilateral buccal impaction and 20 with unilateral palatal impaction) were used to compare the maxillary sinus volumes between the impacted and the normal sides. Also, the maxillary sinus volume in patients with unilateral buccally maxillary impacted canine was compared with those with unilateral palatally maxillary impacted canine. The materialize mimics 21.0 software program was used to calculate the volume of the maxillary sinus.

Results: The volume of the maxillary sinus was statistically significantly smaller in the impaction side ($11377.17 \pm 1386.87 \text{ mm}^3$) compared to the contralateral side ($12770.71 \pm 1621.24 \text{ mm}^3$). However, there is no significant effect of the site of impaction either buccally or palatally on the volume of the maxillary sinus.

Conclusion: A volumetric decrease in the maxillary sinus volume can be expected when the maxillary canines are impacted.

KEYWORDS: Maxillary sinus volume: Impacted maxillary canines: CBCT

INTRODUCTION

The maxillary sinus is a bilateral air-filled chamber existed in the maxilla and is the largest of the four paranasal sinuses^{1,2}. The paranasal sinuses are useful in humidity of the inhaled air, equalizing

changes in air pressure, facilitating respiratory function and resonance, helping in diminution of the weight of the skull, and have an essential role in growth of orofacial structures^{3,4,5}.

The maxillary sinus grows rapidly in size through

* Lecturer of Orthodontic, Faculty of Dentistry, Tanta University

** Assistant professor, Oral Radiology and Diagnostic Sciences, Faculty of Dentistry, Mansoura University, Egypt.

*** Assistant professor, Department of Orthodontics, Faculty of Dentistry, Tanta University, Egypt

two growth spurts: the first one within the first three years of life, and the second from seven to twelve years of age. Then its size becomes almost adult-sized between twelve and fifteen years of age⁶.

Bhushan et al.⁷ didn't find any increase in the maxillary sinus volume after twelve years of age. The mean maxillary sinus volume in early adults is 16,711 cm³ in males and 13,370 cm³ in females⁸.

The floor of the maxillary sinus is formed of the maxillary alveolar process. So, sinus pneumatization can occur after extraction of maxillary posterior teeth⁹, while reduction in maxillary sinus volume may be associated with dental impaction¹⁰.

Maxillary canines are unique members of the dental arches. They play a very important role in occlusion. Also, they are of high esthetic value as they support lip and facial muscles¹¹. The maxillary permanent canine is most likely to be impacted second to the third molars¹², with a prevalence of impaction ranges from 1–3% of the population¹³. Palatal canine impaction occurs 3 to 6 times more than buccal impaction¹⁴.

The inferior border of the maxillary sinus may be interfered by the roots of the maxillary canine even in a well aligned dental arch¹⁵. As well as maxillary canine become in a closer relationship with maxillary sinuses when it is impacted¹⁶.

Endo et al.² evaluated the size of maxillary sinus in different malocclusion groups using 120 lateral cephalogram of patients aged from 12 to 16 years of both sexes. They didn't register any significant differences in maxillary sinus sizes between different groups of malocclusions or between sexes.

Darsey et al.¹⁷ used computerized tomography (CT) scanning for accurate evaluation of the maxillary sinus volumes before and after rapid maxillary expansion. While Saccucci et al.¹⁸ stated that, volumetric measurement of maxillary sinus using cone beam computed tomography (CBCT) has lesser exposure than computed tomography, and lower cost than magnetic resonance imaging.

Zeynep et al.¹⁹ evaluated the volume maxillary sinus in 30 subjects with unilateral impacted canines using pretreatment and posttreatment CBCT. They demonstrated increase in the volume of the maxillary sinus after orthodontic traction of impacted canines.

No previous studies investigated maxillary sinus volumes in patients with unilateral buccally or palatally maxillary impacted canines. So, the aim of the presented study was directed to evaluate the volume of maxillary sinus in patients with unilateral maxillary canine impaction and compare maxillary sinus volume between patients with unilateral buccally maxillary canine impaction and others with unilateral palatally maxillary canine impaction.

MATERIAL AND METHODS

CBCT images of 40 Egyptian patients with unilateral impacted maxillary canine, their ages 13-18 years were collected from Orthodontic department, Faculty of Dentistry, Tanta University, and private radiology centers. Of these 40 patients, twenty had unilateral labial impacted canines and the other twenty had unilateral palatally impacted canines. Patients with hard or soft tissue pathosis, craniofacial anomalies, congenitally missing teeth, extracted posterior teeth and any maxillary sinus pathosis were not included in this study.

The minimum number of sample size for this study was calculated and found to be 40 patients. The criteria used for sample size calculation were as follows: 95% confidence limit, 80% power of the study.

CBCT scans were acquired by iCAT FLX CBCT machine (Imaging Science international, ISI, Hatfield, PA, USA). Scanning parameters were 90 kVp, 24 s, 4 mA, with field of view 16x12 cm and resolution of 0.3 mm voxel size used mainly for ENT purposes in airway and paranasal sinuses assessment.

The raw DICOM files for the selected cases were imported into materialize mimics 21.0 software. Prepare a new mask selection (crop area) with predefined HU custom threshold (min. threshold is -1000 and max. threshold is -500). The dimension of the mask was defined in all directions to cover the entire sinus area then the mask selection was edited carefully to define the boundaries of the sinus accurately by adding or erasing layers one by one from all orthogonal planes.

Each maxillary sinus side made a separate mask which was saved a separate object named with the sinus side (Left or Right sinus). Each object was colored with a different color to distinguish the impacted canine side from the normal side. All objects were visible on screen as a 3D model for further manipulation such as merge, cut, or export to STL if needed. The object properties can be easily shown on screen (Fig 1).

Measurements of the maxillary sinus volume were repeated 2 weeks after the initial measurements. The reliability of these repeated measurements was tested using the intraclass correlation coefficient (ICC) with a 95% confidence interval. ICC values ranged from 0.91 to 0.96, which indicated a high degree of reliability.

The maxillary sinus volume of the impacted canine side was compared to the non-impaction side and the sinus volume of the labially impacted side was compared to the sinus volume of palatally impacted side and the data was statistically analyzed.

Statistical Analysis

The data were collected, tabulated, and analyzed. Statistical analysis was done with SPSS Version 22.0 (SPSS Inc, Chicago, IL, USA). T-test was used for comparing the sinus volume between impaction and non-impaction sides.

RESULTS

Measurements of the maxillary sinus volume at the impaction and non-impaction sides are given in Table 1. There was a statistically significant increase in the maxillary sinus volumes in the non-impaction sides $12770.71 \pm 1621.24 \text{ mm}^3$ compared to the impaction side $11377.17 \pm 1386.87 \text{ mm}^3$ ($P= 0.017$) (Fig 1, 2).

No statistically significant difference in maxillary sinus volumes was recorded in patients who had labial or palatal impacted maxillary canine ($P= 0.283$) (Table 2).

TABLE (1): Comparison of maxillary sinus volumes between impaction and non-impaction sides.

	Maxillary sinus volume (mm ³) impacted side (n=40)	Maxillary sinus volume (mm ³) non-impacted side (n=40)
Range	8547.11 – 13851.15	10115.85 – 14742.77
Mean ± SD	11377.17 ± 1386.87	12770.71 ± 1621.24
T. test	2.530	
P. value	0.017*	

TABLE (2): Comparison of maxillary sinus volumes between labial and palatal impaction groups.

	Sinus volume (mm ³) Labial impaction (n=20)	Sinus volume (mm ³) Palatal impaction (n=20)
Range	9168.24 – 11917.44	8547.11 – 13851.15
Mean ± SD	10814.61 ± 1159.90	11658.45 ± 1459.56
T. test	1.121	
P. value	0.283	

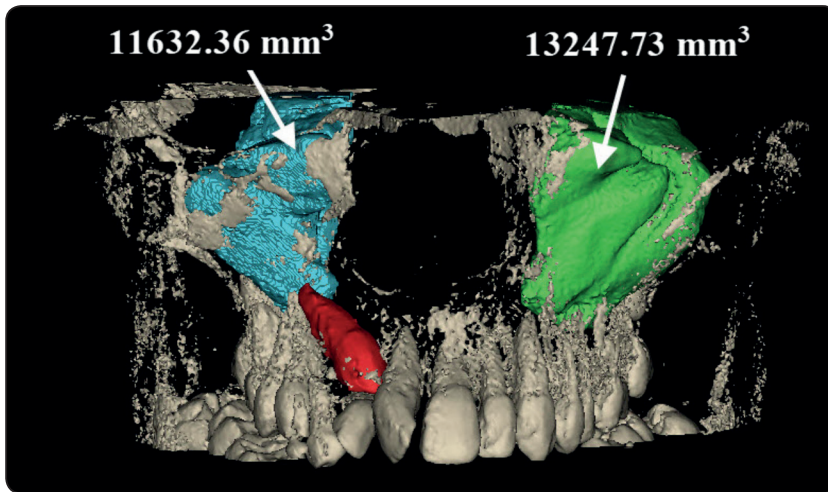


Fig. (1) 3D volumetric measurements of right maxillary sinus (labially impacted canine side) and left maxillary sinus (normal control side).

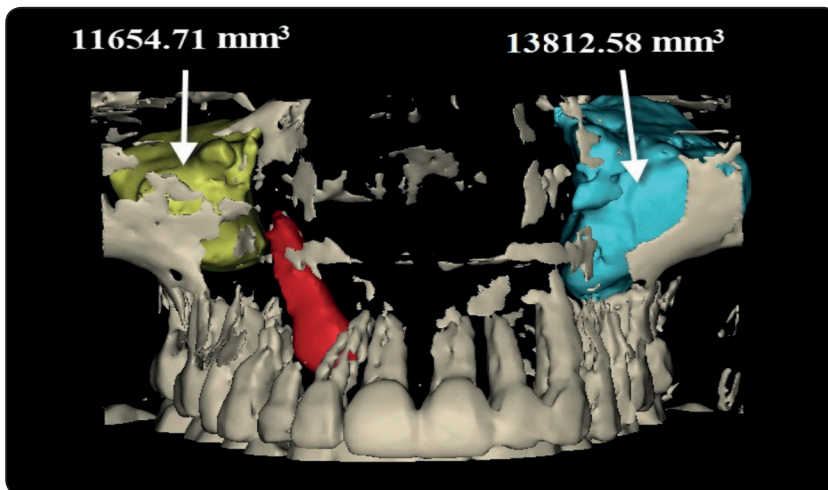


Fig. (2) 3D volumetric measurements of right maxillary sinus (palatally impacted canine side) and left maxillary sinus (normal control side).

DISCUSSION

The introduction of CBCT in dentistry in the late 1990s, has considered the best method for diagnosis and assessing the position of impacted canines and other adjacent structures²⁰.

Lateral cephalometric radiographs have many disadvantages, that the images may be different from the actual size. In addition, the boundaries of the maxillary sinus are superimposed by neighboring structures specially in the deeper areas of nasomaxillary complex²¹. CBCT is more accurate to measure maxillary sinus volume with smaller radiation doses and lower cost compared with computed tomography magnetic resonance

imaging respectively¹⁸. Therefore, CBCT scans were used in the present study for measurement of maxillary sinus volumes.

The maxillary canine eruption occurs between 11 and 12 years of age, while the maxillary sinus reaches its maximum size between 12 and 15 years of age and its volume does not significantly increase after 12 years of age^{6,7,18,22}. Therefore, in the current study the maxillary sinus volume was evaluated in patients aged above 12 years with unilateral maxillary canine impactions.

Maxillary sinus volume may vary by age and gender^{10,23,24}, so when examining changes in maxillary sinus volume, we measured right and left

maxillary sinus volumes in the same patient with unilaterally impacted canine, rather than evaluating sinus volume in different patient groups to eliminate the influence of age and gender on sinus volume. Also, presence of impacted canine on either right or left side will not affect the results because no significant difference in maxillary sinus volumes between the right and left sides was recorded by previous studies^{10,25}.

In the present study, the patients had no extracted or congenitally missing maxillary teeth as Ariji et al.²⁵ reported greater volume of the maxillary sinus in toothed patients than in edentulous patients. Furthermore, Takahashi et al.²⁶ utilized elderly Japanese corpses to report decrease in the volume of the maxillary sinus with molar absence. Also, Velasco-Torres et al.²⁷ found significantly smaller maxillary sinus volume in complete and partially edentulous patients than in dentate patients.

In the current study, smaller maxillary sinus volume was observed on the impacted canine side than on the opposing side. This result agreed with that of Zeynep et al.,¹⁹ who stated that, the volume of right maxillary sinus was significantly smaller than that of the left side when the canine was impacted on the right side. They also reported that deeply impacted canine has an impact on maxillary sinus volume. This may explain our nonsignificant result between maxillary sinus volume in patients with labially or palatally impacted maxillary canines. So, further studies may be important to evaluate the effect of vertical position of impacted maxillary canine on maxillary sinus volume.

On the other hand, Kalabalık and Ertas¹⁰ believed that impacted teeth failed to have any influence on maxillary sinus volume as they found no significant difference in sinus volume between right and left sides when comparing the maxillary sinus volumes in patients with unilateral impacted teeth.

In conclusion, this study has showed a significant decrease in the volume of maxillary sinus in patients

with unilateral maxillary canine impaction on the same side of impaction regardless of the site of impaction either labially or palatally.

REFERENCES

1. Emirzeoglu M, Sahin B, Bilgic S, Celebi M, Uzun A. Volumetric evaluation of the paranasal sinuses in normal subjects using computer tomography images: a stereological study. *Auris Nasus Larynx*. 2007; 34:191-95.
2. Endo T, Abe R, Kuroki H, Kojima K, Oka K, Shimooka S. Cephalometric evaluation of maxillary sinus sizes in different malocclusion classes. *Odontology*. 2010; 98:65-72.
3. Rennie CE, Hood CM, Blenke EJ, et al. Physical and computational modeling of ventilation of the maxillary sinus. *Otolaryngol Head Neck Surg*. 2011; 145: 165-70.
4. Fehrenbach MJ, Herring SW, Thomas P. *Illustrated Anatomy of the Head and Neck*. Philadelphia, Penn: WB Saunders;1996.
5. J. Keir. Why do we have paranasal sinuses? *J. Laryngol. Otol*. 2009; 123: 4-8.
6. Graney DO, Rice DH. *Anatomy*. In: Cummings CW, Harker LA, Krause CJ, Schuller DE, editors. *Otolaryngology: head and neck surgery*. 2nd ed. St. Louis: Mosby Elsevier; 1993. p. 901-6.
7. Bhushan B, Rychlik K, Schroeder J. Development of the maxillary sinus in infants and children. *Int J Pediatr Otorhinolaryngol*. 2016; 91: 146-51.
8. Muszynska D, Kociemba W, Rewekant A, Sroka A, Potoczna K, Banaszewska M, Przystanska A. Development of the maxillary sinus from birth to age 18. Postnatal growth pattern. *International Journal of Pediatric Otorhinolaryngology*. 2015; 79: 1393-400.
9. Sharan A, Madjar D. Maxillary sinus pneumatization following extractions: a radiographic study. *Int J Oral Maxillofac Implants*. 2008; 23: 48-56.
10. Kalabalık F, Ertas E. Investigation of maxillary sinus volume relationships with nasal septal deviation, concha bullosa, and impacted or missing teeth using cone beam computed tomography. *Oral Radiology*. 2019; 35: 287-95.
11. Danaie M, Salehi, P., Kalantary, M. The Importance of Maxillary Canine: A Review. *Journal of Dentistry*, 2003; 4: 53-61.

12. Becker A. The orthodontic treatment of impacted teeth. 2nd ed. London, United Kingdom: Informa Healthcare; 2007. p. 93-174.
13. Bedoya MM, Park JH. A review of the diagnosis and management of impacted maxillary canines. *J Am Dent Assoc.* 2009;140: 1485-93.
14. Walker L, Enciso R, Mah J. Three-dimensional localization of maxillary canines with cone beam computed tomography. *Am J Orthod Dentofac Orthop.* 2005; 128:418-23.
15. Rusu M, Comes C, Stanciu D. Altered anatomy in a case with a buccally impacted maxillary canine tooth. *Rom J Morphol Embryol.* 2010; 51:783-86.
16. Kwak H, Park H, Yoon H, Kang M, Koh K, Kim H. Topographic anatomy of the inferior wall of the maxillary sinus in Koreans. *Int J Oral Maxillofac Surg.* 2004; 33:382-88.
17. Darsey D, English J, Kau C, Ellis R, Akyalcin S. Does hyrax expansion therapy affect maxillary sinus volume? A cone-beam computed tomography report. *Imaging Sci Dent.* 2012; 42:83-88.
18. Saccucci M, Cipriani F, Carderi S, Di Carlo G, D-Attilio M, Rodolfino D. Gender assessment through three-dimensional analysis of maxillary sinuses by means of cone beam computed tomography. *Eur Rev Med Pharmacol Sci.* 2015; 19: 185-93.
19. Zeynep A, Alper A, Hakan E, Palomo J. Maxillary sinus volume in patients with impacted canines. *Angle Orthod.* 2017; 87: 25-32.
20. Jun B, Song S, Park C, Lee D, Cho K, Cho J. The analysis of maxillary sinus aeration according to aging process; volume assessment by 3-dimensional reconstruction by high-resolution CT scanning. *Otolaryngol Head Neck Surg* 2005; 132: 429-34.
21. Baumgaertel S, Palomo J, Palomo L, Hans M. Reliability and accuracy of cone-beam computed tomography dental measurements. *Am J Orthod Dentofacial Orthop* 2009; 136:19-25.
22. Weiglein A, Anderhuber W, Wolf G. Radiologic anatomy of the paranasal sinuses in the child. *Surg Radiol Anat.* 1992;14: 335-9.
23. Ikeda A, Ikeda M, Komatsuzaki A. A CT study of the course of growth of the maxillary sinus: normal subjects and subjects with chronic sinusitis. *ORL J Otorhinolaryngol Relat Spec.* 1998; 60: 147-52.
24. Sahlstrand-Johnson P, Jannert M, Strombeck A, Abul-Kasim K. Computed tomography measurements of different dimensions of maxillary and frontal sinuses. *BMC Med Imaging.* 2011; 11: 8.
25. Ariji Y, Kuroki T, Moriguchi S, Ariji E, Kanda S. Age changes in the volume of the human maxillary sinus: a study using computed tomography. *Dentomaxillofac Radiol.* 1994; 23: 163-8.
26. Takahashi Y, Watanabe T, Imura A, Takahashi O. A study of the maxillary sinus volume in elderly persons using Japanese cadavers. *Okajimas Folia Anat Jpn.* 2016; 93: 21-7.
27. Velasco-Torres M, Padial-Molina M, Avila-Ortiz G, Garcia-Delgado R, O'Valle F, Catena A, et al. Maxillary sinus dimensions decrease as age and tooth loss increase. *Implant Dent.* 2017; 26: 288-95.