

EFFECT OF A TOOTH-BORNE INTER-DENTAL DISTRACTOR ON REDUCTION OF WIDTH OF ALVEOLAR CLEFTS

Marwa E. Fat-hy*, Noha I. Abdel-Rahman**, Marwa Abd-El-Wahab El-Kassaby***
and Ibrahim M. Negm****

ABSTRACT

Objective: The aim of this study was to evaluate the effect of a tooth-borne appliance for interdental distraction osteogenesis on the reduction of the width of wide alveolar clefts.

Materials and methods: Seven patients were recruited to this study having wide alveolar clefts; wider than width of a canine (age from 12 to 25 years). The tooth borne distractor appliance was custom-made for each patient using micro-expansion screw, osteotomies were done under general anesthesia, then activation of the distractor was done until clinically there was complete closure of the alveolar cleft. After consolidation period, evaluation of cleft width reduction was examined radiographically. Statistical analysis was done, where all measurements were described in form of Mean and Standard Deviation. Comparison between pre-operative and post-operative data was done using paired *t*-test. Significance level was considered at $P < 0.05$.

Results: Clinically there was a significant reduction of the width of the alveolar cleft as well as closure of the oro-nasal fistula was observed. Radiographically, width of the cleft was measured pre-distraction and post-consolidation at two levels; cervical level and apical level, In this study there was a statistically significant difference between width of the cleft before and after distraction (P -value= 0.011) at the caudal or occlusal part of the cleft, also there existed statistical difference in reduction of cleft width at the level of root apices (P -value=0.031), with a less mean of width post distraction, denoting tipping of teeth in the transport segment.

Conclusion: This tooth-borne distractor was able to reduce the width of alveolar cleft but has a drawback of causing tipping of teeth in transport segment, which requires docking site surgery in order to close the cleft at the nasal side.

KEYWORDS: Alveolar cleft, distraction osteogenesis, tooth-borne distractor.

* Instructor, Department of Orthodontics, Faculty of Dentistry, Ain Shams University, Cairo, Egypt.

** Associate Professor of Orthodontics, Ain Shams University, Affiliated Associate Professor at the British University in Egypt, Senior Orthodontist at the Cleft Care Centre, Cairo, Egypt.

*** Professor, Head of Department of Oral and Maxillofacial Surgery, Faculty of Dentistry, Ain Shams University, Cairo, Egypt.

**** Associate Professor, Department of Orthodontics, Faculty of Dentistry, Ain Shams University, Cairo, Egypt.

INTRODUCTION

Cleft lip and palate (CLP) and other dentofacial abnormalities are a significant public health concern in newborns. Many dentofacial manifestations impact a kid with a cleft lip (and/or) palate abnormality, affecting both function and appearance. Other issues, such as breast-feeding difficulties due to a poor oral seal, swallowing difficulties, and nasal regurgitation. Due to nasal escape and articulation problems, the kid may experience hearing impairment and speech difficulties as hypernasality of sounds^[1].

Management of cleft patients is multidisciplinary and require many specialties including the orthodontist. During the mixed dentition stage, secondary autogenous alveolar bone grafting is mostly employed for cleft alveolus and palate repair. This technique has several advantages, including providing bone support for teeth near to the cleft, forming a bone matrix through which teeth in the cleft's line of erupt, and re-stabilizing the alveolar process contour and maxillary segments^[2,3].

In patients with large alveolar clefts, greater than the width of a maxillary canine, the greatest disadvantage of secondary grafting is the difficulty in getting complete soft tissue covering by employing the local connected gingiva. As a result, bone transplant failure may occur, necessitating additional alveolar cleft grafting procedures^[4].

Distraction osteogenesis (DO) is a technique of developing new bone by mechanically stretching pre-existing vascularized bone tissue with a distraction device, resulting in the formation of both, new alveolar bone and attached gingiva, so, it can be utilized to help reduce cleft width^[5].

IDO has been used by creating a controlled fracture, then applying a distractor device that could be bone-borne, tooth-borne, or hybrid between both. Bone-borne distractors carry the advantage of highest control on movement of the transported

segment approaching its centre of resistance, but they are coasty, trans-mucosal, so, subjected to failure, also they act through a straight line needing extensive orthodontic treatment to gain symmetric arch form and sometimes not tolerated by the candidates. Tooth-borne devices on contrary give easy manipulation, not expensive, lower morbidity and more tolerable by the patients. But they might result in dental movements rather than bony ones^[6,7,8].

Several researches using various distractor designs or brackets, opening coil springs, and wires for tooth-borne distraction along arch curvature have been conducted. Tipping of the transported teeth as well as the segment occurs, despite the fact that it is a successful treatment. This discrepancy in inclination can be addressed with orthodontic treatment, but it raises the risk of dental relapse, necessitating the use of more rigid devices^[6,7,9,10,11].

This study was conducted to evaluate the effect of a tooth-borne custom-made interdental distractor on reduction of alveolar cleft width.

MATERIALS AND METHODS

This study was performed in faculty of dentistry, Ain-Shams University, were subjects were selected from the outpatient clinic of department of Orthodontics. The ethical committee at the Faculty of Dentistry, Ain-Shams University approved the study design after reviewing the study protocol. Furthermore, the patients or their parents had signed an informed consent form authorizing us to utilize their information for research purposes.

Sample size for the study was calculated based on a significance level of 0.05 and a power of 80% to detect a clinically meaningful difference of 9 mm (± 2 mm) for reduction of cleft volume within a month through a study published in 2020^[11]. Power analysis showed that 4 subjects were required. To compensate for possible dropouts during distraction procedures and increase the power of the study, we decided to include more patients.

The inclusion criteria for the study were (1) patients with ages ranging from 12 to 25 years old, (2) patients with repaired cleft lip and / or palate, (3) patients with wide alveolar clefts more than 6 mm, (4) patients with median facial clefts or absent premaxilla and (5) patients who had previous failed grafting. The Exclusion criteria were (1) patients with contraindications to general anaesthesia and surgery, (2) patients with syndromic cleft lip and palate, (3) patients with very bad oral hygiene and (4) vulnerable groups. According to those criteria, 7 patients were included to the study after they or their parents were informed about the study protocol and the IDO procedures.

Photographs (Fig.1), orthodontic study model were taken for all cases for comprehensive diagnosis and ensuring eligibility of participants in the study. Panoramic and lateral cephalometry radiographs were not taken for study participants, referred cases with previous failed alveolar cleft grafting procedures had their initial radiographs, while new cases eligible in the study were not referred for

taking these radiographs.

Cone Beam Computed Tomography (CBCT) was taken for each patient twice; before distraction (T1) and post retention (T2) using Gendex 3D imaging system (GXDP-800, Finland,2016) and the imaging parameters are (Field of view 8x8, exposure dose 747 mGycm², 90 KVp, 6.3 mA and the acquisition time was 6.1 seconds). The pre-operative CBCT was to design the osteotomy sites precisely as well as measuring the initial cleft width and post-consolidation image to determine the extent of the residual cleft to plan docking site surgery.

Pre-distraction preparation was done through bonding pre adjusted edgewise brackets onto the teeth at the edge of planned osteotomy in order to create clearance interdentially at the site of vertical dental osteotomy. Osteotomy design was L- shape osteotomy, comprised of an inter-dental vertical osteotomy between 1st molar and 2nd premolar at the cleft side and a horizontal osteotomy above apices of teeth in the transport segment by 5mm

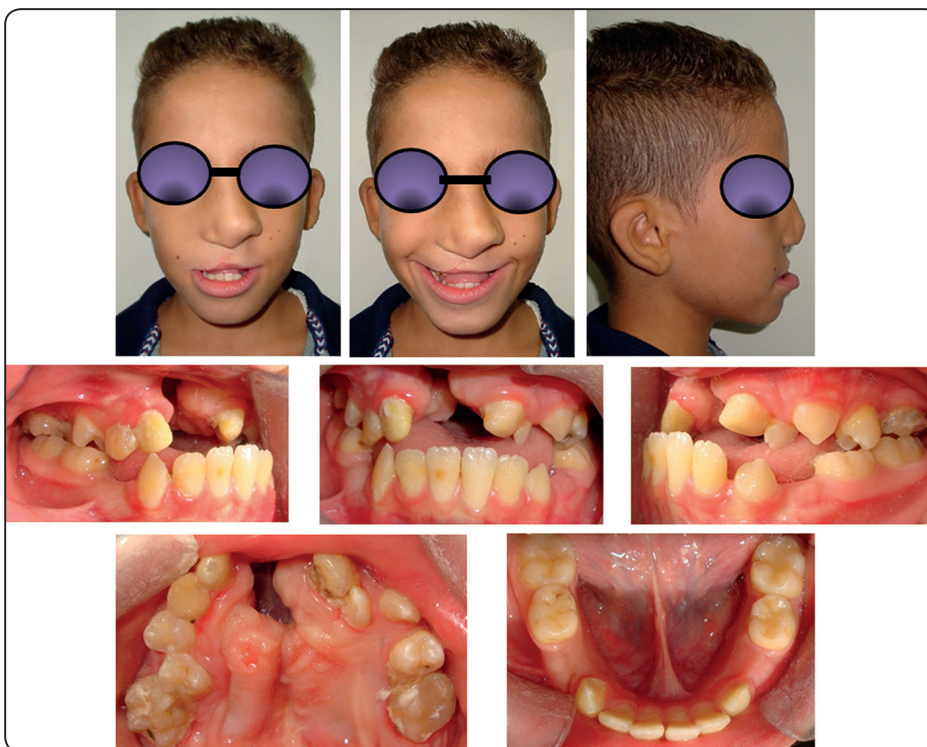


Fig. (1) Pre-treatment extraoral and intraoral photographs taken for patients showing wide alveolar cleft and an oro-nasal fistula.

with a transport segment formed of 2 or 3 teeth; 1st premolar and canine \pm lateral incisor if found and not missing.

The distractor device was custom made for each patient through taking an alginate impression material and constructing the appliance on the poured model. It was comprised of molar bands on 1st molar; the anchor tooth and 1st premolar. Upon which micro-expander screw was soldered. And it included too 2 holding arches, labial and palatal of 1mm stainless steel wire to act as a rail upon which transport segment moved anteriorly along the curvature of the arch of patient (Fig. 2).

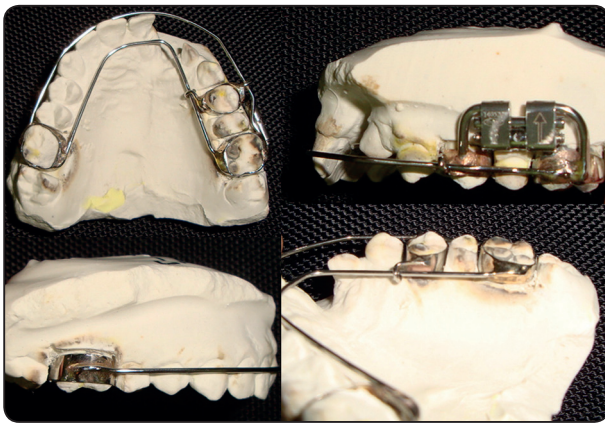


Fig. (2) The custom-made tooth-borne distractor.

The Distraction protocol advocated in this study was a latency period of 7 days to allow formation of callus. Then distraction was started with a rate of 0.4 mm /day with a rhythm of 0.2 mm twice daily. Activation proceeded until teeth at the edge of the cleft became in close contact (Fig.3,4), then a retention period of 3 months for consolidation of distracted bone was held.

CBCT Measurements

The landmarks used to assess the width of the cleft were selected after standardization and superimposition of the pre and post CBCT scans, the landmarks' identification was done, where the landmarks used were:

1. Cemento-enamel junction mesial (CEJ-Mesial): the nearest point to the cleft on the cemento-enamel junction of the tooth distal to the cleft.
2. Cemento-enamel junction distal (CEJ-Distal): the nearest point to the cleft on the cemento-enamel junction of the tooth mesial to the cleft.
3. Root apex: the most apical point of root apices of the two teeth at the edge of the cleft.

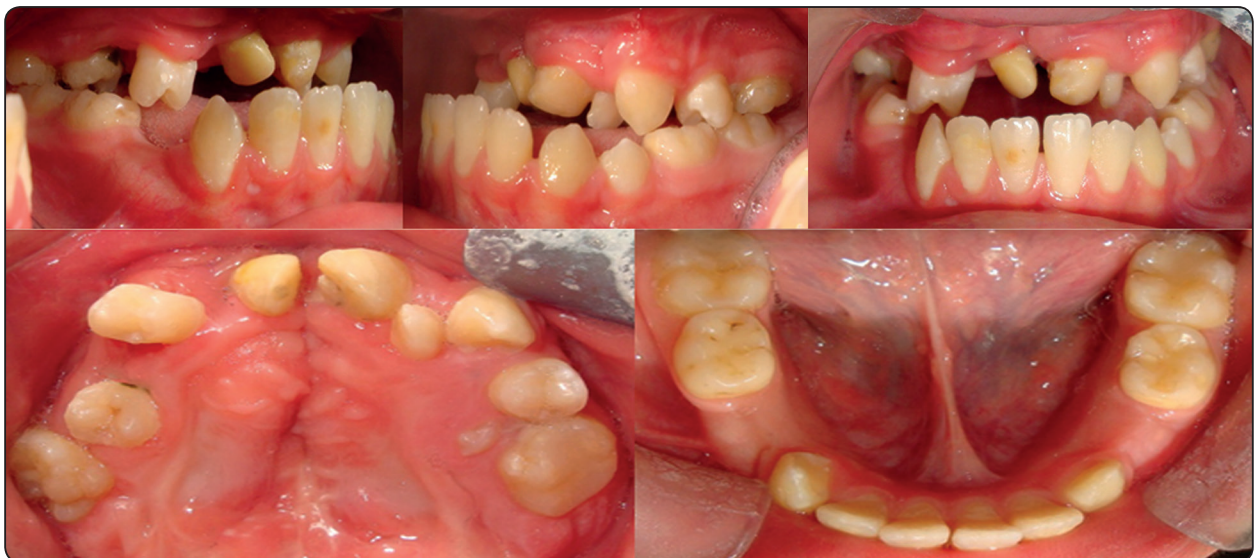

Fig. (3) Post distraction photographs.

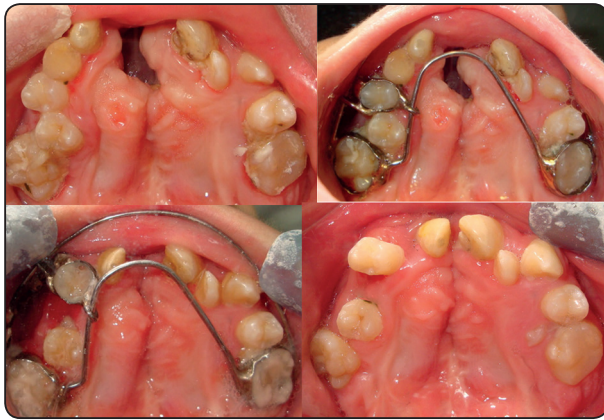

Fig. (4) Progress of the gradual reduction of cleft width.

The measurements obtained were the cleft width at the occlusal side; linear distance between CEJ-Mesial and CEJ-Distal and the cleft width at the nasal side comprised in linear distance between root apices of the same two teeth.

Statistical Analysis

Data were collected, tabulated in Microsoft Office Excel program and then statistical analysis was performed using SPSS computer program (Statistical package for the social sciences). **Shapiro-Wilk test of normality** was used to test normality hypothesis of all quantitative variables for further choice of appropriate parametric and non-parametric tests. The variables were found normally distributed allowing the use of parametric tests. **Paired sample *t* test** was used for comparing pre and post measurements. All these quantitative variables were described in form of Mean and Standard Deviation. Comparison between pre-operative and post-operative data was done using paired *t*-test. The confidence interval was set to 95% and the margin of error accepted was set to 5%. So, the *p*-value was considered significant as the following:

RESULTS

1. Clinically: The latency period events were anticipated, comprised of edema in the infraorbital

region at the operated side, that resolved gradually as well as pain that was controlled with analgesics. Upon activation the width of the cleft and fistula was lessened gradually, and a new regenerated attached gingiva appeared at the distal end of the transport segment. Activation was proceeded till teeth at the edge of the cleft came into close contact were increased tip was noticed in the tooth distal to the cleft edge.

2. Radiographically: Using CBCT, width of the cleft was measured at both acquisitions; pre and post-distraction (T1 and T2), where two measurements were taken between teeth at the edge of the cleft, width of the cleft at the occlusal edge of the cleft, and at the level of root apices (Table 1,2).

TABLE (1) Width of the cleft at the occlusal side.

Width of the cleft at occlusal end (mean \pm SD)	
Pre-distraction	12.70 \pm 4.00 mm
Post-distraction	5.70 \pm 2.40 mm
Difference	6.99 \pm 2.51 mm
95% Confidence Interval	10.99825
P-value	0.011

P < 0.05: Statistically significant

TABLE (2) Width of the cleft at the cranial side.

Width of the cleft at cranial end (mean \pm SD)	
Pre-distraction	18.33 \pm 7.33 mm
Post-distraction	13.84 \pm 6.24 mm
Difference	6.55 \pm 6.44 mm
95% Confidence Interval	8.22926
P-value	0 .031

P < 0.05: Statistically significant

Width of the cleft at the caudal end at the level of alveolar crest of tooth mesial to the edge of cleft was 12.70 ± 4 mm pre- distraction, after activation it was lessened to 5.70 ± 2.40 mm denoting a mean difference of 6.99 ± 2.51 mm reduction of cleft width at the interdental area occlusally, with a P-value (0.011) giving a statistical significant difference in width of cleft before and after distraction.

Regarding the nasal or cranial end of the alveolar cleft, distance spanning the root apices of teeth at the edge of the cleft pre-distraction was 18.33 ± 7.33 mm, which was greater than width at the occlusal end, after distraction it became 13.84 ± 6.24 mm,

with a mean reduction in width 6.55 ± 6.44 mm that was nearly comparable to the difference at the occlusal end. A statistical difference was found in alveolar cleft width reduction at the cranial end with a P-value (0.031).

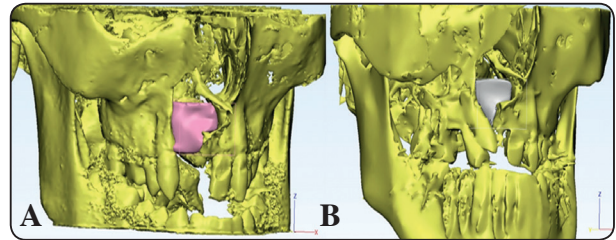


Fig. 5 (A) Pre-distraction cleft size and (B) post-distraction.

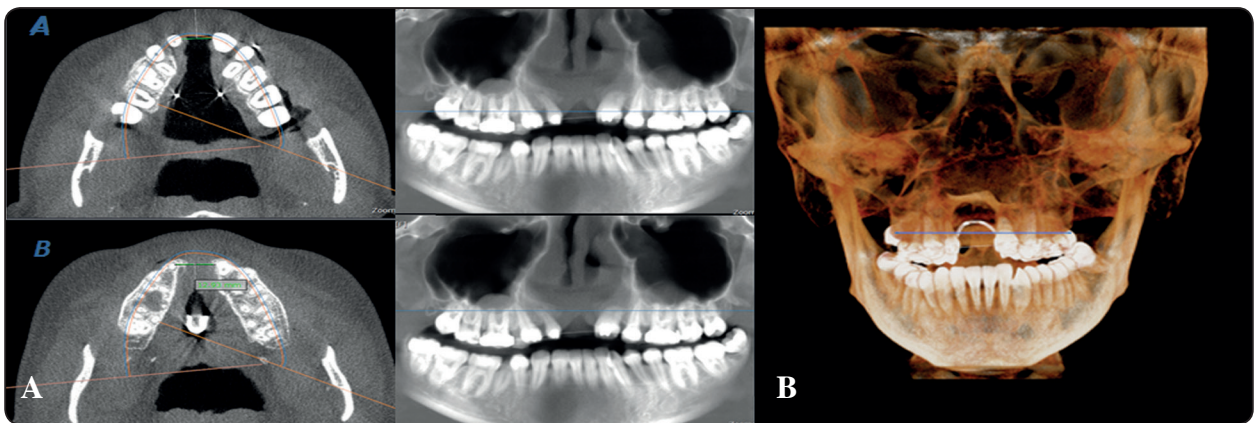


Fig. (6): Pre-distraction width of the cleft, (A) at occlusal side, (B) at cranial side.

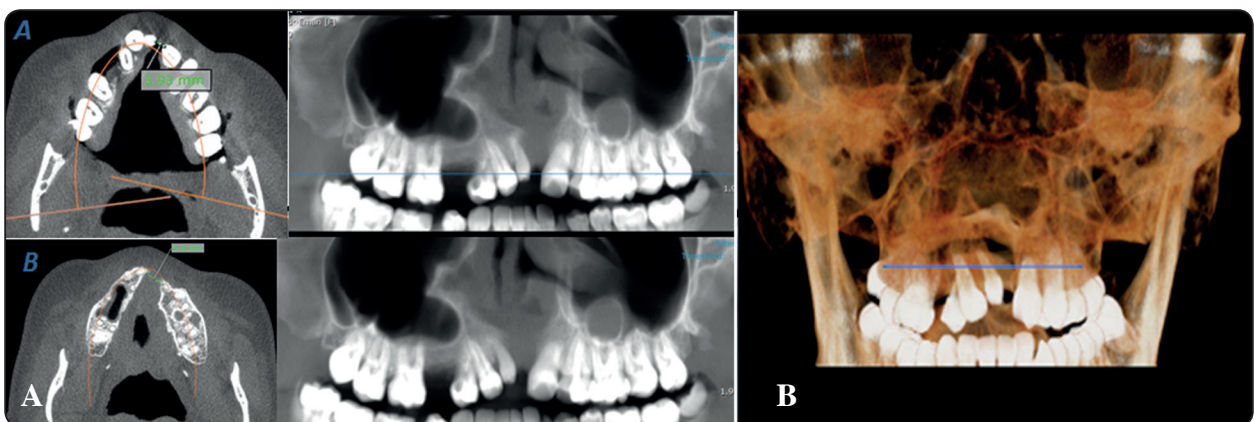


Fig. (7) Post-distraction width of the cleft, (A) at occlusal side, (B) at cranial side.

DISCUSSION

Attaining continuity of maxillary arch is a crucial step in cleft lip and palate patients' treatment. It provides bone support for teeth adjacent to the cleft, creating a bone matrix through which teeth in the line of the cleft can erupt, permits safely orthodontic tooth movement and insertion of dental implants, re-stabilize alveolar process contour and maxillary segments, especially in bilateral cases, continuity of maxillary arch form supporting arch width, minimizing maxillary arch collapse, improve nasal shape, good alar base, and nasolabial support^[2,7,12].

For patients with wide alveolar clefts, interdental distraction osteogenesis was used since 2000^[13,14] in such cases for reduction of the cleft size giving a better prognosis for future secondary alveolar cleft grafting procedure, besides, the formation of a newly regenerated bone and attached gingiva permits alignment of teeth with relief of any existing dental crowding and placement of implants in short time which all-over decrease the total time of orthodontic treatment^[4,15,16].

The micro-expander used in the study was small that it was cemented before the operation with no interference with performing osteotomies, it was convenient for patients, not encroaching their vestibule and cheek and it provided guided anterior movement of segment along patients' arch form through the buccal and palatal holding arches; acting as a rail upon which transport segment was carried forward.

Earlier studies using tooth-borne interdental distraction osteogenesis (IDO) faced some drawbacks comprised in tipping of teeth in transport segment as well as cranial shift, more rigid appliances were bulky while others required levelling and alignment till reaching heavy archwire and performing archwise distraction which was time consuming, so, up till now there was no ideal appliance for IDO along archwire curvature which is simple and rigid enough to reduce width of alveolar cleft^[3,6,17,18].

Width of the cleft examined in this study was performed on CBCT scans, where pre and post distraction CBCT scans were examined (Fig.5). Since in tooth-borne distractors from literature, tipping was encountered, cleft width was examined at 2 levels; occlusal at level of alveolar crest of the tooth mesial to the cleft and a cranial width at the level of root apex. So, distance spanning the two teeth at the edge of the cleft before and after distraction at these 2 levels was measured (Fig.6,7).

It was observed that the width of the cleft at the occlusal level was having a mean of 12.70 ± 4 mm, after distraction it was lessened to 5.70 ± 2.40 mm, denoting a difference of 6.9 ± 2.51 mm. With a P-value of (0.011) showing a statistically significant difference in reduction of width of the cleft at the occlusal side. Moving upward toward the nasal side of the cleft, the width of the cleft was 18.33 ± 7.33 mm before distraction, that was reduced into 13.84 ± 6.24 mm with a difference of 6.5 ± 6.4 mm which is less than the amount of cleft width reduction at the occlusal end, denoting tipping of the segment on moving anteriorly.

CONCLUSION

Tooth-borne appliances for inter-dental distraction osteogenesis provide an affordable and cheap solution for reduction of wide alveolar clefts and creation of newly regenerated bone and attached gingiva distal to the transport segment, but this appliance possesses some drawbacks comprised in tipping of teeth in the transport segment leaving behind residual cleft at the nasal side that will need later on docking site surgery.

REFERENCES

1. Rezaq Alswairki HJ, Abd El-Sayed FA, Fouda MY, Fahim FH, Haque S and Alam MK. Incidence of Egyptian live births of cleft lip and/or palate in Cairo, Luxor, Aswan and New Valley Governorates: A survey study in 237,783 children. *Pesqui Bras Odontopediatria Clin Integr.* 2019; 19(1):1-9.

2. Waite PD and Waite DE. Bone grafting for the alveolar cleft defect. *Semin Orthod.* 1996;2(3):192-196.
3. Erverdi N, Motro M, Gozneli R and Kucukkeles N. A novel vector control device in horizontal bone transport. *J Oral Maxillofac Surg.* 2013;71(4):768-774.
4. Liou EJW and Chen PKT. Intraoral Distraction of Segmental Osteotomies and Miniscrews in Management of Alveolar Cleft. *Semin Orthod.* 2009;15(4):257-267.
5. Cheung LK, Chua HD and Bendeus M. Distraction or osteotomy for the correction of maxillary cleft deformities: which is better? *Ann R Australas Coll Dent Surg.* 2004;17:57-63.
6. Erverdi N, Küçükkeleş N, Şener C and Selamet BU. Interdental distraction osteogenesis for the management of alveolar clefts: Archwise distraction. *Int J Oral Maxillofac Surg.* 2012;41(1):37-41.
7. Hegab AF. Closure of the alveolar cleft by bone segment transport using an intraoral tooth-borne custom-made distraction device. *J Oral Maxillofac Surg.* 2012;70(5):337-348.
8. Bousdras V, Liyanage C, Mars M and Ayliffe P. Segmental maxillary distraction with a novel device for closure of a wide alveolar cleft. *Ann Maxillofac Surg.* 2014;4(1):60.
9. Zemann W and Pichelmayer M. Maxillary segmental distraction in children with unilateral clefts of lip, palate, and alveolus. *Oral Surgery, Oral Med Oral Pathol Oral Radiol Endodontology.* 2011;111(6):688-692.
10. Dolanmaz D, Karaman AI, Durmus E and Malkoc S. Management of alveolar clefts using dento-osseous transport distraction osteogenesis. *Angle Orthod.* 2003;73(6):723-729.
11. Taha M, Nowair I, Khedr MS and Khalifa ME. Evaluation of Two Different Distraction Osteogenesis Techniques In Treatment of Unilateral Alveolar Cleft. *World Journal Of Advance Healthcare Research* 2020;4(1):207-213.
12. Larsen PE. Reconstruction of the alveolar cleft. *Peterson's Princ oral Maxillofac surgery* 2nd ed (Ed M Miloro) New York. Published online 2004:859-870.
13. Yen SL, Gross J, Wang P and Yamashita DD. Closure of a large alveolar cleft by bony transport of a posterior segment using orthodontic archwires attached to bone: report of a case. *J oral Maxillofac Surg Off J Am Assoc Oral Maxillofac Surg.* 2001;59(6):688-691.
14. Liou EJ, Chen PK, Huang CS and Chen YR. Interdental distraction osteogenesis and rapid orthodontic tooth movement: a novel approach to approximate a wide alveolar cleft or bony defect. *Plast Reconstr Surg.* 2000;105(4):1262-1272.
15. Mitsugi M, Ito O and Alcalde RE. Maxillary bone transportation in alveolar cleft-transport distraction osteogenesis for treatment of alveolar cleft repair. *Br J Plast Surg.* 2005;58(5):619-625.
16. Sakamoto T, Ishii T, Sueishi K and Uchiyama T. Interdental Distraction Osteogenesis in Unilateral Cleft Lip and Palate Patient with Wide Alveolar Cleft. *Bull Tokyo Dent Coll.* 2020;61(3):201-209.
17. Fahim FHE, El-kader WA and El-boghdady D. Reduction of Alveolar Clefts by Distraction Osteogenesis in Unilateral Cleft Patients. Doctoral thesis, Cairo university, 2011
18. Neha, Tripathi T, Mohanty S and Rai P. A Novel Minimally Invasive Technique of Using Tooth-Borne Hyrax Expansion Screw for Distraction Osteogenesis of Large Alveolar Cleft Defects (HYDIS-TB). *Cleft palate-craniofacial J Off Publ Am Cleft Palate-Craniofacial Assoc.* 2018;55(6):895-902.