

## Replacement of Complicated VP Shunts with Endoscopic Third Ventriculostomy, Local Experience and Outcome

Karam Kenawy, Khalid Naser, Abdin K. Kasim\*

Department of Neurosurgery, Faculty of Medicine, Sohag University, Sohag, Egypt

\*Corresponding author: Abdin K. Kasim, Mobile: (+20) 01020196831, E-Mail: abdin\_mail@yahoo.com

### ABSTRACT

**Background:** Until recent breakthroughs in neuroendoscopy, the ventriculoperitoneal (VP) shunt remained the mainstay of hydrocephalus therapy. However, shunt complications, including obstruction, infection and overshunting are frequent. Getting out of the siege of VP shunt is the dream of those patients.

**Objective:** This study aimed to present our experience in managing VP shunt complications by endoscopic third ventriculostomy (ETV) and shunt removal.

**Patients and Methods:** We reviewed 18 consecutive patients during the period from January 2017 to December 2020 with different ventriculoperitoneal shunt complications. The authors retrospectively evaluated the causes, preoperative symptoms, and postoperative results for those patients who underwent ETV and shunt removal for management of shunt complications. **Results:** There were 11 males and 7 females with mean age of 12.9 years old. The mean shunt duration was 8 years. Shunts were unilateral (15 cases) or bilateral (3 cases). Shunt complications included: shunt obstruction (9 cases), shunt infection (8 cases) and overshunting (1 case). ETV was done in all cases with septostomy in 7 cases. The mean follow up period was 15 months during which, 15 patients were shunt independent while three patients needed new shunts within the first postoperative month. While transient CSF leak occurred in 4 cases, there was no mortality in this series.

**Conclusion:** Removing a VP shunt and replacing it with ETV with or without septostomy is a possible option in managing shunt complication.

**Keywords:** Hydrocephalus, ETV, Neuroendoscopy, VP Shunt complications.

### INTRODUCTION

Endoscopic third ventriculostomy (ETV) is a common therapeutic method for obstructive hydrocephalus. In 1923, an urologist named William Mixer used an ureteroscope to fenestrate the third ventricle floor for the first time <sup>(1)</sup>. The invention of valve-regulated shunting technology has shown to be a successful therapy for a variety of hydrocephalus forms <sup>(2)</sup>. There has been an increase in the use of endoscopes for ETV and management of various ventricular lesions as technology advances, such as modern endoscopes with fiber-optics and advanced light sources that allow for excellent resolution of ventricular anatomy and control the safe fenestration of the floor of the third ventricle <sup>(2)</sup>.

ETV has been used to treat shunt dysfunction in individuals with obstructive hydrocephalus based on imaging findings. Because of the likelihood of shunt independence following successful ETV, it is worth considering in patients with shunt problems. ETV has a success rate of 67 to 80% in treating shunt malfunction or infection <sup>(1,3,4,5)</sup>.

If chosen correctly, ETV is a successful and safe therapy for individuals with shunt dysfunction. There is no consensus on what will happen to the shunts that were previously implanted in this patient population. Many studies have addressed the shunt by removing it, ligating it, externalising it, or removing it and replacing it with an external ventricular drain. According to Nishiyama *et al.* <sup>(6)</sup>, there is a gradual shift from a shunt-dependent state to a shunt-independent state over the course of 1 week following ETV.

The function of continued cerebrospinal fluid (CSF) diversion is still debatable, since shunt-dependence is gradually replaced by shunt-independence. Furthermore, there is a theoretical danger that CSF diversion will reduce flow via the ventriculostomy, lowering the success rate. For the maturity of the fistulous link, some feel that continuous flow is required <sup>(2)</sup>.

The goal of the current study was to present our experience with endoscopic third ventriculostomy for management of shunt malfunction and infection highlighting our methods, results and potential complications.

### PATIENTS AND METHODS

From January 2017 to December 2020, at the Neurosurgical Department of Sohag University Hospital, Sohag University, 18 patients with complicated VP shunt were endoscopically managed for their shunt complications.

**Inclusion criteria:** Age of 1 year or more, unilateral or bilateral VP shunts, history of at least 1 time previous shunt revision, presentation with shunt complication, and not associated with active brain tumors.

#### Preoperative Evaluation:

All patients underwent preoperative clinical and routine laboratory evaluation. All patients were subjected to CT and / or MRI brain prior to surgery.

#### Surgical approach:

Endoscopic third ventriculostomy with or without septostomy was done with one of the following options:

1. **Endoscopy with primary shunt removal:** For patients presented with distally infected shunts, we did endoscopy and removed the shunt in the same procedure.
2. **Endoscopy with delayed shunt removal:** For patients presented with shunt complications other than infection, we did endoscopy with shunt ligation, then removal of the shunt after 1 week.
3. **Endoscopy after shunt removal:** For patients presented with overshunting resulting in subdural hematoma. They were subjected to drainage of subdural haematoma and shunt removal, then waiting period for about 2 days before we did ETV. Also for patients with proximal shunt infection, we used external ventricular drain before doing endoscopy.

**Septostomy was done in the following conditions:** Bilateral shunts. Unilateral dilatation of the lateral ventricle, and if the proximal VP shunt tube crosses the septum pellucidum to the other lateral ventricle.

**Ethical consent:**

An approval of the study was obtained from Sohag University Academic and Ethical committee. Every patient signed an informed written consent for acceptance of the operation. This work has been carried out in accordance with The Code of Ethics of the World Medical Association (Declaration of Helsinki) for studies involving humans.

**Statistical analysis:**

The collected data were coded, processed and analyzed using SPSS (Statistical Package for Social Sciences) version 22 for Windows® (IBM SPSS Inc., Chicago, IL, USA). Data were tested for normal distribution using the Shapiro Walk test. Qualitative data were represented as frequencies and relative percentages. Chi square test ( $\chi^2$ ) was used to calculate difference between two or more groups of qualitative variables. Quantitative data were expressed as mean  $\pm$  SD (Standard deviation). Independent samples t-test was used to compare between two independent groups of normally distributed variables (parametric data). P value  $\leq$  0.05 was considered significant.

**RESULTS**

Eighteen consecutive patients with complicated VP shunts were included in this study. Out of 18 cases, 7 were females (39 %) and 11 were males (61 %). Age varied from 1 to 17 years with a mean of 12.9 years (Table 1).

**Table (1):** Age and sex incidence:

Age group (Years)	No of Cases	Male / Female
1 – 3	4	1 / 3
3 – 6	6	4 / 2
Above 6 years	8	6 / 2
<b>Total</b>	<b>18</b>	<b>11 / 7</b>

About 44.4% had congenital aqueductal stenosis while brain tumors were least common cause (Table 2).

**Table (2):** Causes of hydrocephalus:

Underlying Cause	No of Patients	%
Congenital aqueductal stenosis	8	44.4
Post hemorrhagic	4	22.2
Post infectious	4	22.2
Brain tumors	2	11.1

RT shunts were found in 12 cases (66.7 %), LT shunts were found in 3 cases (16.6) and bilateral shunts were found in 3 cases (16.7 %) (Table 3).

**Table (3):** Shunt side:

Side of shunt	Right	Left	Bilateral
<b>No of Cases</b>	12	3	3

Shunt obstruction was present in 50 % followed by infection in 44.4% of cases and overshunting in 5.6% (Table 4).

**Table (4):** Type of shunt complication:

Complication	No of Cases	%
Obstruction	9	50
Infection	8	44.4
Overshunting	1	5.6

We replaced shunts by ETV alone in 11 cases while in 7 cases, we added septostomy (Table 5).

**Table (5):** Treatment success:

Procedure	No of Cases	Results	
		Succeeded	Failed
ETV alone	11	9	2
ETV + Septostomy	7	6	1
<b>Total</b>	<b>18</b>	<b>15</b>	<b>3</b>

CSF leak occurred in 4 patients. C.S.F leak was minimal and stopped spontaneously after 2 days of conservative treatment in one case while repeated lumbar puncture (2 to 4 times daily) could control the other 3 cases. In two cases with shunt infection, the ETV procedure failed to control hydrocephalus and we reinserted a VP shunt after 5 days in one case and after 3 weeks in the other case. A third case with history of post hemorrhagic hydrocephalus needed reshunting on the 8<sup>th</sup> postoperative day after failure of ETV and septostomy. There was no mortality in our series (Table 6).

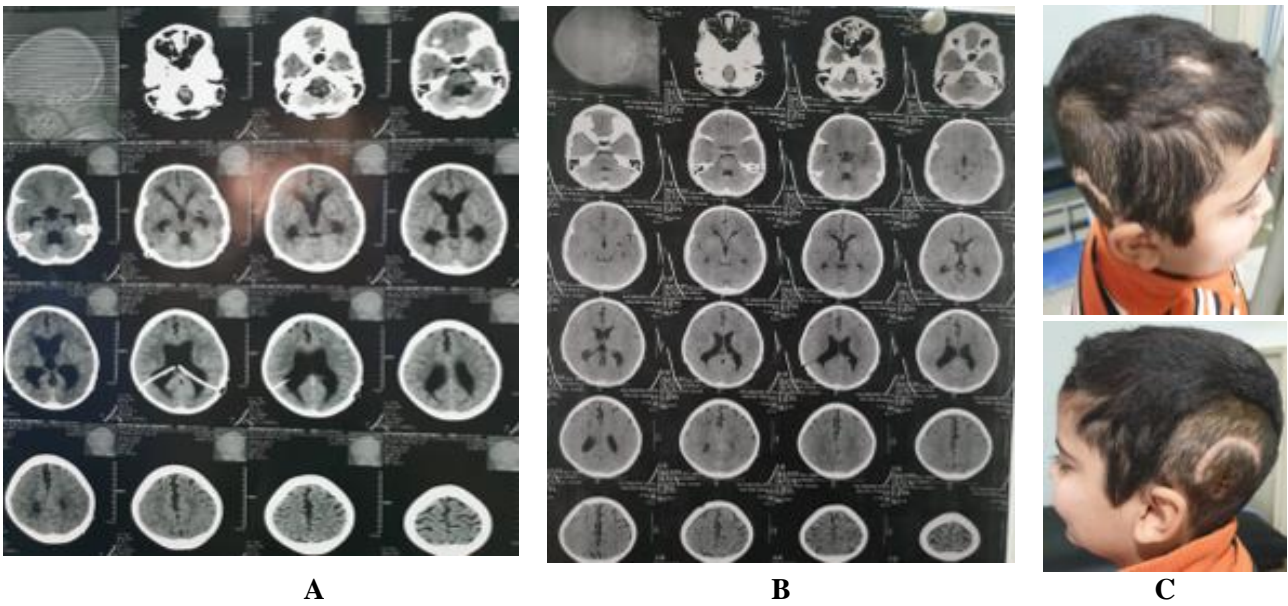
**Table (6):** Postoperative complications:

Complication	No of Cases	%
CSF leak	4	44.4
Wound infection	3	16.7
Failure and reshunting	3	16.7

Post-operative follow up: Follow up period ranged from 6 to 24 month.

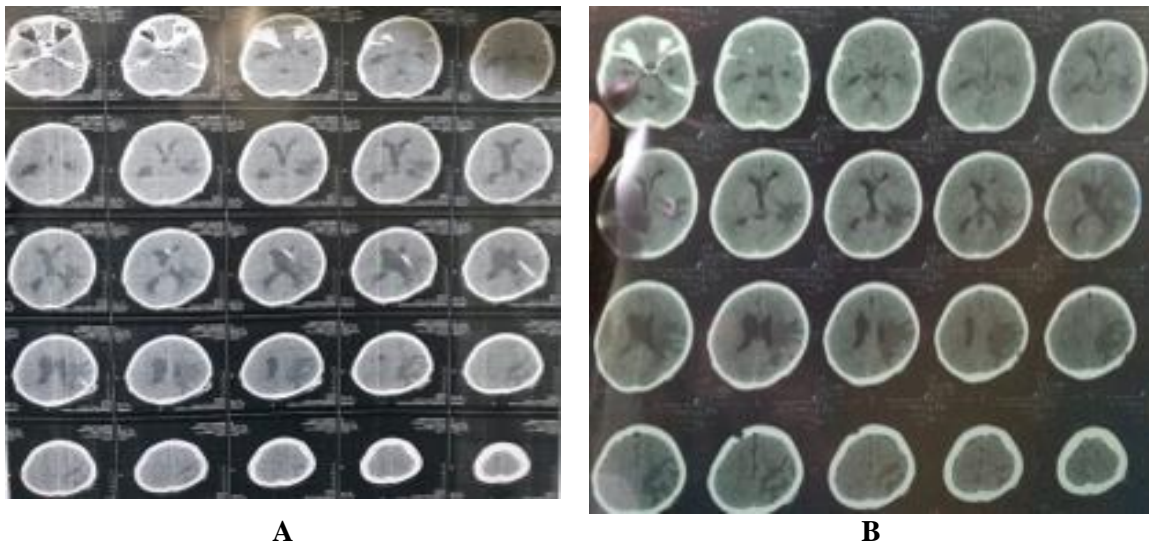
**CASE PRESENTATIONS**

**CASE 1**



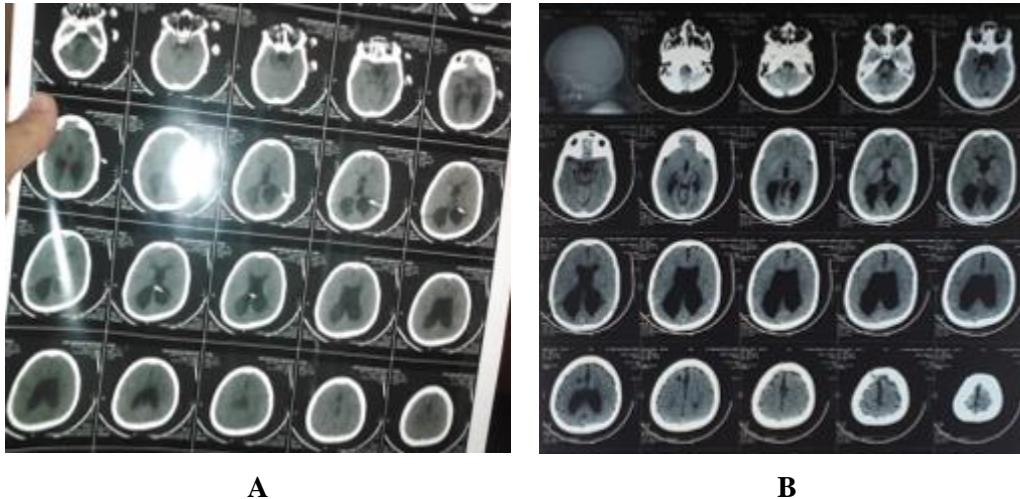
**Figure (1):** Preoperative (A) and postoperative (B) CT scans of a 10-years old boy (C) with bilateral obstructed VP shunts replaced by ETV with septostomy. He had 7 previous operations to treat shunt failure.

**CASE (2)**



**Figure (2):** Preoperative (A) and postoperative (B) CT scans of 11-years old boy with Lt sided obstructed VP shunt replaced by ETV with septostomy. He had 5 previous operations to treat shunt failure and infection.

**CASE (3)**



**Figure (3):** Preoperative (A) and Postoperative (B) CT scans of a 5-years girl with a left side distally infected VP shunt replaced by ETV with septostomy. She had 4 previous operations to treat shunt malfunction and infection.

**DISCUSSION**

Shunt malfunction is well-known VP shunts complication with rates ranging from 25% to 40% in the first year followed by shunt installation to roughly 4% to 5% each year after that <sup>(7)</sup>. Shunt failure is practically unavoidable during the course of patient's life, with 81% of shunts requiring correction after 12 years <sup>(8)</sup>. Shunt infection is rather common, with usual reported rates of 5% to 10% <sup>(9)</sup>, and it has been found to reach up to 19% in a short sequence of studies <sup>(10,11)</sup>.

Concerning shunt independency rate, many authors regard ETV to be an effective therapy for shunt malfunction or infection in patients with obstructive hydrocephalus, with a success rate of more than 80% <sup>(5, 12, and 13)</sup>. In our study, ETV was used in management of shunt complications in 18 cases and was successful in 15 out of 18 cases (83.3%). This higher success rate may be justified with very strict selection criteria in our early series. In two cases with shunt infection (post-meningitic) and one case of shunt obstruction (post-hemorrhagic), the ETV procedure failed to control hydrocephalus and we reinserted a VP shunt within the first postoperative month.

Regarding management of shunt hardware, three options were mentioned by authors regarding shunt hardware: (1) Complete removal of hardware: It should be done wherever possible, because of the following: First, a partially functioning shunt may decrease the flow through the ventriculostomy opening leading to its closure. Second, to avoid complications of retained shunt, as chronic infection and even organ perforation <sup>(14, 15)</sup>. It should be taken in consideration that sometimes, shunts can be difficult to be removed, particularly after years of insertion <sup>(4, 15)</sup>. (2) Shunt ligation: It is done if there is difficulty in removing shunt. This will lower risk of intraventricular haemorrhage <sup>(16)</sup>. (3) Leave hardware in place: It is not preferred, but there is a theoretical benefit. This

includes a lower risk of intracranial haemorrhage and trauma with shunts inserted since long time <sup>(2)</sup>. However, this strategy could have dismal results. In one study including three patients with retained shunt hardware, two patients developed shunt infection and the third patient had wound dehiscence. Patients were managed by shunt removal <sup>(17)</sup>.

In our study, we succeeded to remove shunt hardware in all patients and none of them developed considerable related complications. Our strategy included timing of hardware removal as the following: (1) Primary shunt removal: For patients presented with distally infected shunts, we removed the shunt in the same session from a separate abdominal wound to control infection. (2) Delayed shunt removal: Shunt ligation was used to encourage CSF flow from the ETV route then the shunt was removed after 1 week as a test period. (3) Endoscopy after shunt removal: For patients presented with overshunting resulting in subdural hematoma. They were subjected to drainage of subdural haematoma and shunt removal, then waiting period for about 2 days to allow brain expansion to allow compressing of the subdural space before we did ETV. We think this can help to avoid development of subdural hygroma. Also, for patients with proximal shunt infection, we used external ventricular drain to control infection before doing endoscopy.

We were able to remove the proximal shunt tubes and reservoirs in all patients but the distal shunt tube couldn't be removed in 2 patients with longstanding shunts of more than 5 years duration. None of our patients developed considerable related complications.

Concerning rational for septostomy: Bilateral shunts, the rational was to insure communication of both ventricles which are potentially isolated and to

free both ventricular shunt tubes from adhesions prior to shunt removal. Unilateral dilatation of the lateral ventricle: In this situation, we entered the dilated lateral ventricle first and communicated it to its mate by septostomy. If the proximal VP shunt tube crosses the septum pellucidum to the other lateral ventricle: in this case the shunt may be draining both ventricles before malfunction and so, adhesiolysis was done leaving a septostomy opening.

**Secondary ETV failure:** Secondary ETV failure presents a management challenge. The choice is between repeating (“redo”) ETV procedure or a different CSF diversion procedure. Existing studies also suggest that redo ETV is more technically challenging in patients with failed secondary ETV (11, 16). In our study, we had 3 cases with secondary ETV failure (16.6 %). We preferred to manage these cases by shunt insertion due to above mentioned reason taking in consideration that our series is an early experience for us.

## CONCLUSION

Removing VP shunt and replacing it with ETV with or without septostomy is a safe and effective option in managing shunt complication. Success rate is higher if the patient has no history of post-infectious or post-hemorrhagic hydrocephalus.

**Financial support and sponsorship:** Nil.

**Conflict of interest:** Nil.

## REFERENCES

1. **Jenkinson M, Hayhurst C, Al-Jumaily M et al. (2009):** The role of endoscopic third ventriculostomy in adult patients with hydrocephalus. *J Neurosurg.*, 110: 861-6.
2. **Neils D, Wang H, Lin J (2013):** Endoscopic third ventriculostomy for shunt malfunction: What to do with the shunt? *Surg Neurol Int.*, 4: 3-7.
3. **Cinalli G, Salazar C, Mallucci C et al. (1998):** The role of endoscopic third ventriculostomy in the management of shunt malfunction. *Neurosurgery*, 43: 1323-27.
4. **Hader W, Walker R, Myles S et al. (2008):** Complications of endoscopic third ventriculostomy in previously shunted patients. *J Neurosurg.*, 63 (1): 168-74.
5. **O'Brien D, Javadpour M, Collins D et al. (2005):** Endoscopic third ventriculostomy: An outcome analysis of primary cases and procedures performed after ventriculoperitoneal shunt malfunction. *Arq Neuropsiquiatr.*, 103 (5): 393-400.
6. **Nishiyama K, Mori H, Tanaka R (2003):** Changes in cerebrospinal fluid hydrodynamics following endoscopic third ventriculostomy for shunt-dependent noncommunicating hydrocephalus. *J Neurosurg.*, 98: 1027-31.
7. **Drake J, Kestle J, Tuli S (2000):** CSF shunts 50 years on— past, present and future. *Childs Nerv Syst.*, 16: 800–804
8. **Sainte-Rose C, Piatt J, Renier D et al. (1992):** Mechanical complications in shunts. *Pediatr Neurosurg.*, 17: 2-9.
9. **Duhaime A (2006):** Evaluation and management of shunt infections in children with hydrocephalus. *Clin Pediatr (Phila)*, 45: 705-713.
10. **Braga M, Carvalho G, Brandão R et al. (2009):** Early shunt complications in 46 children with hydrocephalus. *Arq Neuropsiquiatr.*, 67: 273-277
11. **Di Rocco C, Massimi L, Tamburrini G (2006):** Shunts vs endoscopic third ventriculostomy in infants: are there different types and/or rates of complications? A review. *Childs Nerv Syst.*, 22: 1573-1589
12. **Talamonti G, Nichelatti M, Picano M et al. (2019):** Endoscopic Third Ventriculostomy in Cases of Ventriculoperitoneal Shunt Malfunction: Does Shunt Duration Play a Role? *World Neurosurg.*, 127: 799-808.
13. **Buxton N, Macarthur D, Robertson I et al. (2003):** Neuroendoscopic third ventriculostomy for failed shunts. *Surg Neurol.*, 60: 201–3.
14. **Bilginer B, Oguz K, Akalan N (2009):** Endoscopic third ventriculostomy for malfunction in previously shunted infants. *Childs Nerv Syst.*, 25: 683-8.
15. **Waqar M, Ellenbogen J, Mallucci C (2018):** Endoscopic third ventriculostomy for shunt malfunction in children: A review. *J Clin Neurosci.*, 51: 6-11.
16. **Brichtova E, Chlachula M, Hrbac T et al. (2013):** Endoscopic third ventriculostomy in previously shunted children. *Minim Invasive Surg.*, 14:584-588.
17. **Pindrik J, Jallo G, Ahn E (2013):** Complications and subsequent removal of retained shunt hardware after endoscopic third ventriculostomy: case series. *J Neurosurg Pediatrics*, 11: 722-6.