

Assessment and Surgical Correction of The Long Nose

Original
Article

*Amr Ossama Abdelhamid, Hesham El-Sersy, Amr Rabie, Talaat El-Samny,
Mohammed Aleem*

*Department of Otorhinolaryngology, Faculty of Medicine, Ain Shams University, Cairo,
Egypt.*

ABSTRACT

Introduction: The long nose represents one of the most undesirable features in facial aesthetics leading to facial disharmony. Despite being a common feature, review of the surgical literature shows that little attention has been given to analyze and manage the long nose.

Aim: Identify the causes of long nose in the Egyptian population and proposed a surgical algorithm for correction of the long nose deformity.

Patients and Methods: Fifty patients with long nose deformity were recruited in this study. Assessment to identify cause of long nose in addition to pre-operative measurements of nasal length, projection, nasolabial and nasofrontal angles were recorded and compared with the postoperative measurements after correction with the proposed algorithm.

Results: Multifactorial causes contribute to the long nose deformity. Most common cause in our study is lack of nasal tip support in 94% of the cases, this was due to either long weak inferiorly oriented lower lateral cartilages in 35 patients or short weak medial crura in 12 patients. 76% of the cases had an under-projected tip in association with the long nose deformity. Our proposed surgical algorithm shows highly significant statistical difference between the pre-operative and post-operative nasal length as well as nasal tip projection.

Conclusion: Multiple factors contribute to the long nose deformity. Egyptians most commonly have a long nose with under-projected tip due to lack of nasal tip support. Following a Surgical algorithm in rhinoplasty is helpful stepwise approach to plan for surgery however each operation must be tailored accordingly to each patient.

Key Words: Droopy tip, long nose, rhinoplasty.

Received: 11 March 2022, **Accepted:** 29 March 2022

Corresponding Author: Amr Ossama Abdelhamid, MSc, Department of Otorhinolaryngology, Faculty of Medicine, Ain Shams, Cairo, Egypt, **Tel.:** 00201224974405, **E-mail:** amrhamid11@gmail.com

ISSN: 2090-0740, 2022

INTRODUCTION

Rhinoplasty is considered one of the most complex cosmetic surgical procedures performed today, since it is characterized by an intricate interplay between form and function. The prerequisite for successful execution of this challenging procedure is a thorough understanding of the nasal anatomy and physiology^[1]. Moreover, comprehensive clinical analysis and definition of goals, preoperative preparation, precise operative execution, postoperative management, and critical analysis of one's results are considered essential principles for successful rhinoplasty^[2].

The long nose represents one of the most undesirable features in facial aesthetics that may lead to disturbance in the harmony of the face. Despite being a common feature, review of the surgical literature shows that little attention has been given to analyze, evaluate and manage the long nose^[3]. With this in mind, we looked to investigate

the different causes that contribute to the long nose in the Egyptian population and formulate a treatment algorithm for correction.

PATIENTS AND METHODS:

Fifty patients were recruited in our study which was conducted in Ain Shams University Hospitals in the time period between February 2017 to October 2019. All participants signed an informed consent after explaining to them the objective of the study.

The selected patients underwent thorough history and examination to diagnose the underlying deformity. This was followed by preoperative photographs which included frontal, lateral, oblique and basal views. The preoperative lateral view photographs were used to record the nasofrontal angle, nasolabial angle, tip projection in

relation to nasal length using Goode's method and nasal length in relation to midfacial height (Fig 1). These measurements were taken using the software Adobe® Photoshop® CS6. We used these data to study the causes

of long nose in the Egyptian population. In addition to the above measurements we also assessed the degree of skin thickness in our cohort of patients.

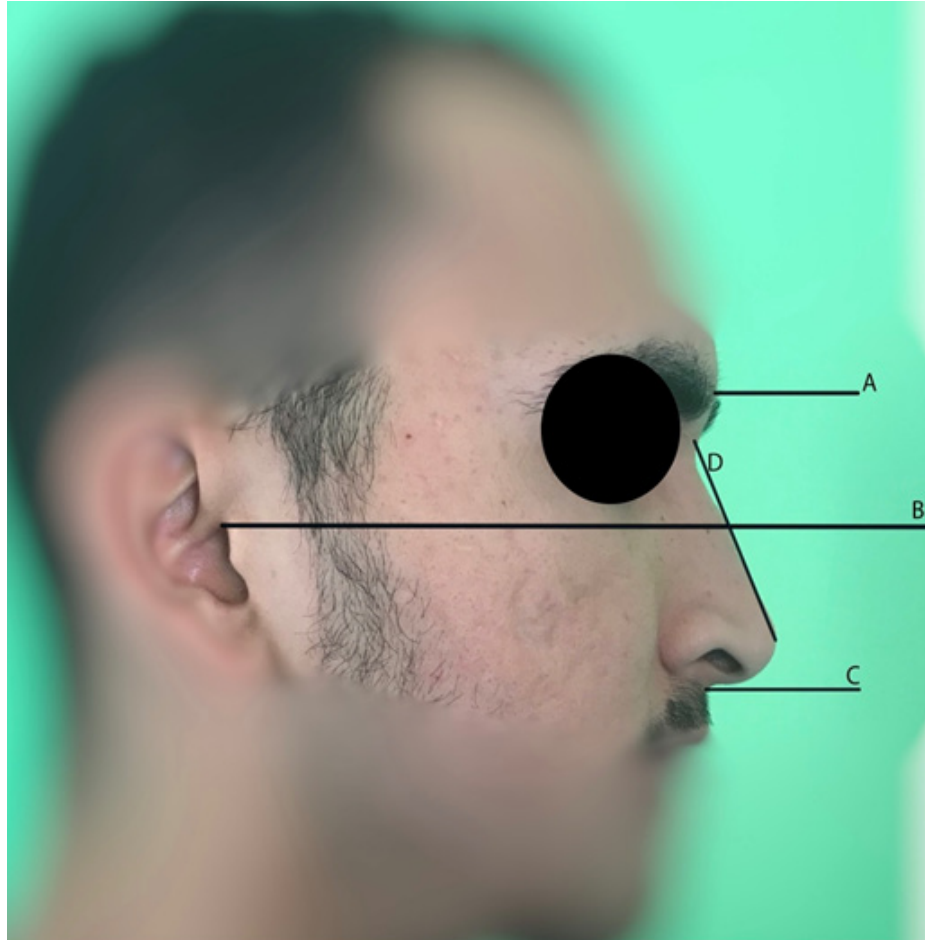
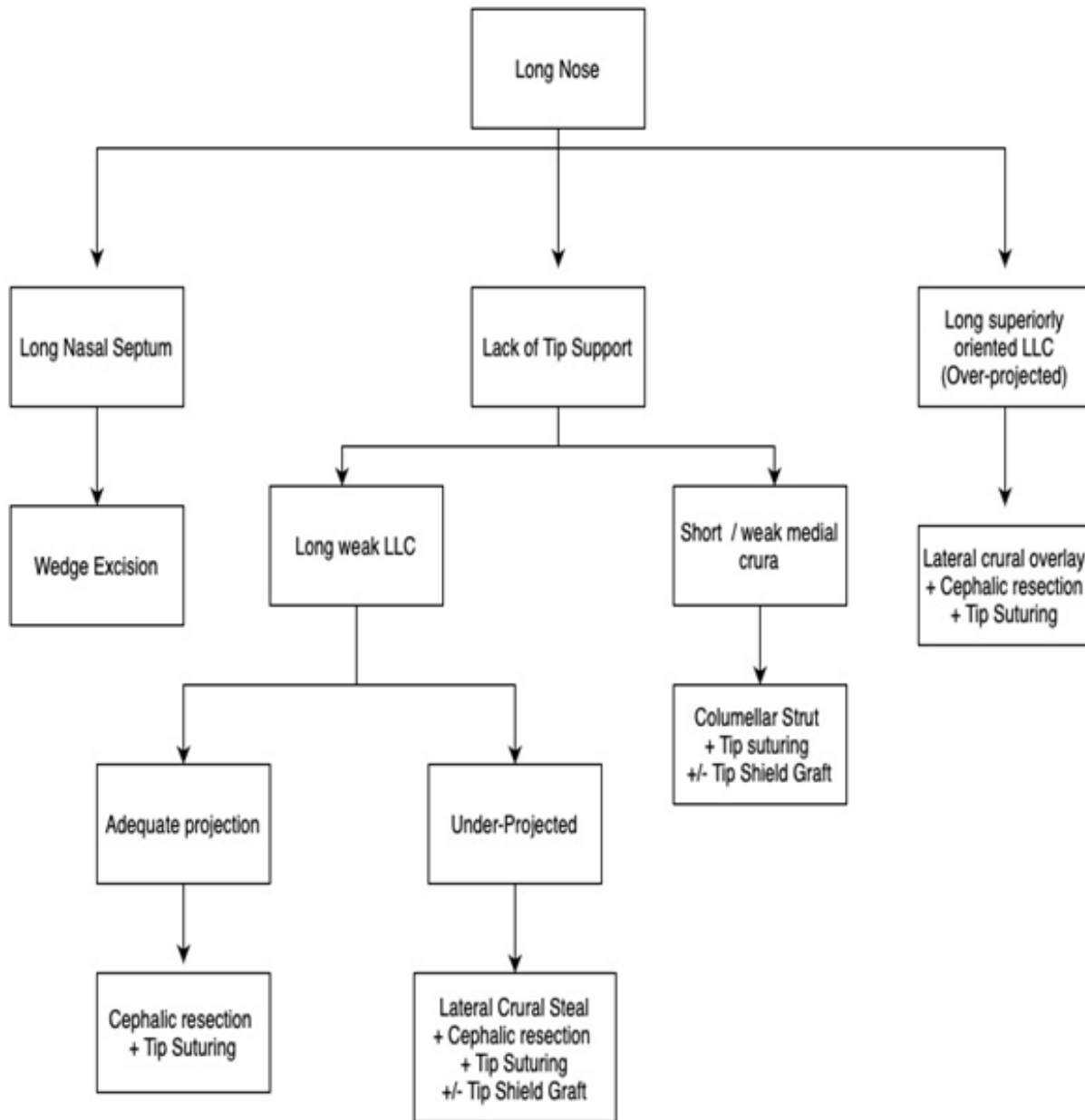


Fig 1 A: line from Glabella parallel to Frankfort horizontal plane. B: Frankfort horizontal plane. C: Line from Subnasale parallel to Frankfort horizontal plane. D: Nasal length from radix to tip defining points. According to Byrd, ideal nasal length is D would be 2/3 line from A to C (Mid facial height).

Patients then underwent open septorhinoplasty approach under general anesthesia after written consent. The septorhinoplasty procedure was planned and performed following our suggested treatment algorithm (Fig 2)

Patients were assessed for follow up at one, three, six and twelve months postoperatively. At one year postoperative, measurements were recorded of the same angles and dimensions and were then compared to our pre-operative measurements for analysis.



In cases of overactive depressor nasi muscle : Cutting of its fibres from its attachment

Fig 2: Our proposed surgical correction algorithm for long noses

RESULTS:

Our study group constituted of 28 male patients and 22 female patients. Mean age was 37.6 years. Most cases had more the one contributing factor to the long nose deformity. The most common contributing factor to the long nose deformity was poor nasal tip support in 94% of the cases. This was either due to long weak inferiorly oriented LLC in 35 patients or due to short weak medial

crura in 12 patients. This is followed by long nasal septum which was the case in 45 patients (Table 1).

These contributing factors results in variable degrees of nasal projection, most commonly under-projected droopy tip in 76% of the cases (Table 2). As a result, we did a sub-analysis dividing our cohort of patients into 3 categories according to their nasal projection.

Table 1: Patient Demographics and Factors contributing to long nose deformity among study group

		No			%
Gender	Male	28			56.0%
	Female	22			44.0%
Factors contributing to Long Nose deformity	Lack of nasal tip support	47			94%
	Long weak inferiorly oriented LLC*	35*	12**	70%*	24%**
	Short weak medial crura**				
	Long Nasal Septum	45			90%
	Long Superiorly oriented LLC	2			4%
	Overactive depressor nasi	2			4%
	High Radix	1			2%

Table 2: Nasal Projection among study group

	No	%
Under-projected Nose	38	76%
Adequately Projected Nose	10	20%
Over-projected Nose	2	4%

Table 3: Comparison between pre and postoperative nasal measurements among under-projected study cases (38/50)

	Mean	±SD	P	Sig
Pre-operative Nasal Length	0.76	0.03	0.001	HS
Post-operative Nasal Length	0.69	0.02		
Pre-operative Nasofrontal angle	142.13	9.30	0.009	HS
Post-operative Nasofrontal angle	138.05	6.69		
Pre-operative Nasolabial angle	81.05	7.52	0.001	HS
Post-operative Nasolabial angle	99.56	4.78		
Pre-operative Tip projection	0.50	0.02	0.001	HS
Post-operative Tip projection	0.57	0.02		

*Paired t test

Data analysis of the under projected subgroup after correcting the underlying deformity as per our proposed algorithm shows highly significant difference between the pre and post-operative measurements in nasal length bring

it closer to the ideal ratio of being 2/3 midfacial height. It also shows highly significant difference in the nasolabial angle and tip projection bringing these measurements and angles closer to the ideal ratios.

Table 4: Comparison between pre and post-operative nasal measurements among cases with normal projection (10/50 patients)

	Mean	±SD	P	Sig
Pre-operative Nasal Length	0.75	0.04	0.001	HS
Post-operative Nasal Length	0.69	0.03		
Pre-operative Nasofrontal angle	137.53	8.36	0.007	HS
Post-operative Nasofrontal angle	135.06	8.63		
Pre-operative Nasolabial angle	93.49	10.09	0.001	HS
Post-operative Nasolabial angle	103.61	8.61		
Pre-operative Tip projection	0.58	0.08	0.971	NS
Post-operative Tip projection	0.58	0.03		

*Paired t test

Data analysis of the cases with adequate projection after correcting the underlying deformity with our suggested algorithm shows highly significant difference in the pre and post-operative measurements of the nasal

length. It also shows improvement in the nasolabial angles. We have also managed to keep the nasal projection within the ideal ratio of 0.55-0.60 as per Goode's ratio.

Table 5: Comparison between pre and postoperative nasal measurements among over-projected cases (2/50 patients)

	Mean	±SD
Pre-operative Nasal Length	0.74	0.02
Post-operative Nasal Length	0.68	0.02
Pre-operative Nasofrontal angle	157.5	2.5
Post-operative Nasofrontal angle	135.3	3.1
Pre-operative Nasolabial angle	83.4	2.4
Post-operative Nasolabial angle	103.15	8.15
Pre-operative Tip projection	0.66	0.04
Post-operative Tip projection	0.58	0.02

Analysis of our patients with over-projected nose was difficult to obtain statistical significance as they were only two patients. However, our algorithm of correction has resulted in reduction of the nasal length and projection

as well as increased rotation of the nasolabial angle and reduction of the nasofrontal angle establishing more aesthetic measurements.

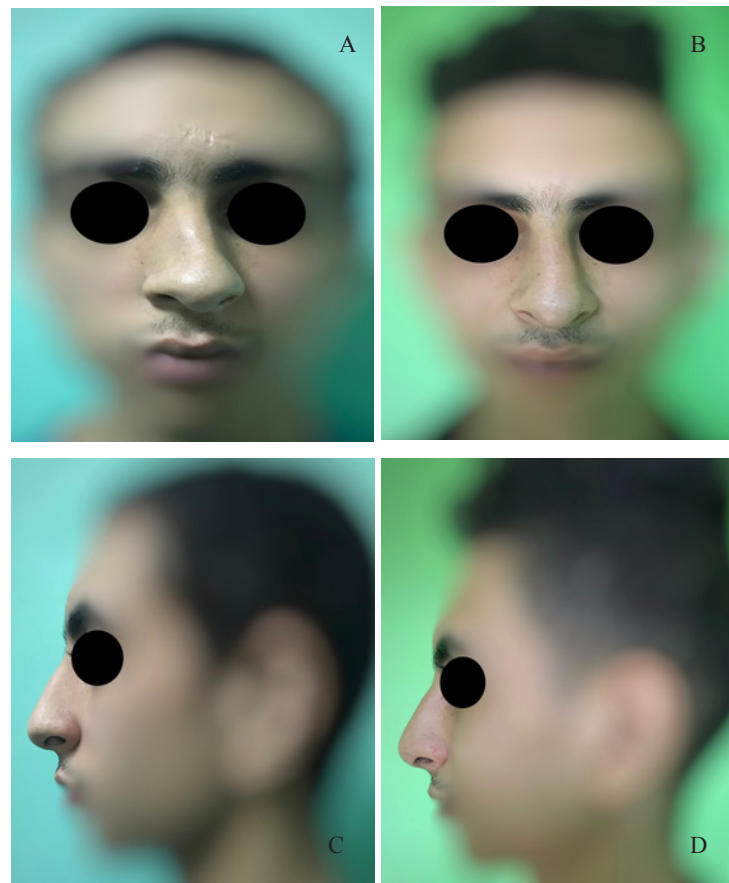


Fig. 3: A, C preoperative photographs for a patient with long nose with an associated crooked nose. This was due to long nasal septum and long lower lateral cartilages B, D Postoperative photographs after correction with the proposed surgical algorithm.

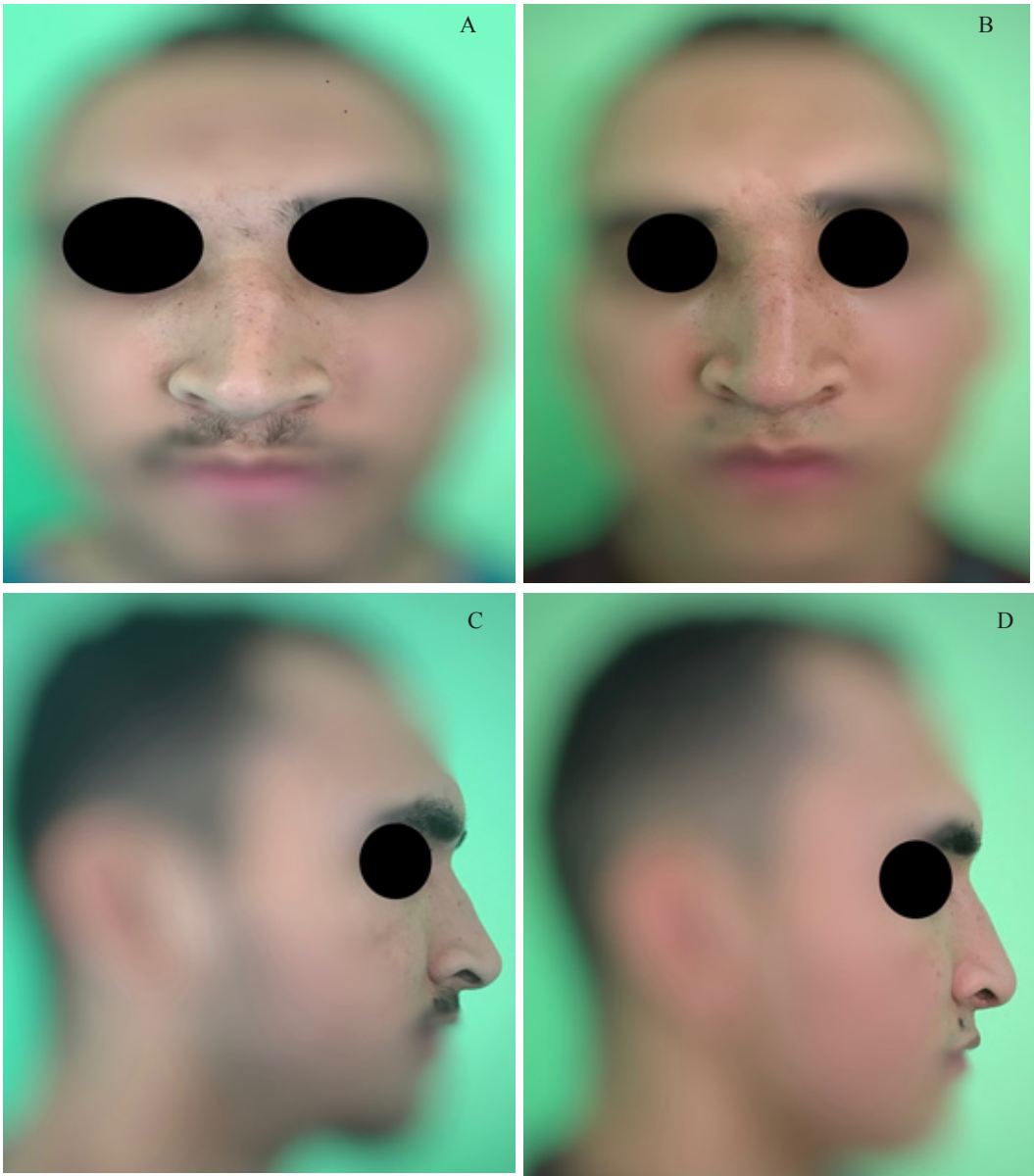


Fig. 4: A, C preoperative photographs for a patient with long nose and poor tip support due to long lower lateral cartilage and short and weak medial crura. B, D Postoperative photographs after correction with the proposed surgical algorithm

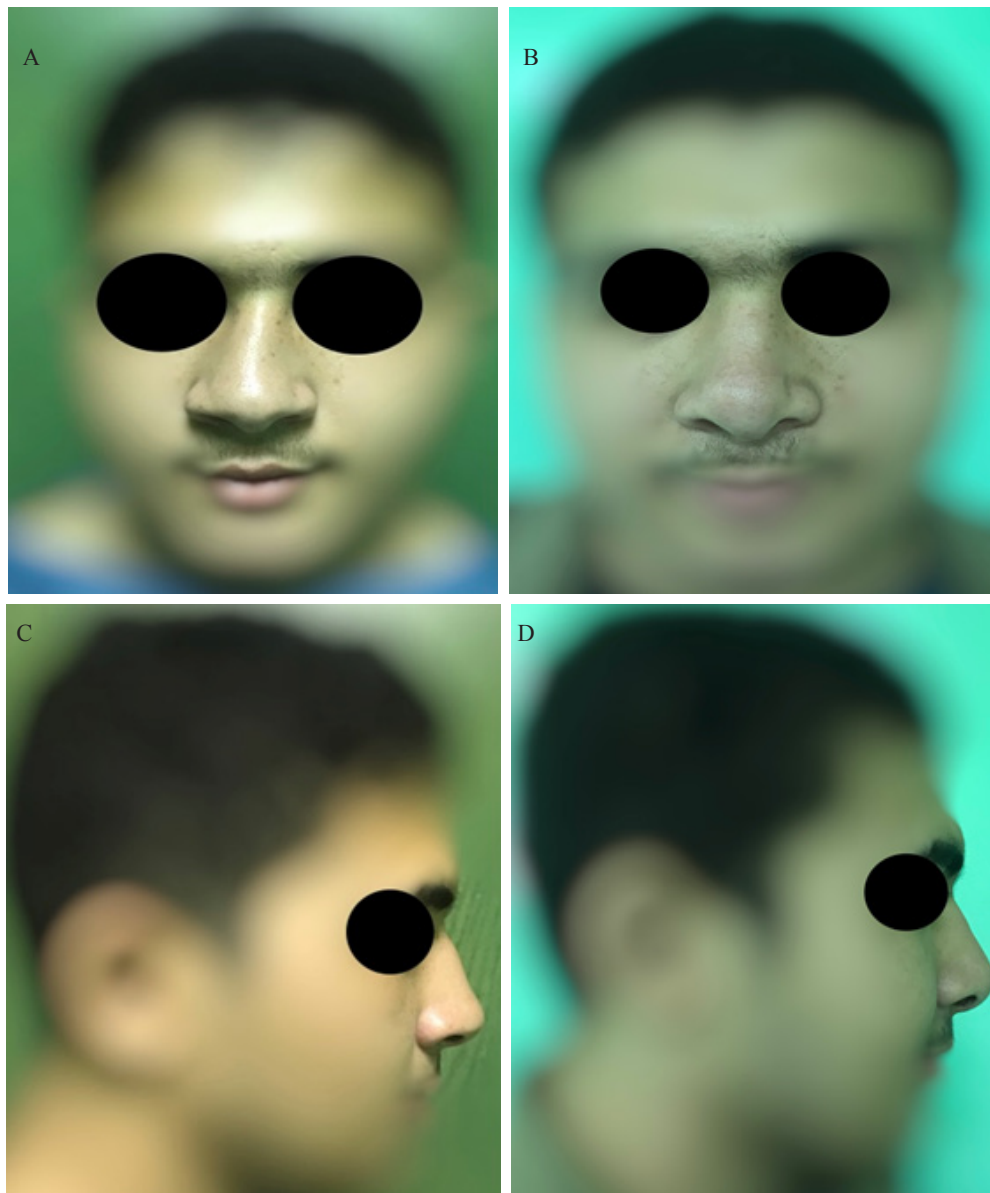

Fig. 5: A, C preoperative photographs for a patient with long nose with adequate projection nose and an associated crooked nose due to long nasal septum. B&D Postoperative photographs after correction with the proposed surgical algorithm.

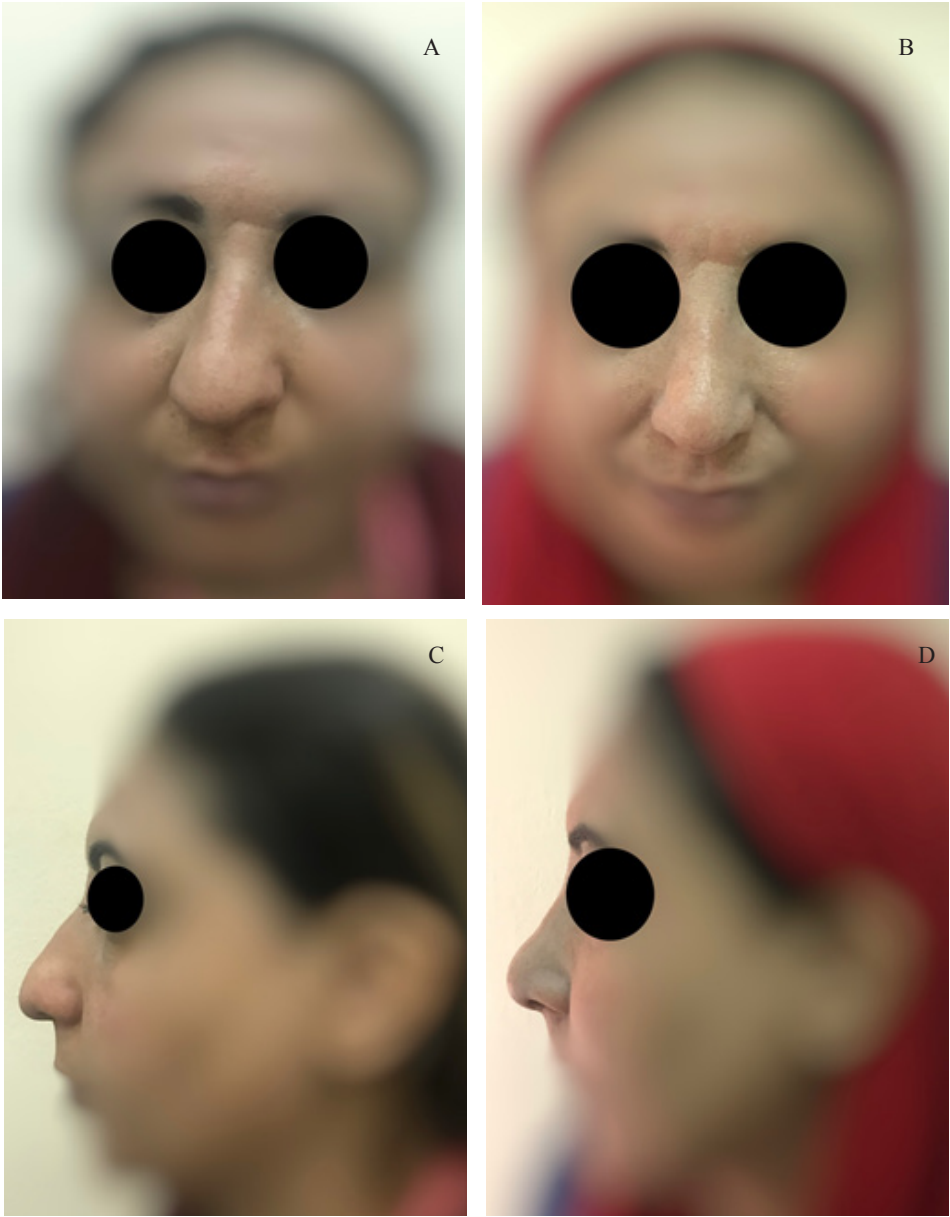

Fig. 6: A, C preoperative photographs for a patient with long nose with an associated crooked nose and droopy nasal tip due to long septum and poor tip support due to long weak LLC and weak medial crura. B, D Postoperative photographs after correction with the proposed surgical algorithm.

DISCUSSION

The Long nose deformity is one of the most complex nasal deformities to correct. This comes from the fact that it often involves more than one factor or cause. Therefore, requiring accurate and precise determining of the cause, as well as planning for correction

Accurate understanding of the nasal angles, projection and rotation particularly around the nasal tip is paramount and understanding the impact of the surgical techniques on these angles postoperatively is the key to successful surgery. This was the driving challenge of the authors to propose this structural algorithm for the management of Long nose.

In our series, we have identified that almost all cases multiple causes that contributed to the long nose rather than one single factor, which makes dealing with such deformity challenging and complex requiring a targeted tailored approach to each case.

As we assessed the causes of the long nose in Egyptian population, we have identified the most common factor to be the lack of nasal tip support (94%). This could be further classified to long, weak inferiorly oriented lower lateral cartilages (70%) or short and/or weak medial crura (24%) both of which will mostly result in a droopy under-projected nose (76%) or in some cases adequate projection (20%) with an acute nasolabial angle. The second most common cause long nasal septum (90%) which co-existed with other deformities of the lower lateral cartilages. Next came the long lower lateral cartilages that were superiorly oriented resulting in an over projected nose in 4% of the cases. One of our patients had a high radix further contributing to his long nose appearance. Finally we identified^[2] cases in our cohort of patients with an overactive depressor nasi muscle resulting in smiling deformity along with their long nose appearance (Table. 1). We have also identified among our study group that the majority had an under-projected nose with 76% of the cases (Table. 2)

Our first step in the correction of the long nose deformity is to address the nasal septum since it contributed to the deformity whether solely or with other factors in 90% of our cases. As highlighted by Guyron^[5], various geometric excisions of caudal septum will affect the nose differently. Excision in rectangular fashion will result in shortening of the entire nasal length. In cases of droopy tip where cephalic rotation is required, then wedge excision with the base of the wedge superiorly will in turn change the position of the anterior septal angle leading to increased tip rotation. Other techniques to shorten the septum include high septal step incisions, which is

described by Aygit *et al*^[4], where the septal cartilage excisions were performed at different levels to increase the rotation and projection

After correcting the nasal septum we addressed the nasal tip support mechanisms. In cases with long weak inferiorly oriented LLC resulting in under-projection we corrected this with combination of cephalic resection of LLC, tip suturing and Lateral crural steal technique to increase tip rotation and projection. On the other hand, the cases with long LLC but with adequate projection (20%) had a long nasal septum as a co-existing factor contributing to the long nose deformity therefore we performed cephalic resection of LLC and tip suturing along with the septal excisions.

Whereas cases with weak and or short medial crura, resulting in droopy under-projected, nose this was corrected with the use of columellar strut. Depending on skin thickness to further increase projection and obtain a well defined tip we additionally used tip shield graft in all cases with thick skin (11 cases) and some cases that had intermediate skin thickness (7 out of 37 cases).

In cases with long LLC with superior orientation resulting in an over- projected nose (4%) we advocate the use of the lateral crural overlay technique, with the aim to deproject the nose. Of note, the lateral crural overlay technique is a powerful technique to deproject the nose so it must be done carefully to avoid over-correction which can be then be difficult and tricky to fix.

Adjunctive maneuvers used for further tip definition such cephalic trim of LLC, suturing techniques which included transdomal, interdomal and septocolumellar sutures as well the use of columellar struts. The Septocolumellar suture is often overlooked especially by junior rhinoplasty surgeons, but in our experience, we find it is an important and additional useful technique particularly in under-rotated noses to increase tip rotation. The septocolumellar suture also slightly increases the tip projection, however we believe that it should not be used as a replacement for a columellar strut, if required, but we consider it more of an additional suture technique that helps fine tune the tip position with respect to the caudal septum.

Finally, the importance of dynamic forces should not be overlooked, as we assessed patients with smiling deformity, where an overactive depressor nasi muscle, pulling the nasal tip downwards, would have to be addressed intraoperatively. This was achieved by dividing and cutting of the muscle fibers from its attachments.

Our proposed algorithm proved high statistical significance between the pre and post operative measurements in the under-projected and adequately projected noses, we could not perform full statistical analysis in the long noses with over-projected subgroup due to the small number of patients in our study. However our post op measurements of nasal length, projection, nasolabial and nasofrontal angles in all the long nose subcategories with different nasal projections are all within or closer to the ideal aesthetic measurements.

On reviewing the literature and published studies, Aygit^[4] and his colleagues in 2006 published their experience on management of long noses. Their approach was different in classifying the long nose in those with long septum and another category with dislocated alar complex. They focused their correction on septal incision techniques to modify the anterior septal angle hence modifying tip rotation and projection. Patients with dislocated alar complex, they used tongue in groove technique, septal extension grafts and columellar struts according to the deformity.

In another study by Farag and his colleagues in 2011^[3], they present a multicenter case series of long noses in 3 Middle Eastern countries. They used the radix to tip distance and the radix to columellar base distance in their analysis of the nasal length. We feel that the analysis of the nasal length in relation to the midfacial height is more representative and considers the whole facial symmetry. Their study shows similar findings in the analysis that the patients with long noses are often due to multiple factors.

Another key paper in 2009 where Sajjadian and Guyuron^[6] presented their experience in management of long noses. In their review article, they classify long droopy noses into two main categories. Those with true long noses with tip ptosis and another category with an apparent long nose due to subnasale retraction.

They subdivided the group with long ptotic tip into long septum, long lower lateral cartilage and short medial crura. They describe similar techniques to correct long septum using wedge excision and tongue in groove. For correction of elongated lower lateral cartilages, they have used a combination of columella strut, onlay graft and tip rotation sutures for underprojected tip, whereas they used lateral crural overlay for overprojected tips. In cases of short medial crura they used columellar strut or medial crura anchor sutures.

Another study from Korea in 2013^[7], focusing on long nose in East Asians has classified long noses

into static and dynamic causes. Static causes being long nasal septum, long lower lateral cartilages and weak aponeurotic attachments to anterior septal angle. Dynamic causes included the forces of muscles influencing the nasal tip. In addition to depressor septi muscle, they highlight the influence of levator labii superioris alaeque nasi muscle as it pulls the alar base to cephalic direction on the nasal wing leading to a droopy tip.

Their corrective surgical algorithm is mainly dependent on lateral crural steal suture, with columellar strut, tip grafts and excision of depressor septi muscle. In special circumstances, they considered additional techniques such as caudal septal excision, lateral crural overlay in overprojected nose. They also described the use of silicone implants to augment in the anterior nasal spine as well as debulking of subcutaneous fat tissue and redundant skin excision. However, both latter techniques we have strong reservations on as we would not advocate skin excision in rhinoplasty, and debulking of subcutaneous fat tissue should be done very carefully as this potentially could compromise the vascularity of the soft tissue envelope leading to catastrophic complications. We have no experience over the use of synthetic implants and again we strongly advocate against their use given the well-known and documented high infection and extrusions rates as reported in literature. Instead in cases with thick skin we recommend the use of cartilaginous tip shield grafts for further tip projection and definition .

To our knowledge, this is the first study to address the long nose in a systematic manner to come up with a surgical algorithm supported by pre and postoperative measurements and results. Hossam Fouda^[8], in 2003, published a large series of 500 patients for management of droopy tip, comparing three alar cartilage modifying techniques and their effect on the tip projection and rotation. Our study results correlates with Fouda, that most cases it is more than one factor contributing to the droopy tip.

Similarly our results also conclude that the lateral crural steal is the best for correcting an underprojected droopy tip, whereas the lateral crural onlay technique is best for the overprojected tip. We differ from Fouda, as he primarily used the tongue in groove technique for droopy tips with normal projection. However, we believe that similar results could be achieved with cephalic LL resection and suturing techniques, and in cases of long nose, wedge excision of septum and altering of the anterior septal angle delivers similar results, avoiding the unpleasant sequel of rigid tip that patients complain of following the tongue in groove technique.

We also differ from Fouda's study as we investigated the role of the long septum in contributing to the long nose and droopy nasal tips with suggested techniques in our algorithm to correct this as highlighted previously. We also differ in assessing the skin thickness and advocating the use of tip grafts to increase tip projection and definition in all cases with thick skin and selected cases with intermediate thickness skin.

CONCLUSION

Careful preoperative analysis is a crucial step in rhinoplasty, and the use of facial analysis software is a valuable adjunctive tool. In our assessment of the long nose in the Egyptian population the most common contributing factor is poor tip support either due to long weak inferiorly oriented LLC or short weak medial crura followed by long nasal septum. We advocate the use of our surgical algorithm as a stepwise approach for correction of the long nose, however every operation should still be tailored accordingly to each patient.

CONFLICT OF INTEREST

There are no conflicts of interest.

REFERENCES

1. **Momeni, A. and Gruber, R. P. (2016).** Primary Open Rhinoplasty. *Aesthetic Surgery Journal*, 36 (9), 983-992.
2. **Rohrich, R. J. and Ahmad, J. (2014).** Getting rhinoplasty right the first time. *Dallas Rhinoplasty: Nasal Surgery by the Masters*. 3rd ed. St. Louis: Quality Medical, 159-176.
3. **Ali, A., El-Barbary, A. and Farag, M. (2011).** Structure rhinoplasty of the long nose. *Aesthetic plastic surgery*, 35 (5), 839-846.
4. **Benlier, E., Top, H. and Aygit, A. C. (2006).** Management of the long nose: review of techniques for nasal tip supporting structures. *Aesthetic plastic surgery*, 30 (2), 159-168.
5. **Guyuron, B. (2000).** Dynamics in rhinoplasty. *Plastic and reconstructive surgery*, 105 (6), 2257-2259.
6. **Sajjadian, A. and Guyuron, B. (2009).** An algorithm for treatment of the drooping nose. *Aesthetic surgery journal*, 29 (3), 199-206.
7. **Park, S.G., Jeong, H. and Ye, C.H. (2014).** Multifactorial approaches for correction of the drooping tip of a long nose in East Asians. *Archives of Plastic Surgery*, 41(6), p.630.
8. **Foda, H. M. T. (2003).** Management of the droopy tip: a comparison of three alar cartilage-modifying techniques. *Plastic and reconstructive surgery*, 112 (5), 1408-1417.