

Hemato-Biochemical changes in dogs infected with *toxocara canis* in Hurghada and Luxor governorate

Moshera S. Shahat^{1*}, Abdel-Raheem A. Abdel-Raheem², Adel Elsayed Ahmed Mohamed¹

¹Department of Animal Medicine, Faculty of Veterinary Medicine, South Valley University, Qena 83523, Egypt, ²Department of Animal medicine. Faculty of Veterinary Medicine, Assiut University, Assiut 71515, Egypt.

Abstract

Toxocara canis is a gastrointestinal nematode affecting dogs with significant public health importance. this study is conducted to find the hematological and biochemical changes in dogs infected with *toxocara canis* and to detect the effects of sex, age, and season on the percent of infection with this parasite. A total of 70 dogs were included in this experiment. Fecal, hematologic and serum samples were collected from veterinary clinics in Hurghada and Luxor governorate. Microscopic analysis of fecal samples revealed three types of intestinal parasites: *Toxocara canis* (n= 19), *Toxascaris leonina* (n= 5), *Isospora canis* (n=4) and mixed infection of *Toxocara canis* and *Isospora canis* (n= 3). Whole blood samples were examined for total erythrocytic count, hemoglobin, packed cell volume, total leukocytic count and differential leukocytic count. Serum samples were separated and analyzed for total protein, albumin, Alanine aminotransferase and Aspartate aminotransferase. Significant decrease in red blood cells count, hemoglobin, and packed cell volume along with significant increase in white blood cells count and eosinophils were recorded in dogs infected with *Toxacara canis*. Significant decrease in total protein, albumin accompanied by significant increase in Alanine aminotransferase, Aspartate aminotransferase values were found. Sex, season, and breed showed non-significant differences in infection percent of intestinal parasites, but age had high impact on infection percent of intestinal parasites.

Keywords:

Aspartate aminotransferase, Dogs, Hemoglobin, Total protein, Toxocara.

DOI: 10.21608/svu.2022.90894.1143 Received: August 15, 2021 Accepted: March 8, 2022
Published: March 30, 2022 *Corresponding Author: Moshera S. Shahat E-mail:
mushira_salah@vet.svu.edu.eg

Citation: Shahat et al., Hemato-Biochemical changes in dogs infected with *toxocara canis* in Hurghada and Luxor governorate. SVU-IJVS 2022, 5(1): 56-67.

Copyright: © Shahat et al. This is an open access article distributed under the terms of the creative common attribution license, which permits unrestricted use, distribution and reproduction in any medium provided the original author and source are created.

Competing interest: The authors have declared that no competing interest exists.



Introduction

Dogs perform a variety of cultural, social, and economic functions in the society. They can be kept as pets and companion animals, for hunting, as guards, draught animals, for food, or for commercial purposes (Savolainen et al., 2002).

Dog parasites exist internally and externally, wide range of them are specific and live only on dogs. Infestation with gastrointestinal parasites occur in all ages of dogs with the greatest incidence in puppies (Seah et al., 1975). Gastrointestinal helminths of dogs have serious impact on the host and human beings. It can cause several losses manifested by inhibition of immune response to infectious diseases, retardation of growth, lowered work and feed efficiency and general ill-health. Animals affected with parasites manifest a variety of signs depending on the parasite burden and species (Soulsby, 1982). *Toxocara canis* is one of the most common and worldwide prevalent parasites that infects canids which act as definitive hosts for this parasite (Bugg et al., 1999; Robertson and Thompson, 2002). Eggs of *T. canis* are Sticky, thick-shelled eggs can survive harsh environmental conditions (Daryani et al., 2009). infestation occurs by ingestion of eggs containing infective stage larvae; transplacental infection and transmammary route are another way for transmission of *T. canis* infection (Overgaauw, 1997). When the larva passes on to the alimentary tract, pups suffer from vomiting, diarrhea, distended abdomen, emaciation, poor coat quality and, pain which can be represented by whine, shriek of puppies and, overlapping hind limbs while standing or walking. In adult dogs, the infestation is usually subclinical and there are no respiratory manifestations. Signs restricted to diarrhea, weight loss, and general malaise (Epe, 2009). Intestinal helminths are found to have deleterious effects on blood parameters and cause

microcytic hypochromic anemia in parasitized animals (Qadir et al., 2011). (Kumar et al., 2014; Salem et al., 2015) recorded a significant reduction in RBCs count, hemoglobin, and PCV levels while, leukocytosis with significant eosinophilia and neutrophilia has been observed in dogs infected with *T. canis*.

The incidence of parasites in dogs can be related to many factors such as age, gender, and breed which are considered the most common ones, seasonal variations and diversity indexes also can be included (Oliveira-Sequeira et al., 2002; Egui'a Aguilar et al., 2005).

This study aimed at determining the levels of some hematological and biochemical parameters on the *T. canis* infected and clinically healthy dogs and compared the data acquired.

Materials and methods

1. Ethical statement:

All animals included in this study were handled according to the regulations of the Animal Ethics Committee at the Faculty of Veterinary Medicine, South Valley University, Qena, Egypt, with good animal practice following the guidelines of The Research Code of Ethics (RCOE-SVU) at the South Valley University.

2. Animals

Seventy dogs of both sexes and different ages (Age =1 month to 4 year) and breeds (local and exotic) from animal care hospital in Luxor governorate and Hurghada were examined for intestinal nematodes during the period from May 2019 to November 2020.

Out of 70 dogs, 39 animals were used as a healthy control group after thorough clinical and laboratory examination, Microscopical fecal examinations were done three times on three consecutive days to be sure free from intestinal parasite.

3. Samples

A) Blood samples:

Two blood samples were collected from the cephalic vein, whole blood sample for hematological studies and a clear non-hemolysed serum sample was prepared for biochemical studies (Jain, 1986)

B) Fecal samples:

A total number of 70 fecal samples were collected from dogs in Luxor governorate and Hurghada according to (Charles and Hendrix, 1998).

4. Clinical examination:

Clinical examination of dogs was carried according to (Englar, 2017). The clinical symptoms were recorded, with special focus on presence of diarrhea, abdominal pain, nausea/vomiting and itching in perianal region, body condition, and mucous membrane examination.

5. Fecal examination:

Fecal samples were examined macroscopically for color, blood, mucous, consistency and presence of gross parasites. Microscopic examination was performed using direct smear (Urquhart et al., 2001).

Fecal floatation method was performed according to (Cable et al., 1985). Sedimentation technique was performed according to (Abdel-Rahman et al., 1982).

6. Hematological examinations:

Red blood cells (RBCs) and white blood cells (WBCs) counts were determined according to manufacture instruction using a (NEUBAUER HEMOCYTOMETER, Germany).

Hemoglobin (Hb) concentration measured by colorimetric endpoint cyanomethemoglobin method using

DRABKIN SOLUTION. Packed cell volume (PCV) was determined by the microhematocrit centrifugation technique (Jain, 1986). Mean corpuscular volume (MCV), mean corpuscular hemoglobin (MCH) and mean corpuscular hemoglobin concentration (MCHC) were calculated mathematically according to (Coles, 1986).

Serum samples were analyzed for total protein (TP), Albumin, Alanine aminotransferase (ALT), Aspartate aminotransferase (AST), urea, and creatinine spectrophotometrically (UV-1201, Shimadzu, Japan) using commercial biochemical kits (SPECTRUM DIAGNOSTICS, Egypt) and according to the manufacture instruction.

7. Statistical analysis:

The data analysis was performed using of Excel spreadsheet (Microsoft Excel 2016) for descriptive statistics. Data were presented as Mean \pm SD. Significant of difference between health and diseased group was determined by T-test using the PRISM statistical software (Graph Pad Prism 7 program).

Results

Out of 70 examined dogs, 48 dogs were apparently healthy showed no clinical signs (asymptomatic) and 22 dogs showed signs of disease (symptomatic). Symptomatic dogs were presented with one or more of the following signs: emaciation, off food, diarrhea, abdominal pain, dull hair coat, hair shedding, pale mucous membrane, and vomiting (Table 1).

Fecal examination of both symptomatically and asymptotically dogs revealed 31 dogs were infested with nematodes and protozoa (22 symptomatic and 9 asymptomatic) (Table 2).

Table 1: Clinical symptoms observed in dogs infested with parasites.

Groups	Group 1	Group 2	Group 3	Group 4
Spp. infection	<i>Toxocara canis</i>	<i>Toxascaris leonina</i>	<i>Cystoisospora</i> spp.	Mixed infection (<i>Toxocara canis</i> with <i>Isoospora canis</i>)
Diarrhea	+	+	+	+
Abdominal pain	+	-	+	+
Nausea/vomiting	+	-	-	-
Itching in perianal region	-	-	-	-
Body condition	Poor	Poor	Poor	Poor
Mucous membrane	Pale	Pale	Pale	Pale

Table 2: Infection percentage of nematodes in symptomatic and asymptomatic examined dogs.

Parasite	Symptomatic (n=22)	Asymptomatic (n=48)
	Positive (n=22)	Positive (n=9)
<i>Toxocara canis</i>	12 (54.5%)	7 (14.6%)
<i>Toxascaris leonina</i>	4 (18.2%)	1 (2.1%)
<i>Isoospora canis</i>	3 (13.6%)	1 (2.1%)
Mixed Infection	3 (13.6%)	0 (0.0 %)
Total Infection/ percentage (%)	22 / (100%)	9 / (18.8%)
Total Infection/ percentage (%)	0 (0.0%)	39 (81.3%)

Fecal examination:

Macroscopic examination of the feces showed no gross parasites. Microscopic examination of the feces revealed presence of eggs of *Toxocara canis* (Fig.1-A), *Toxascaris leonina* (Fig.1-B) and *isospora* oocyst (Fig.1-C).

The study revealed the overall percentage of intestinal parasites infestation was found to be 44.3% (31/70). The infection percent was 65.5% (19/29) in puppies and 36.8% (7/19) in dogs (from 3-6 months of age) and 22.7% (5/22) in adult dogs (above 6 months of age). Furthermore, the overall percentage of infection was 44.7% (17/38) in male dogs and 43.8% (14/32) in females (Table 4). Three types of GI parasites were detected: the predominant one was *Toxocara canis* (27.1%) followed by *Toxascaris leonina* (7.1%) then *isospora canis* (5.7%). three of examined dogs (4.3%) had been infected with more than one parasite (*Toxocara canis* and *isospora canis*) (Table 3).

Factors affecting the infestation with intestinal nematodes:

Age, season, sex, and breed were the factors affecting infection percent of intestinal parasites.

According to age, puppies from 1-3 months showed higher significant infection percent ($P < 0.01$) of intestinal nematodes (65.5%) compared to dogs from 3-6 months of age (36.8%) and dogs above 6 months of age (22.7%) (Table 4). Infection percent of *Toxocara canis* was highly significant ($P < 0.01$) in puppies (15/29) compared to dogs from 3-6 month (3/19) and above 6 months (1/22) represented by 51.7%, 15.8% and 4.5% respectively. On the other hand, age was not statistically significant in infection rate of *Toxascaris leonina*, *Cystoisospora spp* and mixed infection.

According to season, samples were collected at two seasons, the infection percent showed no significant ($P > 0.05$) variation in cold season (21/41) in compared to hot season (10/29) that

represented 51.2% and 34.5%, respectively (Table 4).

The obtained data of the examined dogs of both sexes (38 male and 32 female) showed non statistically significant ($P>0.05$) variation in infection percentage between male (44.7%) and female dogs (43.8%) (Table 4).

According to the breeds, there was no significant ($P>0.05$) variation between local and exotic breeds. The infection percent of intestinal parasites in local and exotic breeds was 45.6% and 38.5% (27/70), respectively (Table 4).

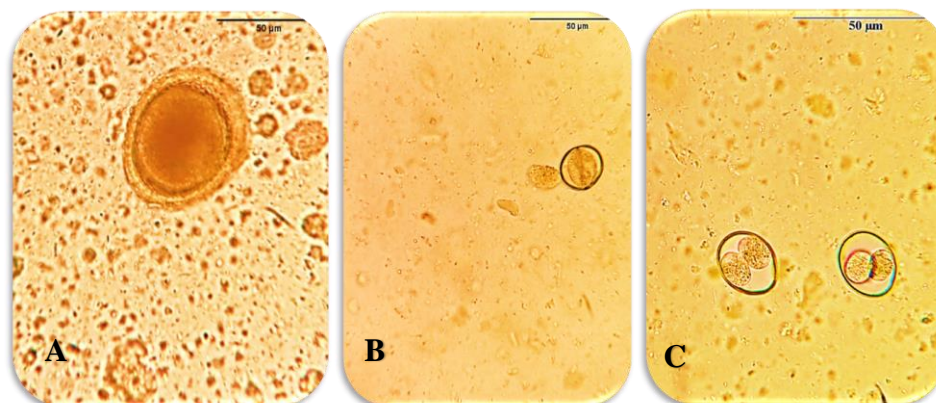


Fig. 1. Types of eggs in fecal examination: **A)** *toxocara canis* egg (400Xmagnification). **B)** *Toxascaris leonina* egg (400Xmagnification). **C)** *Isospora canis* oocyst (400Xmagnification).

Table 3: Overall infection percent of intestinal parasites in dogs.

Group	No. of animals (n= 70)	Percentage (%)
1. Healthy control group	39	55.7 %
2. Positive group	31	44.3 %
• <i>Toxocara canis</i>	19	27.1 %
• <i>Toxascaris leonine</i>	5	7.1 %
• <i>Cystoisospora spp</i>	4	5.7 %
• Mixed infection (<i>Toxocara canis</i> with <i>Isospora canis</i>)	3	4.3 %

Table 4: Factors associated with gastrointestinal infection in dogs.

Factors	No. of dogs		Percentage (%)	P. value	
	Examined	positive			
Sex	Male	38	17	44.7 %	0.9340
	Female	32	14	43.8 %	
Age	1-3 M	29	19	65.5 %	0.0072**
	3-6 M	19	7	36.8 %	
	> 6 M	22	5	22.7 %	
Breed	Local	43	22	51.2 %	0.2164
	Exotic	27	9	33.3 %	
Season	Hot	29	10	34.4 %	0.1649
	Cold	41	21	51.2 %	

**highly significance difference at $P < 0.01$

Hematological results:

There was high significant reduction ($P<0.01$) in the levels of erythrocytic parameters (Hb, PCV and RBCs) and significant increase ($P<0.05$) in the WBCs value in the parasitized in compared to the non-parasitized group of animals.

DLC was statistically non-significant except for eosinophils which significantly increased ($P<0.05$) in parasitized compared to non-parasitized animals. Hematological parameters for parasitized and non-parasitized dog populations are presented in Table 5.

Table 5. Mean \pm SD and P-value of hematological parameters of healthy and intestinal parasites-infected dogs.

Parameter	Healthy group (n= 39)	Infected group (n= 31)	P. value
RBCs ($\times 10^6 / \text{mm}^3$)	5.49 \pm 0.72	4.94 \pm 0.61	0.0015**
HB (g/dl)	12.49 \pm 0.82	11.80 \pm 1.02	0.0010**
PCV (%)	35.56 \pm 2.92	32.16 \pm 3.93	0.0001**
MCV (fL)	65.22 \pm 4.08	65.06 \pm 3.71	0.8690
MCH (Pg.)	23.37 \pm 4.94	24.03 \pm 1.79	0.4913
MCHC (%)	35.57 \pm 5.51	37 \pm 2.77	0.1982
WBCs ($\times 10^3 / \text{mm}^3$)	10 \pm 1.75	11.18 \pm 1.95	0.0423*
Lymphocytes (%)	26.28 \pm 1.95	25.61 \pm 1.98	0.1668
Neutrophils (%)	59.1 \pm 3.25	59.77 \pm 1.77	0.3112
Monocytes (%)	6.72 \pm 0.85	6.61 \pm 0.68	0.5943
Eosinophils (%)	5.72 \pm 1.15	6.45 \pm 1.36	0.0190*
Basophils (%)	0.44 \pm 0.55	0.52 \pm 0.67	0.5866

Serum biochemical results:

Serum total protein (TP) and albumin values of parasitized group were found to be significantly lower ($P<0.01$) than non-parasitized one.

Both serum ALT and AST values were significantly increased ($P<0.05$) in parasitized than non-parasitized group whereas urea and creatinine values were non-significantly different between both groups. Biochemical data were presented in Fig. 2.

Discussion

Toxocara canis is the most predominant parasite in the present study with 27.1% infestation percent. This finding agreed with several studies. Kimura et al., (2013) and Kumar et al., (2014) reported *toxocara canis* infection percent of 21%, 22% 30%, 25%, and 28.93%, respectively. On the other side, Ugbomoiko et al., (2008)

and Radwan et al., (2009) reported higher percent of *Toxocara canis* infection 41.7% of domestic dogs in Nigeria and 53.4% in Egypt, respectively. This variation could be related to differences in management systems, health care and degree of environmental contamination with infective stages (Kumar et al., 2014).

The infection percent of *Toxascaris leonina* in the present study was 7.1% of the examined dogs. This result coincided with Trasviña-Muñoz et al., (2017) who reported infection percent of 5.5% for *Toxascaris leonina*.

The occurrence of *Cystoisospora spp.* was (5.7%) in 70 examined dogs. This result was close to results reported by Ferreira et al., (2005). The authors found that 5.6% of dogs affected by *Cystoisospora spp.* This result was lower than those reported by Anene et al., (1996) (18.3%), Buehl et al., (2006) (8.7%) and Nisar et al., (2009) (18%).

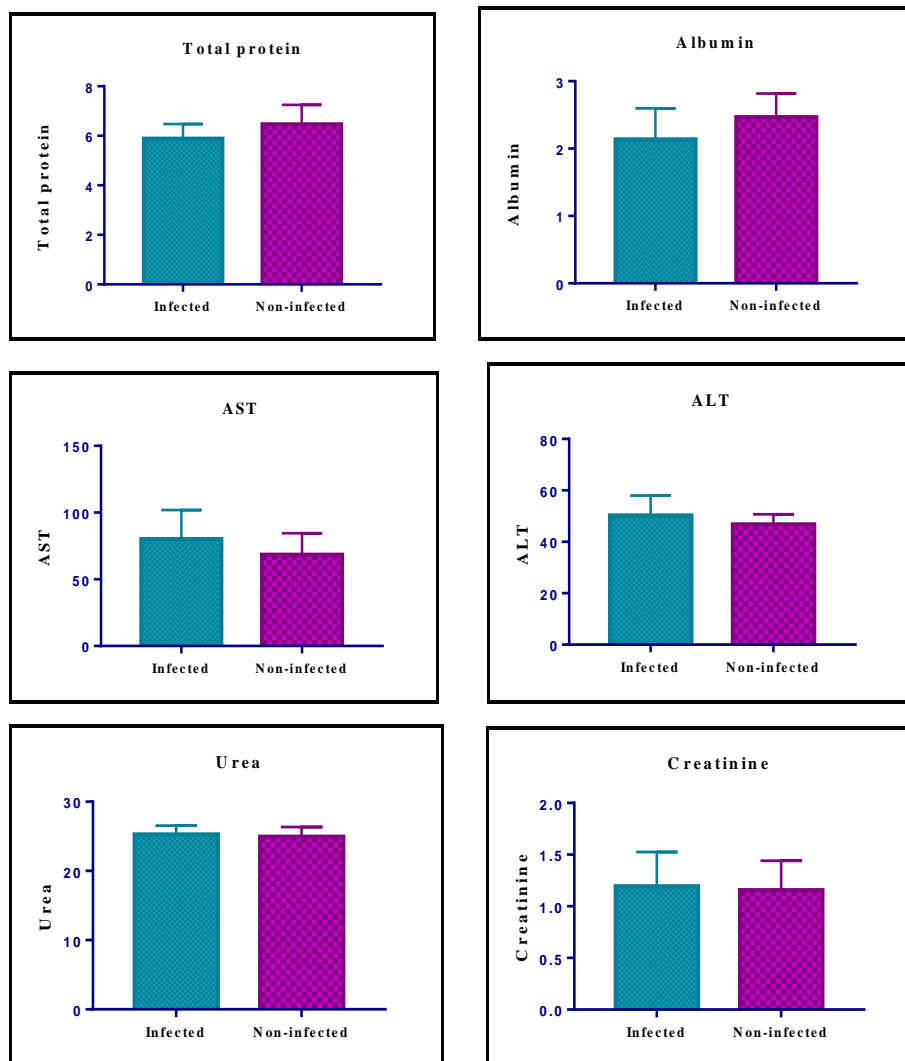


Fig. 2. Mean value (\pm SD) of serum total protein, albumin, AST, ALT, urea, and creatinine of healthy and infected dogs. * refers to significant difference at $P < 0.05$, and ** refers to highly significant difference at $P < 0.01$.

This could be attributed to the use of anti-coccidial drugs, geographic conditions, and awareness of the owners about the disease.

Age of animals played a very important role in infection percentage of gastrointestinal parasites in dogs. Puppies from 1-3 months showed significant ($P < 0.05$) infection percent of intestinal parasites (65.5%) compared to (36.8%) in dogs from 3- 6 months and (22.7%) in dogs above 6 months. This result agreed with (Eslami et al., 2010 and Ahmed et al.,

2014). The authors attributed this finding to the age acquired specific immunity against parasites or to trans-placental or trans-mammary infection during the first few days of life (Epe, 2009). *Toxocara canis* and *Toxascaris leonina* were the predominant gastrointestinal nematodes among puppies. Similar findings have been reported by (Swai et al., 2010 and Kumar et al., 2014).

In the present study, there was no significant ($P > 0.05$) difference in infestation percent between male and

female dogs. Similar findings have been reported in previous studies (Awoke et al., 2011 and Abere et al., 2013). On the other side, Ahmed et al., (2014) and Davoust et al., (2008) indicated that female dogs were at risk of acquiring enteric parasitic infestation than male dogs. This may be due to the physiological peculiarities of the female dogs, which usually constitute stress factors thus reducing their immunity to infections (Swai et al., 2010)

This study showed no significant variation in infection percent between cold and hot season. This result agreed with (Oliveira-Sequeira et al., 2002).

Breeds were found to be a non-significant risk factor for occurrence of gastrointestinal parasitic infestation in dogs. (45.6%) in local breeds and (38.5%) in exotic breeds. Similar finding reported by (Swai et al., 2010 and Kumar et al., 2014).

Current study reveals that 68.6% (48/70) of examined dogs were apparently healthy, while 31.4% (22/70) of them showed signs of diseases. Out of 48 asymptomatic dogs, 9 animals (18.8%) were confirmed for enteric parasites infestation, while all symptomatic cases were infected with gastrointestinal parasites. This result confirming that absence of clinical symptoms is not an evidence for absence of infection. This finding agreed with (Stehr-Green et al., 1987 and Mohamed et al., 2009). Also, (Schmidt et al., 2016) reported that apparently healthy dogs at clinical examination were infected with nematodes suggesting that symptomatology-based diagnosis alone is inadequate.

Obtained hematological data revealed a significant reduction in the RBCs, Hb and PCV values in the infected group than in the healthy group. These results agreed with (Qadir et al., 2011; Kumar et al., 2014).

There was significant increase in WBCs in infected dogs indicating

leukocytosis. This finding agreed with (Chattha et al., 2009 and Sharma et al., 2010). This increase might be related to liberation of histamine and histamine like substances from tissues damaged by the parasite effect.

Significant increase in eosinophils was observed in infected group indicating eosinophilia. Similar results obtained by (Ogunkoya et al., 2006 and Sharma et al., 2010). This increase could be attributed to the larval migration and defense mechanism against enteric parasites (Kirkova et al., 2005).

Generated biochemical data revealed a significant ($P < 0.05$) decrease in total serum protein (TP) especially albumin level in infected group compared to healthy group. Similar trend has been reported earlier by (Kaymaz et al., 1999 and Nwoha et al., 2013). Hypoproteinemia is attributed to increase the serum leakage through the injured gut and to the interference with efficacy of absorption of the damaged intestine (Kumar et al., 2014).

In current study, both ALT and AST values were significantly increased in the infected group in compared to healthy group. This result agreed with (Hayden and Kruiningen, 1975 and Nwoha et al., 2013). This increase may be correlated to damage of liver by migrating larvae leading to increase hepatic permeability of those enzymes to blood stream (Kumar et al., 2014).

In conclusion, the overall percentage of intestinal parasites infestation in this study was 44.3% and *Toxocara canis* was the most common parasite with infection percent (27.1%) and it was found to be influenced by age. intestinal parasites, especially *toxocara canis*, were found to exert significant effects on hematological and biochemical parameters suggesting their importance as a health problem in dogs.

Conflict of interest statement

The authors declare that there is no potential conflict of interest.

References

Abdel-Rahman MS, Hilal MS, Selim MK (1982). Diagnostic techniques of parasites in veterinary medicine (Ed.) Fac. Vet. Med. Cairo university.

Abere T, Bogale B, Melaku A (2013). Gastrointestinal helminth parasites of pet and stray dogs as a potential risk for human health in Bahir Dar town, north-western Ethiopia. *Veterinary World*, 6(7): 388-392. <https://doi.org/10.5455/vetworld.2013.388-392>

Anene, B.M.; Nnaji T.O. and Chime, A.B. (1996): Intestinal parasitic infections of dogs in the Nsukka area of the Enugu State, Nigeria. *Preventive Veterinary Medicine*, 27 (1-2): 89-94.

Awoke E, Bogale B, Chanie M (2011). Intestinal Nematode Parasites of Dogs: Prevalence and Associated Risk Factors. *International Journal of Animal and Veterinary Advances*, 3 (5): 374-378.

Ahmed WM, Mousa WM, Aboelhadid SM and Tawfik MM (2014): Prevalence of zoonotic and other gastrointestinal parasites in police and house dogs in Alexandria, Egypt. *Veterinary World*, 7(5): 275-280.

Buehl IE, H. Prosal; H. C. Mundt; A. G. Ticgy and A. Joachim (2006). Canine isosporosis epidemiology of field and experimental infection. *Journal of veterinary medicine. B, Infectious Disease and Veterinary Public Health*, 53(10): 482-487.

Bugg RJ, Robertson ID, Elliot AD, Thompson RC (1999). Gastrointestinal parasites of urban dogs in Perth, Western Australia. *Veterinary journal (United Kingdom)*, 157 (3): 295-301. <https://doi.org/10.1053/tvj.1998.0327>.

Cable RM (1985). *An Illustrated Laboratory Manual of Parasitology*. 5th edition. Surjeet publications Delhi, P 242-243.

Charles M and Hendrix (1998). *Diagnostic Veterinary Parasitology*. 2nd edition. P 254.

Chattha MA, Aslam A, Rehman ZU, Khan JA, Avais M (2009). prevalence of *Toxocara canis* infection in dogs and its effects on various blood parameters in lahore (pakistan). *Journal of animal & plant sciences*, 19(2): 71-73.

Coles HE (1986). *Veterinary Clinical Pathology*. 4th edition, W.B. Company. P 31.

Daryani A, Sharif M, Amouei A, Gholami S (2009). prevalence of *toxocara canis* in stray dogs, northern iran. *Pakistan journal of biological science*, 12 (14): 1031-1035. <https://doi.org/10.1016/j.ijid.2008.05.1002>

Davoust B, Normand T, Bourry O, Dang H, Leroy E, Bourdoiseau G (2008). Epidemiological survey on gastrointestinal and blood-borne helminths of dogs in northeast Gabon. *Onderstepoort Journal of Veterinary Research*, 75 (4): 359-364.

Egui'a-Aguilara, P.; Cruz-Reyesb, A. and Marti'nez-Mayac, J.J. (2005):

- Ecological analysis and description of the intestinal helminths present in dogs in Mexico City. *Veterinary Parasitology*, 127 (2) :139–146
- Englar RE (2017): *Performing the Small Animal Physical Examination*. 1st edition. John Wiley & Sons, Inc.
- Epe C (2009). Intestinal nematodes: biology and control. *Veterinary Clinic of North America Small Animal Practice*, 39 (6):1091–1107. <https://doi.org/10.1016/j.cvsm.2009.07.002>
- Eslami A, Ranjbar-Bahadori SH, Meshgi B, Dehghan M, Bokaie S (2010). Helminth infections of stray dogs from garmsar, Semnan province, central Iran. *Iranian Journal of Parasitology*, 5 (4): 37-41.
- Ferreira Ju´nior A, Gonc,alves-Pires MRF, Silva DAO, Gonc,alves ALR, Costa-Cruz JM (2005). Parasitological and serological diagnosis of *Strongyloides stercoralis* in domesticated dogs from southeastern Brazil. *Veterinary Parasitology Journal*, 136: (2): 137–145. <https://doi.org/10.1016/j.vetpar.2005.10.022>
- Hayden DW, Kruiningen HJ (1975). Experimentally induced canine toxocarosis: Laboratory pathologic changes, with emphasis on the gastrointestinal tract. *American Journal of veterinary research*, 36 (11): 1605-1614. <http://europemc.org/abstract/MED/53022>
- Jain NC (1986). *Schalm's Veterinary Hematology*. 4th edition. Lea and Febiger, Philadelphia, U.S.A.
- Kaymaz AA, Bakirel U, Gonul R, Tan H (1999). Serum protein electrophoresis in dogs with intestinal parasites. *Turkish Journal of Veterinary and Animal Sciences*, 23 (5), 457-459.
- Kimura A, Morishima Y, Nagahama S, Horikoshi T, Dagawa A, KawabuchiKurata T, Sugiyama H, Yamasaki HA (2013). Coprological survey of intestinal helminthes in stray dogs captured in Osaka prefecture, Japan. *Journal of Veterinary Medical Science*, 75(10), 1409-1411. <https://doi.org/10.1292/jvms.12-0499>
- Kirkova Z, Dinev I (2005). Morphological changes in the intestine of dogs, experimentally infected with *Trichuris vulpis*. *Bulgarian Journal of Veterinary Medicine*, 8 (4): 239–243.
- Kumar M, Sharma B, Kumar A, Lal HP, Kumar V, Tripathi MK (2014). Prevalence and Haemato-Biochemical Studies of *Toxocara canis* Infestation in dogs and risk perception of zoonoses by dog owners in Mathura, India. *Asian Journal of Animal and Veterinary Advances*, 9 (10): 653-663. <https://doi.org/10.3923/ajava.2014.653.663>
- Mohamed AS, Moore GE and Glickman LT (2009). Prevalence of intestinal nematode parasitism among pet dogs in the United States (2003–2006). *Journal of the American Veterinary Medical Association*, 234(5): 631-637.
- Nisar M, Khan JA, Khan MS, Khan IA (2009). Prevalence of coccidiosis in dogs along with haematological alteration as a result of chemotherapeutic trial. *Pakistan Veterinary Journal*, 29 (3): 138-140.

- Nwoha RIO, Anene BM, Eze IO (2013). Serum biochemical and liver enzymes change in dogs with single and conjunct experimental infections of trypanosoma brucei and ancylostoma caninum. *International Journal of Tropical Medicine*, 7 (4): 138-142. <https://doi.org/10.3923/ijtm.2012.138.142>
- Ogunkoya AB, Useh NM, Esievo KAN (2006). The Haemogram of Dogs with Gastrointestinal Parasites in Zaria, Nigeria. *Journal of Animal and Veterinary Advances*, 5 (9): 782-785.
- Oliveira-Sequeira TCG, Amarante AFT, Ferrari TB, Nunes LC (2002). Prevalence of intestinal parasites in dogs from Sa ~o Paulo State, Brazil. *Veterinary Parasitology*, 103 (1-2): 19–27. [https://doi.org/10.1016/S0304-4017\(01\)00575-1](https://doi.org/10.1016/S0304-4017(01)00575-1)
- Overgaauw PA (1997). Aspects of Toxocara epidemiology: Toxocarosis in dogs and cats. *Critical Reviews in Microbiology*, 23 (3): 233–251. <https://doi.org/10.3109/10408419709115138>
- Qadir S, Dixit AK, Dixit P, Sharma RL (2011). Intestinal helminths induce haematological changes in dogs from Jabalpur, India. *Journal of Helminthology*, 85 (4): 401–403. <https://doi.org/DOI:10.1017/S0022149X10000726>
- Radwan NA, Khalil AI, Mahi RAE (2009). Morphology and Occurrence of Species of Toxocara in Wild Mammal Populations from Egypt. *Comparative Parasitology*, 76 (2): 273- 282.
- Robertson ID, Thompson RC (2002). Enteric parasitic zoonoses of domesticated dogs and cats. *Microbes and Infection*, 4(8): 867-873. [https://doi.org/https://doi.org/10.1016/S1286-4579\(02\)01607-6](https://doi.org/https://doi.org/10.1016/S1286-4579(02)01607-6)
- Salem NY, Yehia SG, El-sheriff MA (2015). HematoBiochemical and Mineral Status in Dogs with Intermittent Diarrhea and Unthriftiness. *Research Journal of Veterinary Practitioners*, 3(4): 89-92.
- Savolainen P, zhang YP, Luo J, Lundeberge J, Leitner T (2002). Genetic evidence for an East Asia origin of domestic dogs. *Science*, 298(5598): 1610-16132.
- Schmidt EMS, Tvariionaviciute A, MartinezSubiela S, Cerón JJ, Eckersall PD (2016). Changes in biochemical analytes in female dogs with subclinical Ancylostoma spp. infection. *BioMed Central Veterinary research*, 12(1): 203.
- Seah SSK, Hucal G, Law C (1975). Dogs and intestinal parasites: a public health problem. *Canadian Medical Association Journal*, 112 (10): 1191-1194. <https://pubmed.ncbi.nlm.nih.gov/1125888>
- Sharma SK, Sinha SRP, Sinha S, Jayachandran C, Kumar M (2010). post treatment haematological studies in toxocarosis in dogs. *Journal of Veterinary parasitology*, 24 (1): 63-65.
- Soulsby E JL (1982). *Helminthes, Arthropods and protozoa of Domesticated animals*. 7th edition. Baillie Tindal, London: 809.

- Stehr-Green JK, Murray G, Schantz PM, Wahlquist SP (1987). Intestinal parasites in pet store puppies in Atlanta. *American journal of public health*, 77 (3): 345-346. <https://doi.org/10.2105/ajph.77.3.345>
- Swai ES, Kaaya EJ, Mshanga DA, Mbise EW (2010). A Survey on Gastro-Intestinal Parasites of Non-Descript Dogs in and Around Arusha Municipality, Tanzania. *International Journal of Animal and Veterinary Advance*, 3(2): 63-67.
- Trasviña-Muñoz E, López-Valencia G, Centeno PÁ, Cueto-González SA, Monge-Navarro FJ, TinocoGracia L, Núñez-Castroa K, Pérez-Ortiza P, MedinaBasulto GE, Tamayo-Sosaa AR, Gómez-Gómez, D (2017). Prevalence and distribution of intestinal parasites in stray dogs in the Northwest area of Mexico. *Austral Journal of Veterinary Sciences*, 49(2): 105-111. <https://doi.org/10.4067/S0719-81322017000200105>
- Ugbomoiko US, Ariza L, Heukelbach J (2008). Parasites of importance for human health in Nigerian dogs: High prevalence and limited knowledge of pet owners. *Biomed Central Veterinary research*, 4(1): 49-57.
- Urquhart GM, Armour J, Duncan JL, Dunn A M, Jennings FW (2001). *Veterinary Parasitology*. English Language Book Society Longman.