

Efficacy of Nano fat versus Non-Enzymatic Stromal Vascular Fraction in the Treatment of Androgenetic Alopecia

Ibrahim Mahmoud Ibrahim Mohamed Elnokrashy ^{1,*} MSc, Mohamed Ahmed El-Khalawany, ¹MD, Shady Mahmoud Attia, ¹MD

* Corresponding Author:

Ibrahim Mahmoud Ibrahim Mohamed Elnokrashy
ibrahimelnkrashy@gmail.com

Received for publication November 22, 2021; Accepted March 31, 2022; Published online March 31, 2022.

Copyright The Author published by Al-Azhar University, Faculty of Medicine, Cairo, Egypt. Users have the right to read, download, copy, distribute, print, search, or link to the full texts of articles under the following conditions: Creative Commons Attribution-Share Alike 4.0 International Public License (CC BY-SA 4.0).

doi: 10.21608/aimj.2022.104278.1657

¹Dermatology & Venereology and Andrology Department, Faculty of Medicine, Al-Azhar University, Cairo, Egypt.

ABSTRACT

Background: Androgenic alopecia is a common condition that is defined by the progressive conversion of terminal hairs to villus hairs in a unique distribution in both males and females. Therefore, autologous fat injection is tried as a new promising treatment for AGA.

Aim of the study: To evaluate the efficacy of nanofat versus non-enzymatic stromal vascular fraction in the treatment of androgenic alopecia.

Patients and Methods: A prospective randomized controlled study was done among 30 patients have androgenic alopecia from February 2021 to October 2021. Patients were separated into two groups of equal size; Group A which is treated by autologous Nanofat injection and Group B which is treated by stromal vascular fraction injection.

Results: The present study showed great improvement in 1 participants (6.7%) in group A and 4 participants (26.7%) in group B. moderate improvement present in 2 participants (13.3%) in group A and 7 participants (46.7%) in group B. slight improvement occurred in 8 participants (53.3%) in group A and 2 participants (13.3%) in group B. after 6 months of treatment No response occurred in 4 participants (26.7%) in group A and 2 participants (13.3%) in group B. As regard hair count/cm², it was 129.9 ± 13.7 /cm² before treatment and it was 139.5 ± 18.1 /cm² after treatment in group A. While it was 129.5 ± 10.8 /cm² before treatment and it was 158.1 ± 21.02 /cm² after treatment, all nonresponsive participants had higher grades of AGA.

Conclusion: Both Nanofat and SVF were effective in treatment of Androgenic alopecia with statistically significant difference as regard increase in hair density, clinical improvement and patient satisfaction.

Keywords: Autologous Nanofat; Stromal vascular fraction; Androgenic alopecia.

Disclosure: The authors have no financial interest to declare in relation to the content of this article. The Article Processing Charge was paid for by the authors.

Authorship: All authors have a substantial contribution to the article.

INTRODUCTION

Androgenic alopecia is a kind of hair loss that affects both men and women. Androgenic alopecia is caused by a combination of genetic predisposition and hormonal imbalances. We now have a better grasp of the factors that incriminated in hair loss in androgenic alopecia due to recent discoveries in molecular biology and genetics.¹

The utilization of adipose tissue and ADSCs in regenerative medicine is becoming more common in all sectors of medicine. Hair loss and thickness of subcutaneous fat in the scalp have been linked as the decrease in scalp thickness and loss of its fat was found to be associated with hair loss. In addition, several researches on the effect of ADSCs in the growing of hair have shown connection between these two forms of cell treatments and the growing of hair. In consequence, the adipose tissue has been proven to be an important part of the natural hair cycle.²

ADRCs not only have the ability to differentiate into mesenchymal cells but also produce multiple growth factors that may have an effect in new vessel formation which is essential in management of many hair loss problems.³ Moreover, addition of fat in the subcutaneous layer of the scalp lead to increase of its thickness which is frequently thinner in androgenic alopecia.⁴

The area with support cells is called the stroma. Accordingly the stroma contains high amount of stem cells (ADSCs) in the area that surround blood vessels. Yet Nano fat is emulsified adipose tissue, it can be produced mechanically and easily pass from 27 gauge needle.⁵

Unique compartment present in the fat tissue that have regenerative properties and can differentiate to many types of cell which called SVF. In addition to, adipose derived stem cells, SVF contains variant cell types; ASCs, mesenchymal, endothelial cells, pericytes, leukocytes. Despite that the enzyme dependant technique is highly successful at SVF

separation, it is a costly and consumes a lot of time, and also it requires an additional level of enzymatic purification. Also, it damaging the stem-cell niche; defined as the environment that present around the stem cell which allows connection between it and the neighbouring cells which enhances surviving, dividing and growth of cells.⁶ So using the simple mechanical method is now growing and even may replace the complicated expensive enzymatic method of SVF preparation. Non- enzymatic SVF is a mechanical process that get rid of almost all lipids and fluids from aspirated fat so stem cells and fragmented extracellular matrix are the only reminder.⁷

As regard stem cell therapy, one of these promising fields is Nanofat stem cells (NFSCs) which considered a subdivision of ADSCs. A study of histological modifications in the skin that follow adipose tissue and ADSCs injection found that this therapy was successful in modification of the structures present in dermis in order to rejuvenate the skin. NFSCs have great role in tissue healing after being injured also major role in rejuvenating the skin, reformation of elastin, collagen, cellular matrix, and blood vessels. Which is essential for the reversal of skin aging signs.⁸ This work aim to evaluate the efficacy of Nanofat vs non-enzymatic SVF in treating androgenic alopecia.

PATIENTS AND METHODS

This study was done for 30 patients (8males and 22 females) suffering from androgenic alopecia from February to October 2021. patients were randomized into 2 equal groups; Group A injected with single session of autologous Nanofat and Group B injected with single session of stromal vascular fraction injection. All patients were recruited from the Dermatology outpatient clinic of Al-Azhar University Hospitals.

Evaluation was done by USB digital trichoscopy and canon digital camera (EOS 800EF-S 18-55mm F4-5.60 IS STM lens - 24.2MP DSLR) at baseline and after 6 months of treatment. two independent blinded dermatologists were asked to compare digital and trichoscopic pictures at 6 months after treatment with baseline pictures regarding hair status as following; Great worsening get score -3, Moderate worsening get score -2, Slight worsening get score -1, Stabilized get score 0, Slight improvement get score 1, Moderate improvement get score 2 and Great improvement get score 3.

Also we ask patients to evaluate their satisfaction level by giving themselves a score from 0-3 points and the score was translated as follow; highly dissatisfied get score 0, dissatisfied get score 1, satisfied get score 2 and highly satisfied get score 3. An approval was obtained from the Ethical Research Board (ERB) of the Faculty of Medicine, Al-Azhar University in Cairo. Before the study proceeding, all patients assigned Informed consent after the obvious explanation of the possible adverse events.

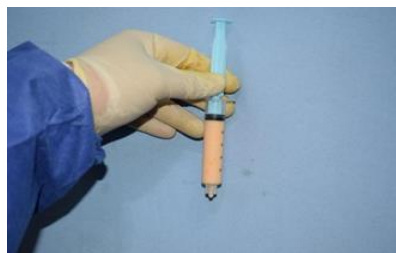

Fig.1: Emulsified Nanofat

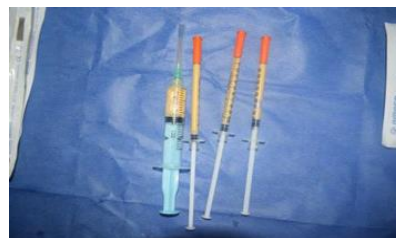

Fig. 2: Nanofat injection syringes

As regard autologous Nanofat preparation we collected fat under tumescent anesthesia using the Coleman method. After that we performed liposuction using a 3 mm specific cannula with 3 holes, starting in deep fat tissue in the abdomen and moving up repeatedly with a fanning technique with back and forth movements. After the harvesting is made, we washed the collected fat with ringer to discard all of the blood and adrenaline; they are both harmful to the fat particles and decrease their chance of survival in the recipient sit. The emulsification process starting by gentle thirty passages through the 2.4 mm adaptor with minimal pressure applied to generate force that is enough to emulsify and not to crush and destroy cells. Then we made another thirty passes through the 1.4 and 1.2 mm adaptors to produce an equal decrease in fat size. A single pass of this micro fat through the Nanofat filter with 0.6mm pores was done to produce Nanofat. After processing was completed, patients had scalp injection of 0.1 ml/cm² of emulsified Nano fat using 30 G syringes.



Fig.3: SVF preparation, upper oil, Middle fat and SVF pellet in the bottom

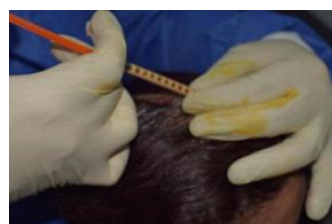

Fig.4: Nanofat injection technique

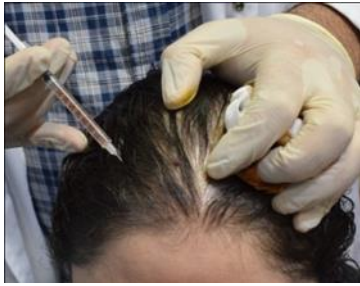


Fig.5: SVF injection

On the other hand, SVF preparation is quite different in which After we harvesting a 60 ml of fat, the process of condensation started by centrifugation of lipoaspirate at 500g for 2 minutes and this was enough to isolate the tumescent fluid and the blood elements in the lowest layer were they then discarded. After centrifugation, fat was passed 30

times between two Luer lock 20-ml syringes connected to each other by connectors 2.4mm, 1.4mm, and 1.2mm arranged from higher diameter to lower diameter with minimal pressure force in order to achieve successful mechanical micronization of fat. The micronized fat was the undergoing another centrifugation (1200 g for 3 minutes) to eliminate the oil. When oil was eliminated, the emulsified fat was filtered by passing through a Nano filter with a 0.6mm pore size to produce residual tissue of emulsified fat and filtrated fluid of emulsified fat. For the last time the product was centrifuged at 1200g for 6 minutes, as a result of this process, 3 layers are obtained depending on the density with the SVF pellet in the bottom. After isolation of SVF in one -ml syringes, the scalp is injected with 0.1 ml/cm² of SVF intra-dermal with small 30 G needle.

RESULTS

The present study showed great improvement in 1 participants (6.7%) in group A and 4 participants (26.7%) in group B. moderate improvement present in 2 participants (13.3%) in group A and 7 participants (46.7%) in group B. slight improvement occurred in 8 participants (53.3%) in group A and 2 participants (13.3%) in group B. after 6 months of treatment No response occurred in 4 participants (26.7%) in group A and 2 participants (13.3%) in group B. As regard hair count/cm², it was 129.9 ± 13.7 /cm² before treatment and it was 139.5 ± 18.1 /cm² after treatment in group A. While it was 129.5 ± 10.8 /cm² before treatment and it was 158.1 ± 21.02 /cm² after treatment, all nonresponsive participants had higher grades of AGA.

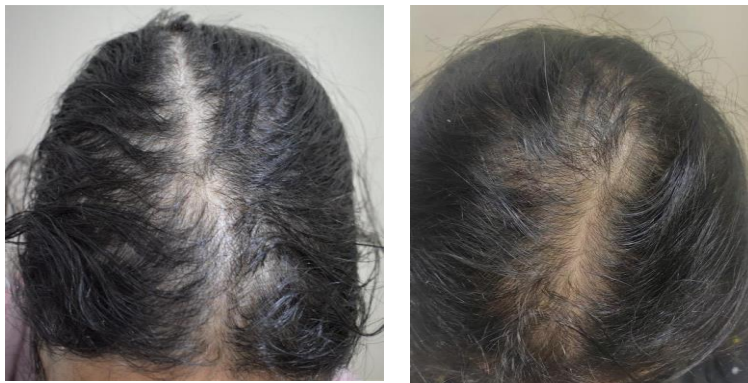

Fig.6: Female patient 27 years old complaining of hair loss of 1 year duration before (left) treated with single session SVF injection showing improvement after (right) 6 months of single session of SVF injection.

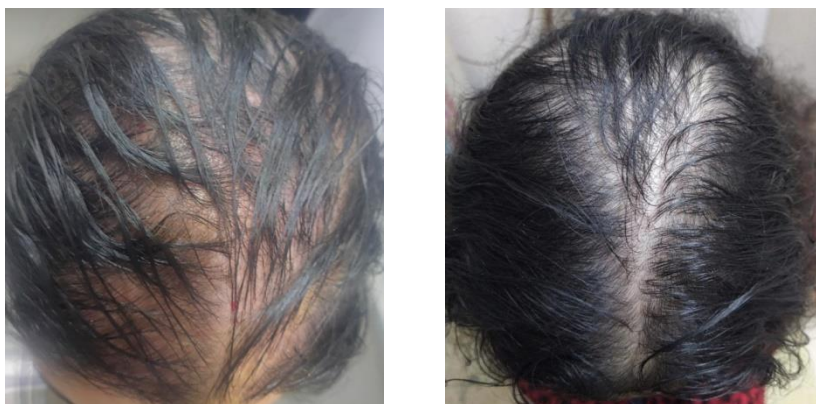


Fig.7: Female patient 23 years old complaining of hair loss of 6 months duration before (left) treated with single session Nanofat injection showing improvement after (right) 6 months of single session of Nanofat injection.

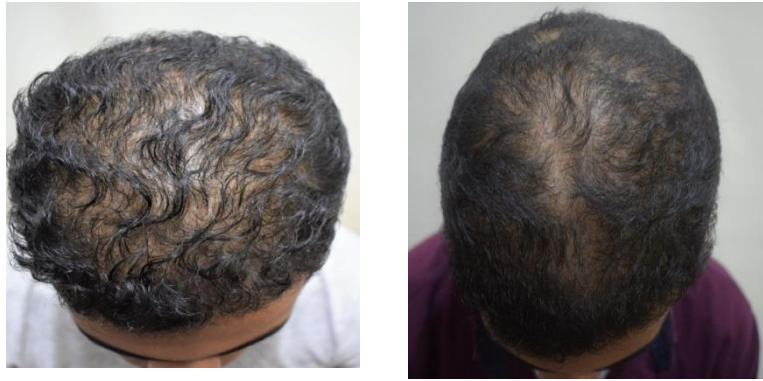

Fig.8: Male patient 21 years old complaining of hair loss of 11 months duration before (left) treated with single session SVF injection showing improvement after (right) 6 months of single session of SVF injection.

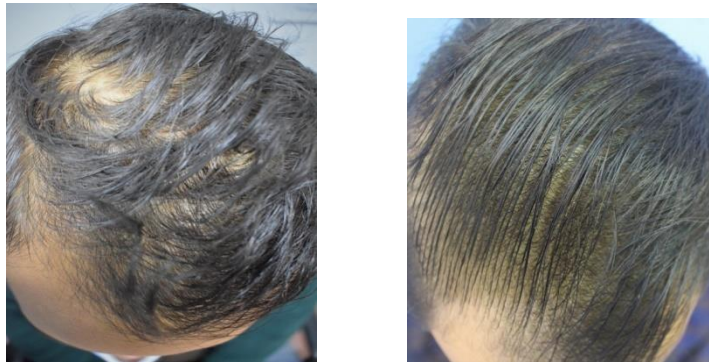

Fig.9: Male patient 25 years old complaining of hair loss of 2 years duration before (left) treated with single session Nanofat injection showing improvement after (right) 6 months of single session of Nanofat injection.

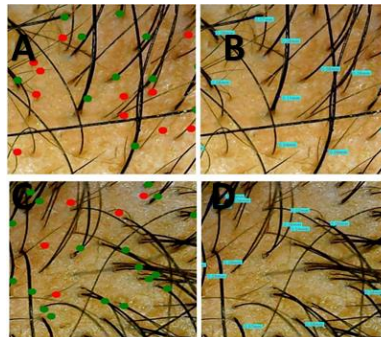


Fig. 10: USB digital trichoscopy is used to assess hair density and thickness before (A, B) and after (C, D), showing decrease hair density and hair thinning before treatment (A,B) and increase hair density and thickness after single session of SVF injection.(C,D).

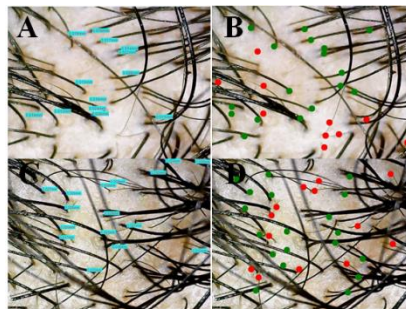


Fig. 11: USB digital trichoscopy is used to assess hair density and thickness before (A, B) and after (C, D), showing decrease hair density and hair thinning before treatment (A,B) and increase hair density and thickness after single session of Nanofat injection.(C,D).

		Group A (N = 15)		Group B (N = 15)		Stat. test	P-value
Improvement	Stable	4	26.7%	2	13.3%	$X^2 = 8.84$	0.031 S
	Slight improvement	8	53.3%	2	13.3%		
	Moderate improvement	2	13.3%	7	46.7%		
	Great improvement	1	6.7%	4	26.7%		

Table 1: Comparison between studied groups as regard digital and trichoscopic photography
This table shows statistically significant difference (p-value < 0.05) between studied groups as regard digital and Trichoscopic photography.

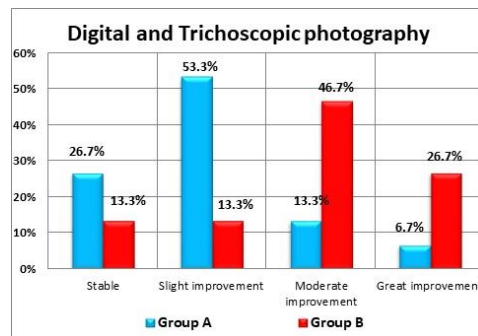


Fig. 11: Comparison between studied groups as regard digital and trichoscopic Photography, showing that group B is improved more than group A as regard digital and trichoscopic photos.

Hair count (/cm ²)		Group A (N = 15)		Group B (N = 15)		Stat. test	P-value
Before	Mean	129.9	129.5	T = 0.074	0.942 NS		
	±SD	13.7	10.8				
After	Mean	139.5	158.1	T = 2.58	0.015 S		
	±SD	18.1	21.02				
Follow	T	1.65	4.7				
	p-value	0.110 NS	< 0.001 HS				

Table 2: Comparison between studied groups as regard hair count.

This table shows no statistical significant difference (p-value > 0.05) between studied groups as regard hair count/cm² before treatment. It was 129.9 ± 13.7 /cm² in group A versus 129.5 ± 10.8 /cm² in group B. Statistically significant difference (p-value < 0.05) between studied groups as regard hair count/cm² after treatment. It was 139.5 ± 18.1 /cm² in group A versus 158.1 ± 21.02 /cm² in group B. No statistical significant difference (p-value > 0.05) of hair count/cm² (before & after treatment) in group A. Before treatment, it was 129.9 ± 13.7 /cm² while after treatment; it was 139.5 ± 18.1 /cm². Highly statistical significant difference (p-value < 0.001) of hair count/cm² (before & after treatment) in group B. Before treatment, it was 129.5 ± 10.8 /cm² while after treatment; it was 158.1 ± 21.02 /cm².

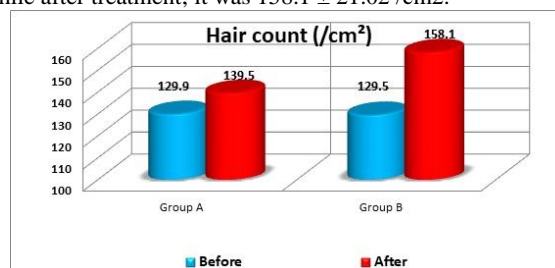


Fig. 12: Comparison between studied groups as regard hair count/cm², showing that group B is improved more than group A as regard hair count/cm²

		Group A (N = 15)		Group B (N = 15)		Stat. test	P-value
Patient's satisfaction	Highly dissatisfied	6	40%	4	26.7%	$X^2 = 8.8$	0.032 S
	Dissatisfied	5	33.3%	0	0%		
	Satisfied	3	20%	7	46.7%		
	Highly satisfied	1	6.7%	4	26.7%		

Table 3: comparison between studied groups as regard patient's satisfaction.

This table shows statistically significant difference (p-value < 0.05) between studied groups as regard patient's satisfaction

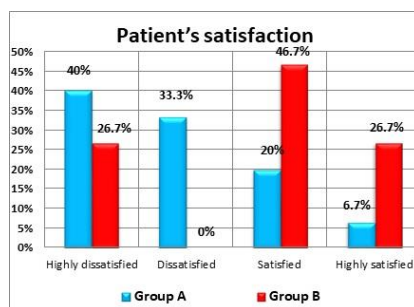


Fig. 13: Comparison between studied groups as regard patient's satisfaction showing that, satisfaction level is higher in group B than group A.

DISCUSSION

Androgenic alopecia is a kind of hair loss that affects both men and women. Androgenic alopecia is caused by a combination of genetic predisposition and hormonal imbalances. We now have a better grasp of the factors that incriminated in hair loss in androgenic alopecia due to recent discoveries in molecular biology and genetics.

Several studies was done to evaluate the efficacy of single session nanofat or SVF in the treatment of AGA and due to the complexity of this procedure and good response in most patients by single injection, there was no need for more sessions. Recently, treatments of androgenic alopecia are getting more attention and become promising, autologous adipose tissue is one of the best promising treatments in managing AGA. It is used for many indications as augmenting tissue, contour of face, and rejuvenating the skin. Advances have been done in the formation and processing of fat in order to achieve many regenerative effects in addition to the filling effect of fat cells and also it may had the ability to reverse the process of degeneration that occur in hair follicle.

This new era of fat applications was mainly started in 2001 when Zuk et al. explain multi potent progenitor cells called adipose derived stem cells (ADSCs).⁹ this cells have the capability to differentiate to many kinds of cells and have regenerative properties.

This current study was done for 30 patients having androgenic alopecia. 15 patients are treated by single injection of Nanofat and other 15 patients are treated by single injection of non-enzymatic SVF. All patients completed the study. Both treatments were relatively effective and may be promising options in treating of androgenic alopecia. There was statistical significant difference as regard hair density and thickness, patient satisfaction and global photography at the end of treatment period and follow up for six months.

We found one study that evaluate Nanofat efficacy in treatment of androgenic alopecia, this study conducted by (Michelangelo Vestita, et al .., 2019). The purpose of his work was to assess the effectiveness of Nanofat as a new treatment in androgenic alopecia. The study was done for 12 males affected with androgenic alopecia diagnosed clinically and trichoscopically. After Nanofat preparation, each participant was treated by one

injection of Nanofat. Evaluation was done for every patient by trichoscopy at the same marked area before and after follow up period.¹⁰ This study found that all patients show an increase in hair count and diameter at the 3 months follow up and partial persistence at 12 months. This difference may be due to higher grades of AGA in our study and higher sample size. Also negative impact of Covid -19 on hair status may have a role.

On reviewing the literature, we found few studies that evaluate stromal vascular fraction efficacy in treatment of androgenic alopecia. Sun Jong Kim et al., 2021, study was done to confirm the efficacy of the SVF in the treatment of AGA. They treated 9 patients with single injection of SVF in the vertex of the scalp. They found significant increase in hair diameter and count after 6 months therapy.¹¹ Our results are relatively similar to (Sun Jong Kim et al., 2021) as our study shows that SVF is very effective in the treatment of androgenic alopecia.

In agreement with our study, David Perez-Meza et al., 2017, they brought 9 patients; 8 males, 1 female with different grades of AGA. Only six had completed the Study as 3 of them dropped from the study. Inadequate amount of aspirated lipids was harvested in one patient and therefore, they inject fat alone. In this study, a mean increase of 31 hairs/cm² of scalp was found in patients treated by fat plus SVF while the one participant who had fat injection alone recorded a mean increase of 14 hairs/cm². Also they concluded that while fat alone may be an efficient approach for the treatment of AGA. But SVF addition may improve the outcome of therapy.¹²

Our results suggesting that SVF is more effective in hair loss than Nanofat and combination may be even better which is relatively similar to David Perez-Meza study as they suggest that fat alone may improve early AGA. However addition of SVF may enhance this result and increase response.

On the other hand and in support of our findings in our study, SVF efficacy in the treatment of AGA was mentioned by Ozturk P et al, as they brought 20 patients (14 males and 6 females) with AGA. Fat harvesting and processing were done, then all patients were injected with SVF in the scalp. Improvement was noted as regard hair density and diameter.¹³

Finally, there were no studies that compare the efficacy of these two modalities and we think that both methods are encouraging but not the ideal

solution of the androgenic alopecia which is caused by multi-factorial etiology. More comparative studies of different treatments that may treat the etiology of androgenic alopecia are strongly recommended.

CONCLUSION

Both Nanofat and SVF showed promising results in treating of androgenic alopecia with Stromal vascular fraction being more effective than Nanofat as their statistically significant difference between two groups at end of follow up as indicated by the p-value which was (< 0.05) as regard the digital and trichoscopic photography and also patient satisfaction as indicated by P value (< 0.05).

REFERENCES

- Martinez-Jacobo L, Villarreal-Villarreal CD, Ortiz-López R, Ocampo-Candiani J, Rojas-Martínez A. Genetic and molecular aspects of androgenetic alopecia. *Indian J Dermatol Venereol Leprol.* 2018 ; May-Jun;84(3):263-8.
- Festa E, Fretz J, Berry R, Schmidt B, Rodeheffer M, Horowitz M, Horsley V. Adipocyte lineage cells contribute to the skin stem cell niche to drive hair cycling. *Cell.* 2011 Sep 2;146(5):761-71.
- Kinnaird T, Stabile E, Burnett MS, Lee CW, Barr S, Fuchs S, Epstein SE. Marrow-derived stromal cells express genes encoding a broad spectrum of arteriogenic cytokines and promote in vitro and in vivo arteriogenesis through paracrine mechanisms. *Circ Res.* 2004 Mar 19;94(5):678-85.
- Hori H, Moretti G, Rebora A, Crovato F. The thickness of human scalp: normal and bald. *J Invest Dermatol.* 1972 Jun;58(6):396-9.
- Tonnard P, Verpaele A, Peeters G, Hamdi M, Cornelissen M, Declercq H. Nanofat grafting: basic research and clinical applications. *Plast Reconstr Surg.* 2013 Oct;132(4):1017-26.
- Dai Prè E, Busato A, Mannucci S, Vurro F, De Francesco F, Riccio V, Solito S, Biswas R, Bernardi P, Riccio M, Sbarbati A. In Vitro Characterization of Adipose Stem Cells Non-Enzymatically Extracted from the Thigh and Abdomen. *Int J Mol Sci.* 2020 Apr 27;21(9):3081.
- Wang J, Liao Y, Xia J, Wang Z, Mo X, Feng J, He Y, Chen X, Li Y, Lu F, Cai J. Mechanical micronization of lipoaspirates for the treatment of hypertrophic scars. *Stem Cell Res Ther.* 2019 Jan 24;10(1):42.
- Charles-de-Sá L, Gontijo-de-Amorim NF, Maeda Takiya C, Borojevic R, Benati D, Bernardi P, Sbarbati A, Rigotti G. Antiaging treatment of the facial skin by fat graft and adipose-derived stem cells. *Plast Reconstr Surg.* 2015 Apr;135(4):999-1009.
- Ziade G, Karam D. Emulsified fat and nanofat for the treatment of dark circles. *Dermatol Ther.* 2020 Nov;33(6):e14100.
- Vestita M, Filoni A, Bonamonte D, Elia R, Giudice G. Abstract: The Use of Nanofat in Androgenic Alopecia. a Prospective Blinded Study. *Plast Reconstr Surg Glob Open.* 2017;5(9 Suppl):90.
- Kim SJ, Kim MJ, Lee YJ, Lee JC, Kim JH, Kim DH, Do YH, Choi JW, Chung SI, Do BR. Innovative method of alopecia treatment by autologous adipose-derived SVF. *Stem Cell Res Ther.* 2021 Aug 28;12(1):486.
- Perez-Meza D, Ziering C, Sforza M, Krishnan G, Ball E, Daniels E. Hair follicle growth by stromal vascular fraction-enhanced adipose transplantation in baldness. *Stem Cells Cloning.* 2017 Jul 6;10:1-10.
- Ozturk P, Bekerecioglu M. The Effect of Stromal Vascular Fraction for Patients with Androgenetic Alopecia. *J Turk Acad Dermat.* 2020;14:107-11.