



## THREE-DIMENSIONAL EVALUATION OF ANTERIOR OPEN BITE CORRECTION IN ADULT ORTHODONTIC PATIENTS: A PROSPECTIVE CLINICAL STUDY

Mahmoud Mohamed Mabrouk Gaafar<sup>1\*</sup>, Hussein Nassef Al-Khalifa<sup>2</sup>, El-Hassanein Hussein El-Hassanein<sup>3</sup>

### ABSTRACT

**Objective:** This study aimed to Evaluate AOB correction in adult orthodontic patients by Using Rapid Molar Intruder and posterior bite plane. **Subjects and Methods:** The current study was conducted on 20 orthodontic patients (4 males and 16 females) with an age range from 16 to 22 years who were collected from the outpatient clinic at Orthodontic Department, Faculty of Dental Medicine, Boys, Al-Azhar University, Cairo, Egypt. They were randomly divided into two groups; each consisted of 10 patients. The first group consisted of 10 patients, who received Rapid Molar Intruder (RMI) appliance with fixed appliance therapy. The second group consisted of 10 patients, who received fixed appliance therapy with posterior bite planes. **Results:** The results show a statistically non-significant difference between both groups. **Conclusions:** In the present study, Both Rapid molar intruder (RMI) and posterior bite plane (PBP) are efficient solutions regarding open bite correction.

**KEYWORDS:** Anterior open-bite, Rapid molar intruder, posterior bite plane, CBCT.

### INTRODUCTION

Anterior open bite (AOB) is one of the most difficult malocclusions to treat orthodontically without proper diagnosis, identification and elimination of etiologic factors, treatment stability of anterior open bite will have poor prognosis. When treatment is planned it should consider patient's age, dental and skeletal discrepancies, as treatment of AOB ranged from observation or simple control to complex surgical procedure<sup>(1,2)</sup>.

Treatment of AOB in growing patients could be done by preventing passive eruption of posterior teeth, using orthopedic functional appliances, while

treatment in adult patients is very challenging, treatment could be either by molar intrusion or incisor extrusion or both. Anterior incisor extrusion showed many drawbacks, because it left the skeletal component of deformity unchanged and in such cases, patients usually had shorter roots and less facial bone support of anterior teeth, leading to compromised esthetic results<sup>(3)</sup>.

Caravelli in 1842 coined the term "open bite" as a distinct classification of malocclusion. The anterior open bite (AOB) is also defined as the lack of incisal contact between anterior teeth in centric relation<sup>(1-5)</sup>, Subtelny and Sakuda<sup>(6)</sup> defined open

1. Masters Candidate, Kobry Al-Koba Military Hospital.
2. Associate Professor, Department of Orthodontics, Faculty of Dental Medicine, Boys, Cairo, Al-Azhar University.
3. Lecturer, Department of Orthodontics, Faculty of Dental Medicine, Boys, Cairo, Al-Azhar University.

• **Corresponding author:** mahmoudgaafar911@gmail.com

bite, as open vertical dimension between the incisal edges of the maxillary and mandibular anterior teeth, although deficiency in vertical dental contact can occur between the anterior or the buccal segment. Mizrahi<sup>(1)</sup> described anterior open-bite as a vertical discrepancy where upper incisor crowns fail to overlap the incisal third of the lower incisor crowns when the mandible is brought into full occlusion.

Posterior teeth intrusion is one of the treatment strategies for treating anterior open bites. Treatment approaches for open bite patients differ when dealing with adults and growing patients. In growing patients, the vertical forces applied against the molars serve not only to intrude the molars but simply to control their vertical eruption<sup>(3)</sup>.

In adults or non-growing patients with the absence of vertical compensation of ramus growth, the true intrusion of molar teeth is needed to let the mandible to auto-rotate and subsequently close the open bite anteriorly. According to jaw geometry, 1 mm of intrusion posteriorly would result in about 2 mm of anterior open bite closure<sup>(3)</sup>.

In addition, removable splint appliances leave the orthodontist totally dependent on patient compliance<sup>(2)</sup>, whereas bonded functional appliances present hygiene and posttreatment adhesive clean-up problems. The same compliance issue affects the successful application of a vertical chin cap<sup>(3)</sup>.

Bite blocks often are used as a component of orthodontic appliances to intrude or control eruption of the posterior teeth. Bite blocks made of wire or plastic fit between the maxillary and mandibular teeth at a slightly increased vertical dimension. The stretched muscles theoretically place an intrusive force on the posterior teeth, which in turn helps control eruption. With limited eruption, skeletal growth is directed more anteriorly and less vertically<sup>(4)</sup>.

Consequently, there is a need to provide some modicum of posterior vertical control or molar intrusion that can be achieved independent of patient

cooperation. The use of implants or screws as anchorage for molar intrusion may provide one such solution<sup>(5,6)</sup>, but the cost, discomfort, and potential morbidity are of concern. Therefore, a new method of obtaining vertical control by molar intrusion without dependence upon patient compliance or a surgical procedure or both<sup>(7)</sup>. The rapid molar intruder (RMI) uses flexible springs to deliver intrusion forces to the maxillary and mandibular first molars. The appliance consists of one spring module and two ball connectors per side.

## SUBJECTS AND METHODS

### Study design:

The study design was a prospective clinical study, with a parallel design where participants were randomly assigned into 2 groups; group I and II; with a 1:1 allocation ratio. No changes to the methods after study commencement occurred.

### Sample size calculation.

The estimated minimum sample size of 18 patients was selected that would be sufficient with power of 80% and 5% significance level to detect a clinically relevant difference based on a previous study<sup>(2)</sup>. It was decided to increase the sample size to 20 patients to compensate for any possible drop-outs or missing patients during the investigation.

### Ethical considerations:

The study was approved by the orthodontic scientific committee and department council. The patients and/or guardians were fully informed about the procedures, and informed written consents were signed by them before commencing the study work.

### Participants:

The current study was conducted initially on 20 orthodontic patients who were collected from the outpatient clinic at Orthodontic Department, Faculty of Dental Medicine, Boys, Al-Azhar University, Cairo, Egypt.

They were randomly divided into two groups; each consisted of 10 patients as follows:

The first group consisted of 10 patients, who received Rapid Molar Intruder (RMI) appliance with fixed appliance therapy.

The second group consisted of 10 patients, who received fixed appliance therapy with posterior bite planes.

The patients included in the study fulfilled the following criteria: Adult orthodontic patients with AOB, all permanent teeth are erupted (3rd molars not included), anterior open-bite, in part, due to posterior dento-alveolar excess without transverse problems, no cranio-facial syndromes, good oral and general health. No significant medical history that could interfere with orthodontic treatment and no previous orthodontic treatment.

The patients were excluded from the study if they had the following: severe anterior open bite especially those with skeletal origin. Uncooperative patient to the degree that affect obtaining the treatment objective.

The process of randomization and group allocation was undertaken using online software\*. Unfortunately, 2 patients were dropped out from the current study (1 patient from the group of the rapid molar intruder, and 1 patient from who had posterior bite plane). This was mainly due to lack of patient compliance and co-operation and the failure to communicate with most of them after performing the fixed orthodontic procedures. Additionally, it was very difficult to compensate for dropped out patients due to the relatively low prevalence and nature of this complex malocclusion. Therefore, the study objectives were evaluated with the remaining 18 patients.

### **Interventions**

For each patient enrolled in the study, the following orthodontic records were taken before treatment:

### **Preoperative:**

#### **Case history and clinical examination:**

A complete diagnostic sheet was done for each patient, including a detailed case history, extra-oral and intra-oral examinations. Additionally, a thorough medical history was taken carefully from each patient to exclude any systemic disease that could interfere with orthodontic and/or surgical procedures and the patients were checked to meet the inclusion criteria previously mentioned.

#### **Patients' records:**

**Routine orthodontic records:** For each patient a set of four extra-oral and five intra-oral photographs were taken, Panoramic radiograph, Standardized lateral cephalometric radiograph and Orthodontic study models.

**Research related records:** To fulfill the objectives of the current study, the following records were obtained for each patient prior to and upon completion of the period of posterior intrusion: Extra-oral and intra-oral photographs and Cone beam computed tomography:

For each patient, two CBCT scans were obtained; one pre-intrusion (T1) and another immediately after completion of intrusion (T2).

The CBCT images were acquired using Planmecca ProMax 3d scanner\*. Each patient was positioned in the machine and imaged at the same manner according to the recommendations of CBCT manufacturer. The Frankfurt plane was positioned parallel to the horizontal plane and the midsagittal plane was perpendicular to the horizontal plane.

### **Operative procedures**

#### **Orthodontic appliance**

**Molar bands:** Before the appliance was installed, working models were obtained from the patients with maxillary and mandibular molar bands (Ortho organizer metal bands, USA.) selected of a

readymade band with auxiliary tubes seated on the first molars <sup>(2)</sup>.

Because the force is applied buccal to the center of resistance of the molar teeth, buccal tipping of the molar crowns will be inevitable <sup>(2)</sup> To prevent this side effect, a lingual and transpalatal 1-mm stainless steel arches were bent for each patient on the plaster models. Care was taken not to place the transpalatal arches too far from the palate to eliminate the intrusion force that might be exerted by the relative pressure of tongue.

The lingual and palatal arches were then soldered to the molar bands. For those patients with fully erupted second molars in the RMI plus fixed appliance group, a 1-mm stainless steel wire occlusal rest was added that extended from the transpalatal and lingual arches to the occlusal surface of the second molar and second premolar to avoid elongation of these teeth and to distribute the force of the RMI across all of the posterior teeth rather than only the first molars <sup>(2)</sup>.

**Brackets:** Roth Oramco Straight-Wire™ (Oramco Corp., Orange, California, USA) Synthesis metal bracket system with 0.22 slot were bonded, using orthodontic bonding agent (Unitek™ Orthodontic Composite, 3M, Unitek, USA).

**Arch wire:** After direct bonding of the bracket

system installation of Nickel Titanium (Ni-Ti) arch wire (G&H wire company, USA) for leveling and alignment of teeth starting from 0.012" up to Stainless Steel (StSt) arch wire 0.016×0.022" in diameter.

#### **Fixed appliance:**

##### **Rapid Molar intruder (RMI) fixed functional appliance group:**

The rapid molar intruder (RMI) (Rapid molar intruder, American Orthodontics, Sheboygan, Wis.) utilized flexible springs to deliver intrusion forces to the maxillary and mandibular first molars (Fig. 1). The appliance consisted of one spring module and two ball connectors per side. The terminal ends of the flexible spring modules are designed to attach the ball connectors, which will insert into headgear or lip bumper tubes welded on molar bands <sup>(2)</sup>, When the patient tends to close his or her jaws, the intrusion force created by the flexion of the elastic spring modules is transferred to the maxillary and mandibular first molars.

##### **Posterior bite plane (PBP) group**

TPA with 3 to 4 mm<sup>6-12</sup> beyond the resting position to maintain pressure on the neuromuscular system supporting the mandible. acrylic posterior bite plane was delivered and the patients was trained to bite on it (Fig 2).

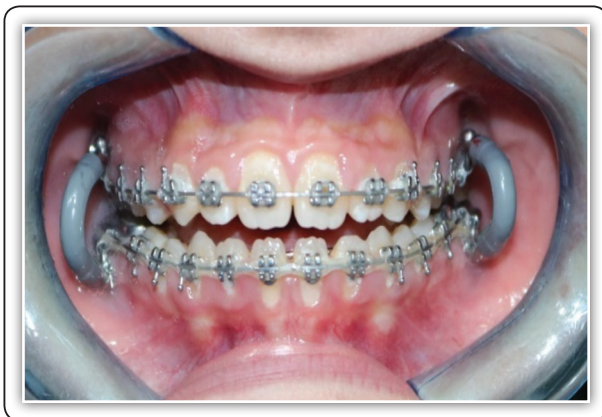

FIG (1): RMI with fixed appliance.

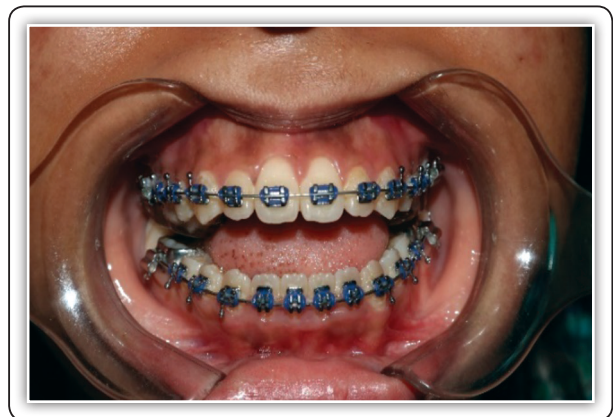

FIG (2): TPA with 4 mm acrylic posterior bite plane.

**Cone beam computed tomography (CBCT) analysis**

In order to accurately analyse the patients’ condition, a pre-intrusion CBCT scan was performed, the scan was done pre-intrusion (T1) and repeated 6 months after completion of intrusion (T2).

Radiographic assessment relied on registration of the pre-intrusion CBCT plan upon the post-treatment CBCT results, The pre-operative data from the CBCT scan were imported into InvivoDental Application v.5.3.1 (Anatomage.Inc., San Jose, CA). The three orthogonal planes; Axial, Coronal and Sagittal, are realigned to represent the Frankfort Horizontal Plane, the Vertical Plane. And the Midsagittal Plane respectively.

The Frankfort Horizontal Plane was identified by the patient’s Right Porion and their Right and Left Orbital Points. The Midsagittal plane was identified by the patient’s ANS, PNS, and Nasion Point. The Vertical Plane was identified as a plane perpendicular to the FHP and the MSP, and passing through the posterior wall of the Incisive Foramen (Fig 3).

Following point base registration, high precision Automatic Volume Based Registration is utilized for perfect superimposition between the pre-operative and post-operative scans.

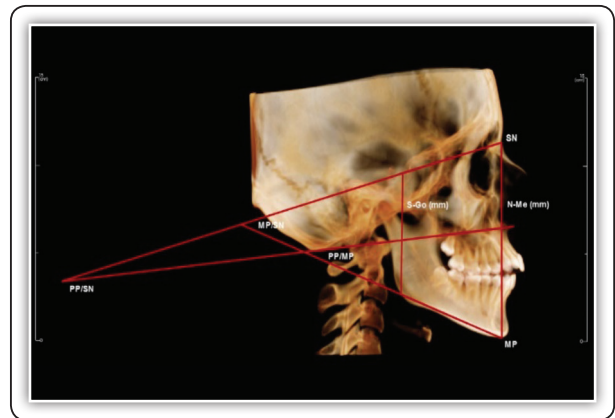


FIG (3): Skeletal reference lines and planes

**Finishing and retention**

After completion of posterior segment intrusion and obtaining the study objectives, comprehensive orthodontic treatment was completed according to the previously proposed treatment plan. At the end of the treatment, patients received bonded retainers for both arches and Hawley retainer with posterior bite plane for the upper arch.

**Statistical analysis**

Data were collected, revised, coded and entered to the Statistical Package for Social Science (SPSS) version 23. The quantitative data were presented as mean, standard deviations and ranges when parametric. Also, qualitative variables were presented as number and percentages.

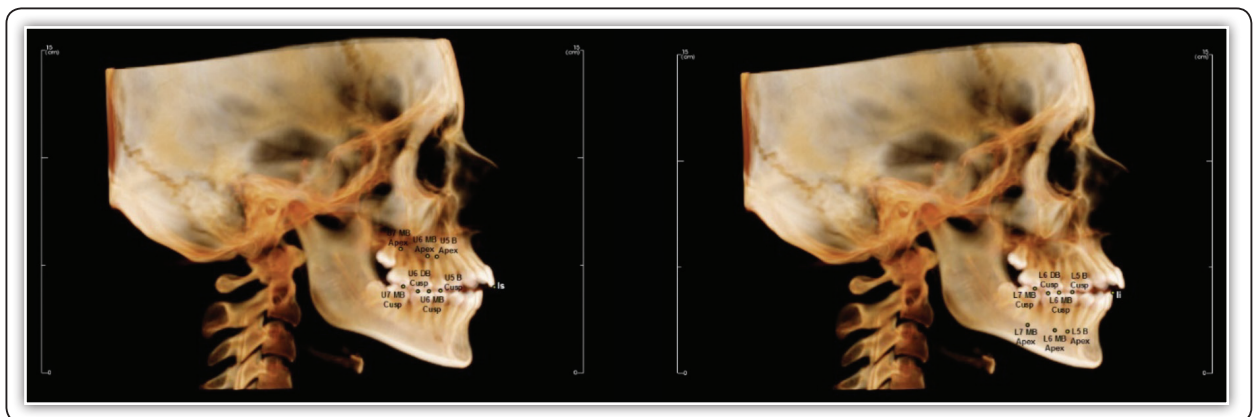


FIG (4): Dental reference points

The comparison between groups regarding qualitative data was done by using Chi-square test and/or Fisher exact test, The comparison between the two groups regarding quantitative data and parametric distribution was done by using Independent t-test while with non-parametric distribution was done by using Mann-Whitney test, The comparison between two paired groups regarding quantitative data and parametric distribution was done by using Paired t-test while with non-parametric distribution was done by using Wilcoxon Rank test.

**Error analysis**

The reliability of the analyzed data was verified using the method of intra-observer error assessment. A paired t-test was used to compare the first and the second readings of 24 randomly selected CBCT images, reanalyzed by the same investigator.

**RESULTS**

The previous table shows that there was statistically significant decrease in all the studied parameters post intrusion than pre intrusion in RMI group and in PBP group

The previous table shows that there was no statistically significant difference found between the two studied groups regarding the studied parameters post intrusion.

**Comparison of the skeletal measurements between groups:**

The previous table shows that there was no statistically significant difference found between the two studied groups regarding the studied parameters except angle between Frankfurt plan and mandibular plane was found significant higher in PBP group than RMI group with p-value = 0.014.

**TABLE (1):** Comparison of molar intrusion measurements between groups Comparison between the studied parameters pre and post intrusion in RMI group and PBP group

molar position	groups	measurements	Pre		Post		Difference			Test value	P-value	Sig.
			Mean ± SD	Range	Mean ± SD	Range	Mean	SD	SE			
upper right first molar position	RMI group	UR6 distance to Frankfort plane	45.86 ± 6.26	40.8–56.8	43.93 ± 4.42	40.5–51.1	-1.93	1.92	0.64	-2.668≠	0.008	HS
	PBP group	UR6 distance to Frankfort plan	45.63 ± 0.74	44.5–46.8	43.53 ± 1.01	42.1–45	-2.09	0.31	0.10	-2.692≠	0.007	HS
lower right first molar position	RMI group	LR 6 distance to mandibular plane	32.82 ± 3.34	27.8–37.7	32.17 ± 3.71	26.8–37.7	-0.66	0.42	0.14	-2.410≠	0.016	S
	PBP group	LR 6 distance to mandibular plane	34.78 ± 2.73	30.7–38.2	32.71 ± 4.29	25.7–36.3	-2.07	1.82	0.61	-2.670≠	0.008	HS

*Comparison between the studied parameters pre and post intrusion in RMI group and PBP group*

*P-value > 0.05: Non-significant; P-value < 0.05: Significant; P-value < 0.01: Highly significant*

*•: Paired t-test; ≠: Wilcoxon Rank test*

**TABLE (2):** Comparison between RMI and PBP group regarding the studied parameters post intrusion

Difference	RMI Group			PBP Group			Test value	P-value	Sig.
	Mean	SD	SE	Mean	SD	SE			
UR6 distance to Frankfort plane	1.93	1.92	0.64	2.09	0.31	0.10	-0.247•	0.808	NS
LR 6 distance to mandibular plane	0.66	0.42	0.14	2.07	1.82	0.61	-2.265•	0.038	S

The previous table shows that there was no statistically significant difference found between the two studied groups regarding the studied parameters post intrusion except amount of open bite from the incisal edge (upper) to the incisal edge (lower) and angle between Frankfurt plan and mandibular plane was found higher in PBP group than RMI group with p-value = 0.033 and 0.005 respectively.

**Independent t-test comparing the treatment changes in skeletal angular measurements between groups**

The previous table shows that there was no statistically significant difference found between the two studied groups regarding the difference between pre and post intrusion in all the studied and angle between Frankfurt plane and mandibular plane was found higher in RMI group than PBP group with p-value = 0.006 and 0.022 respectively

**TABLE (3):** Comparison between RMI and PBP group regarding the studied parameters pre intrusion and post intrusion

Pre	RMI Group		PBP Group		Test value	P-value	Sig.
	Mean ± SD	Range	Mean ± SD	Range			
Amount of openbite from the incisal edge (upper) to the incisal edge (lower)	6.70 ± 0.65	6 – 8.1	6.49 ± 0.55	5.4 – 7.2	-0.444≠	0.666	NS
Mandibular plane angle	30.79 ± 5.73	22 – 38	36.89 ± 3.30	33 – 42	-2.767•	0.014	S
Change in ANB angle.	2.91 ± 0.65	2 – 4.3	3.04 ± 1.61	1.4 – 6.3	-0.178≠	0.859	NS
Post	RMI Group		PBP Group		Test value	P-value	Sig.
	Mean ± SD	Range	Mean ± SD	Range			
Amount of openbite from the incisal edge (upper) to the incisal edge (lower)	3.88 ± 0.34	3.6 – 4.7	4.48 ± 0.76	3.6 – 5.9	-2.127≠	0.033	S
Mandibular plane angle	28.79 ± 5.62	21.2 – 37	35.81 ± 3.17	32.1 – 41	-3.264•	0.005	HS
Change in ANB angle.	2.26 ± 0.68	1.5 – 3.8	2.15 ± 0.92	1 – 3.8	-0.177≠	0.860	NS

*P-value > 0.05: Non-significant; P-value < 0.05: Significant; P-value < 0.01: Highly significant*

*•: Independent t-test; ≠: Mann-Whitney test*

**TABLE (4)** Comparison between RMI and PBP group regarding the difference between pre and post intrusion

Difference	RMI Group			PBP Group			Test value	P-value	Sig.
	Mean	SD	SE	Mean	SD	SE			
Amount of openbite from the incisal edge (upper) to the incisal edge (lower)	2.82	0.35	0.12	2.02	0.67	0.22	3.175•	0.006	HS
Mandibular plane angle	2.01	1.04	0.35	1.08	0.35	0.12	2.543•	0.022	S
Change in ANB angle.	0.65	0.16	0.05	0.89	0.77	0.26	-0.916•	0.374	NS

*P-value > 0.05: Non-significant; P-value < 0.05: Significant; P-value < 0.01: Highly significant*

*•: Independent t-test*

## DISCUSSION

Anterior open bite (AOB) has always been one of the most challenging malocclusions, not only to treat, but also to retain. Although, it is suggested that vertical discrepancies have to be solved before anteroposterior ones, the treatment of such cases continued to gain more linkage over their vertical counterparts (8-10).

The etiology of the AOB is multifactorial and was attributed to a combination of skeletal, dental, and soft-tissue defects (4,6,9,16). Many treatment modalities were proposed for such cases, like high pull head gear, vertical pull chin cup, as well as, intraoral functional appliances such as Harvold activator, open bite bionator, posterior bite blocks, as intrusive modalities whereby successful molar intrusion was achieved in an attempt to correct AOB (15,18).

One of the treatment options for correction of the anterior open bite was intrusion of the posterior teeth. Therefore, molar intrusion was suggested to be the best treatment choice because it could lead to an autorotation of the mandible in the counterclockwise direction, thus improving the long anterior facial height (6). However, there might be other, less-invasive treatment options not requiring orthognathic surgery. If it is possible to orthodontically intrude posterior teeth, the accompanying changes in occlusal plane, mandibular plane, lower anterior face height, and anterior dental overbite would close the patient's open bite. However, intrusion of posterior or anterior dentition is always difficult to achieve without the side effect of extrusion of the anchorage teeth (6, 11-17).

However, several reports argued that with the exception of posterior bite blocks, many of the treatment mechanics aimed to correct open bite were not effective in rotating the mandible forward and producing more condylar growth and having a lot of demerits as well (3,9,25).

The current randomized clinical study was directed to compare between two non-invasive,

non-compliant techniques for the correction of anterior open bite by the intrusion of the posterior maxillary teeth.

In the current study; two groups of initially 10 Egyptian patients for each, with AOB malocclusion were treated using RMI in the first group and PBP in the second group for maxillary molar intrusion. All the selected patients were ranged from 16-22 years; with mean age was  $18 \pm 3.4$  years (25). All of these patients refused the first option of combined orthognathic treatment option. However, they accepted a less invasive approach by using fixed functional appliance.

### Results interpretation

Concerning the results of the present study, there is no significant difference between both approaches of molar intrusion for correction of the current cases of anterior open bite (AOB).

### Amount of intrusion of maxillary 1<sup>st</sup> permanent molars

In the current study; within  $6 \pm 0.2$  months(2), the average amount of the achieved upper molars intrusion was 1.6 mm and 1.8 mm in both RMI and PBP groups, respectively. These findings are in agreement with what was previously reported in the literature (6,12,21) However, most of these reports used only miniplates and miniscrews for maxillary molar intrusion with 2D cephalometric radiographs for evaluation of intrusion.

The results of this study revealed that both RMI and PBP could be successfully used for molar intrusion. Statistical evaluation of these interventions revealed a significant amount of maxillary first right and left molars' intrusion ( $1.55 \pm 0.71$ mm and  $1.11 \pm 0.71$ mm, respectively, in group with RMI, as well as,  $1.37 \pm 0.39$ mm,  $1.50 \pm 0.46$ mm, respectively, in the group with PBP). These results agree with several studies which showed comparable amounts of successful molar intrusion using temporary anchorage devices (TADs) for AOB correction (12, 13, 15, 21).



On the other hand, other studies obtained different amounts of intrusion using TADs supported intrusive mechanics.<sup>(14, 16)</sup> The degree of the pre-treatment vertical skeletal discrepancy and the current study design could be accused for the yielded variability. E.g. Sherwood et al<sup>(6)</sup>, and Erverdi et al<sup>(15)</sup>, used titanium miniplates at the lower face of the zygomatic process of maxilla to assist in the correction of SAOB. Sherwood et al.<sup>(6)</sup>, demonstrated a mean upper molar intrusion of 1.99mm with intrusive forces continued for 5.5 months in 4 patients whereas Erverdi et al.<sup>(15)</sup>, reported a mean maxillary molar intrusion of 2.6mm in 10 patients after a mean of 5.1 months. Interestingly, Yao et al.<sup>(25)</sup>, used a combination of buccal miniplates and palatal mini-screws in 18 patients and buccal and palatal mini-screws in 4 patients who had over erupted maxillary molars. They reported that the mean intrusion of maxillary first molars was 3 to 4mm in a mean of 7.6 months.

A previous study showed the amount of molar intrusion achieved could be related to the application of intrusive mechanics for both upper and lower molars by using full fixed appliances and application of intrusive mechanics on the whole posterior upper and lower segments. In the current study, the intrusive forces were applied to both maxillary and mandibular molars and the intrusive mechanics were initiated after completion of leveling and alignment using fixed appliance.

#### **Amount of intrusion of mandibular 1<sup>st</sup> permanent molars**

In the current study; the mean of achieved lower molars intrusion was 1.2 mm in patients who had RMI fixed functional appliance, and 2.15 mm in the group of PBP in average time of  $6\pm 0.2$  months. These findings agree with those of previous study obtained  $1.9\pm 1.1$ mm<sup>(2)</sup> in growing individual using RMI without fixed appliance and  $3.05\pm 0.45$  mm<sup>(2)</sup> using RMI with fixed appliance, and disagreed with a study obtained 3-5 mm<sup>(44)</sup> intrusion, using skeletally anchored system.

#### **Change of mandibular plane angle**

This study resulted in  $-2^\circ$  and  $-1^\circ$  decrease in mandibular plane angle, with RMI and PBP respectively, These findings agreed with previous studies that reported significant mandibular autorotation signs<sup>(6, 18)</sup>, Tamami Shino who reported  $1^\circ$  mandibular rotation, but disagrees with the studies reported more than  $-2^\circ$  decrease in mandibular plane angle (Up to  $-3.9^\circ$ )<sup>(20, 25)</sup>. All these studies reported using miniscrews and miniplates for molar intrusion.

#### **Change of ANB angle**

In the present CBCT study, there was an average decrease in ANB angle in both groups treated with RMI and PBP of  $-0.7^\circ$  and  $-0.8^\circ$  respectively. This agrees with Albogha et al<sup>(2)</sup> who reported a decrease in ANB angle by  $-1.1 \pm 1.0^\circ$  with RMI and Taylor R et al<sup>(18)</sup> who reported an average of  $1.2^\circ$  decrease in ANB angle using mini-implant for intrusion and disagree with Tamami Shino<sup>(20)</sup> who reported no change of ANB angle with skeletally anchored intrusion, Similar findings were previously reported for skeletal open bite treatment with various appliances.<sup>(20)</sup>

#### **Amount of anterior open bite correction**

In the present CBCT study, there was a significant amount of open bite correction in both groups treated with RMI and PBP of 2.82 mm and 2.02 mm respectively. These findings agree with Mhd Albogha<sup>(2)</sup> who obtained correction of AOB by  $3.8\pm 1.9$  using RMI and  $3.6\pm 1.6$  using MMB in growing individuals, but did not agree with Alev Cinsar<sup>(25)</sup> who obtained an average 4.6 mm reduction of AOB using RMI plus fixed appliance in growing individuals and those of Firouz et al<sup>(25)</sup> and Tamami Shino et al<sup>(20)</sup>, who obtained a mean of 4.6 and 5.5 mm correction of AOB in growing individuals, using high-pull headgear and skeletal anchorage intrusion, respectively.

There was no statistically significant difference between RMI group and PBP group regarding

the percentage of reduction between pre and post intrusion regarding the distance between the mesio-buccal cusp tip of upper and lower first molars and Frankfort horizontal plane and mandibular plane respectively.

Concerning the change in ANB angle in both groups there was no statistically significant difference.

On the other hand, the change in the angle between the Frankfort and mandibular plane was highly significant in the RMI group than the PBP group.

## CONCLUSIONS

On the basis of the current results and with the limitations of the present study, the following conclusions could be drawn:

1. Both Rapid molar intruder (RMI) and posterior bite plane (PBP) are efficient solutions regarding open bite correction.
2. Both appliances are efficient for producing upper and lower molar intrusion.
3. Both appliances produce good skeletal and dental results.
4. There was a statically significant difference in skeletal effect of RMI over posterior bite plane regarding the reduction of anterior openbite and mandibular plane angle.
5. RMI is more hygienic and comfortable for the patient than PBP.

## REFERENCES

1. Woodside D, Linder-Aronson S. Progressive increase in lower anterior face height and the use of posterior occlusal bite-block in its management. *Orthodontics: State of art, essence of the science* ed St Louis: Mosby Co. 1986;209.
2. Albogha MH, Takahashi I, Sawan MN. Early treatment of anterior open bite: Comparison of the vertical and horizontal morphological changes induced by magnetic bite-blocks and adjusted rapid molar intruders. *The Korean Journal of Orthodontics*. 2015;45(1):38-46.
3. Iscan HN, Sarisoy L. Comparison of the effects of passive posterior bite-blocks with different construction bites on the craniofacial and dentoalveolar structures. *American journal of orthodontics and dentofacial orthopedics*. 1997;112(2):171-8.
4. Shapiro PA. Stability of open bite treatment. *American journal of orthodontics and dentofacial orthopedics*. 2002;121(6):566-8.
5. Sugawara J, Baik UB, Umemori M, Takahashi I, Nagasaka H, Kawamura H, et al. Treatment and posttreatment dentoalveolar changes following intrusion of mandibular molars with application of a skeletal anchorage system (SAS) for open bite correction. *The International journal of adult orthodontics and orthognathic surgery*. 2002;17(4):243-53.
6. Sherwood KH, Burch JG, Thompson WJ. Closing anterior open bites by intruding molars with titanium miniplate anchorage. *American Journal of Orthodontics and Dentofacial Orthopedics*. 2002;122(6):593-600.
7. Carano A, Machata W, Siciliani G. Noncompliant treatment of skeletal open bite. *American journal of orthodontics and dentofacial orthopedics*. 2005;128(6):781-8.
8. Ross VA, Isaacson RJ, Germane N, Rubenstein LK. Influence of vertical growth pattern on faciolingual inclinations and treatment mechanics. *American Journal of Orthodontics and Dentofacial Orthopedics*. 1990;98(5):422-9.
9. Sankey WL, Buschang PH, English J, Owen III AH. Early treatment of vertical skeletal dysplasia: the hyperdivergent phenotype. *American Journal of Orthodontics and Dentofacial Orthopedics*. 2000;118(3):317-27.
10. Baccetti T, Franchi L, Schulz SO, McNamara Jr JA. Treatment timing for an orthopedic approach to patients with increased vertical dimension. *American Journal of Orthodontics and Dentofacial Orthopedics*. 2008;133(1):58-64.
11. Shetty KD, Soni VP. Skeletal open bite: A non surgical approach. A review of different techniques *Scientific J*. 2007.
12. Akay MC, Aras A, Günbay T, Akyalçın S, Koyuncue BÖ. Enhanced effect of combined treatment with corticotomy and skeletal anchorage in open bite correction. *Journal of oral and maxillofacial surgery*. 2009;67(3):563-9.
13. Prosterman B, Prosterman L, Fisher R, Gornitsky M. The use of implants for orthodontic correction of an open bite. *American Journal of Orthodontics and Dentofacial Orthopedics*. 1995;107(3):245-50.
14. Park Y-C, Lee S-Y, Kim D-H, Jee S-H. Intrusion of posterior teeth using mini-screw implants. *American journal of orthodontics and dentofacial orthopedics*. 2003; 123(6):690-4.

15. Erverdi N, Usumez S, Solak A. New generation open-bite treatment with zygomatic anchorage. *The Angle Orthodontist*. 2006;76(3):519-26.
16. Park Y-C, Lee H-A, Choi N-C, Kim D-H. Open bite correction by intrusion of posterior teeth with miniscrews. *The Angle Orthodontist*. 2008;78(4):699-710.
17. Seres L, Kocsis A. Closure of severe skeletal anterior open bite with zygomatic anchorage. *Journal of Craniofacial Surgery*. 2009;20(2):478-82.
18. Hart TR, Cousley RR, Fishman LS, Tallents RH. Dento-skeletal changes following mini-implant molar intrusion in anterior open bite patients. *The Angle Orthodontist*. 2015;85(6):941-8.
19. Hamdy M. Effect of mini-screw implant supported intrusion on mandibular rotation in a group of children: Master thesis, Faculty of Oral and Dental Medicine, Cairo University; 2009.
20. Shino T, Yatabe K, Yokoyama Y. Skeletal open bite corrective treatment using temporary skeletal anchorage devices of miniplates and miniscrews. *Orthodontic Waves*. 2016;75(3):76-82.
21. Tuncer C, Ataç MS, Tuncer BB, Kaan E. Osteotomy assisted maxillary posterior impaction with miniplate anchorage. *The Angle Orthodontist*. 2008;78(4):737-44.
22. Akay MC. Corticotomy and Miniplate Anchorage for Treating Severe Anterior Open-Bite: Current Clinical Applications. *A Textbook of Advanced Oral and Maxillofacial Surgery*: IntechOpen; 2013.
23. Leung MT-C, Lee TC-K, Rabie ABM, Wong RW-K. Use of miniscrews and miniplates in orthodontics. *Journal of Oral and Maxillofacial Surgery*. 2008;66(7):1461-6.
24. Park JH, Tai K, Takagi M. Open-bite treatment using maxillary and mandibular miniplates. *Journal of clinical orthodontics: JCO*. 2015;49(6):398-408.
25. Ng J, Major PW, Flores-Mir C. True molar intrusion attained during orthodontic treatment: a systematic review. *American journal of orthodontics and dentofacial orthopedics*. 2006;130(6):709-14.