

## Pudendal Nerve Blockade Is Superior to Epidural Analgesia for Andrological and Surgical Procedures on the External Genitalia of Male Goats in the Standing Position

Mohammed Zayed<sup>1</sup>, Nasra Ahmed M. Yousef<sup>2</sup>, and Ahmed Saad A. Hassaneen<sup>2, 3\*</sup>

<sup>1</sup>Department of Surgery, Anesthesiology, and Radiology, Faculty of Veterinary Medicine, South Valley University, 83523, Qena, Egypt, <sup>2</sup>Department of Theriogenology, Obstetrics and Artificial Insemination, Faculty of Veterinary Medicine, South Valley University, 83523, Qena, Egypt. <sup>3</sup>Educational and Research Animal Farm, Faculty of Veterinary Medicine, South Valley University, 83523, Qena, Egypt.

### Abstract

The aim of the present study was to evaluate the efficacy of pudendal nerve block as an alternative procedure to epidural analgesia for penile relaxation in male goats. Five healthy male goats were subjected to pudendal nerve block and lumbosacral epidural analgesia with a two-weeks interval as a washing period. Bilateral pudendal nerve block was performed using 1% of lidocaine hydrochloride (HCl) by ischiorectal fossa approach. Lumbosacral epidural analgesia was performed using 1% of lidocaine HCl in the lumbosacral space. Nociception was investigated by pinprick. Time to the onset and duration of the anti-nociception effect in the perineal region were recorded. Area of desensitization and penile relaxation were observed. Incoordination, ataxia, and analgesic effects were carefully observed and recorded according to the scoring system before analgesic administration and at 5-, 15-, 30-, 60-, and 90-min after administration. Pulse rate, respiratory rate, and rectal temperature were recorded at 0-, 5-, 15-, 30-, 60-, and 90-min after administration. This study showed that both the pudendal nerve block and the epidural analgesia resulted in analgesic effects, however, the penile relaxation without manipulation was observed in 4 out of 5 male goats subjected to the pudendal nerve block. None of the male goats subjected to lumbosacral epidural analgesia showed penile relaxation, spontaneously. The time of onset was significantly earlier in the pudendal nerve block compared to the epidural analgesia. Moreover, the duration of action was significantly shorter in the pudendal nerve block compared to the epidural analgesia. Incoordination, ataxia, and recumbency were observed in 3 out of 5 male goats subjected to epidural analgesia. In conclusion, the pudendal nerve block is likely superior to the epidural analgesia for examination of the penis and surgical procedures on the male goat reproductive system in the standing position.

**Keywords:** Local analgesia, Male reproductive surgery, Penile relaxation, Small ruminants.

DOI: 10.21608/svu.2022.111977.1165 Received: December 19, 2021 Accepted: January 10, 2022

Published: April 3, 2022

\*Corresponding Author: Ahmed S. A. Hassaneen E-mail: ahmed.hassaneen@vet.svu.edu.eg

Citation: Zayed et al., Pudendal Nerve Blockade Is Superior to Epidural Analgesia for Andrological and Surgical Procedures on the External Genitalia of Male Goats in the Standing Position. SVU-IJVS 2022, 5(2): 1-10.

Copyright: © Zayed et al. This is an open access article distributed under the terms of the creative common attribution license, which permits unrestricted use, distribution and reproduction in any medium provided the original author and source are created.

Competing interest: The authors have declared that no competing interest exists.



## Introduction

Andrological and surgical procedures in the perineal and inguinal regions are of high clinical importance in male animals including small ruminants. The most common andrological procedures include examination and management of penile and preputial affections such as pizzle rot (ulcerative balanoposthitis), persistent penile frenulum, preputial abscess, and penile hematoma (Ladds, 2000; Rowe, 2014), while the common surgical procedures include castration (Nagamine and Sunagawa, 2017; Oguntoye and Olaifa, 2019; Yami, 2008), amputation of urethral process and surgical tube cystostomy for treatment of obstructive urolithiasis (Ewoldt et al., 2006; Frotier et al., 2004; Haven et al., 1993). Such procedures require desensitization of the area of intervention, and penile relaxation. For these purposes, several techniques have been reported in veterinary practice including general anaesthesia, epidural analgesia, administration of tranquilizers or sedatives (Alsobayil et al., 1999; Muir et al., 2000; Purohit, 1999). The ability to perform surgical and reproductive procedures in ruminants under local analgesia minimizes the risk of general anaesthesia (Skarda, 2007). Epidural analgesia is commonly applied in veterinary practice as a local technique of analgesia for the management of reproductive and surgical affections in small ruminants (Hassaneen, 2018; Hassaneen et al., 2020). Epidural analgesia provides complete desensitization for perineum procedures, however, some significant drawbacks had been previously reported including technical failure, contamination, and motor paralysis of the hind limbs resulting in ataxia, incoordination, and recumbency as well-known adverse effects (Day and Skarda, 1991, Hansen, 2001, Ismail, 2016). Furthermore, epidural analgesia is likely associated with increased risk of post-surgery urine retention (Peterson et al., 2014).

Regional analgesia has been developed for its simple technique, consistent anaesthetic effect, and high pain relief. Pudendal nerve block is an effective technique to anesthetize the anus, perineum, external genitalia, and penis in male goats (Fazili et al., 2016). The pudendal nerve supplies the perineum and external genitalia. Anatomical investigations on the course, and distribution of the pudendal nerve in goats have been previously described (El-Kammar, 2006). Exposure of the glans penis in male goat for examination is a frequent requirement in veterinary practice, particularly in cases of inability to fully protrude the penis for the treatment of injuries, infections and removal of neoplasms (Fazili et al., 2016).

The current study aimed to evaluate the anti-nociceptive effects of pudendal nerve block compared to epidural analgesia as an alternative safe method using 1% of lidocaine HCl, and to provide adequate desensitization and penile relaxation and protrusion in the standing position. For these purposes, this study investigated the time, and duration of analgesia, desensitized area, penile relaxation. In addition, the general health parameters; temperature, pulse rate, and respiratory rate were recorded.

## Materials and methods

### *Ethical approval:*

All procedures in the present study were performed and approved in accordance with the Ethics Committee of the Faculty of Veterinary Medicine, South Valley University, Qena, Egypt.

### *Animals and management:*

Five healthy male (Zaraibi X Egyptian Baladi) cross-bred goats weighing between 20 kg and 45 kg ( $29 \pm 9.6$  kg; mean  $\pm$ SD) and aged 12–24 months-old were used in this study. All animals were maintained at the

Educational and Research Animal Farm, Faculty of Veterinary Medicine, South Valley University throughout the experiment. Food and water were withdrawn on the morning of the experiments.

### ***Experimental preparation and procedure***

#### **Bilateral pudendal nerve block (n = 5):**

The pudendal nerve block was carried out as previously described (Fazili, 2016). In brief, the perineal area was scrubbed with povidone iodine (The Nile Co. for Pharmaceuticals and Chemical Industries). The male goats were subjected to bilateral pudendal nerve block using 1% lidocaine hydrochloride 1 mL/10 Kg of body weight (lidocaine HCl, 2% preparation diluted with equal volume of normal saline) (Sigma-Tec pharmaceutical Indust.) following the ischiorectal fossa technique (Fig. 1A). The lubricated gloved index finger was introduced into the rectum and directed laterally to palpate the slit-like lesser sacrosiatic foramen, (about 4 to 5 cm from the anus). 21-gauge needle was introduced percutaneously in the deepest depression of the ischiorectal fossa and guided by the index finger inserted inside the rectum to the sacrosiatic foramen for deposition of the local anesthetic and to ensure that the needle did not penetrate the rectal wall. The procedure was similarly repeated on the other side.

#### **Epidural analgesia (n = 5):**

For the epidural analgesia, the lumbosacral approach was performed as recently reported (Zayed et al., 2020). In brief, following the lumbosacral area aseptic preparation, local subcutaneous infiltration with 1 mL 1% lidocaine HCl was performed to prevent animal movement during injection. Sterile 18- gauge, 8 cm-long spinal needles (Braun Melsungen Co., Germany) was inserted into the epidural space at the interspace between the last lumbar and the sacrum after penetrating the

ligamentum flavum. Then, the needle was inserted at an angle of about 45° to the skin surface and guided anteriorly and ventrally to locate the site appropriately. Accurate siting of the needle into the extradural space was confirmed by the loss of resistance to the injection and absence of any fluid or blood on aspiration.

The washout period between treatments was fourteen days.

#### **Analgesia assessment**

Both anesthetic techniques were performed in conscious animals without sedation. Animal general health variables were recorded before treatment administration at baseline at 0 min and at 5, 15, 30, 60, and 90 min after treatment. The health variables were measured, at the same time points, while the male goats are standing including pulse rate, respiratory rate (as the number of chest movements per minute), and body temperature.

Analgesic and sedative effects were evaluated by assessment scores (Table 1). The onset (min; mean  $\pm$  SD) and duration of analgesia (min; mean  $\pm$  SD), and sedative effects were recorded. The onset of analgesia was considered the time from the administration time of the anesthetic drug to loss of the sensation. Time from loss and reappearance of the sensation (determined by positive response to the nociceptive stimuli). Sensory blockade was evaluated bilaterally using a 23 G hypodermic needle inserted into the skin (pin prick) at the perineal area, inguinal region, external genitalia and proceeding cranially to the lumbar region. Analgesia was considered satisfactory when the goat did not respond to needle pricks in all the surveyed regions. The goats were evaluated for motor blockade or the presence of ataxia when stimulated to walk.

**Table 1. Assessment scores during the antinociceptive effect of pudendal nerve block or epidural analgesia.**

| Parameters                          | Scores   |
|-------------------------------------|--|
| <b>Incoordination of hind limbs</b> | 0 No incoordination<br>1 Slight incoordination of hind quarters<br>2 Moderate incoordination but able to walk without support<br>3 Severe incoordination and unable to stand without support |
| <b>Posture</b>                      | 0 Normal standing<br>1 Standing with mild hind quarter weakness<br>2 Being able to stand with severe hind quarter weakness<br>3 Recumbency.  |
| <b>Loss of sensation</b>            | 0 Strong response<br>1 Moderate<br>2 Very weak<br>3 Abolished  |
| <b>Area of desensitization</b>      | 0 Nil<br>1 Perineum<br>2 Udder<br>3 Hind legs<br>4 Flank   |

### Statistical analysis

All results were expressed as means  $\pm$  standard deviation (SD). Data were analyzed statistically using t test using SPSS 25.0 (IBM, Armonk, NY). P-values less than 0.05 were considered statistically significant. \* $P < 0.05$ , and \*\*\*  $P < 0.001$ .

### Results

#### ***Analgesic and sedative effects following pudendal nerve block:***

Pudendal nerve block in male goats resulted in complete desensitization of the perineal region, testis and scrotum (Fig. 1B), and relaxation of retractor penis muscle was observed as indicated by relaxation and protrusion of the penis from prepuce (occurred in 4 out of 5 treated male goats) (Fig. 1C, 1D). Only one animal could not protrude its penis, however its preputial ring was relaxed. Blocking of deep and superficial pudendal were recognized through complete desensitization of perineal and inguinal regions using pin prick test. Analgesia of the area from anus to scrotum in male was also obtained by blocking superficial perineal branch of

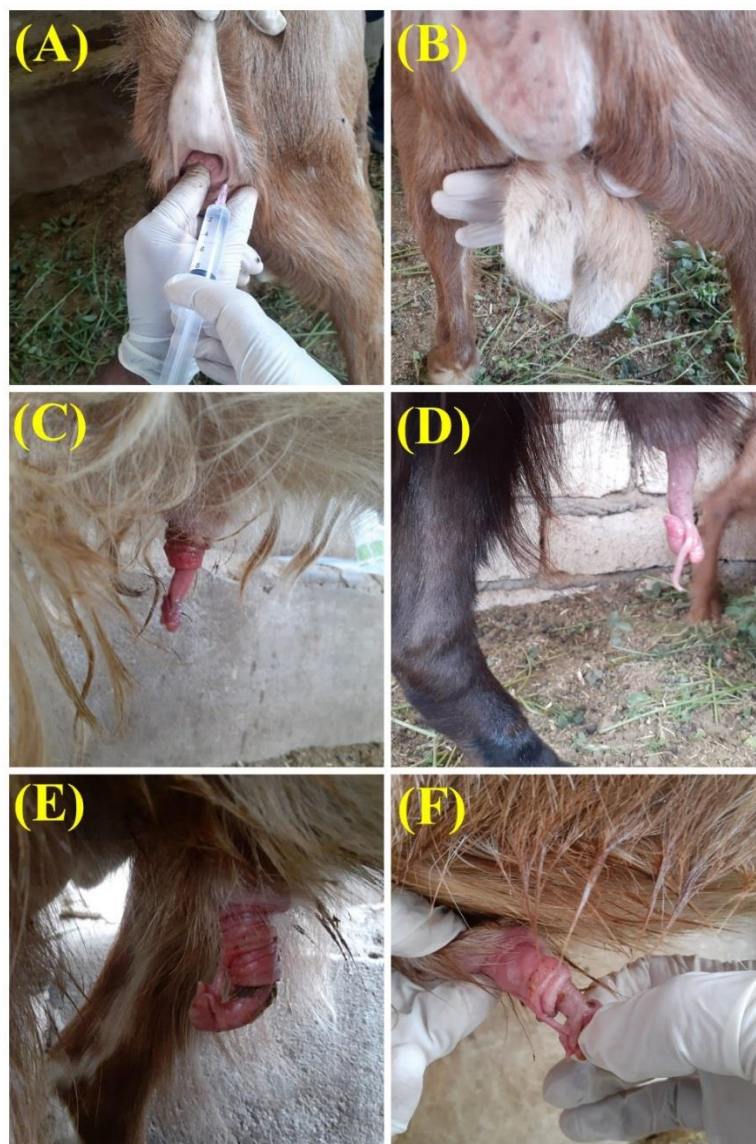pudendal nerve which emerges at both sides of anus. No reaction was observed by manual manipulation of the glans penis or urethral process of the prolapsed penis in all treated male goats (Fig. 1E, 1F), this confirm that protrusion of the penis and urethral process was accompanied with complete loss of sensation. The duration time of exposure of the prolapsed penis along with complete desensitization was continued for about 20-25 min, however, mild manipulation of the penis after its retraction resulted in its re-protrusion. Two male goats showed longer duration of penile relaxation for about 40-50 min. A persistent penile frenulum was detected in one of the treated male goats as a common congenital affection of the male goat genital system (Fig. 1E, 1F).

None of the treated male goats showed any signs of motor block (incoordination, ataxia, or recumbency) during the whole observation period after the pudendal nerve block.

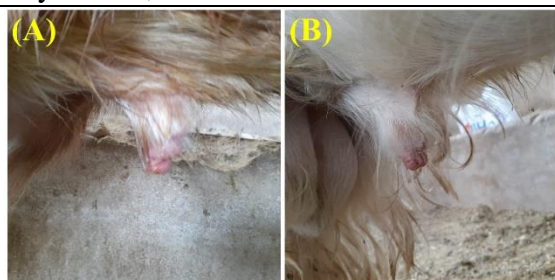#### ***Analgesic and sedative effects following epidural analgesia:***

Epidural analgesia using the lumbosacral approach resulted in a complete desensitization of perineal area and inguinal region. Analgesia of the scrotum was maintained. None of the male goats subjected to epidural analgesia showed prolapse of the penis throughout the observation period even with preputial manipulation. However, 3 out of 5 of the

treated animals showed relaxation and prolapse of the preputial orifice (Fig. 2A, 2B). Motor blockade, incoordination and associated ataxia were observed in all animals with varying degree. Moreover, one treated male goat showed recumbency due to paralysis of the hind limbs after epidural analgesia.



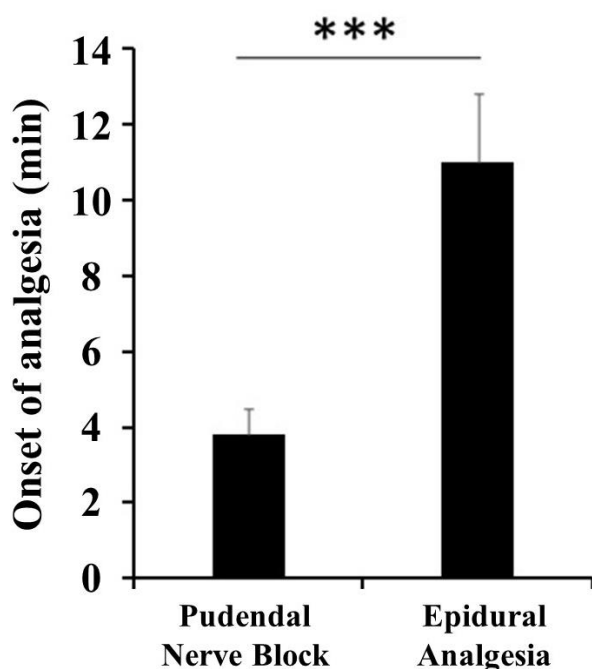
**Fig. 1. Pudendal nerve block in male goats.** Representative images are showing the ischiorectal fossa approach; where the gloved lubricated left index finger is inserted in the rectum to guide the needle to the slit-like sacrosciatic foramen (A), thorough andrological examination of the desensitized external genitalia (B), completely relaxed and protruded penis (C), completely relaxed penis showing the glans penis and the urethral process (D), and persistent penile frenulum as a congenital male genital system abnormality of the penis and prepuce (E, F).



**Fig. 2. Epidural analgesia in male goats.** Representative images are showing relaxed preputial rings after epidural analgesia (A, B).

#### Onset of analgesia (min):

The pudendal nerve block showed a highly significant earlier onset of analgesia compared to the epidural analgesia (Fig. 3). The onset of analgesia after pudendal nerve block (means  $\pm$  SD) was  $3.8 \pm 0.7$  min, while after epidural analgesia, it was  $11.0 \pm 1.8$  (Fig. 3).



**Fig. 3. Onset of analgesia (mean  $\pm$  SD) in male goats subjected to pudendal nerve block (n = 5) or epidural analgesia (n = 5). \*\*\*P < 0.001 (t- test).**

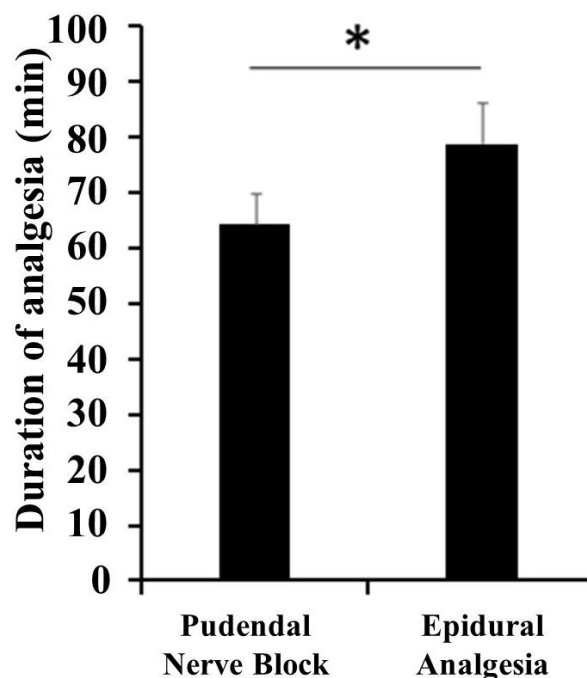
#### Duration of analgesia (min):

The pudendal nerve block showed a significant shorter duration of analgesia compared to the epidural analgesia (Fig. 4). The duration of analgesia after pudendal nerve block (means  $\pm$  SD) was  $64.2 \pm 5.5$  min, while after epidural analgesia, it was  $78.0 \pm 7.3$  (Fig. 4).

#### Effect of pudendal nerve block and epidural analgesia on health parameters:

Both pulse rate and respiratory rate remained within the normal physiological limits in all treated animals following either pudendal nerve block or epidural analgesia.

Body temperature was within the normal physiological limits in all treated animals following epidural analgesia, however, male goats treated with pudendal nerve block showed slight transient rise in body temperature ( $0.8 \pm 0.1$  °C) for about 20-30 min.



**Fig. 4. Duration of analgesia (mean  $\pm$  SD) in male goats subjected to pudendal nerve block (n = 5) or epidural analgesia (n = 5). \*P < 0.05 (t- test).**

## Discussion

The present study evaluated the anti-nociceptive effects of pudendal nerve block compared to epidural analgesia. In the current study, the pudendal nerve block provided proper analgesia for andrological and surgical procedures on the male goat external genital system in the standing position. On the other hand, epidural analgesia showed signs of incoordination, ataxia, and even recumbency without protrusion or prolapse of the penis. Therefore, pudendal nerve block could be a peripheral alternative to epidural analgesia with superior anti-nociceptive effect without motor blockade side effects on the hindlimbs.

The ischiorectal approach used in this study for the pudendal nerve block is more safe than the blind ischial arch approach, that the index-finger guided technique avoid the other approach potential complications such as puncture or penetration of the rectum, puncture of the blood vessels, or formation of hematoma (Gallacher et al., 2016).

The present study revealed significantly earlier onset and significantly shorter duration of analgesia in the pudendal nerve block compared to the epidural analgesia. In addition, the appropriate protrusion of the penis for less than half an hour and the possibility of its re-protrusion after gentle manipulation reported in this study is more suitable for both andrological examination and surgical intervention. In addition, the current study revealed motor blockade in the hindlimbs of the male goats subjected to epidural analgesia. This finding is supported by the

recently reported finding that hind limb incoordination has been observed during lumbosacral epidural analgesia in goats (Zayed et al., 2020).

In the present study, analgesic effects including the penis and male external genitalia in pudendal nerve block indicating that pudendal nerve block could be clinically superior than epidural analgesia to provide rapid onset, appropriate duration and safe analgesia and desensitization of the perineal region and inguinal region in male goats in the standing position. Increasing the dose of local anesthetic to ensure adequate desensitization of the penis and external genitalia in case of epidural analgesia would likely result in recumbency with risk of injury and contamination of the prolapsed penis and hinder the performance of surgical procedures (Clarke, 2014).

From the pharmacological point of view, although, lidocaine HCl 2% is the most commonly used local anesthetic (Marongiu, 2012), the use of 1% instead of 2% lidocaine HCl is more safe in goats (Clarke, 2014). In the present study, 1% lidocaine HCl was administered to avoid the systemic toxic effect. It is well-known that, the local analgesic drug may reach higher or lesser degree to brain and/or heart producing physiological alterations in these organs. The maximum dose should not be exceeded to avoid the undesirable effects, known as systemic toxicity of the local analgesic. Such local analgesic-produced toxicity should be avoided (Grubb and Lobprise, 2020).

## Conclusion

The present study concluded that the pudendal nerve block through the

ischiorectal fossa approach is superior to the epidural analgesia for andrological examination and surgical procedures on the penis and male goat genitalia. Pudendal nerve block could induce earlier onset, satisfactory protrusion of the male goats' penis without manual manipulation in the standing position. Moreover, the lower concentration of the lidocaine HCl (1%) is more beneficial to avoid the major disadvantage of the prolonged penile relaxation, risk of recumbency, and the chances of local analgesic drug toxicity.

#### **Conflict of interest statement**

The authors declare that they have no conflict of interest.

#### **Financial support**

This work was supported financially by the Faculty of Veterinary Medicine, South Valley University, Qena, Egypt.

#### **Acknowledgement**

The authors would like to appreciate thanks to the veterinary assistants, workers, and staff members the Educational and Research Animal Farm, Faculty of Veterinary Medicine, South Valley University.

#### **References**

- Alsobayil FA MK (1999). Anesthetic Management of Dromedary Camels. *Compendium on Continuing Education for The Practicing Veterinarian*, 3: S102– S111.
- Clarke KW, Trim CM, Hall LW (2014). *Veterinary Anaesthesia*, London: Saunders Elsevier, England.

Day TK, Skarda RT (1991). The Pharmacology of Local Anesthetics. *Veterinary Clinincal North American Equine Practice*, 7: 489-500.

El-Kammar MAA MA (2006). Pudendal Nerve Blockage: Surgical and Topographical Anatomical Study in Goat. *Kafr El-Shiekh Veterinary Medicine Journal*, 4.

Ewoldt JM, Anderson DE, Miesner MD, Saville WJ (2006). Short- and Long-Term Outcome and Factors Predicting Survival After Surgical Tube Cystostomy for Treatment of Obstructive Urolithiasis in Small Ruminants. *Veterinary Surgery*, 35: 417-422.

Fazili MR, Handoo N, Mir MY, Qureshi B (2016). Pudendal Nerve Block in Male Goats: Comparison of Ischiorectal Fossa and Ischial Arch Approaches Using Low Volume 1% Lignocaine Hydrochloride. *Macedonian Veterinary Review*, 39: 111-115.

Fortier LA, Gregg AJ, Erb HN, Fubini SL (2004). Caprine Obstructive Urolithiasis: Requirement for 2nd Surgical Intervention and Mortality After Percutaneous Tube Cystostomy, Surgical Tube Cystostomy, or Urinary Bladder Marsupialization. *Veterinary Surgery*, 33: 661-7.

Gallacher K, Santos LC, Campoy L, Bezuidenhout AJ, Gilbert RO (2016). Development of a Peripheral Nerve Stimulator-Guided Technique for Equine Pudendal



- Nerve Blockade. *Veterinary Journal*, 217: 72-77.
- Grubb T, Lobprise H (2020). Local and regional Anaesthesia in Dogs and Cats: Overview of Concepts and Drugs (Part 1). *Veterinary Medicine and Science*, 6: 209-217.
- Hansen BD (2001). Epidural Catheter Analgesia in Dogs and Cats: Technique and Review of 182 Cases (1991-1999). *Journal of Veterinary Emergency and Critical Care*, 11: 95-103.
- Hassaneen A (2018). Complete Cervico-vaginal Prolapse (CVP) in a Ewe. *SVU-International Journal of Veterinary Sciences*, 1: 50-59.
- Hassaneen ASA, Azab AA, Fouad IF, Noby MA, Mawas AS, Yousef NA (2020). Arthrogyposis Multiplex Congentia and Fetal Mummification in Sheep with Hydrops of Fetal Membranes. *Advances in Animal and Veterinary Sciences*, 8: 848-852.
- Haven ML, Bowman KF, Engelbert TA, Blikslager AT (1993). Surgical Management of Urolithiasis in Small Ruminants. *Cornell Veterinry*, 83: 47-55.
- Ismail ZB (2016). Epidural Analgesia in Sheep and Goats: A Review of Recent Literature. *Bulletin UASVM Veterinary Medicine* 2.
- Ladds P (2000). Comparative Pathology of the Genitalia of the Bull, Ram and Buck. XXI World Buiatrics Congress, 761-763.
- Larson LL (1953). The Internal Pudendal (Pudic) Nerve Block for Anesthesia of the Penis and Relaxation of the Retractor Penis Muscle. *Journal American Veterinary Medicine Association*, 123: 18-27.
- Marongiu ML (2012). Local Anesthesia for Husbandry Procedures and Experimental Purposes in Farm Animals. In: PEREZ-MARIN, C. C. (ed.) *A Bird's-Eye View of Veterinary Medicine*. IntechOpen.
- Muir WW, Skarda RT, Bednarski RM (2000.) *Handbook of Veterinary Anesthesia*, Mosby, Philadelphia.
- Nagamine I, Sunagawa K (2017). Effects of the Castration on the Growth, Meat Production and Odors in Male Goats. *Animal Behaviour and Management*, 53: 137-150.
- Olaifa AK, Oguntoye CO (2019). Effects of Castration on Epidural Administration of Lidocaine-Tramadol in West African Dwarf (Wad) Goats. *Nigerian Journal of Physiological Sciences*, 34: 141-147.
- Peterson NW, Buote NJ, Bergman P (2014). Effect of Epidural Analgesia with Opioids on the Prevalence of Urinary Retention in Dogs Undergoing Surgery for Cranial Cruciate Ligament Rupture. *Journal of American Veterinary Medicine Association*, 244: 940-943.
- Purohit (1999). Anesthesia. In: WOLFE DF, M. H. (ed.) *Large Animal Urogenital Surgery*. 3rd Ed. ed. Philadelphia: Williams & Wilkins, .

Rowe J (2014). Buck management. American Association of Bovine Practitioners, 47: 91-94.

Skarda (2007). Local and Regional Anesthetics and Analgesic Techniques: Ruminants and Swine. In: Tranquilli WJ, T. J., Grimm KA, (ed.) Lumb & Jones' Veterinary Anesthesia and Analgesia. 4th ed.: Blackwell.

Yami (2008). Castration of sheep and goats. Technical Bulletin (ESGPIP), 18.

Zayed M, Mahmoud E, Khalil A, Salah M, Moustafa M, Youssef M, Hassaneen A (2020). Lumbosacral Injection of Lidocaine, Detomidine and Lidocaine–detomidine in goats: Anti-nociceptive Effects and Changes on Haematobiochemical Parameters. Journal of Applied Animal Research, 48: 57-62.