

## IMMEDIATE IMPLANT PLACEMENT THROUGH INTER-RADICULAR BONE DRILLING BEFORE VERSUS AFTER ROOTS EXTRACTION IN MANDIBULAR MOLAR AREA (A RANDOMIZED CONTROLLED CLINICAL TRIAL)

Mohamed M. Shokry\* and Maha R. Taalab\*\*

### **ABSTRACT**

Placement of immediate implant in mandibular molar area is considered a great challenge, due to the difficulty of implant bed preparation in the presence of interradicular bone septa. Therefore, this study introduces a simple technique for implant bed preparation.

**Objectives:** This study aimed to compare clinically and radiographically the effect of performing two different surgical approaches for implant bed preparation.

**Materials and Methods:** A randomized, controlled clinical trial was conducted on twenty six adult patients equally divided between a study group; where an immediate implant was installed following an innovative drilling protocol through drilling in the inter-radicular bone preceding molar extraction and a control group; where an immediate implant was installed conventionally after molar extraction. Clinical evaluation included assessing implant stability quotient (ISQ) at base line and after 6 months. While radiographic evaluation was done through periapical X-ray and CBCT to assess the implant position and marginal bone loss around the installed implants at baseline and after 6 months.

**Results:** Clinical results revealed that there was no statistical significance difference in mean average ISQ between both groups at base line and after 6 months. Regarding the radiographic results the study group showed that the paralleling pin was more centrally oriented within the inter-radicular bone in comparison to control group. Concerning the marginal bone loss there was no statistical difference between the two groups.

**Conclusion:** The implant bed preparation before roots extraction allows optimal positioning and angulation of the immediate implant in mandibular molar area, thus enabling ideal future prosthesis.

\* Associate Professor of Oral & Maxillofacial Surgery, Oral & Maxillofacial Surgery Department Faculty of Dentistry, Alexandria University, Alexandria, Egypt.

\*\* Associate Professor at Oral Medicine, Periodontology, Oral Diagnosis and Oral Radiology department, Faculty of Dentistry, Alexandria University, Alexandria, Egypt.

## INTRODUCTION

Immediate implantation has significant benefits over the traditional delayed approach. It has less surgical procedures, reduces overall time for treatment and therefore costs less. It also helps to maintain the gingival architecture and to increase the comfort, acceptance and satisfaction of the patient<sup>(1-5)</sup>.

Studies concerning the evaluation of the immediate implant placement in the esthetic as well in the premolar region follow a firm surgical protocol to reach a proper three-dimensional position of the implant in addition to its primary stability and the condition of surrounded tissues<sup>(6-8)</sup>. Though, there is less knowledge on the immediate placement of implants in the posterior zone where the esthetic effect is lower but there is greater surgical difficulty in tooth extraction, drilling, and placement of implants<sup>(9-11)</sup>.

Because of the premature loss of molars, the posterior mandible is a common place for implant placement. Placing an implant in a multi-rooted tooth socket is never a simple procedure, because there is always a disparity between implant size and socket size. In addition, complications are caused by the inferior alveolar nerve's structural barriers, ridge malformations, and the softer bone quality. The diameter of the implant may be smaller than the diameter of the extraction socket, creating a gap between the installed implant and the socket wall<sup>(9,10)</sup>.

Despite the above-mentioned issue, the cumulative survival rates reported for immediate implants placed in molar sites are similar to those placed in healed sites, which ranges from 93.9% to 99%<sup>(4,8,10,11)</sup>. An essential aspect to achieve this positive outcome is the primary stabilization of the implant in the apical and/or lateral bone, where anatomic conditions can hinder this goal. Therefore, a thorough implant surgery planning, skills, and clinical experience are relevant factors in the success of the surgical procedure<sup>(4,12)</sup>.

Changes to current surgical techniques are recommended to promote accurate placement of implants in the posterior region. To stabilize the inter-radicular bone septa through the residual tooth roots, different authors recommend implant drilling prior to tooth extraction<sup>(13-15)</sup>. In 2017, a pilot study conducted on 22 patients compared the traditional technique of dental extraction, followed by inter-radicular bone drilling, and immediate implant placement to the technique of inter-radicular bone drilling by the aid of ultrasound devices. The tested new technique shows better statistical results when compared to the conventional one in terms of primary stability and implant position.<sup>(9)</sup>

The difficulty of the operation depends mainly on the morphology of the inter-radicular bone which has a great influence on the implant primary stability. Several efforts are made to make an osteotomy in the proper position in the inter-radicular septa, its anatomic configuration may lead to slippage of the implant drill resulting in an improper implant position. In this current study, immediate implant placement in the lower molar region is performed and evaluated using an innovative and simple technique.

In light of the above information and since implant bed preparation is a critical step for the success of the future ideal prosthesis in the mandibular molar region, the aim of this work was to compare the effect of performing two different surgical approaches for implant bed preparation on implant stability quotient (ISQ), position of the implant and marginal bone loss around the installed implants.

## MATERIALS AND METHODS

### Study design

A six months randomized controlled clinical trial study was carried out at the Oral and Maxillofacial Surgery clinics of Faculty of Dentistry, Alexandria University between May 2021 and November 2021.

Ethical approval was obtained from the Research Ethics Committee at the Faculty of Dentistry, Alexandria University, Egypt (2019H-0067-D-R-0331) The objective of the study and the methods used in it were described to the patients and the complications and the risks that might arise intra or postoperatively were explained to them and they are requested to sign an informed consent. The study was performed in accordance with the Helsinki declaration of 1975, as revised in 2013.

### Participants

Twenty-five to fifty years old patients of both genders were included in the study if they are seeking extraction of non-restorable mandibular molar and indicated for immediate implant placement, only mandibular molars with wide bony septa were selected. Also, the surgical site and tooth indicated for extraction must be free from any clinical or radiographic signs of acute infection, draining fistula or pus exudate, moreover, absence of fenestrations or dehiscence in the buccal socket wall and adequate amount of attached gingiva. Mandibular molars with thin or tilted bony septa were excluded from the study. The selected patients were excluded if they are smokers, receiving bisphosphonates or under chemo/and or radiotherapy to the orofacial region or having any systemic diseases that may jeopardize the implant surgery. More over pregnant females were also excluded.

### Sample size estimation

Sample size was estimated using epitools.org software with the aid of a similar study performed by Scarano (9). The sample size yielded a total number of 24 participants. An extra 2 participants were added to the total sample size in order to compensate the attrition of the sample that might occur throughout the follow up period. Therefore, twenty-six patients were selected conveniently according to some eligibility criteria to participate in this study. The collected sample was thereafter divided randomly

into two equal groups each consist of 13 patients using a computer-generated randomization table through randomizer.org website.

*Group I:* Study group; an immediate implant was installed following an innovative drilling protocol through drilling in the inter-radicular bone preceding molar extraction.

*Group II:* Control group; an immediate implant was installed conventionally after molar extraction.

### Pre-surgical phase

A through intraoral examination was performed for every patient, impressions were taken and study casts were poured and mounted on a semi-adjustable articulator. Cone beam computerized tomography (CBCT) were done to be used for the preoperative 3D analysis of the surgical site and for the proper selection of the appropriate implant size (**Figure 1**). Based on the previous gathered information, diagnostic waxing ups were fabricated and surgical templates were obtained. Amoxicillin antibiotic with clavulanic acid 1 g bid for 7 days (Augmentin GlaxoSmithKline UK) were prescribed to the patients and to be started one day before the surgery.

### Surgical Phase

The surgical procedures were performed under complete aseptic conditions by the same surgeon. Swabbing of the operative field with betadine was done before the initiation of the surgery. Local anesthesia was administrated through infiltration technique using articaine 4% with adrenaline as a vasoconstrictor 1:100,000 (Primacaine, Pierre Rolland, Bordeaux, France) in the vestibular and lingual sulci.

For both groups, a full thickness envelope mucoperiosteal flap was performed including one tooth mesial and one distal to the operation site using bard parker handle # 3 and blade # 15. The flap was then reflected by the aid of molt # 9 mucoperiosteal flap elevator.

Non-restorable teeth with a remaining crown part, were decoronated at the gingival margin level and the roots were separated by the aid of a cylindrical diamond bur (AV-010, Beavers Dental, Kerr Corp) mounted on a high-speed turbine. On the other hand, in case of teeth presented with remaining roots only without the coronal part the surgery was started without the previous step.

For the study group, the drilling sequence as recommended by the manufacturer was done through the furcation area between the two roots, always verifying the drilling angulation with a paralleling pin (Figure 2a, 2b). After the drilling sequence was finished, the remaining roots were carefully extract-

ed by the aid of curved periostomes (Hu-Friedy Mfg. Co., LLC). This step was done with great care in order to preserve the alveolar bone walls and prevent any bone deformation along the path of the drilling.

The osteotomy site was then carefully inspected, curetted for any remaining granulation tissues and washed surgically using sterile saline solution, then a (3i zimmer biomet implant, USA) was inserted in the center of the interradicular bone, in a type A or B position according to Tarnow classification (16) (Figure 2c). The shoulder of the implant is placed slightly (2 mm) apical to the buccal alveolar crest to compensate for expected crestal bone remodeling, and any peri-implant defects grafted appropriately.

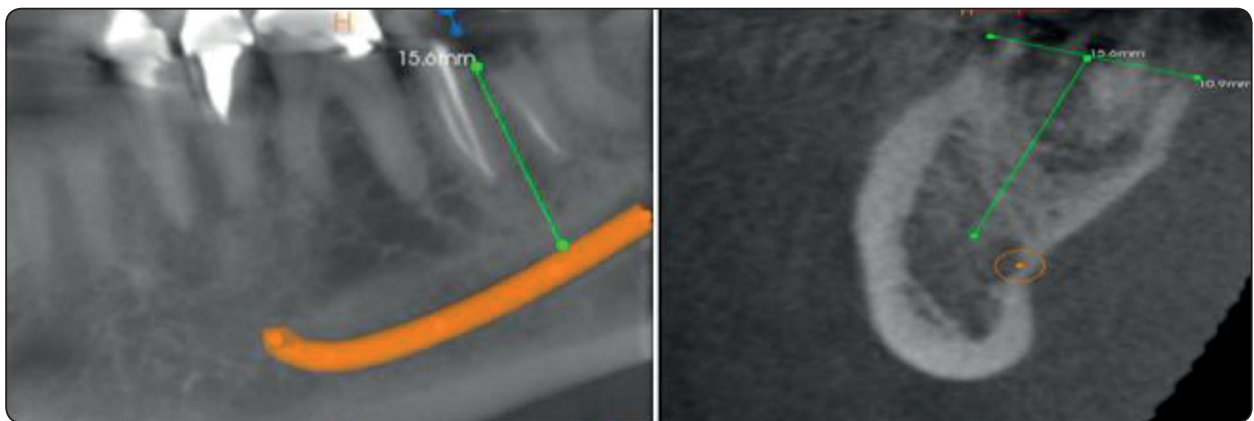


Fig. (1) Preoperative CBCT showing a non-restorable mandibular second molar indicated for immediate implants (study group)

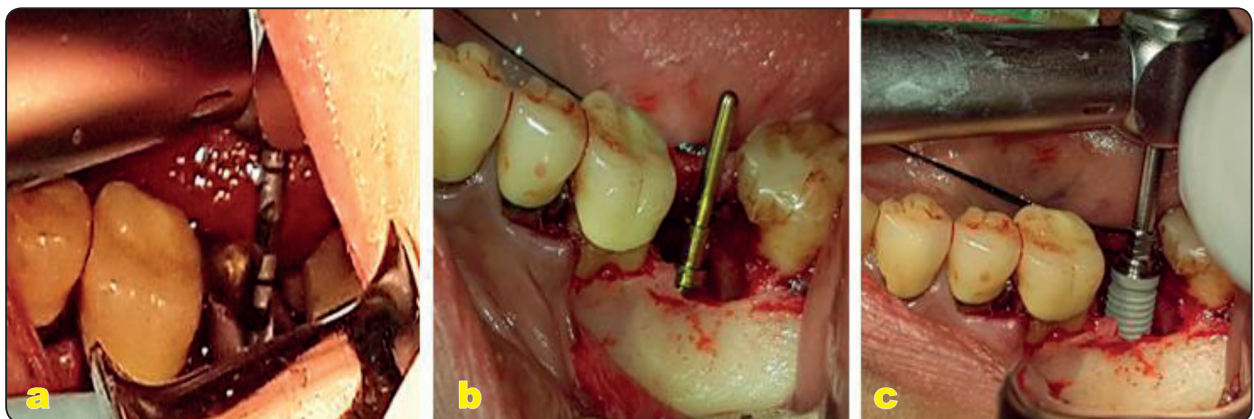


Fig. (2): a- Twist drill placed in the furcation area. b- Paralleling pin in place in the furcation area between the two roots with proper orientation. c- Insertion of the implant in the osteotomy site after roots removal.

On the other hand, for the control group, a conventional protocol for immediate molar placement was performed. After decoronation of the tooth, the remaining roots were sectioned and removed separately and atraumatically using periostomes.

After effectively removing all the roots, the bony socket walls were checked to verify the existence of four intact outer walls and the lack of any pathology or fenestration. Preparation of the interradicular bone was then initiated. A round bur was positioned onto the inter-radicular septum. The sequential drills were always inserted slightly off-center towards the lingual aspect; this helps in centralization of the implant position away from the buccal plate of bone.

Once the implant bed was complete, a paralleling pin is inserted within the osteotomy site to act as a profile gauge. A digital periapical radiograph was then taken to verify the position and depth of the osteotomy preparation and to check if the osteotomy was centralized within the bony septum or had slipped in the distal or mesial root. As in study group, to compensate for natural bone resorption after tooth removal, the osteotomy must allow the implant to sit 2 mm below the margin of the intact buccal bony wall.

In all cases within both groups, the implant was primarily seated with the implant surgical unit at 35-45 Ncm and then finally seated by hand implant insertion wrench driver until the implant platform reaches 2 mm subcrestally. Following the later step, the primary stability was measured by the Osstell® device (Integration Diagnostics AB, Göteborg, Sweden).

Thereafter, in both groups when the residual socket space (jumping gap) was more than 2 mm wide, a bovine derived xenograft was packed around the installed implants (Bio-Oss®, Geistlich, Wolhusen, Switzerland); and covered with collagen membrane (OsseoGuard®, Zimmer Biomet, USA) that stabilized in place by making a hole in it through which the cover screw of the implant pass and screwed to the implant (**Figure 3**).

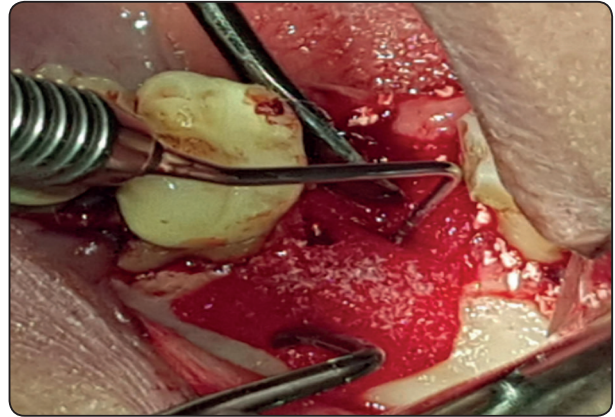


Fig. (3): Bone graft and collagen membrane secured in place over the installed implant

The flap was then repositioned after apical periosteal releasing incision to reach a proper primary soft tissue closure free of tension and sutured with Vicryl 4.0 sutures (Ethicon Coated VICRYL, USA) and a post-operative periapical radiograph was taken with a parallel-aiming device.

After implant surgery, all patients continue the preoperative prescribed of antibiotics (2x Amoxicillin 1000 mg / day for 7 days) and analgesics (3x Ibuprofen 600 mg / day for 3 days) and 0.125 % chlorhexidine gluconate mouthwash (Hexitol, Arab Borg Company, Cairo-Egypt).

The second stage surgery started 5-6 months later through installation of the healing abutment then final abutment and finally a single metal-ceramic crown was delivered for the patients.

### Follow up phase

Both the Clinical and radiographic evaluations were performed immediately postoperative and after 6 months at the second surgery after abutment placement to check implant stability quotient (ISQ), position of the implant and marginal bone loss around the installed implants.

### Clinical evaluation

The clinical evaluation included checking wound healing and the presence or absence of infection at

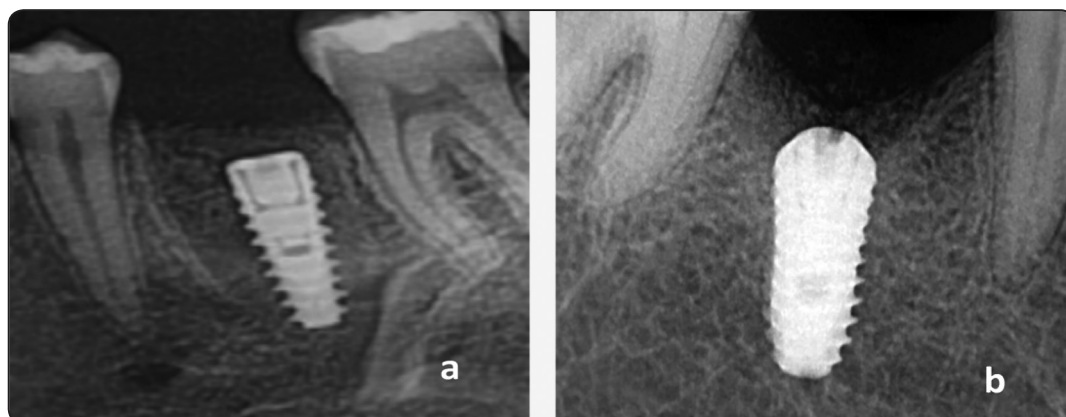


Fig. (4): Post-operative digital periapical x-rays a- Study group, with immediate molar implant well centralized within the root's sockets. b- Control group with the implant slightly deviated from the center of the extraction socket.

10th day post-surgically and measuring the implant stability through taking the ISQ by the Osstell® device. A special Smart peg was inserted into the implant fixture immediately following implant placement for resonance frequency analysis. The analyzer probe was located closer to the Smart peg from both buccal and lingual directions, and the Osstell® device obtained the ISQ value. This ISQ value was taken as a baseline measurement after implant placement then after 6 months.

### Radiographic evaluation

Radiographic evaluation was performed through doing immediate postoperative periapical x-ray to check the proper position of the dental implant whether centrally located in the inter-radicular bone or deviated mesial or distal (**Figure 4 a, b**). Moreover marginal bone loss was measured buccal and lingual to the placed implant through measuring the distance from the bone crest to most apical part of the implant at base line and 6 months after surgery at time of final crown placement using standardized CBCT cross-sectional cut (Carestream kodak 9300). (**Figure 5a, b**)

## RESULTS

Data were fed to the computer and analyzed using IBM SPSS software package version 24.0. (Armonk, NY: IBM Corp). Qualitative data were

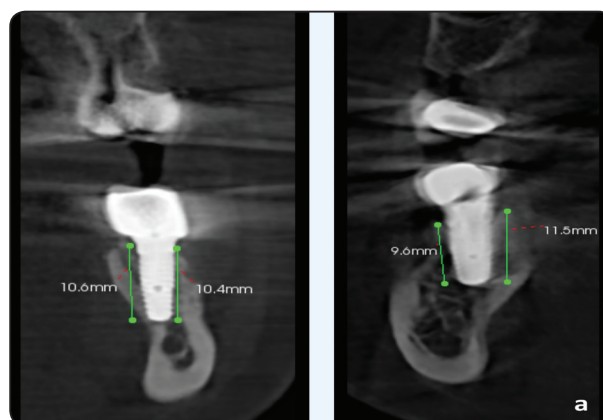


Fig. (5) Standardized Cross-sectional view of the CBCT showing marginal bone loss measurements after 6 months in test group (a) and in control group (b).

described using numbers and percentages. The Kolmogorov-Smirnov test was used to verify the normality of distribution Quantitative data were described using range (minimum and maximum), mean, standard deviation and median. Significance of the obtained results was judged at the 5% level. Wilcoxon signed ranks test was used for abnormally distributed quantitative variables, to compare between two periods.

### Demographic Characteristics

The selected twenty-six participants were allocated randomly into two equal groups; study group and control group each consisted of thirteen

patients. The study group included 8 females and 5 males, their age ranged from 25 to 45 years with a mean of  $(33.83 \pm 6.22)$  years, while the control group included 7 females and 6 males, their age ranged between 26 to 40 years with a mean of  $(34.17 \pm 5.51)$  years).

### Clinical results

Upon clinical evaluation, by 10<sup>th</sup> postoperative day, the flap condition and the overlying mucosa following the implant placement in all the cases within both groups showed eventual healing with absence of any signs of infection or flap dehiscence (**Figure 6**).

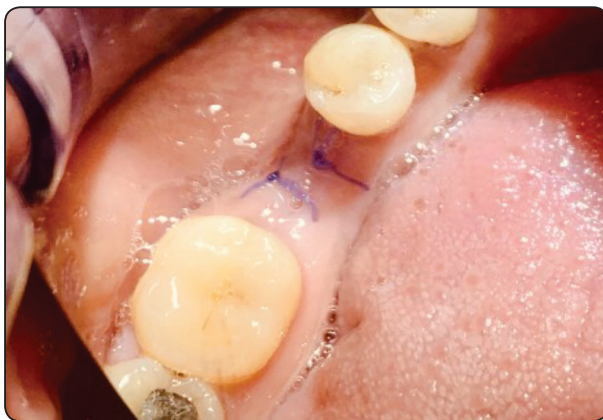

Fig. (6): Ten days post-operative clinical photograph showing proper healing.

### Implant stability

The primary implant stability was checked using the Osstell® device (Gothenburg, Sweden) in two intervals: first immediately after implant placement before screwing the cover screw and the second one after 6 months during the second stage surgery before the initiation of the fabrication of the fixed prosthesis. (Table 1)

There was no statistical significance difference in mean ISQ between both groups ( $P=0.392$ ) immediately postoperative. The immediate mean of ISQ for the study group was  $62.43 \pm 7.4$  with minimum value of 51 and maximum value of 71. Whereas, it recorded a mean value of  $58.3 \pm 8.43$  with minimum value of 44 and maximum value of 69 for the control group.

After 6 months the mean average ISQ within the study group was  $71.88 \pm 4.12$  with a minimum value of 61 and a maximum value of 77. Whereas it recorded a mean value of  $64 \pm 5.88$  with minimum value of 57 and maximum value of 73 within the control group. By comparing both mean values for the two groups, it showed no statistical significance between both groups ( $P=0.057$ ).

TABLE (1): Comparison between the two groups regarding implant stability(ISQ).

Interval	Study	Control	Test of sign.	P value
Time of implant placement				
Min - Max	71 - 51	69 - 44	t= 0.866	0.392
Mean $\pm$ SD	7.4 $\pm$ 62.43	8.43 $\pm$ 58.3		
Median	60	59		
After 6 months				
Min - Max	77 - 61	73 - 57	t= 1.843	0.057
Mean $\pm$ SD	4.12 $\pm$ 71.88	5.88 $\pm$ 64		
Median	72	68		

## Radiographic results

### Implant position

In the study group, the standardized periapical radiographs taken after completion of the osteotomy showed that the paralleling pin was centrally oriented within the inter-radicular bone. All implants were ideally placed within the root extraction sockets. In contrast, once the osteotomy was completed on the control side, only one implant was placed in the central portion of the interradicular bone, while the remaining 12 implants were placed mesially or distally in relation to the septum with a tilted axis.

### Marginal bone loss

Marginal bone loss was measured buccal and lingual to the placed implant by measuring the distance from the bone crest to most apical part of the implant at base line and 6 months after surgery before final crown placement using the CBCT cross-sectional cut. Table 2 shows that there was no statistical significance difference in mean marginal bone loss after 6 months between the two groups at  $P=0.057$  as the mean marginal bone loss for the study group was  $0.48 \pm 0.22$ , while for the control group it was  $0.60 \pm 0.16$ .

TABLE (2): Comparison between the two studied groups according to marginal bone loss.

Bone height (BH)	Study (n = 13)	Control (n = 13)	Test of Sig.	p
<b>Immediate post-operative</b>				
Min. – Max.	10.21 – 12.43	10.32 – 12.45	t=0.092	0.927
Mean ± SD.	11.33 ± 0.90	11.36 ± 0.84		
<b>After 6 months</b>				
Min. – Max.	9.35 – 11.98	9.78 – 11.86	t=0.236	0.815
Mean ± SD.	10.85 ± 1.01	10.76 ± 0.77		
<b>Change in BH after 6 months(marginal bone loss)</b>				
Mean ± SD.	0.48 ± 0.22	0.60 ± 0.16	U=47.50	0.057
Median (Min. – Max.)	0.45 (0.23 – 1.08)	0.63 (0.30 – 0.81)		
$t_0 (p_0)$	7.858* (<0.001*)	13.354* (<0.001*)		

SD: Standard deviation

t: Student t-test

$t_0$ : Paired t-test

U: Mann Whitney test

p: p value for comparing between the two studied groups

$p_0$ : p value for comparing between immediate post-operative and 6 months in each group

\*: Statistically significant at  $p \leq 0.05$



## DISCUSSION

Immediate insertion of dental implants in fresh sockets poses unique challenges for the implantologist that are usually not encountered when performing the conventional delayed implant placement protocol. As examples of these issues; the diameter of the extraction socket is usually larger than the size of the installed dental implant, presence of necrotic bone at the implant osteotomy site, implant position and angulations control difficulties, bony dehiscence / perforations that may occur during drilling prior to implant placement and finally difficulty in achieving appropriate primary stability.<sup>(17)</sup>

Furthermore, the initial osteotomy must be oriented towards the medial portion of the alveolus when engaging the extraction socket's inter-radicular septum. The drill could slip uninterruptedly, resulting in inaccurate site preparation and, ultimately, inadequate insertion of the implants which can complicate the prosthesis fabrication<sup>(3,17)</sup>.

Different treatment options are available for immediate implantation following extraction of a multirrooted tooth. Attempts are made to create an osteotomy centralized in the inter-radicular bone which allows placing the implant in a suitable prosthetic location, a favorable occlusal force distribution in addition to a better plaque control by the patients, however its morphology may cause the implant bur to vibrate down to a less ideal position within the extraction sockets<sup>(8,13,17)</sup>.

Bone to implant contact (BIC) together with Implant stability are the most significant indicators for a successful dental implant surgery<sup>(11)</sup>. Immediate implant placement following extraction of molar teeth affords a stimulating and fascinating problem due to its multiple root morphology. In the case of extraction and immediate placement of dental implants, it is important to maintain a proper alveolar bone dimensions, particularly that of the labial and lingual sides, to provide the optimal environment for boosting BIC and stability of the installed implants. Furthermore, in relation to inter-

arch space, esthetics, and occlusion, the role of the definitive restoration must be considered. Thus, minimal alveolar bone removal is necessary to provide an appropriate surgical site for successful dental implant placement<sup>(12)</sup>.

The post extraction immediate implant placement has a higher chance of changing the shape of the socket wall during extraction, resulting in a poor implant placement. As a result, cautious extraction with desmotomes or ultrasonic tools is recommended to avoid deformation of the interradicular bone, which could change the bone-drilling path and change the ultimate implant position<sup>(9)</sup>. In the current study we used the curved periostomes to achieve an atraumatic molar extraction either before or after drilling for implant placement.

For those reasons, some authors have tried using various techniques for preparing implant sites. Fugazzotto used a bur inserted at an acute angle in the inter-radicular bone. During drilling for osteotomy, the bur was then straightened. Successive burs were inserted at a less acute angle before final preparation for osteotomy was finalized<sup>(8)</sup>.

In this study a simple technique was used for implant bed preparation to overcome the drawbacks of post extraction immediate implant placement in mandibular molar area. The technique depends on decoronation of the non-restorable molar at the gingival margin level then the roots were separated by the aid of a cylindrical diamond bur followed by osteotomy formation with the usual drilling sequence, roots removal with curved curettes to allow atraumatic extraction that preserve the osteotomy bony walls then implant was placed. The retained roots act as a guide for the drilling procedure and so prevent any slippage for the drills which allows centralized precise implant position and angulation.

According to the researchers, this technique may be acceptable for non-expert doctors, making it easier to get a correct 3D implant position and primary insertion stability<sup>(13)</sup>. However, many studies revealed that in the traditional technique, the amount

of knowledge and experience are critical elements in the procedure's success<sup>(14,15)</sup>. Absence of acute infection, root integrity, and sufficient residual bone to allow an immediate implant approach are the main indications to do this treatment protocol<sup>(16,17)</sup>.

The increased hardness of the root, which may result in a longer drilling time and a higher risk of rising intrabony temperature and disrupting normal healing due to the remains of dental tissue from drilling, are some of the technique's limitations. Regarding this point, Davarpanah and Szmukler-Moncler<sup>(18)</sup> published a case report on 5 patients, and the results showed that dental waste did not appear to interfere with implant osseointegration. However, there was little scientific evidence on this point, so caution is advised, with a focus on thorough irrigation and surgical cleaning.

The effect of the current technique on implant stability, position and marginal bone loss was evaluated in comparison to the conventional post extraction implant bed preparation technique.

Although there was no statistical difference in ISQ values between the two groups at baseline and after 6 months, however the level of ISQ in the control group was less than in the study group at baseline and after 6 months; this result may be attributed to the major bone density buccally and lingually in the centrally placed implants in the study group, on the other hand, the control group's implants only contacted the mesial and distal surfaces of the bone-to-bone septum. The absence of statistically significant difference between both groups regarding the ISQ levels immediately and at 6 months follow up result was in disagreement with those of Scarano's<sup>(9)</sup> who showed significantly higher implant stability quotient values ( $p < 0.05$ ) as compared to the traditional technique of extraction and immediate implant. This may be attributed to the smaller sample size.

Regarding the implant position the periapical radiographs taken for implants in the study group after completion of the osteotomy showed that

the paralleling pin was centrally oriented within the inter-radicular bone. All implants were ideally placed within the root extraction sockets. In contrast, once the osteotomy was completed on the control side, only one implant was placed in the central portion of the interradicular bone, while the remaining 12 implants were placed mesially or distally in relation to the septum with a tilted axis. These results are in accordance to those reported by Rebele et al who performed a similar approach on two patients in which the implant site was prepared prior to molar extraction, the osteotomies were performed directly through the teeth's initially retained root complexes. After completion of the drilling protocol, the remaining root aspects were extracted, and the surgical steps were continued in the conventional manner. The authors reported that this technique allows for precise implant bed preparation, therefore allows enabling ideal implant position<sup>(13)</sup>.

For marginal bone loss, the results gathered from this study showed that there was no statistically significant difference in marginal bone loss between both groups at 6-month follow-up period. Lesser amount of bone loss was found at the study group, this could be justified by the centralized position of the implant within the socket however the insignificance could be due to the small sample size. The results were in disagreement with a study carried out by Fugazzotto (2008) who described the immediate mandibular molar implant in 341 cases and showed that there was a statistical difference between test and control group<sup>(8)</sup>.

Augmenting the jumping gaps surrounding the immediately placed implants is a critical step that may affect implant success therefore several bone grafts have been used for this purpose. A study was performed 2011 and the authors had used autogenous bone graft around fifteen implants and they failed before prosthetic phase<sup>(19)</sup> however, others used synthetic bone substitute  $\beta$ -Tricalcium phosphate with one implant failed after 4 weeks of implant placement<sup>(20)</sup>. Moreover, other studies

used bovine xenograft particles that was used in this study with 100% implant success which may be due to the low resorption rate of xenograft and so can preserve the surrounding bony walls and to minimize the possibility of implant failure <sup>(21,22,9)</sup>.

Several techniques have been reported in the literature for the coverage of the socket after immediate implant placement with simultaneous grafting of the jumping gap <sup>(23)</sup>. The non-resorbable polytetrafluoroethylene (PTFE) has been used to seal the socket after immediate implant placement by Hoffmann et al., (2008)<sup>(24,58)</sup>. The authors used the PTFE to cover the immediate implant and reported that it resulted into a significant regeneration of the socket however some cases had complications of membrane exposure and flap dehiscence. Other authors used resorbable collagen membrane and reported its success in socket coverage <sup>(19)</sup>.

In this clinical investigation guided bone regeneration procedure was used to fill the gap around the installed implants, which included bovine xenograft grafting and collagen membrane on top of the immediately placed implant in the extraction socket. This step is crucial to achieve a proper type of osseointegration and to increase the bone to implant contact area. This runs in line with a study conducted by Hockers et al who evaluated the use of resorbable membranes and xenografts in the treatment of bone defects around dental implants <sup>(25)</sup>.

## CONCLUSION

Within the limitations of this study and after analyzing the current results, we can conclude that the inter-radicular bone-drilling approach prior to roots extraction could be regarded as an effective modification to the usual drilling procedure that allow accurate central position for the implant in mandibular molar area which has an impact on the success of the future prosthesis. Implants that placed by inter-radicular implant bed preparation before roots extraction had a higher primary stability and less marginal bone loss than those placed after

extractive of roots though not significant due to the small sample size. The use of xenograft and collagen membrane coverage on immediate implants has a positive impact on the bone level changes in both groups. More research with a larger sample size is needed to see if this technique could be generalizable.

## REFERENCES

1. Schropp L, Isidor F. Timing of implant placement relative to tooth extraction. *J Oral Rehabil.* 2008;35( Suppl 1):33-43.
2. Barone A, Toti P, Quaranta A, Derchi G, Covani U. The Clinical Outcomes of Immediate Versus Delayed Restoration Procedures on Immediate Implants: A Comparative Cohort Study for Single-Tooth Replacement. *Clin Implant Dent Relat Res.* 2015;17:1114-26.
3. Lazzara RJ. Immediate implant placement into extraction sites: surgical and restorative advantages. *Int J Periodontics Restorative Dent.* 1989;9:332-43.
4. Crespi R, Cappare P, Gherlone E. Fresh-socket implants in periapical infected sites in humans. *J Periodontol.* 2010;81:378-83.
5. Lee DH, Choi BH, Jeong SM, Xuan F, Kim HR. Effects of flapless implant surgery on soft tissue profiles: a prospective clinical study. *Clin Implant Dent Relat Res.* 2011;13:324-9.
6. Hwang KG, Park CJ. Ideal implant positioning in an anterior maxillary extraction socket by creating an apicopalatal guiding slot: a technical note. *Int J Oral Maxillofac Implants.* 2008;23:121-2.
7. Wilson TG Jr, Buser D. Timing of Anterior Implant Placement Postextraction: Immediate Versus Early Placement. *Clin Adv Periodontics* 2011;1:61-76.
8. Fugazzotto PA. Implant placement at the time of mandibular molar extraction: description of technique and preliminary results of 341 cases. *J Periodontol* 2008;79:737-47.
9. Scarano A. Traditional Postextractive Implant Site Preparation Compared with Pre-extractive Interradicular Implant Bed Preparation in the Mandibular Molar Region, Using an Ultrasonic Device: A Randomized Pilot Study. *Int J Oral Maxillofac Implants.* 2017;32:655-60.
10. Atieh MA, Payne AG, Duncan WJ, de Silva RK, Cullinan MP. Immediate placement or immediate restoration/loading

- of single implants for molar tooth replacement: a systematic review and meta-analysis. *Int J Oral Maxillofac Implants.* 2010;25:401-15.
11. Peñarrocha M, Uribe R, Balaguer J. Immediate implants after extraction. A review of the current situation. *Med Oral* 2004; 9:234-42.
  12. Barone A, Toti P, Marconcini S, Derchi G, Saverio M, Covani U. Esthetic Outcome of Implants Placed in Fresh Extraction Sockets by Clinicians with or without Experience: A Medium-Term Retrospective Evaluation. *Int J Oral Maxillofac Implants.* 2016;31:1397-406.
  13. Rebele SF, Zuhr O, Hürzeler MB. Pre-extractive interradicular implant bed preparation: case presentations of a novel approach to immediate implant placement at multirrooted molar sites. *Int J Periodontics Restorative Dent.* 2013; 33:89-96.
  14. Scarano A, Carinci F, Quaranta A, Iezzi G, Piattelli M, Piattelli A. Correlation between implant stability quotient (ISQ) with clinical and histological aspects of dental implants removed for mobility. *Int J Immunopathol Pharmacol.* 2007; 20 (1 Suppl 1):33-6.
  15. Rodriguez-Tizcareño MH, Bravo-Flores C. Anatomically guided implant site preparation technique at molar sites. *Implant Dent.* 2009;18:393-401.
  16. Smith RB, Tarnow DP. Classification of molar extraction sites for immediate dental implant placement: technical note. *Int J Oral Maxillofac Implants.* 2013;28:911-6.
  17. Schwartz-Arad D, Grossman Y, Chaushu G. The clinical effectiveness of implants placed immediately into fresh extraction sites of molar teeth. *J Periodontol.* 2000;71:839-44.
  18. Davarpanah M, Szmukler-Moncler S. Unconventional implant treatment: I. Implant placement in contact with ankylosed root fragments. A series of five case reports. *Clin Oral Implants Res.* 2009;20:851-6.
  19. Urban T, Kostopoulos L, Wenzel A. Immediate implant placement in molar regions: a 12-month prospective, randomized follow-up study. *Clin Oral Implants Res.* 2012;23:1389-97.
  20. Hamouda NI, Mourad SI, El-Kenawy MH, Maria OM. Immediate implant placement into fresh extraction socket in the mandibular molar sites: a preliminary study of a modified insertion technique. *Clin Implant Dent Relat Res.* 2015; (17 Suppl 1): e107-16.
  21. Hayacibara RM, Gonçalves CS, Garcez-Filho J, Magro-Filho O, Esper H, Hayacibara MF. The success rate of immediate implant placement of mandibular molars: a clinical and radiographic retrospective evaluation between 2 and 8 years. *Clin Oral Implants Res.* 2013;24:806-11.
  22. Tallarico M, Xhanari E, Pisano M, De Riu G, Tullio A, Meloni SM. Single post-extractive ultra-wide 7 mm-diameter implants versus implants placed in molar healed sites after socket preservation for molar replacement: 6-month post-loading results from a randomised controlled trial. *Eur J Oral Implantol.* 2016;9:263-75.
  23. Elshoabi M. Pre-extractive inter-radicular implant bed preparation versus conventional post extractive inter-radicular implant bed preparation in mandibular molars: A Randomized Clinical Trial. *Adv J Dent.* 2020;2:61-79.
  24. Hoffmann O, Bartee BK, Beaumont C, Kasaj A, Deli G, Zafiroopoulos GG. Alveolar bone preservation in extraction sockets using non-resorbable dPTFE membranes: a retrospective non-randomized study. *J Periodontol.* 2008; 79:1355-69.
  25. Hockers T, Abensur D, Valentini P, Legrand R, Hammerle CH. The combined use of bioresorbable membranes and xenografts or autografts in the treatment of bone defects around implants. A study in beagle dogs. *Clin Oral Implants Res.* 1999;10:487-98.