

## RELIABILITY OF USING VIRTUAL PLANNING SOFTWARE IN PREDICTION OF 3D VOLUMETRIC SOFT TISSUE CHANGES AFTER GENIOPLASTY IN PATIENTS WITH CHIN DEFORMITY (CASE SERIES)

Mennatallah A. Mahmoud\*, Mohamed M. Khashba\*\* and Nader N. ElBokle\*\*\*

### ABSTRACT

**Objectives:** The aim of this study was to evaluate the reliability of software soft tissue prediction.

**Materials and Methods:** Computer-guided genioplasty was done for seven patients with a retruded chin followed by six months' postoperative period of follow-up to evaluate the results. Materialize Mimics software was used for the simulation and 3-Matic software was used for guide designing and computing the comparison between the actual and simulated soft tissue.

**Results:** This study found that the software accuracy was an average of 92.86%, which is an all-simulation accuracy percentage that ranged from -2 to 2 mm and the mean of absolute error was 0.169.

**Conclusion:** This software was reliable in the prediction of soft tissue changes except in the submental region and the tip of the chin.

**KEYWORDS:** Chin Deformity, Genioplasty, Virtual Planning Software

### INTRODUCTION

Numerous studies had been done to study the beauty of the face and to analyze the face proportions and dimensions. It is a small area in the whole body but it is the window to connect with the world. One of the main factors to keep the face harmony balanced is the chin (Arroyo *et al.*, 2016).

In this era of technology, the selection of the treatment plan does not only depend on the surgeon's decision but also on the patient-perceived need, expectation, and objective. The prediction of the orthognathic surgery had to move in a more advanced way to fulfill the patient imagination and solidify the confidence between the patient and

\* Student, Department of Oral and Maxillofacial Surgery, Faculty of Dentistry, Cairo University

\*\* Assistant Professor of Oral and Maxillofacial Surgery, Faculty of Dentistry, Cairo University

\*\*\* Professor of Oral and Maxillofacial Surgery, Faculty of Dentistry, Cairo University

the surgeon. Virtual software added great value in orthognathic surgery. Through different models, the software can predict the soft tissue reaction toward any bony move (Van Hemelen *et al.*, 2015; Olivetti *et al.*, 2019).

Furthermore, the software has become more helpful and highly recommended because of its ability to register the patient photo that represents the surface texture of the skin over the thresholded soft tissue that was calculated from the CT or CBCT. Many patients' decisions are taken now based on this simulation especially those who seek esthetic outcome. That's why recent studies have focused on checking the prediction reliability (Terzic, Combescure and Scolozzi, 2013).

The effect of orthognathic surgery had been studied by measuring the soft tissue and hard tissue changes in 2 dimensions, but recently a volumetric change was the target. Thus, it was essential to start building a ratio based on a 3D design considering the different responses between the soft tissue and the hard tissue towards a specific move. Although the soft tissue is the mirror image of the hard tissue, it has multiple factors that make its response different than the hard tissue (Olate, Zaror and Mommaerts, 2017; Shetty and Kumar, 2018).

Therefore, this study aimed to check the software simulation accuracy compared to the actual results and to establish a ratio correlating the 3D volumetric changes between the soft tissue and hard tissue.

## **PATIENTS AND METHODS**

### **Study design**

This study was conducted on seven patients with genial deformity selected from the outpatient clinic of Oral & Maxillofacial surgery department, Faculty of Oral and Dental Medicine, Cairo University. All patients signed an informed consent prior to their participation in the study. This study was conducted according to the Declaration of Helsinki and was

approved from the ethical committee in Cairo University.

### **Patient collection**

#### **Inclusion criteria**

Patients with isolated genial deformities that required surgical correction and indicated for osseous genioplasty, and patients older than 18 years old were included in the study.

#### **Exclusion criteria**

Patients with uncontrolled systemic diseases, with previous radiotherapy to the area of interest, on bisphosphonates therapy, with cleft lip, palate, or other craniofacial anomalies, with a history of facial trauma or previous orthognathic surgery, or with orthodontic appliances were excluded from the study.

### **Preoperative preparation**

Impression of the lower arch was taken using Alginate material (Tropicalgin, Zhermack, Italy), the cast after that was scanned using Deluxe Open Technologies Scanners (Italy). DICOM format was imported to Materialize Mimics software (Materialize Dental, Leuven, Belgium). Threshold segmentation was selected for 3D calculation of soft or hard tissues (bone and teeth). Calculation of the 3D part followed the thresholding with optimal quality.

3D cephalometric analysis was applied by determining the exact location of Bilateral Porion, Pognion, Sella, Gnathion, Lower incisor tip, Menton, bilateral Mental foramen, Nasion, and bilateral Orbitale. By locating those points, the Frankfort, Mental plane, Nasion perpendicular, and orbital plane got constructed

According to the analysis and available thickness of the symphysis, the virtual cut was done and moved anteriorly. The safety of the mental nerves and anterior teeth were considered during planning the level of the cut.

After the chin was virtually moved, soft tissue was simulated, exported, and saved as STL file for the comparison after 6 months follow up with the actual soft tissue.

The mandible, the cast of the lower jaw, the cutting plane, and the chin segment in the new position was exported to “3-MATIC 12” software for designing the cutting and positioning guide.

First, the cast was aligned with teeth mask to have a proper teeth indentation as the cutting guide will depend on the teeth then the teeth on the model were cut from the mandible and replaced by the scanned teeth of the cast.

Then the chin cutting guide was drawn and extruded by 3 mm thickness, the plane of the cutting line was superimposed to determine the slit of the saw that will cut through on the guide.

Cylinders were inserted to create the holes for the screws; those predetermined screw holes of the cutting guide were designed to represent the same screw holes of the positioning guide.

The Positioning guide was designed to guide the chin segment after the osteotomy in the planned position while keeping enough space for plate

fixation. The parts of the cutting guide and the Positioning guide were exported as STL file and both of them were 3D printed using SLA technology. (Fig. 1)

#### Surgical Procedure:

The procedure was performed under general anesthesia with nasotracheal intubation. Local anesthesia of 4 % articaine (Artinibsa: Inibsa Dental, Barcelona, Spain) with 1:100,000 epinephrine was given at the site of the incision.

The occlusal wafer was adapted to the teeth followed by the chin cutting part and finally, the connector joined both pieces together. The cutting guide was fixed by using 2.0 monocortical mini-screws in their specific holes to be ready for cutting. (Fig 2) & (Fig. 3)

By using a micro reciprocating saw, the osteotomy was done bi-cortically through the slit designed in the cutting guide. After mobilizing the chin segment, the chin was advanced and the positioning guides were fixed with the same mini-screws in the predetermined holes of the cutting guide. The holes guaranteed the exact new position of the chin segment that match with preoperative planning.

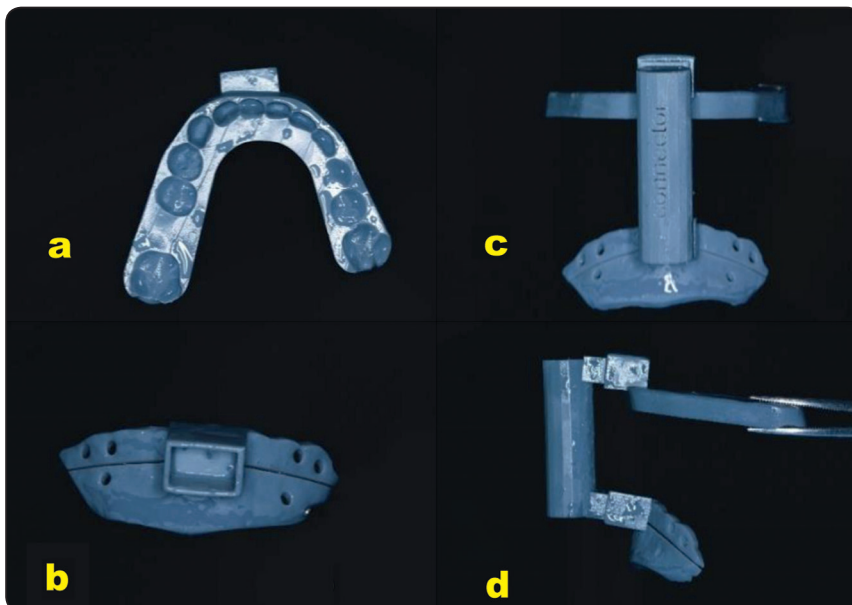


Fig. (1): a) Occlusal wafer, b) chin cutting guide, c) frontal view of the cutting guide parts assembled together with the connector, d) profile view of the assembled cutting guide parts.

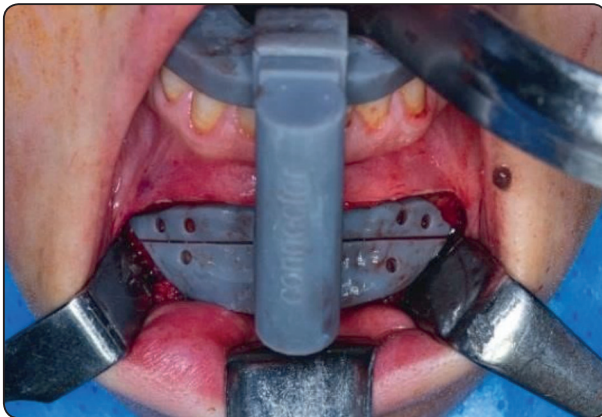


Fig. (2): The connector was placed between the wafer and the cutting guide to determine the exact position of the cutting guide on the bone.

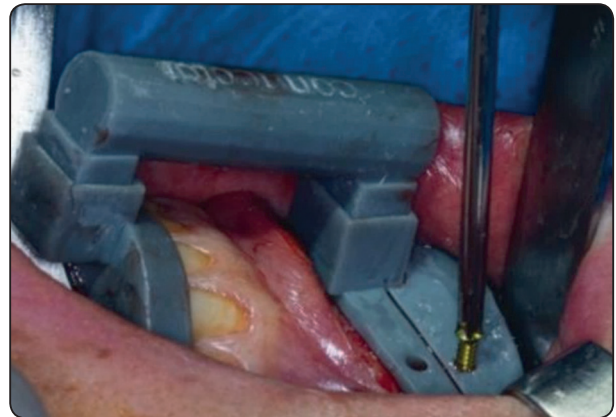


Fig. (3): The guide fixed in place using Titanium 2.0 mini-screws.

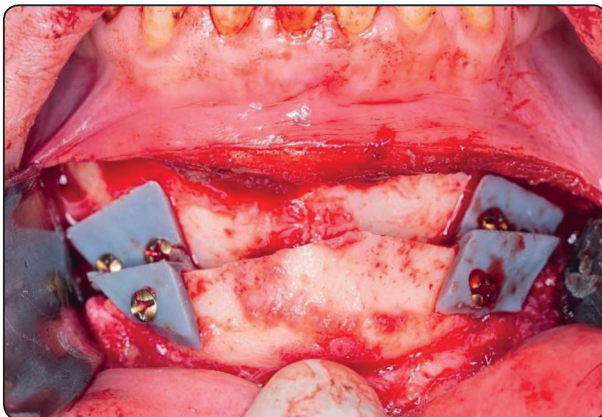


Fig. (4): Positioning guides after fixation, each guide needed 3 screws for stable fixation

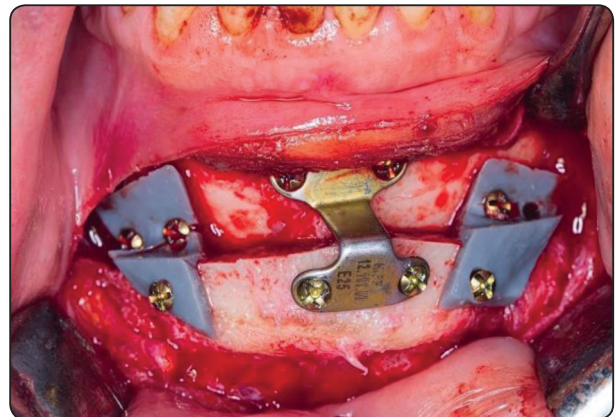


Fig. (5): Prefabricated 2.0 chin plate along with the positioning guide

2.0 mm chin plate were bent on the chin and fixed with 2.0 titanium mini-screws before removing the positioning guide. (Fig. 4) & (Fig. 5)

Wound closure was then done using 3-0 polyglycolic suture in two layers.

#### Postoperative care and follow-up

All patients were instructed to complete 5 days' course of Unasyn (Cluvalinic acid and Sulbactam) antibiotic 1.5 gm q 12 hr, Voltaren (Diclofenac sodium) 75mg q12hr for 2 days, Dexamethasone 8mg intramuscular injection vial q8h for 2 days, AntiSeptol (Chlorhexidine Mouthwash) 4 times per day for 14 days.

The following postoperative instructions were given to all patients, which included: Ice packs to chin (maintained 10 minutes every 30 minutes for the first 24 hours), Pressure bandages were asked to be maintained in place covering the chin area for the 1<sup>st</sup> three postoperative days, avoid rinsing or spitting on the day of surgery, avoid eating hot and hard food on the day of surgery, start mouth rinses and gentle teeth brushing the day following the procedure. Patients were specifically forewarned and reassured that swelling and numbness in the chin area were expected and normal.

All patients were instructed to complete 5 days' course of Unasyn antibiotic 1.5 gm q 12 hr (Cluvalinic acid and Sulbactam), Voltaren 75mg q12hr for

2 days (Diclofenac sodium), Dexamethasone 8mg intramuscular injection vial q8h for 2 days, AntiSeptol (Chlorhexidine Mouthwash) 4 times per day for 14 days. All patients were followed up after 1 week of surgery, one month, 3 months, and 6 months' interval.

### Post-Operative evaluation

#### Image acquisition and registration

CBCT was done six months postoperatively with the same parameters and using the same machine as mentioned before. The DICOM files resulted from the scan were imported into "Mimics 20 innovative suite software", thresholding within the previous range of soft tissue and hard tissue was done and calculated.

The two parts of the soft tissue and the hard tissue of the skull were exported as STL to be aligned with the previous saved preoperative STLs and simulated soft tissue STLs on Proplan CMF (ProPlan, Ink Technologielaan Leuven Belgium) by using surface registration.

The surface registration depended on the unchanged regions on the soft tissue part which were the forehead, both eyes with eyelids, the cheek areas, and the nasal bridge region. The accuracy of the surface registration was checked from the distance color mapping and verified through 2d views (Coronal, Axial, Sagittal). (Fig. 6)

All STLs were processed, cleaned of artifacts, re-meshed, and turned to a solid part using Mesh mixer Software (Autodesk, McInnis Parkway, San Rafael). The simulated soft tissue part and the actual postoperative part were used to test the accuracy of the simulation.

#### Accuracy of Surgical guide

The simulated mandible with the advanced chin was aligned with the postoperative actual mandible using surface registration. Pogonion point was identified on both parts and measured to the Nasion

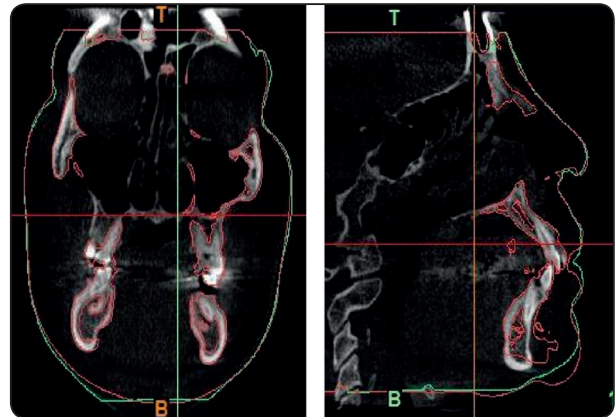


Fig. (6): verification of the registration on the 2D view

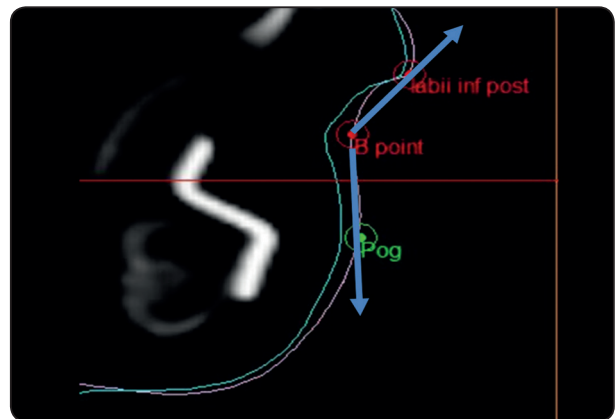


Fig. (7): Mento-labial angle was measured between Labii inferioris, B point and Pog. Soft tissue to compared between the actual and simulated soft tissue

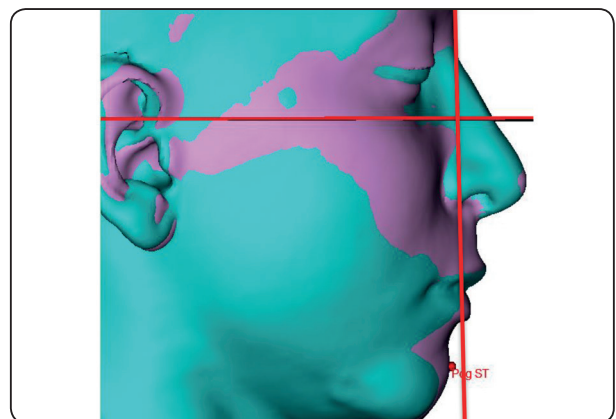


Fig. (8): Horizontal measure was done using Zero Meridian analysis to be compared between the actual and simulated soft tissue.

perpendicular plane to determine the difference between the actual and simulated position.

### Determining the accuracy of the simulation

The actual postoperative soft tissue surface was compared with the virtual simulation using 3-Matic. The comparison algorithm measured the distance of every triangle corner of the postoperative surface. This resulted in a set of measures that can be used for the statistical analysis. (Bianchi *et al.*, 2010; Marchetti *et al.*, 2011; Mazzoni *et al.*, 2015)

Also, Linear (vertical and horizontal), angular measures (Mento-Labial), were taken for both actual and simulated soft tissue

## RESULTS

Frontal and profile photos were taken after 6 months.

### Clinical results

#### Intra-operative

- The operation time was recorded from the incision till the suturing. it decreased gradually by the last patient. The maximum was 180 minutes and the minimum was 120 minutes with a mean (SD) of  $149.29 \pm 22.81$  minutes

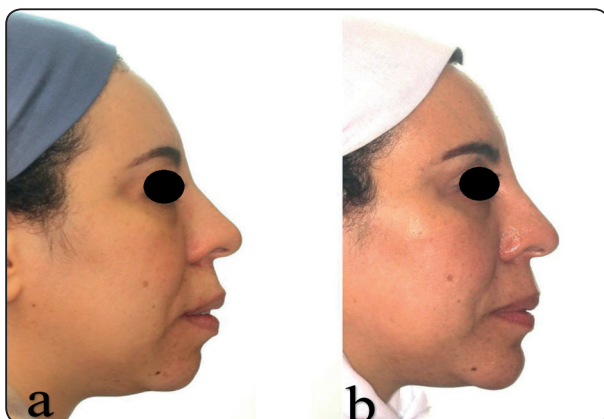

Fig. (9): Profile view a. preoperative, b. postoperative

### Postoperative complication

All patients healed well with no wound dehiscence. No significant intraoperative complication was reported during surgery. The postoperative edema was shown with different degrees between mild, moderate, and severe within 2 to 4 weeks, till it resolved totally at 3 months. Nerve affection was assessed using the two-point discrimination method. After 1 week, 1 month, and 3 months. During the first week of follow-up, all patients had numbness in the lower lip and chin due to flap retraction, the numbness decreased in the second and third weeks and almost recovered within 3 months for all patients except one patient who recovered after 6 months.

### Patient Satisfaction:

The score of the patient satisfaction questionnaire was evaluated after 1 month, 3 months, and 6 months. One-way ANOVA test used for comparison between 1 month, 3 months, and 6 months, there was an insignificant increase in patient satisfaction after 3 months, followed by a significant increase after 6 months.

### Statistical analysis

Paired Student "t" test was used to evaluate the accuracy of surgical guide, accuracy of prediction. Intra-observer reliability was done to investigate the measurement errors for the methods used in this study using ICC (interclass correlation co-efficient) and Paired Student's t- test.

### Accuracy of surgical guide

The position of the actual chin segment post-operatively and after simulation was compared by using Pog to Nasion perpendicular analysis.

Student "t" test showed no statistically significant difference between positions, the mean and standard deviation of both actual and simulated was listed in (Table 1)

TABLE (1): Student “t” test comparing between actual and simulated pogonion position,

Actual		Simulated		“t”	Probability
Mean	St Dev	Mean	St Dev		
0.886	0.402	1.200	0.379	1.506	0.079 NS*

\*NS=Non significant at  $P \geq 0.05$

**Accuracy of the prediction**

**Software Descriptive statistical analysis**

The reliability was calculated by comparing the simulated soft tissue with the actual postoperative in 3 different histogram range (between -2 to 2 mm, above it and below it)

This results in a set of measurements (Mean absolute error, standard deviation, and percentage of each histogram) that can be used for statistical analysis.

For all 7 patients, the average absolute error was 0.169(0.1) mm. In 3.07%(2.49)of the simulation, the error was  $\geq 2$ mm while in 4.36% (1.65) of the simulation the error was  $\geq -2$  mm. The error range of -2 to 2 mm constructed 92.86% (1.46) of the simulation as shown in (Table 2)

TABLE (2): Descriptive statistical analysis for each patient.

Pt no.	Total Histogram range	Mean absolute error	Standard deviation	Histo-gram from -2 to 2 mm		Histogram more than 2		Histogram more than -2	
1	-4.2 to 2.9	0.05	0.866	94%	2 to 2.9	1%	-2 to -4	5%	
2	-5.5 to 5.5	0.1	1.3	93%	2 to 5.5	4%	-2 to -5.5	3%	
3	-4 to 2.5	-0.3	1.02	90%	2 to 2.5	3%	-2 to -4	7%	
4	-2.5 to 3.5	0.25	1.123	92%	2 to 3.5	8%	-2 to -2.5	2%	
5	-3.2 to 3.9	0.21	0.9	93%	2 to 3.9	3%	-2 to -3.2	4%	
6.	-4.5 to 2.2	-0.22	0.81	94%	2 to 2.2	0.5%	-2 to -4.5	5.5%	
7	- 4.2 to 3	0.055	0.88	94%	2 to 3	2%	-2 to -4.2	4%	

**Linear Dimensional analysis**

**Horizontal measurement**

**Zero meridian analysis**

Results showed a statistically significant difference between actual and simulated Pog`, the simulated readings were higher than the actual readings which meant that the simulation under predicted the Pog` after the anterior chin advancement (Table 3).

TABLE (3): Student “t” test to compare actual and predicted records of Zero Meridian Analysis,

Actual		Predicted		“t”	Probability
Mean	St Dev	Mean	St Dev		
0.929	0.499	1.700	0.522	4.58	0.001*

\*: Significant at  $P \leq 0.05$ .

**Lateral points:**

Lateral to the Pog`, 2 points were taken on the right and left sides. Student “t” test showed no statistically significant difference between simulated and actual measurements on both right and left sides (Table 4).

TABLE (4): Student paired “t” test to compare lateral records in both actual and predicted records. NS=Non significant at  $P \geq 0.05$

	Simulated		Actual		“t”	Probability
	Mean	St Dev	Mean	St Dev		
Right	66.24	13.61	70.83	12.80	1.092	0.158 NS
Left	66.87	16.05	72.34	14.38	1.352	0.113 NS

**Vertical measurement:**

Point of Pog` was measured vertically to the Frankfort plane. Data were presented as a mean and standard deviation, Student “t” test was used to compare the results and it showed no statistical difference in the vertical dimension between simulation and actual (Table 5)

TABLE (5): Student paired “t” test to compare pognion point in both actual and predicted records, NS=Non significant at  $P \geq 0.05$ .

Pognion	Simulated		Actual		“t”	Probability
	Mean	St Dev	Mean	St Dev		
	81.08	7.40	81.05	7.23	0.082	0.468 NS

Table (7): Intra class Correlation coefficient for different parameters (n = 7)

Measurements	Actual			Predicted/ Simulation		
	ICC coefficient	95% C.I	p	ICC coefficient	95% C.I	p
Zero meridian analysis	0.721	0.028 – 0.946	0.022*	0.749	0.090 – 0.952	0.016*
Mentolabisal angle	0.721	0.029 – 0.946	0.022*	0.907	0.557 – 0.983	0.001*
Right lateral points	1.000	0.999 – 1.000	<0.001*	1.000	0.999 – 1.000	<0.001*
Left lateral points	1.000	0.999 – 1.000	<0.001*	1.000	0.999 – 1.000	<0.001*

CI: Confidence interval \*: Statistically significant at  $p \leq 0.05$

**Index for interagreement score**

Value of ICC	Strength of agreement
Below 0.50	Poor
0.50 and <0.75	Moderate
0.75 and 0.90	Good
Above 0.90	Excellent

**Angular dimensional analysis (Mento-labial angle)**

The Data was presented as mean and standard deviation. Student “t” test was used to compare the results of mento-labial angle between simulated and actual soft tissue. And it showed a statistically significant difference (Table 6)

TABLE (6): Student “t” test to compare actual and predicted records of Mento-labial angle.

Actual		Predicted		“t”	Probability
Mean	St Dev	Mean	St Dev		
126.929	7.992	135.714	6.626	7.753	.001*

**Reliability analysis**

**Intra-observer reliability**

There was very good intra-observer reliability regarding all measurements with Intra Class Correlation Coefficient (ICC) with an average 0.875. (Table 7)



## DISCUSSION

Multiple studies had utilized 2D cephalometry in the prediction of the facial profile after the surgery. However, within the last decade, a CT scan was used instead of the lateral cephalometric X-ray. (Grauer et al., 2009; Jung et al., 2009; J. Y. Park et al., 2013).

All the studies that used CT scan in their facial analysis reported that the CT has multiple drawbacks, such as the high radiation dose and the supine position of the patient during image acquisition. This will cause changes in the soft tissue especially at the lower face because of the gravity.

This study depended on the CBCT for its lower dose compared to the CT with the ability to scan the patient in an upright position while soft tissue is relaxed to avoid the error factor of the gravity.

Although there were plenty of studies that were directed toward facial analysis by angular and linear measures on 3D view, Olate et al.(2017) concluded in a systematic review that no data can be applied to determine the soft to hard tissue region using 3D analysis in orthognathic surgery.

Therefore, it has been logical to start analyzing the face in the 3D quantitative assessment of hard and soft tissue by evaluating the changes in a volume, not a linear or angular measure. Maal et al was the first to study the volumetric changes of hard tissue and soft tissue after mandibular advancement surgery (Maal et al., 2012).

This study was conducted to assess the validity of using virtual surgical planning software (Materialize Mimics software) in the prediction and (Materialize 3-Matic software) in calculating a ratio based on volumetric changes and to evaluate the soft tissue response around the chin.

One of the major challenges to conduct this type of study is to ensure that the surgical simulation simulated by software matches precisely with the actual surgery.

The surgery planning was performed on Materialize Mimics software and 3Matic software was used for designing a cutting and a positioning guide to transfer the virtual planned surgery to the actual surgery.

Designing a cutting guide and positioning guide to ensure the accuracy of the Computer-guided genioplasty proved its accuracy by multiple authors. One of them was Wang et al who came with a highly accurate result in transferring the simulated surgery to the actual one. The largest difference error between the planned and the actual postoperative chin was 0.9mm. This study has a more accurate result as the maximum linear difference between the actual and simulated genioplasty was 0.5mm (Shaheen *et al.*, 2019; Wang *et al.*, 2020).

This point is very important because if any discrepancy between the actual surgery and the simulated surgery is found, it will affect the soft tissue prediction evaluation. (Marchetti et al. 2011) cut this debate by using the postoperative CT scan and simulating the surgery on the preoperative CT. This could be done by tracing the osteotomy lines and reposition the segment on the same of the actual postoperative position. Although this trial has a good result, moving the reproduced segments into their real postoperative position is a user-dependent procedure that must be associated with some degree of error.

To ensure that the edema has no contributing error in the soft tissue evaluation, the time interval between the preoperative CBCT and the postoperative CBCT was 6 months. (Kau, Cronin and Richmond, 2007) showed also that 6 months is the average time needed for the soft tissue to return to its normal size and shape and be free of any edema and swelling.

The whole comparison results depended on the precise superimposition of two parts and there were multiple registration methods for superimposition. The surface registration is an ideal method as it

considers the factor of every point embedded among the models' surface to be investigated.

Surface-based registration (SBL) is preferred over Point-Based Registration because it is not affected by human error during the point registration. Even if multiple points were used in the registration, still SBL or Volume Based Registration (VBL) would be much preferable (Bianchi et al., 2010; Shaheen et al., 2019).

One of the drawbacks of the Materialize Mimics Software is the limited option in the registration as it is limited whether using point registration or global registration only. This was overcome by using Materialize Proplan CMF software (Knoops et al., 2019; Shaheen et al., 2019).

The accuracy of the soft tissue parts registration was evaluated by verification of the unchanged surface of both simulated and actual soft tissue outline on the Axial, sagittal and coronal cuts and by observing the Root Mean Square (RMS) value. It was reported when the RMS was equal to 0.5 or less, this means accurate alignment. The average of RMS in this study for surface registration is 0.4 for the seven patients (Bared et al., 2014; Lo et al., 2018).

By evaluating the results of this study regarding the accuracy of the prediction, it was found that the accuracy maximum tolerance level was at 2mm in a study published by Bianchi et al., Similarly, in this study, the range of accuracy evaluation was limited from -2 to 2mm as the negative value means the under-prediction while the positive value means over-prediction (Bianchi et al., 2010; Mazzoni et al., 2015).

The mean absolute error in the present study using Materialize mimics software was equal to 0.169 which was lower than that found by Marchetti et al and Bianchi et al where they evaluated the use of SurgiCase-CMF software (Materialize,leuven, Belgium) for soft tissue simulation and found that

the mean absolute error was equal to 0.75 (Mazzoni et al., 2015).

Most of the studies made on the accuracy of the prediction were heterogeneous because the authors selected patients who were indicated for bi-maxillary surgery with or without genioplasty. There is a slight positive bias for this study and other studies in the literature that used the software comparison because the comparison between both actual and simulated soft tissue involved the areas that were not changed after surgery. Especially in this study, the unaffected part that wasn't changed was larger because it includes the whole mid-face and the body of the mandible not only the eyes and the forehead.

Labio- Mental angle showed a higher magnitude of error prediction as the mean difference between the actual and predicted was  $8.7^\circ$  and the "t" test was equal to 7.5 while the mean of linear measurement from pog` to Zeromeridian was 0.8 mm and the "t" test was equal to 4.58. This value of the difference in both linear and angular measurement means that the software was under-predicting the soft tissue response accurately compared to the actual results at those measures. On other hand, (Elshebiny et al. 2019) found in their analysis after bi-maxillary surgery with genioplasty, that the mean difference in the IMA was  $5.11^\circ$  by using Dolphin 3D software.

In addition, the error of underprediction was also showed in observing the different results between Li, Pog`, GN`, ME` and the point in the sub-mental region. The maximum error of prediction was at the sub-mental followed by gnathion`, pognion`, meton`.

Similarly, (Zhang, 2018) used Dolphin software in the prediction. He that the pognion, gnathion, and menton` was under-predicted. Specifically the Gn` and Me` recorded the highest error followed by Pog`. However the results of the point's difference were almost similar to Zhang's study; the lower lip result was totally against Zhang's result. In this

result, the lower lip showed the least prediction error while Zhang's result showed that the lower lip scored the highest prediction error. The sub-mental area showed the highest error in all patients. This value may be attributed to its non-linear response to the soft tissue.

## CONCLUSION

It was concluded that there is a discrepancy between the actual postoperative results and the virtual simulation results especially in the submental region and the tip of the chin.

## REFERENCES

- Bared, A., Rashan, A., Caughlin, B. P., & Toriumi, D. M. (2014) 'Lower Lateral Cartilage Repositioning Objective Analysis Using 3-Dimensional Imaging', *JAMA Facial Plast Surg*, 16(4), pp. 261–267. doi: 10.1001/jamafacial.2013.2552.
- Bianchi, A., Muyltermans, L., Di Martino, M., Lancellotti, L., Amadori, S., Sarti, A., & Marchetti, C. (2010) 'Facial Soft Tissue Esthetic Predictions: Validation in Craniomaxillofacial Surgery With Cone Beam Computed Tomography Data', *Journal of Oral and Maxillofacial Surgery*, 68(7), pp. 1471–1479. doi: 10.1016/j.joms.2009.08.006.
- Elshebiny, T., Morcos, A. S., & Mohammad, A. A. (2019) 'Accuracy of Three-Dimensional Soft Tissue Prediction in Orthognathic Cases Using Dolphin Three-Dimensional Software', *Journal of Craniofacial Surgery*, 30(2), pp. 525–528. doi: 10.1097/scs.0000000000005037.
- Grauer, D., Cevdanes, L. S. H. and Proffit, W. R. (2009) 'Working with DICOM craniofacial images', *American journal of orthodontics and dentofacial orthopedics* : official publication of the American Association of Orthodontists, its constituent societies, and the American Board of Orthodontics, 136(3), pp. 460–470. doi: 10.1016/j.ajodo.2009.04.016.
- Hotz, H., Peixoto, I., Freire, L., Lima, R., Roberto, J., & Jurado, P (2016) 'Clinical evaluation for chin augmentation: literature review and algorithm proposal', *Brazilian Journal of Otorhinolaryngology*, 82(5), pp. 596–601. doi: 10.1016/j.bjorl.2015.09.009.
- Jung, Y. J., Kim, M. J. and Baek, S. H. (2009) 'Hard and soft tissue changes after correction of mandibular prognathism and facial asymmetry by mandibular setback surgery: Three-dimensional analysis using computerized tomography', *Oral Surgery, Oral Medicine, Oral Pathology, Oral Radiology and Endodontology*, 107(6). doi: 10.1016/j.tripleo.2008.12.026.
- Kau, C. H., Cronin, A. J. and Richmond, S. (2007) 'A Three-Dimensional Evaluation of Postoperative Swelling following Orthognathic Surgery at 6 Months', *Plastic and Reconstructive Surgery*, 119(7), pp. 2192–2199. doi:10.1097/01.prs.0000260707.99001.79.
- Knoop, P. G. M., Borghi, A., Breakey, R. W. F., Ong, J., Jeelani, N. U. O., Bruun, R., Schievano, S., Dunaway, D. J., & Padwa, B. L. (2019) 'Three-dimensional soft tissue prediction in orthognathic surgery: a clinical comparison of Dolphin, ProPlan CMF, and probabilistic finite element modelling', *International Journal of Oral and Maxillofacial Surgery*, 48(4), pp. 511–518. doi: 10.1016/j.ijom.2018.10.008.
- Lo, L. J., Weng, J. L., Ho, C.T., & Lin, H. H. (2018) 'Three-dimensional region-based study on the relationship between soft and hard tissue changes after orthognathic surgery in patients with prognathism', *PLoS ONE*, 13(8), pp. 1–15. doi: 10.1371/journal.pone.0200589.
- Maal, T. J. J., De Koning, M. J. J., Plooi, J. M., Verhamme, L. M., Rangel, F. A., Bergé, S. J., & Borstlap, W. A. (2012). One year postoperative hard and soft tissue volumetric changes after a BSSO mandibular advancement. *International Journal of Oral and Maxillofacial Surgery*, 41(9), 1137–1145.
- Marchetti, C., Bianchi, A., Muyltermans, L., Martino, M. Di, Lancellotti, L., & Sarti, A. (2011) 'Validation of new soft tissue software in orthognathic surgery planning', *International Journal of Oral and Maxillofacial Surgery*, 40(1), pp. 26–32. doi: 10.1016/j.ijom.2010.09.004.
- Mazzoni, S., Bianchi, A., Schiariti, G., Badiali, G., & Marchetti, C. (2015) 'Computer-Aided Design and Computer-Aided Manufacturing Cutting Guides and Customized Titanium Plates Are Useful in Upper Maxilla Waferless Repositioning', *Journal of Oral and Maxillofacial Surgery*, 73(4), pp. 701–707. doi: 10.1016/j.joms.2014.10.028.
- Olate, S., Zaror, C. and Mommaerts, M. Y. (2017) 'A systematic review of soft-to-hard tissue ratios in

- orthognathic surgery. Part IV: 3D analysis – Is there evidence?’, *Journal of Cranio-Maxillofacial Surgery*, 45(8), pp. 1278–1286. doi: 10.1016/j.jcms.2017.05.013.
- Olivetti, E. C., Nicotera, S., Marcolin, F., Vezzetti, E., Sotong, J.P.A., Zavattoni, E., & Ramieri, G (2019) ‘applied sciences 3D Soft-Tissue Prediction Methodologies for Orthognathic Surgery — A Literature Review’, pp. 1–23.
  - Park, J.-Y., Kim, M. J. and Hwang, S. J. (2013) ‘Soft tissue profile changes after setback genioplasty in orthognathic surgery patients’, *Journal of Cranio-Maxillofacial Surgery*, 41(7), pp. 657–664. doi: 10.1016/j.jcms.2013.01.005.
  - Shaheen, E., Shujaat, S., Saeed, T., & Jacobs, R., (2019) ‘Three-dimensional planning accuracy and follow-up protocol in orthognathic surgery: a validation study’, *International Journal of Oral and Maxillofacial Surgery*, 48(1), pp. 71–76. doi: 10.1016/j.ijom.2018.07.011.
  - Shetty, S. K. and Kumar, M. (2018) ‘Scholars Journal of Dental Sciences (SJDS) Computerized Prediction of Orthognathic Surgery’. doi: 10.21276/sjds.2018.5.2.5.
  - Terzic, A., Combescure, C. and Scolozzi, P. (2013) ‘Accuracy of Computational Soft Tissue Predictions in Orthognathic Surgery From Three-Dimensional Photographs 6 Months After Completion of Surgery: A Preliminary Study of 13 Patients’, *Aesthetic Plastic Surgery*, 38(1), pp. 184–191. doi: 10.1007/s00266-013-0248-4.
  - Van Hemelen, G., Van Genechten, M., Renier, L., Desmedt, M., Verbruggen, E., & Nadjmi, N. (2015) ‘Three-dimensional virtual planning in orthognathic surgery enhances the accuracy of soft tissue prediction’, *Journal of Cranio-Maxillofacial Surgery*, 43(6), pp. 918–925. doi: 10.1016/j.jcms.2015.04.006.
  - Wang, L. dong, Ma, W., Fu, S., Zhang, C. bin, Cui, Q. ying, Peng, C. bang, & Li, M. (2020) ‘Design and manufacture of dental-supported surgical guide for genioplasty’, *Journal of Dental Sciences*. doi: 10.1016/j.jds.2020.07.017.
  - Zhang, X. (2018). Accuracy of computer-aided prediction in soft tissue changes after orthodontic treatment. *The American Association of Orthodontists*, 823–831.