

Comparative study between transpedicular screws fixation with and without interbody fusion using cages in lumbar spondylolisthesis.

Osama Mostafa Mowafy,¹ MBBCH, Mostafa mahmoud Abo El Khir,² MD, Tarek Mohamed Abd El-Hameed El-Zayat,³ MD, Ibrahim Ewais,² MD.

* Corresponding Author:

Osama Mostafa Mowafy

Osamamowafy28@gmail.com

Received for publication November 18, 2021; Accepted April 09, 2022; Published online April 09, 2022.

Copyright The Authors published by Al-Azhar University, Faculty of Medicine, Cairo, Egypt. Users have the right to read, download, copy, distribute, print, search, or link to the full texts of articles under the following conditions: Creative Commons Attribution-Share Alike 4.0 International Public License (CC BY-SA 4.0).

doi: 10.21608/aimj.2022.106779.1666

¹Neurosurgery Department, Agouza Police Hospital, Cairo, Egypt.

²Neurosurgery Department, Ahmed Maher Teaching Hospital, Cairo, Egypt.

³Diagnostic Radiology Department, Ahmed Maher Teaching Hospital, Cairo, Egypt.

ABSTRACT

Background: lumbosacral spondylolisthesis is a common pathology characterized by single or multi-level slippage of lumbar vertebra over the other and may be associated with spinal canal stenosis and neural foramina compromise and may be presented by lower back pain, radicular pain, or neurogenic claudication pain. The current study aimed to compare the short-term clinical outcomes of two surgical fusion techniques in the management of this pathology.

Aim of the study: Comparative study to evaluate outcome clinically and radiologically in cases of 1st and 2nd grade of degenerative lumbar spondylolisthesis treated with transpedicular fixation with or without interbody fusion by lumbar cage.

Patients and Methods: 40 patients of lumbosacral spondylolisthesis were included in this study. Patients randomly divided into two groups according to the surgical approach and fixation technique used in the management. Group (A): operated by posterior lumbar decompression, transpedicular screw fixation and posterolateral intertransverse bony fusion. Group (B): operated by posterior decompression, transpedicular screw, posterolateral interbody fusion by insertion of interbody cages.

Results: Statistical significance was reached in blood loss, and post-operative fusion rates, but there was no significant difference between the two groups regarding to intra-operative or post-operative complication rates, clinical outcome, and patient satisfaction.

Conclusion: The application of the lumbar interbody cage with posterior lateral intertransverse fusion proved to have better fusion rates, but still intertransverse bony fusion alone gives the same results regarding patient satisfaction and post-operative clinical improvement with shorter operative time.

Keywords: Comparative study; screws fixation; lumbar interbody; cages.

Disclosure: The authors have no financial interest to declare in relation to the content of this article. The Article Processing Charge was paid for by the authors.

Authorship: All authors have a substantial contribution to the article.

INTRODUCTION

Spondylolisthesis describes the anterior or posterior displacement of a vertebra or the vertebral column in relation to the vertebrae below and has been recognized as a disorder characterized by a visible lumbosacral deformity, slipped vertebrae and fractures or other deformities of the pars interarticularis since 1782. The incidence of spondylolisthesis in the general adult population is 4–8%, varying depending on the race, age and sex of the population sample.¹

The most widely recognized classification system subdivides spondylolisthesis into isthmic, degenerative dysplastic, traumatic and pathologic type in addition to the postsurgical type.²

Most cases with spondylolisthesis are asymptomatic. Although the various types of spondylolisthesis differ as regard to cause, age, sex and pathology, several clinical presentations are common to all types including back pain, radicular pain, neuroclaudication pain, deformity kyphosis or scoliosis and gait disturbance).³

Degree of slip “meyerding grading system”. The antero-posterior diameter of the superior surface of the vertebra divided into quarters:

Grade I: Less than 25% slip, Grade II: From 25-50% slip, Grade III: From 50-75% slip, Grade IV: More than 75% slip⁴.

Standing lateral radiographs are the preferred method of evaluating slippage. Lateral X-rays of the spine

help to establish the diagnosis and degree of spondylolisthesis. Dynamic radiographs, such as the hyperextension and flexion views, may detect occult mobility. Recently, MRI is also helpful in defining the causes of radiculopathy⁵.

Many cases of isthmic spondylolisthesis can be managed conservatively. Surgery is indicated in resistant cases, operative intervention for spondylolisthesis employs variable combinations of neural decompression, fusion and internal fixation⁶.

The goals of surgery are relief of pain, improvement or resolution of neurologic deficit and improvement in the quality of life. Decisions about surgery are usually based not only on the nature of the localized pathology and associated symptoms and disability, but also on other factors such as the patient's occupation, athletic or recreational activity, and socio-economic situation⁷.

The aim of this study is to evaluate clinical and radiological outcome in cases of 1st and 2nd grade of degenerative lumbar spondylolisthesis treated with transpedicular fixation with or without interbody fusion by lumbar cage.

PATIENTS AND METHODS

Prospective and retrospective study will be carried on 40 patients presented with 1st and 2nd grade degenerative spondylolisthesis.

The inclusion criteria were: 1) patients with 1st and 2nd grade degenerative lumbar spondylolisthesis; 2) Patients who will agree to join the study according to the ethical considerations and consent will be taken from them.

However, exclusion criteria were: 1) Patients with other types of lumbar spondylolisthesis; 2) Patients with other grades of lumbar degenerative spondylolisthesis (3rd and 4th grades); 3) patients with other spine pathology (lumbar fracture, disc prolapse); 4) patients respond to conservative treatment

Preoperatively, the work of assessment included history taking, neurological examination and calculation of Oswestry Disability Index (ODI) and Visual Analogue Score (VAS) for pain assessment. In addition, imaging studies included MRI, computed tomography (CT) and dynamic plain X-ray.

The surgical treatment was carried out under general anesthesia with preoperative antibiotic prophylaxis in a prone position on spinal frame, with the abdomen free and the spine flexed to open the inter-laminar spaces. The surgical technique continues as described by Alexander, 1995.⁸

The operative data included the affected site, the intraoperative blood loss, and mode of fixation used. Postoperatively, there was assessment of pain and neurological disability if present. In addition, any intraoperative or post-operative complications were documented.

In this study we followed patients immediate postoperative and at 3th and 12th month postoperative where we evaluated them by clinical and radiological means.

Ethical considerations:

Lumber laminectomy and disc removal with lumbar pedicle screw fixation with or without inter body fusion consent includes discussing the operative procedure with the patient with its intended benefits of pain relief and possible improving function and symptoms of walk.

Discussing neurological deterioration, complications such as (Dural tear, infection, hematoma, nerve root injury).

The patient confidentiality and his/her right for withdrawal at any time was assured. The study protocol was approved by the local institutional review board (IRP) of Al-Azhar Faculty of Medicine.

Statistical analysis:

Statistical analysis were performed using Stata/IC version 16.1 for Windows (StataCorp, LLC, College Station, TX, USA). Descriptive statistics for quantitative data were expressed in tables as the mean \pm SD, while qualitative data were expressed as number and percentage. We checked the normality of continuous data using Shapiro Walk test. We used paired Student's t-test to compare VAS for back pain, VAS for radical pain before and after operation. Unpaired Student's t-test was used to compare surgical outcomes between both groups. Chi square test was used to examine the differences between categorical variables. P-value was considered significant if < 0.05 .

RESULTS

The present trial included 40 subjects with various degrees of Spondylolisthesis; They were divided into 2 main groups: group A : TPF (Transpedicular fixation) and group B: TPIF (Transpedicular with interbody fusion).

The mean age of group A was 57.85 ± 5.49 years ranging between 46 and 60 years. However, the mean age of group B was 56.55 ± 6.63 years, ranging from 44 to 67 years.

Out of 20 patients in group A, 14 (70 %) patients were females, and the others were males. While in group B there were 13 (65 %) females, and the others were males.

Only one patient in our study had two levels of spondylolisthesis in group A. while all patients in group B had only one level of listhesis.

In group A only two patients had Grade II listhesis, and the others had Grade I listhesis. While in group B only one patient has Grade II listhesis and other patients had Grade I listhesis.

In group A the mean preoperative back pain visual analogue score (VAS) was 7.25. The same as in group B. The mean preoperative leg (VAS) of the

studied patients in group A was 5.2. While patients in group B had mean score 4.75. the mean preoperative ODI of the studied patients in group A was 72.4 while in group B it was 78.7 .In addition, there was significant decrease in VAS and ODI at 3 months postoperatively (table2).

In group A, estimated blood loss was 567.5 cm³ which is lower than that in group B 800 cm³.In the group A, there was only one patient (5%) had a dural tear, on the other hand the group B had five complications (20%): three dural tears, one (5%) root injury and one deep wound infection.

As regard the postoperative fusion rate, in group A 14 (70%) out of total 20 patient achieved grade II, however the remaining six patients (30%) achieved grade III and no patients achieved grade I. On the other hand, nine patients (45%) in group B achieved grade I, 11 patients (55%) achieved grade III.

Case presentation:

Figures 1 and 2 represented pre- and post-operative images for a 48 year old female patient with history of slowly progressive back pain and bilateral claudication pain with failure of conservative measures more than 6 months. Pre-operative x-rays and MRI were done showing L4-L5 Spondylolysthesis.

Patient underwent L4-5 fixation with pedicle screws with interbody fusion by PLIF cage.

The patient improved clinically as determined by ODI and VAS for back and leg pain. Post-operative x-rays of lumbar spine was done showing rods and screws and cage in the proper site with no post-operative instability

Parameters	TPF n=20	TPIF n=20	P-value
Age (years)	57.85± 5.49	56.55 ± 6.63	0.503
Range	(46-60)	(44-67)	
Gender			
Female	14 (70.0)	13 (65.0)	1.000
Male	6 (30.0)	7 (35.0)	
Number of levels			
One level	19 (95.0)	20 (100.0)	1.000
Two level	1 (5.0)	0 (0.0)	
Grade of spondylolisthesis			
Grade I	18 (90.0)	19 (95.0)	1.000
Grade II	2 (10.0)	1 (5.0)	
Pre-VAS for BP	7.25 ± 1.02	7.25 ± 0.85	1.000
Pre-VAS for RP	5.20 ± 0.70	4.75 ± 0.64	0.040*
pre ODI	72.40 ± 6.41	78.70 ± 8.37	0.011*

Table 1: Demographic and Clinical Characteristics of Patients. TPF, trans pedicular fixation; TPIF, transpedicular with interbody fusion; VAS, visual analogue scale; ODI, Oswestry Disability Index. Data expressed as mean ± SD, frequency (percentage). *P value was considered significant if < 0.05

Parameters	TPF n=20	TPIF n=20	P-value
Blood loss (cm ³)	567.50 ± 92.16	800.00 ± 81.11	<0.001*
Change in VAS for BP	5.15 ± 0.75	4.55 ± 0.69	0.012*
Change in VAS for RP	4.60 ± 0.50	4.15 ± 0.37	0.003*
ODI change	42.80 ± 5.33	45.20 ± 4.79	0.142
Postoperative complications	1 (5.0)	5 (20.0)	
Dural tear	1 (5.0)	3 (15.0)	
Wound infection	0 (0.0)	1 (5.0)	0.325
Root injury	0 (0.0)	1 (5.0)	
Postoperative fusion rate			
Grade I	0 (0.0)	9 (45.0)	
Grade II	14 (70.0)	11 (55.0)	<0.001*
Grade III	6 (30.0)	0 (0.0)	

Table 2: Comparison of surgical outcomes between TPF and TPIF. TPF, trans pedicular fixation; TPIF, transpedicular with interbody fusion; VAS, visual analogue scale; ODI, Oswestry Disability Index; BP, back pain; RP, radical pain. Data expressed as mean ± SD, frequency (percentage). *P value was considered significant if < 0.05.

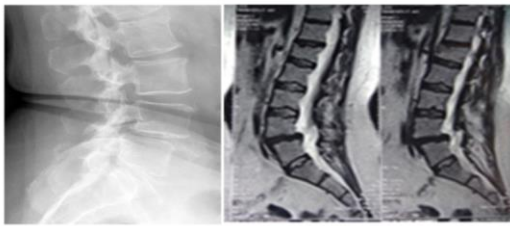


Fig 1: Preoperative x-rays & MRI of 48 years old female with L4-5 degenerative type 1st degree spondylolisthesis.

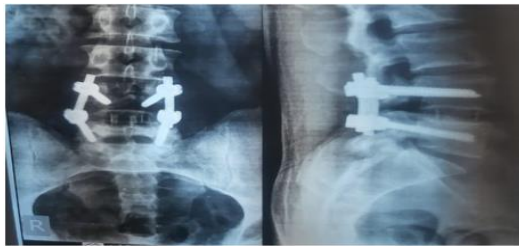

Fig 2: Post op PXR AP & LAT views post operative showing fixation with pedicle screws with interbody fusion by PLIF cage.

DISCUSSION

Results of the present study revealed female sex predominance, and the majority were females 67.5%.

Ghogawala et al.⁹ reported in his study female ratio (68%) and male ratio (32%) which is near to our study results.

The mean age in our study was 57.85 years in group A and 56.55 years in group B, which is lower than the mean age of other similar studies. Jacobsen et al.¹⁰ reported a mean age of 68 years in men and 71 years in women.

In our study VAS was 7.25 in both groups. Kim et al.¹¹ reported VAS for back pain 7 which is near to our study results.

There was no difference between both groups in the improvement of leg pain VAS (0.6) with no significant difference comparing VAS scores between the two groups at postoperative follow-up. This agrees with Liu et al.¹² who reported that there is no significant difference was found in the term of postoperative back and leg VAS score.

In our study we found that the mean preoperative Oswestry Disability Index score (ODI) of the studied patients in group A was 72.4 while in group B it was 78.7 With high significant difference comparing both groups. This is slightly more Delawi et al.¹³ results which were 65. This is going in agreement with Rezk et al.¹⁴ study which reported the mean preoperative ODI 75.

In our study, in group A, there was only one patient (5%) had a dural tear, on the other hand group B had

five complications (20%): three dural tears, one (5%) root injury and one deep wound infection.

Moussa AA, et al.¹⁵ reported complications with TPIF in 5 subjects (25.0%); of those, CSF leak was reported in 2 subjects, represented 40% of all complications, mal-directed screw, slippage of the case, and secondary myelomeningocele (each in one case).

In our study the mean intraoperative blood loss of the studied patients in group A was found to be 567 ml. While in group B was found to be 800 ml. McAfee et al.¹⁶ reported that, the average blood loss in posterolateral fusion was 280 ml compared to 450 ml blood losses in interbody fusion group.

In our study, 70 % of group A achieved grade II fusion, however the remaining 30 % patients achieved grade III and no patients achieved grade I. On the other hand, 45 % patients in group B achieved grade I and 55% patients achieved grade III.

Rao et al.¹⁷ agree with our study as he found that the interbody fusion was advantageous for increasing the fusion rate and obtained early stability and high rate of fusion following PLIF with the use of pedicle screws for fixation than using posterior lateral screw fusion alone.

CONCLUSION

Spondylolisthesis is managed mainly surgical in case of failure of conservative treatment. Transpedicular fixation by screws with and without interbody fusion give the same results regarding postoperative clinical improvement and patient satisfaction, with more money cost, intraoperative blood loss, and complications with interbody fusion, however PLIF still have better fusion rates specially at the earlier duration of follow up.

REFERENCES

1. Vogt MT, Rubin D, Valentin RS, et al. Lumbar olisthesis and lower back symptoms in elderly white women: the study of osteoporotic fractures. *Spine*. 2003; 23: 2640-7.
2. Wiltse LL, Newman PH and Macnab I. Classification of spondylolysis and spondylolisthesis. *ClinOrth*. 1976; 117: 23-29.
3. Kalichman L, Kim DH, Li L, et al. Spondylolysis and spondylolisthesis: prevalence and association with low back pain in the adult community-based population. *Spine*. 2009; 34(2):199-205.
4. Wiltse LL, Newman PH and Macnab I. Classification of spondylolysis and spondylolisthesis. *ClinOrth*. 1983; 117: 23-9.
5. Min JAA, Hadenspeck KA and Schultz AB: Posterior element loads in lumbar motion segments. *Spine*. 2007; 8: 331-7.

6. Weinstein, Mummaneni P and Haid R. Current Treatment Strategies for the Painful Lumbar Motion Segment: Posterolateral Fusion Versus Interbody Fusion. *Spine*. 2007; 30: 33-43.
7. Herron LD and Trippi AC. L4-5. degenerative spondylolisthesis. The results of treatment by decompressive laminectomy without fusion. *Spine*. 1989;14: 534-8.
8. Alexander E, Kelly DL, Davis CH, et al. Intact arch spondylolisthesis. A review of 50 cases and description of surgical treatment. *J Neurosurg*. 1995; 63: 840-4.
9. Ghogawala Z, Dziura J, Butler W.E, et al. Laminectomy plus fusion versus laminectomy alone for lumbar spondylolisthesis. *N Engl Med* 2016; 374: 1424-34.
10. Jacobsen S, Sonne-Holm S, Røvsing H, et al. Degenerative Lumbar Spondylolisthesis: An Epidemiological Perspective. *The Copenhagen Osteoarthritis Study*. *Spine*. 2007; 32:120 –5.
11. Kim JS, Kim DH, Lee SH, et al. Comparison study of the instrumented circumferential fusion with instrumented anterior lumbar. *World Neurosurg*. 2010; 73: 565-571.
12. Liu X-Y, Qiu G-X, Weng X-S, et al. What is the Optimum Fusion Technique for Adult Spondylolisthesis—PLIF or PLF or PLIF Plus PLF? A Meta-analysis From 17 Comparative Studies. *Spine*. 2014; 39 (22): 1887-98.
13. Delawi D, Dhert WJ, Castelein RM, et al. The incidence of donor site pain after bone graft harvesting from the posterior iliac crest may be overestimated 2007: a study on spine fracture patients. *Spine*. 32:1865–8.
14. Rezk EMA, Elkholy AR and Shamhoo EA. Transforaminal lumbar interbody fusion (TLIF) versus posterior lumbar interbody fusion (PLIF) in the treatment of single-level lumbar Spondylolisthesis. *Egypt J Neurosurg*. 2019; 34(26): 6.
15. Moussa AA, Ali MS and Galal M. Outcome of transpedicular screw fixation with Posterior Interbody Fusion in Management of Spondylolisthesis. *IJMA*. 2020.; 2(2): 358-64.
16. McAfee P, DeVine J, Chaput C, Prybis B, et al. The Indications for Interbody Fusion Cages in the Treatment of Spondylolisthesis: Analysis of 120 Cases. *Spine*. 2005; 6: 60-65.
17. Rao G, Abdul Azeez Q and Kumar S. Evaluation of the clinico-radiological outcome of lumbar interbody fusion using cage and local bone graft in management of lumbar spondylolisthesis. *International Journal of Orthopaedics Sciences*. 2018;4(4):814-22.