

***Role of Fucus Vesiculosus L. Alga in Promoting  
Thyroid Function in Experimental Rats***

***Ghada Mohammed El-Zeny El-Mansy<sup>1</sup>,  
Zainab Abdul-Wahhab Salem<sup>1</sup>  
and Amira Lotfy Abd El-Raof Abd-Allah<sup>1</sup>.***

<sup>1</sup>Nutrition and Food Science Department, Faculty of Home  
Economics, Al-Azhar University, Egypt.

***Abstract***

Background: Fucus Vesiculosus is one of the Laminariales that belong to the family of seaweed. It has a long history of use as food and medication due to its biological properties. Fucus are a very valuable precious food sources with high nutritional value and low in calories because of the lower content of lipids and polysaccharides.

Aim: The study has been conducted to identify the preventive role and positive effects of the seaweed Fucus Vesiculosus and its role to minimize the side effects of Propylthiouracil (PTU) on the function and structure of the thyroid gland.

***Materials and Methods***

In this study, 42 white male rats have been used. (weighting  $160 \pm 10$  g) were divided into 2 main groups, the first group is the negative control group (n= 6 rats) was fed on basal diet for (35 days) and the second main group is an experimental group (n= 36 rats) and this group was fed on a basal diet with received daily oral dose of propylthiouracil (15mg/kg body weight) by gastric tube for (17 days) to induce hypothyroid, then was further subdivided into 6 subgroups

**Ghada Mohammed , Zainab Abdul-Wahhab Salem  
and Amira Lotfy Abd El-Raof Abd-Allah .**

---

(n= 6 rats each group); the 1st group (positive control group) was fed on the basal diet for (18 days); the 2nd group (drug Levothyroxine) was fed on a basal diet plus received a daily oral dose of levothyroxine (10mc /kg body weight) by gastric tube for (18 days); the 3rd group (D+F 2.5%) was fed on a basal diet containing dried fucus (25 g/kg body weight) and received a daily oral dose of levothyroxine (5mc /kg body weight) by gastric tube for (18 days); the 4th group (D+F 5.0% ) was fed on a basal diet containing dried fucus (50 g/kg body weight) and received daily oral dose of levothyroxine (5mc /kg body weight) by gastric tube for (18 days); the 5th group (F 2.5%) was fed on a basal diet containing dried fucus (25 g/kg body weight) for (18 days) : and the 6th group (F 5.0%) was fed on a basal diet containing dried fucus (50 g/kg body weight) for (18 days). The intervention continued for 35 consecutive days.

## ***Results***

The results showed that there is no significant difference between rats treated with fucus (50 g/kg) + drug (5mc/kg), and (-ve) normal control group in weight gain .

Hormone tests results show that there is a significant increase in the level of (FT3 and FT4) hormones and a decrease in TSH hormone in the group treated by *Fucus Vesiculosus*. Also, liver enzyme shows a significant decrease when compared with the control group. The level of kidney function of treated rats decreased significantly than the corresponding values of the control group.

**Keywords:** Laminariales ,thyroid gland, propylthiouracil, levothyroxine, seaweed, hypothyroidism

## ***Introduction***

The thyroid gland constitutes an important component of the endocrine system that regulates several physiological functions ranging from oxygen utilization, growth and development to cellular metabolism (***Singh et al.,2021***). Thyroid hormones (TH) regulate the essential metabolic process to normal growth and development, they also regulate the organism's metabolism, correlating the body weight and the expenditure of energy (***Gnocchi et al., 2016***).

The prevalence of these thyroid disorders varies widely according to geographical distribution, diet and nutrition and patient population. The occurrence of hypothyroidism in India is 11%, compared with only 2% in the UK and 4.6% in the USA. In countries with enough iodine in the diet, the most common cause of hypothyroidism is the autoimmune condition Hashimoto's thyroiditis. Less common causes include the following: previous treatment with radioactive iodine, injury to the hypothalamus or the anterior pituitary gland, certain medications or previous thyroid surgery (***Abid et al., 2016***).

Even as the global prevalence of iodine deficiency disorders as estimated by the total goiter rate has fallen from 13.1% to 3.2% over the past 25 years, it still constitutes a significant thyroid problem even in developed countries. An estimated 4.8 million newborns were expected to be affected by iodine deficiency with its consequences of life-long productivity losses in the USA alone (***Gorstein et al.,2020***).

Propylthiouracil (PTU) inhibits the production of new thyroid hormones in the thyroid gland. It acts by inhibiting the enzyme thyroid peroxidase, which usually converts iodide to an iodine molecule and incorporates the iodine molecule into amino acid tyrosine (***Amisha and Rehman ,2021***).

**Ghada Mohammed , Zainab Abdul-Wahhab Salem  
and Amira Lotfy Abd El-Raof Abd-Allah .**

---

The common side effects are timidity, nausea, vomiting, burn, taste loss, numbness, headache, allergy, hair whitening, aplastic anemia, and leukopenia. Also, other symptoms include agranulocytosis and infections of the throat, digestive system, and skin with fever and decrease of blood platelets, which have an important role in blood coagulation(**Seneret et al., 2006**).

For the treatment of hypothyroidism the levels of thyroid hormones should be elevated to normal levels. The common way is the replacement of them with the administration of “levothyroxine”( **Mistry et al., 2011**). Besides levothyroxine, some medications like supplementations or plants are used to help the treatment of hypothyroidism.

These components could decrease the peripheral hypothyroidism symptoms or increase the production of related hormones (**Anaraki et al.,2017**)

Although the well-known hypothyroidism medication, levothyroxine, shows an excellent efficacy, it causes different side effects like tachycardia, heat intolerance and tremor .So, the use of medicinal plants instead of levothyroxine, or along with it, in treatment of hypothyroidism for better outcome or decrease of its side effects, is attractive for the researchers (**Ernst ,2005**).

It has been shown that some plants like *Fucus vesiculosus* improve hypothyroidism by involving different mechanisms .*Fucusvesiculosus* is one of the *Laminariales* that belong to the family of seaweed and one of the richest in polyphenols ( **Bogolitsyn et al., 2020**). It has a long history of use as food and medication due to its biological properties.

It is considered one of the natural antioxidants, which prevents free radicals (**Song et al., 2000**). It prevents tumors, motivates the lipase enzyme, minimizes cholesterol levels, maintains blood sugar levels, activates, enhances heart metabolism and stimulates the thyroid gland (**Mayer et al., 2011**).

Fucus contains a natural source of Iodine, algin, mucilage, bromine, sodium, potassium, lutein, zeaxanthin, chlorophyll, cellulose, mannitol, silicon, essential fatty acids, vitamin C, B-vitamins, beta-carotene ,zinc, magnesium, selenium, manganese ,iron ,phosphorus ,iodide , oleic acid, polyphenols, protein, fiberand high in phytochemicals (**Dean-Green, 2012**).

These health-promoting plant compounds, which include phlorotannins and fucoxanthin, may help lower oxidative stress and imbalance between free radical and antioxidant levels in your body (**Yoo et al., 2018**).

Fucus is high in fiber which can support a healthy gut. In particular, it's high in alginic acid and fucoidans, which have both been shown to have health-promoting properties (**Afonso et al., 2019**).

In traditional medicine, fucus became very popular mainly due to their high content in iodine, which renders them remarkable therapeutic properties for treating goiter, i.e., the swelling of thyroid and thyroid-related complications, and obesity (**Küpperet al., 2011**).

The present study is going to evaluate the nutritional and therapeutic effects of *Fucus vesiculosus* on the level of thyroid hormones in Propylthiouracil - induced hypothyroid.

**Ghada Mohammed , Zainab Abdul-Wahhab Salem  
and Amira Lotfy Abd El-Raof Abd-Allah .**

---

## ***Materials and Methods***

### **Materials:**

#### **Fucus Vesiculosus:**

*Fucus vesiculosus* algae were obtained from Kunuz EL-Tabieih Company, Alexandria, Egypt.

#### **Propylthiouracil and Levothyroxine:**

Propylthiouracil (PTU) was purchased from Sedico, Pharmaceutical Co., 6<sup>th</sup> October City, Egypt. Each tablet contains 50 mg of PTU. The tablet was dissolved in 10ml water, and each rat received 15 mg/kg body weight from PTU via stomach tube according to (***Hatem and AL-Mayali, 2018***). Levothyroxine was purchased from Sedico, Pharmaceutical Co., 6<sup>th</sup> October City, Egypt. Each tablet contains 50 mcg of levothyroxine.

### **Animals**

Forty Two healthy adult male albino rats "Sprague Dawley" strain weighing 160 ±10 g were purchased from the Animal House Colony of the National Research Center, Dokki, Cairo, Egypt. Rats were kept in single wire cages with wire bottoms under hygienic conditions. The diet was introduced to the rats in special food containers to avoid scattering of food and water supply was given ad-libitum. Food and water were checked daily.

### **Diet materials**

Casein (85%), Vitamins mixture and salt mixture were obtained from El-Gomhoryia Company for Chemical Industries, Cairo, Egypt. Bran, corn starch and corn oil were purchased from the local market.

**Methods:**

**Preparation of algae:**

It was purchased in dry form and purified from impurities then ground using a blinder into a fine powder and were kept separately in dark glass containers in a refrigerator till use.

**Determination of proximate composition of the dried algae:**

Moisture, crude fiber, ash, protein and fat contents of dried *Fucus vesiculosus* were determined according to the Association of Official Analytical Chemists, (**AOAC, 2010**) at Central lab. of Food Technology Research Institute Agric. Res. cent. Egypt. Total carbohydrate was calculated by difference using the following equation:

**Total carbohydrate** = 100- (%moisture + %fat+ %ash + %crude fibers + %protein)

**Fractionation and determination of phenolic compounds:**

The polyphenolic compounds of algae extract will be fractionated and identified for phenolic compounds by HPLC, according to the method of (**Goupy et al., 1999**) at Central lab. of Food Technology Research Institute Agric. Res. cent. Egypt.

**Iodine content:**

Iodine content was determined according to the method described by (**Kirkbright et al., 1974**) using Atomic absorption spectroscopy.

**Selenium content:**

Selenium content was determined according to the method described by (**Walkinson, 1966**) using minifluorometer (mode TD-360, Turner Design, Sunnyvale, CA, USA ).

**Preparation experimental diet:**

The Basal diet was prepared from fine ingredients per 100g. The diet had the following composition: casein ( $\geq 80\%$  protein) 14% ,Corn oil

**Ghada Mohammed , Zainab Abdul-Wahhab Salem  
and Amira Lotfy Abd El-Raof Abd-Allah .**

---

4%, Bran 4%, mineral mixture 4 % mixture according to (*Hegstedet al., 1941*), vitamin mixture 1% according to (*Campbell,1963*),DL-methionine 0.3L% and corn starch up 100g (*Reeves et al., 1993*).

**Experimental Design:**

Rats (n = 42 rats) were housed individually in wire cages at a room temperature maintained at  $25 \pm 2$  °C and kept under normal healthy conditions. All rats (42 rats) were fed on a basal diet for one week before starting the experiment for adaptation. After this week, they were divided into two main groups:

**The first main group (6 rats)** : normal rats fed on basal diet only as a negative control group for 35 days.

**The second main group( 36 rats)** : fed on a basal diet with received daily oral dose of propylthiouracil (15mg/kg body weight) by gastric tube for (17 days) to induce hypothyroid state according to (*Hatem and AL- Mayali, 2018*) . A sample was taken from the eyes of rats at the end of the seventeenth day to confirm the occurrence of hypothyroidism. TSH, FT4 and FT3 were determined to ensure the hypothyroidism. Afterward, administrated rats (n=36) were divided into 6 equal groups (6 rats) as follows:-

**Subgroup (1):** Rats were fed on a basal diet only and kept as a positive control group without any treatment.

**Subgroup (2):** Rats were fed on a basal diet and received a daily oral dose of levothyroxine (10mc /kg body weight) by gastric tube for (18days).

**Subgroup (3):** Rats were fed on a basal diet containing *F. vesiculosus* algae powder (25g/kg body weight) and received a daily oral dose of levothyroxine (5mc /kg body weight) by gastric tube for (18days).

**Subgroup (4):** Rats were fed on a basal diet containing *F. vesiculosus* algae powder (50g/kg body weight) and received a daily



oral dose of levothyroxine (5mc /kg body weight) by gastric tube for (18days).

**Subgroup (5):** Rats were fed on a basal diet containing *F. vesiculosus* algae powder (25g/kg body weight) for (18days).

**Subgroup (6):** Rats were fed on a basal diet containing *F. vesiculosus* algae powder (50g/kg body weight) for (18days).

**Biological evaluation:**

At the end of the experiment, feed intake (FI), body weight gain % (BWG%) and feed efficiency ratio (FER) were calculated. According to (**Chapman et al., 1959**), body weight gain and feed efficiency ratio were calculated using the following equations:

**Feed intake**=Initial diet weight (g) –left over diet weight (g)

**Weight Gain (g)** = Final weight (g) – initial weight (g)/ 35

**BWG %**= Weight Gain (g) / initial weight (g) ×100

$$\text{Feed Efficiency Ratio} = \frac{\text{Gain in body weight (g)}}{\text{Feed intake (g)}}$$

**Biochemical analysis of serum:**

At the end of the experiment, the rats were fasted overnight before being sacrificed under ether anesthetized and blood samples were collected from the hepatic portal vein. Each sample was placed in a dry clean centrifuge tube, then centrifuged for 10 minutes at 3000" r. p. m "to separate the serum. Serum was carefully separated into dry clean Wasserman tubes using a Pasteur pipette and kept frozen at-20°C till analysis

**Blood samples were used to estimate the following parameters concentration:**

**1. Determination of the concentration of thyroid hormones:-**

**Ghada Mohammed , Zainab Abdul-Wahhab Salem  
and Amira Lotfy Abd El-Raof Abd-Allah .**

---

Free thyroxin (FT4), Free triiodothyronine (FT3) and thyroid-stimulating hormone (TSH) were estimated in the serum according to the method described by (*Shamsian et al., 2016*).

## **2. Determination of the activity of liver enzymes and kidney function :**

Glutamic oxalic transaminase (GOT), Glutamic pyruvictransaminase (GPT),alkaline phosphatase (ALP),Uric acid and Creatinine were determined according to the methods described by (*Reitman and Frankel ,1957*),(*Roy ,1970*),(*Fossati et al., 1980*) and (*Faulkner and King ,1976*), respectively.

### **Histopathological examinations:**

The Thyroid samples of sacrificed rats were taken and immersed in 10% formalin solution. The fixed specimens were then trimmed, washed and dehydrated in ascending grades of alcohol. Then they were, cleared in xylol, embedded in paraffin, sectioned at 4-6 microns thickness and stained with heamtoxylin and eosin for examining according to ( *Carleton ,1979*).

### **Statistical analysis:**

Statistical analysis was performed using the program of Statistical Package for the Social Sciences software (SPSS) version 18. The results were expressed as mean  $\pm$  Standard deviation (mean  $\pm$  S.D.). Data were analyzed using one-way ANOVA (*Snedcor and Cochran, 1979*).

## ***Results and discussion***

### **Chemical composition of *Fucus vesiculosus*.**

*Fucus vesiculosus* was analyzed for its chemical composition (moisture, protein, carbohydrates, fat, crude fiber and ash). The obtained results showed in Table (2) on the dry weight basis. It could be noticed that the moisture, protein, carbohydrate, fat, crude fiber and ash content in fucus were recorded (3.5 , 7.8 ,37.87 , 0.08, 15.26& 35.49%), respectively.

This is in agreement with previous findings (*Malyarenko et al., 2017*) who concluded that this high content in carbohydrates does not correspond to high caloric values though, since most of these consist of dietary fibers. Also the Proximate composition of fucus is very similar to that reported by (*Catarino et al., 2018*) who found that the fucus content of moisture, protein, carbohydrates, fat, crude fiber and ash recorded (71 to 84 ,1 to11, 34 to 66 ,1.2 to 4 , 4 to 59 and 23 to 36%), respectively. These results are in agreement with the data reported by Fleurence (*Lorenzo et al.,2017*), who also noticed low protein content (<15 g/100 DW) in *F. vesiculosus*.

**Determination of selenium and iodine:**Table (3) represented which mineral was found in fucus.It could be noticed that iodine and selenium content infucus were recorded (165 & 8 mg ), respectively. These results are in agreement with those of a previous study by (*Truus et al .,2004*) who found that the iodine content of fucus ranges from(130 to 165mg) .Also (*Laekeman,2014*) found that dry extract of fucus containing ranges from(87.5 to175mg) of iodine. While selenium content in fucus differs greatly from that reported by (*Balina et al., 2016*) .

This difference may be due to the method of determination, calculation or the fucus variety.

**Phenolic compounds of *Fucus vesiculosus* by HPLC analysis.**

Table (4) represented the phenolic compounds found in *Fucus vesiculosus* content of Pyrogallol ,Ellagic, Chlorogenic, Ferulic, Catechol, Gallic, Caffeic, Catechein, Coumarin, Vanillic ,Benzoic, Caffeine, and 4-Aminobenzoic.Their ratio (774.16 ,426.14 ,122.73,

**Ghada Mohammed , Zainab Abdul-Wahhab Salem  
and Amira Lotfy Abd El-Raof Abd-Allah .**

---

122.56, 59.55 ,39.26, 34.57 ,20.41 ,17.22 ,13.82 ,13.78 ,8.68 ,1.22mg/100g) ,respectively. These results are in relative agreement with (**Sumampouw et al., 2021**) who found that the HPLC data revealed that the majority of the *Fucus vesiculosus* had gallic, caffeic, chlorogenic, vanillic, and Ferulic acid as major phenolic acids ranging from 5.21 to 166.67 mg/100g.

Also (**Sánchez-Bonet et al., 2021**) found the characterization of the polyphenols present in a *Fucus vesiculosus* extract (FVE) was carried out and compared with reverse-phase high-performance liquid chromatography coupled to a diode array detector (HPLC-DAD). The following compounds were identified: Pyrogallol, gallic acid, catechin, vanillic acid, chlorogenic acid, caffeic acid, coumaric acid and ferulic acid.

#### **Biological effects:**

Table (5) cleared that FI of (+ve) control group was less than (-ve) control group (11.10 and 11.20 g/day, respectively), with no difference between them. All treated groups recorded no difference in FI when compared with the (-ve) group. The highest mean value of FI was recorded for the group treated with the high level of fucus (50 g/kg) + drug (5mcg/kg) which was recorded (11.23 g/day).

Results of BWG% recorded increase in positive (+ve) control group when compared to normal rats (-ve) (0.47 and 0.19, respectively), all treated groups showed slightly decrease in BWG from 0.21 to 0.35 of (+ve) control group. The best result was recorded for the group treated with the high level of fucus (50 g/kg) + drug (5mcg/kg) which was less than the positive control group with (55.3%).

Results of FER recorded a significant increase in (+ve) control group, when compared (-ve) group (0.08 and 0.03, respectively), all

treated groups showed a decrease in FER from (0.04 to 0.06), when compared with (+ve) group. Simeller to negative control group, the best result of FER was recorded for the group treated with the high level of fucus (50 g/kg) + drug (5mcg/kg), which recorded (-62.5%) than the positive control group .

These results concurred with the finding of *Korukantiet al., (2013)* they reported that *F.vesiculosus* treatment prevented the rats from becoming obese and the biochemical and physical parameters were maintained to normal levels, the body weight significantly increased due to the accumulation of fat in the body and the *Fucus vesiculosus* exhibited its protective nature in rats by preventing their weight gain. Also, agree with *(El-Shaer et al., 2021)* who found that obese rats treated with *Fucus vesiculosus* powder (2.5 and 5%) and alcoholic extract (1ml and 2ml) showed lower values in FI as compared with the control positive group. .Also, rats treated with the levels of *Fucus vesiculosus* powder (2.5 and 5%) and alcoholic extract (1ml and 2ml) showed decreases in mean values of BWG% compared with the control positive group.

### **Biochemical parameters:-**

#### **1-Thyroid hormones**

Table (6), illustrate the thyroid hormones for controls and treated groups. Results of FT4 showed that the (-ve) control group recorded 144.76% over than (+ve) control group. While drug levothyroxine treated group recorded a significant increase in FT4 (81.90%) as compared to (+ve) control group.

All experimental groups treated with fucus had a significant increase in FT4 ranging from( 46.66 to 135.23 % )of (+ve) control. The best result was recorded for the group treated with the high dose of fucus (50 g/kg) + drug (5mcg/kg), which recorded the nearest value of FT4, for the normal control group.

**Ghada Mohammed , Zainab Abdul-Wahhab Salem  
and Amira Lotfy Abd El-Raof Abd-Allah .**

---

Results of FT3 in Table (6) show that the mean value of the (-ve) control group revealed 181.52% over than (+ve) control group, with a significant difference between them. While the drug levothyroxine treated group recorded a significant increase in FT3 (92.39%) as compared to (+ve) control group, as well experimental groups treated with fucus showed significant increases in FT3 ranging from (21.19% to 154.89%) of (+ve) control. The best result was recorded for the group treated with the high dose of fucus (50 g/kg) + drug (5mcg/kg), which was the nearest value of the normal control group.

Also, Table (6) clear that the TSH of (-ve) control group recorded (-91.30%) less than (+ve) control group, with a significant differences between them. Likewise levothyroxine treated group showed a significant decrease in TSH activity (-60.86%). Feeding rats on fucus led to a significant reduction in TSH values than (+ve) control group. The best result was recorded for the group treated with the high level of fucus (50 g/kg) + drug (5mcg/kg), which recorded a non-significant difference with (-ve) group.

**(Ilyas, 2015)** found that there is a significant decrease in T3 and T4 levels in the blood serum of rats treated with Propylthiouracil (PTU). The reason for T3 and T4 is attributed to PTU that leads to disorder of thyroid gland and inhibits thyroid peroxidase and 5-deiodinase and these are basic enzymes to make thyroid hormones. The inhibition of making these enzymes decrease the levels of thyroid hormones diffusion and eventually increases of TSH hormone. This increase of TSH stimulates thyroid gland growth, and this leads to its enlargement **(Hatem and AL-Mayali., 2018)**.

**Also, (Ali et al., 2012)** and **(Sabr ,2015)** suggested that loss of thyroid hormones, most probably caused by loss of thyroxin binding globulin along with T4 bound to it, thus stimulating TSH

production. Additionally, **(Alfallouji et al. 2012)** suggested that hypothyroidism syndrome is associated with an overall increase in oxidative stress. Other than the decrease in thyroid function due to oxidative stress, loss of thyroid hormone-binding proteins in urine could be another cause of the decrease in serum T3 and T4 levels.

These results are in agreement with those of a previous study **(Hameed et al., 2014)**, which concluded that the use of algae extracts may regulate the thyroid hormones levels and improve the function of the thyroid gland in sera of hypothyroidism animals. The above results may be due to the effects of *F. vesiculosus*, which is rich in iodine and that might help in the metabolism of thyroid hormones **(Bradley, 1992)**. The thyroid gland actively absorbs iodine; it combines iodine with tyrosine in enzymatic reactions to synthesize thyroxine and triiodothyronine, the active thyroid hormone. Also, *F. vesiculosus* is rich in fucoidan and polyphenols (phlorotannins), both of which showed powerful antioxidant and anti-inflammatory activities and inhibited lipid peroxidation **(Gupta, and Abu-Ghannam, 2011)**.

Also, **(Hatem and AL-Mayali., 2018)** found that there was a decrease in TSH levels in the blood serum of rats that given *Fucus vesiculosus*. The possible reason for TSH decrease could be the inhibition of negative feedback because of the high concentration of T3 and T4, which are shown in that study, prevent the secretion of TSH from the pituitary gland. The increase of T3 and T4 in their study is attributed to other interactions of medications especially those that include iodine, which affects the structure and function of thyroid gland hormones **(Steinmaus et al., 2007)**.

*Fucus vesiculosus* action also reduces hypothyroidism and improved tissue to contain flavonoids that reduced oxidative stress and raised the level of antioxidants in the body **(Elst et al., 1991)**.

Additionally, **(Hameed et al., 2020)** found that the oral administration of *F. vesiculosus* for four weeks indicated that the

**Ghada Mohammed , Zainab Abdul-Wahhab Salem  
and Amira Lotfy Abd El-Raof Abd-Allah .**

---

levels of T3 and T4 were increased, while the level of TSH was decreased. Their results indicated that the highest T3 and T4 increases were of ( 21 and 4%), respectively, for 150mg/kg of the same treatment, while the highest TSH reduction was by 13% for 150mg/kg treatment, as compared with the control treatment. The reason is that fucus vesiculosus is rich in biological compounds as polysaccharide, polyphenolic, antioxidants and phlorotannins in addition to mannitol, alginate, iodine and fucoidan (**Abdelkadder et al.,2015**) .

## **2-Liver function**

Table (7) showed that the mean value of the AST (U/L) of the (-ve) control group showed ( -39.31%) less than the (+ve) control group, with a significant difference between them. Also levothyroxine treated group recorded a significant decrease in AST activity (-29.84%).

The experimental groups treated with fucus (2.5% and 5%) revealed non-significant decreases in AST activity (-13.90% and -15.80%, respectively) of (+ve) control group, while the treatments with the different doses of fucus + levothyroxine groups recorded significant decreases in AST activity (-24.46% and -47.55%, respectively). The best result was recorded for the group treated with the high level of fucus (50 g/kg) + drug (5mcg/kg), which was lower significantly than (+ve) control group (-47.5%).

As for ALT activity (U/L) it could be observed that (-ve) control group showed (-32.55%) less than (+ve) control group, with a significant difference between them. Also levothyroxine treated group recorded non-significant decrease in ALT activity (-21.46%). The experimental groups treated with fucus only or (fucus+levothyroxine) revealed non-significant decreases in ALT activity ranging from (-0.56% to -23.73%) when compared with (+ve) control group.



On the other hand, it was observed that ALP (U/L) of (-ve) control group recorded -39.87% less than (+ve) control group, with a significant difference between them. Also levothyroxine treated group recorded significant decrease in ALP activity (-28.31%). The experimental groups treated with fucus (2.5% and 5%) revealed non-significant decreases in ALP activity (-0.82% and -9.94%), respectively of (+ve) control group, while the treatments with the different doses of fucus + levothyroxine groups recorded significant decreases in ALP activity (-26.96% and -35.50%, respectively). The best result was recorded for the group treated with the high level of fucus (50 g/kg) + drug (5mcg/kg).

These results are supported by the results published by **(Gabbia et al., 2020)**, They found that administration of *F. vesiculosus* and *A. nodosum* led to significant reductions in microvesicular steatosis and plasma biochemical, such as alanine aminotransferase (ALT), aspartate aminotransferase (AST), alkaline phosphatase (ALP), total and conjugated bilirubin, and triglycerides. Also, **(El-Shaer et al., 2021)** found Groups which was fed on high fat diet (20% animal lipid) supplemented in the basal diet for (4) weeks to induce obesity and treated with fucus powder and alcoholic extract decreased serum levels of GPT, ALP and GOT.

These results are in agreement with those of a previous study **(Hayashi et al., 2008)** who examined the effect of fucoidan extracted from *F. vesiculosus* on acute liver failure induced by a single injection of CCl<sub>4</sub>. Intraperitoneal injection of mice with CCl<sub>4</sub> increased biochemical markers of liver injury., serum AST and ALT had increased. Intravenous administration of fucoidan attenuated this elevation of serum AST and ALT. Notably, the injection of 50 mg/kg fucoidan restored serum AST and ALT to normal levels, the molecular mechanisms of fucoidan in hepatocytes and hepatic . Note that fucoidan has antifibrotic activity and that it is a promising lead for

**Ghada Mohammed , Zainab Abdul-Wahhab Salem  
and Amira Lotfy Abd El-Raof Abd-Allah .**

---

the development of anti-fibrotic agents. Identification of the molecular target and the active structure of fucoidan may lead to the development of novel anti-fibrotic agents. these findings suggest that fucoidan may be useful for treating hepatic fibrosis.

Also, **Li et al.,( 2016)** found that the effects of a fucoidan from *Fucus vesiculosus* on concanavalin A (ConA)-induced acute liver injury in mice. Pretreatment with fucoidan protected liver function indicated by ALT, AST by suppressing inflammatory cytokines, such as tumor necrosis factor alpha (TNF- $\alpha$ ) and interferon gamma (IFN- $\gamma$ ), where ALT, AST decreased after fucoidan from *Fucus vesiculosus* pretreatment .

In fact ,according to **(Saito et al., 2006)**, fucoidan can reduce hepatic fibrosis in an animal model , because it has many biological activities, including anti-coagulant, anti-thrombosis, anti-inflammatory, anti-liver failure, and anti-tumor activities biological activities, including anti-coagulant, anti-thrombosis, anti-inflammatory, anti-liver failure, and anti-tumor activities.

### **3-kidney function**

Table (8) showed that the mean value of uric acid (mg/ dL) of (-ve) control group recorded -52.92% less than that of the (+ve) control group, with significant difference between them, also levothyroxine treated group showed significantly decreased in UA activity (-30.58%) of (+ve) control group. The experimental groups treated with fucus showed a significant reduction in UA activity ranging from -16.49% to -46.73% as compared to (+ve) control group. The best result was recorded for the group treated with the low dose fucus (25 g/kg) + drug (5mc/kg) followed by the high dose of fucus (50 g/kg) + drug (5mcg/kg), which revealed the nearest values of serum uric acid for the normal control group.

Results of serum creatinine (Create) (mg/ dL) in Table (8) revealed that (-ve) control group recorded-40.25% less than (+ve) control group, with a significant difference between them. While levothyroxine treated group showed a significant decrease in Create activity (-29.87%). The groups treated with fucus showed a significant reduction in Create activity ranging from (-6.49% to -29.87%) when compared with (+ve) control group, except the group treated with a low dose of fucus (2.5%). The best result was recorded for the group treated with a low dose of fucus (25 g/kg) + drug (5mcg/kg) and levothyroxine group.

These results were agreed with those of (*AlKahtane et al., 2020*) who found that mice treated with fucoidan from *Fucus vesiculosus* at 100 mg/kg/day for 21 days, exhibited comparable serum levels of liver injury biomarkers (AST, ALT, and ALP), renal injury biomarkers (urea and creatinine), LDH, cholesterol, and pro-inflammatory cytokines (IL-1 $\beta$ , IL-6, and TNF- $\alpha$ ) to mice in the control group. This improvement may be due to the antioxidant effect of fucoidan.

Many studies have referred to *Fucus vesiculosus* contains fucoidan, which is a polysaccharide and includes superoxide and hydroxyl roots that inhibit lipid peroxide the reason for tissue changes (*Parys et al., 2010*).

(*Wang et al., 2019*), found also efficacies were reported for fucoidan in the amelioration of acute kidney injury and diabetic nephropathy. This improvement is due to the presence of anti-inflammatory and antioxidants effects in the fucoidan.

### **Histological results.**

The present study results show that there are morbid tissue changes in the thyroid gland of male rats that are treated with *Fucus*

**Ghada Mohammed , Zainab Abdul-Wahhab Salem  
and Amira Lotfy Abd El-Raof Abd-Allah .**

---

*vesiculosus* and propylthiouracil (PTU). When examining tissue sections of the thyroid gland of normal control group (1) showing well-formed, tightly packed follicles separated by narrow interfollicular tissue, which contains connective tissues with blood capillaries and clusters of interfollicular cells rounded follicles showing the follicles (F).

The follicles are of various sizes and tend to be larger towards periphery. The follicles are lined by simple low cuboidal cells (black arrow) with round nuclei. The lumina of the central follicles are filled with homogeneous acidophilic structureless colloid having peripheral minute vacuolation (blue arrows)

**(Photos G.1).**

On the other hand, thyroid gland of rats positive control group (2) showing many histopathological changes including disorganized thyroid parenchyma and highly congested blood vessels (red arrows). Many follicles show small lumina (yellow arrows) or become obliterated by hyperplasia and hypertrophy of lining epithelium (circles) with little (black arrows) or no (green arrows) colloidal material compared to control. Lining epithelium is mostly high cuboidal cells containing hyperchromatic nuclei (blue arrows). Some of the follicular cells exhibited apparent cytoplasmic vacuolation (blue arrowheads). Both follicular cells and the interfollicular cells revealed moderate hyperplasia (blue arrows)

**(Photos G.2).**

Moreover, thyroid gland sections of the treated group with levothyroxine drug (3) showing larger follicles (black arrows) compared to untreated group (2). Few follicles have irregular walls (blue arrows) with mild follicular cells and interfollicular cells hyperplasia (circles)

**(Photos G.3).**

Mean while, thyroid gland sections of the treated group with (D+F 2.5%) (4) showing larger follicles than follicles in treated group 5 and only few follicles have irregular walls (blue arrows)

**(Photos G.4).**

Interestingly, thyroid gland of treated group with( D+F 5.0%) (5) showing diffuse hyperplasia of follicular and interfollicular cells (asterisk). The follicles are smaller than follicles in treated groups with 3,6,7 and having irregular walls (blue arrows) with decrease amount of eosinophilic colloidal material (green arrows)

**(Photos G. 5).**

Meanwhile, thyroid gland sections of the treated group with low dose of tested fucus 2.5% (6) showing some small hyperplastic follicles (circle) having small lumina. Few Follicles have irregular walls (blue arrows). Some follicles have more eosinophilic colloidal material (green arrows)

**(Photos G.6).**

While thyroid gland sections of the treated group with high dose of tested fucus 5.0% (7) showing larger follicles (black arrows) compared to untreated group (2) and moderately congested blood vessels (red arrows). Few follicles have irregular walls with mild follicular cells and interfollicular cells hyperplasia (circles).Some follicles have more eosinophilic colloidal material (green arrows)

**(Photos G.7)**

These results concurred with the finding of **(EL-Tantawi and Abozeid.,2019)**There were many histopathological changes in all treated groups. Thyroid tissue of the induced hypothyroid group (G2) rats treated orally with 50 mg/ kg body Wt./day of Propylthiouracil showed less well-rounded thyroid parenchyma. The thyroid follicles were disorganized with irregular follicular walls and highly congested blood capillaries. The thyroid follicles appeared with empty lumina,

**Ghada Mohammed , Zainab Abdul-Wahhab Salem  
and Amira Lotfy Abd El-Raof Abd-Allah .**

---

lined mostly with high cuboidal cells containing hyperchromatic nuclei. Some of the follicular cells exhibited apparent cytoplasmic vacuolation.

Also, Both follicular cells and the interfollicular cells revealed moderate hyperplasia. Also (**Hatem andAL-Mayali., 2018**) found When examining tissue sections of the thyroid gland of the control group dyed with hematoxylin and eosin. The natural structure of gland tissues shows that it includes rounded or oval follicles lined with cubic epithelial cells. Also, these follicles are full of colloid, which shows the natural activity .

The animals in the first treatment (T1) that are given *Fucus vesiculosus* for 42 days with 35 mg/ kg concentration of body weight, the tissue examination of thyroid gland sections of (T1) show that there are no tissue deformations with good response to *F.vesiculosus* that causes the growth of several follicles of different sizes that do not contain colloid or have colloid.

This is an indication of the natural function of the thyroid gland. Then the tissues are compared with the control group, which showed that there approximate similarity for the normal tissues of the control group.

## **Conclusion**

It can be said that the use of *Fucus Vesiculosus* L. alga singly or with levothyroxine improved both the level of thyroid hormones, liver and kidney functions ,This may be due to the high content of phenolic compounds content, iodine antioxidants and inflammatory substances .So, patients who suffering from hypothyroidism can use this algae either individually or as a dietary supplement with

levothyroxine drug (which is the best) for enhancing their thyroid hormones and health status.

**Table (1):** Composition of basal diet and experimental diets for normal and Hypothyroidism rats .

Group Items	Controls			Fucus (25 g/kg)		Fucus (50 g/kg)	
	(-ve)	(+ve)	Drug	F 2.5%	D+F 2.5%	F 5%	D+F 5%
Casein	14	14	14	14	14	14	14
Corn oil	4	4	4	4	4	4	4
Bran	4	4	4	4	4	4	4
Salt mix.	4	4	4	4	4	4	4
Fucus vesiculosus	—	—	—	2.5	2.5	5	5
Vitamin mix	1	1	1	1	1	1	1
Methionine	0.3	0.3	0.3	0.3	0.3	0.3	0.3
Corn starch	72.7	72.7	72.7	70.2	70.2	67.7	67.7

**Ghada Mohammed , Zainab Abdul-Wahhab Salem  
and Amira Lotfy Abd El-Raof Abd-Allah .**

Total	100	100	100	100	100	100	100
-------	-----	-----	-----	-----	-----	-----	-----

(-ve) Negative

(+ve) Positive

Drug. :treatment with Levothyroxine 10mcg /kg

D+F 2.5%: drug (5mcg/kg)+ fucus( 25g/kg)

D+F 5% :drug (5mcg/kg)+fucus (50 g/kg)

F 2.5%: fucus( 25g/kg)

F 5%: fucus (50 g/kg)

**Table (2):** Chemical composition of *Fucus vesiculosus* per 100g dry weight.

Parameter	Amount
Moisture	3.5%
Protein	7.8%
Carbohydrate	37.87%
Fat	0.08%
Crude fiber	15.26%
Ash	35.49%

**Table (3):** Determination of iodine and selenium of *Fucus vesiculosus* (mg/100g)

Parameter	Amount
Iodine	165 mg
Selenium	8 mg

**Table(4):** Phenolic compounds of fucusby HPLC analysis(mg/100g).

Phenolic compounds	Test results of Total Phenolic compounds (mg/100g)
Pyrogallol	774.16
Ellagic	426.41
Chlorogenic	122.73
Ferulic	122.56
Catechol	59.55
Gallic	39.26
Caffeic	34.57
Catechein	20.41



Coumarin	17.22
Vanillic	13.82
Benzoic	13.78
Caffeine	8.68
4- Amino-benzoic	1.22

**Table (5):** Effect of levothyroxine and fucuson feed intake (FI), body weight gain (BWG%) and feed efficiency ratio (FER) of hypothyroid rats.

Parameters	FI g/day		BWG %		FER	
	Mean ± SD	% Change of C+VE	Mean ± SD	% Change of C+VE	Mean ± SD	% Change of C+VE
Negative group	11.20 <sup>a</sup> ±0.27	0.90%	0.19 <sup>a</sup> ±0.01	-59.57%	0.03 <sup>a</sup> ±0.001	-62.50%
Positive group	11.10 <sup>a</sup> ±0.35	-	0.47 <sup>a</sup> ±0.02	-	0.08 <sup>a</sup> ±0.003	
Drug	10.76 <sup>a</sup> ±0.29	-3.06%	0.22 <sup>d</sup> ±0.01	-53.19%	0.04 <sup>a</sup> ±0.001	-50%
D + F 2.5%	10.97 <sup>a</sup> ±0.71	-1.17%	0.28 <sup>e</sup> ±0.02	-40.42%	0.05 <sup>a</sup> ±0.003	-37.5%
D + F 5%	11.23 <sup>a</sup> ±0.41	1.17%	0.21 <sup>e</sup> ±0.01	-55.31%	0.03 <sup>a</sup> ±0.001	-62.5%
F 2.5%	11.15 <sup>a</sup> ±0.19	0.45%	0.35 <sup>b</sup> ±0.02	-25.53%	0.06 <sup>b</sup> ±0.001	-25%
F 5%	11.08 <sup>a</sup> ±0.23	-0.18%	0.23 <sup>d</sup> ±0.02	-51.06%	0.04 <sup>a</sup> ±0.001	-50%

Values are expressed as mean ± S. D.

Significance is expressed at p<0.05 using one way ANOVA test and Duncan test

Values which have different letters in each column differ significantly, while those with similar letters completely or partially is not significant.

Drug :treatment with Levothyroxine 10mcg /kg

D+F 2.5%: drug (5mcg/kg)+ fucus( 25g/kg)

D+F 5% :drug (5mcg/kg)+fucus(50 g/kg)

F 2.5%: fucus( 25g/kg)

F 5%: fucus (50 g/kg)

**Table (6):** Effect of Levothyroxine and *Fucus vesiculosus* on serum FT4, FT3 and TSH of hypothyroid rats.

Parameters	FT4 U/L		FT3 U/L		TSH U/L	
	Mean ± SD	% Change of C+VE	Mean ± SD	% Change of C+VE	Mean ± SD	% Change of C+VE
Negative group	2.57 <sup>a</sup> ±0.22	144.76%	5.18 <sup>a</sup> ±0.19	181.52%	0.02 <sup>e</sup> ±0.01	%91.30-
Positive group	1.05 <sup>f</sup> ±0.21	-	1.84 <sup>e</sup> ±0.37	-	0.23 <sup>a</sup> ±0.05	-
Drug	1.91 <sup>cd</sup> ±0.26	81.90%	3.54 <sup>c</sup> ±0.56	92.39%	0.09 <sup>d</sup> ±0.01	-60.86%
D + F 2.5%	2.17 <sup>bc</sup> ±0.34	106.66%	4.30 <sup>b</sup> ±0.69	133.69%	0.05 <sup>e</sup> ±0.03	-78.26%
D + F 5%	2.47 <sup>ab</sup> ±0.27	135.23%	4.69 <sup>ab</sup> ±0.49	154.89%	0.03 <sup>e</sup> ±0.02	-86.95%

**Ghada Mohammed , Zainab Abdul-Wahhab Salem  
and Amira Lotfy Abd El-Raof Abd-Allah .**

F 2.5%	1.54 <sup>e</sup> ± 0.22	46.66%	2.23 <sup>e</sup> ± 0.16	21.19%	0.17 <sup>b</sup> ± 0.03	-26.08%	Drug- :treat ment
F 5%	1.71 <sup>d</sup> ± 0.29	62.85%	2.82 <sup>d</sup> ± 0.43	53.26%	0.13 <sup>c</sup> ± 0.03	-43.47%	

with Levothyroxine 10mcg /kg

D+F 2.5%: drug (5mcg/kg)+ fucus( 25g/kg)

D+F 5% :drug (5mcg/kg)+fucus(50 g/kg)

F 2.5%: fucus( 25g/kg)

F 5%: fucus(50 g/kg)

Values are expressed as mean ± S. D

Significance is expressed at p<0.05 using one way ANOVA test and Duncan test.

Values which have different letters in each column differ significantly, while those with similar letters completely or partially is not significant.

**Table (7):** Effect of Levothyroxine and Fucus vesiculosus on serum AST, ALT and ALP of hypothyroid rats

Parameters Groups	ASTU/L		ALT U/L		ALP U/L	
	Mean ± SD	% Change of C+VE	Mean ± SD	% Change of C+VE	Mean ± SD	% Change of C+VE
Negative group	114.02 <sup>c</sup> ± 17.69	-39.31%	33.62 <sup>b</sup> ± 5.68	-32.55%	314.82 <sup>c</sup> ± 15.88	-39.87%
Postive group	187.90 <sup>a</sup> ± 40.11		49.85 <sup>a</sup> ± 11.50		523.62a± 83.08	
Drug	131.82 <sup>bc</sup> ± 33.73	-29.84%	39.15 <sup>ab</sup> ± 15.20	-21.46%	375.37bc± 67.53	-28.31%
D + F 2.5%	141.93 <sup>bc</sup> ± 17.44	-24.46%	43.00 <sup>ab</sup> ± 9.15	-13.74%	382.45b± 38.30	-26.96%
D + F 5%	117.33 <sup>c</sup> ± 28.58	-47.55%	38.02 <sup>ab</sup> ± 13.11	-23.73%	337.73bc± 52.22	-35.50%
F 2.5%	161.77 <sup>ab</sup> ± 16.58	-13.90%	49.57 <sup>a</sup> ± 5.28	-0.56%	527.92a± 30.00	-0.82%

## Egyptian J. of Nutrition Vol. XXXVII No. 1 (2022)

F 5%	158.20 <sup>ab</sup> ± 20.04	-15.80%	49.04 <sup>a</sup> ± 9.11	-1.62%	471.54 <sup>a</sup> ± 37.67	-9.94%
------	---------------------------------	---------	------------------------------	--------	--------------------------------	--------

Drug. :treatment with Levothyroxine 10mcg /kg

D+F 2.5%: drug (5mcg/kg)+ fucus( 25g/kg)

D+F 5% :drug (5mcg/kg)+fucus (50 g/kg)

F 2.5%: fucus( 25g/kg)

F 5%: fucus (50 g/kg)

Values are expressed as mean ± S. D.

Significance is expressed at p<0.05 using one way ANOVA test and Duncan test.

Values which have different letters in each column differ significantly, while those with similar letters completely or partially is not significant

**Table (8):** Effect of Levothyroxine and Fucus vesiculosus on serum uric acid and serum creatinine of hypothyroid rat.

**Ghada Mohmmmed , Zainab Abdul-Wahhab Salem  
and Amira Lotfy Abd El-Raof Abd-Allah .**

Parameters Groups	UA mg/ dl		Create mg/ dl	
	Mean ± SD	% Change of C+VE	Mean ± SD	% Change of C+VE
Negative group	1.37 <sup>a</sup> ±0.06	-52.92%	0.46 <sup>c</sup> ±0.05	-40.25%
Postive group	2.91 <sup>a</sup> ±0. 24		0.77 <sup>a</sup> ±0.11	
Drug	2.02 <sup>c</sup> ±0.08	-30.58%	0.54 <sup>bc</sup> ±0.05	-29.87%
D + F 2.5%	1.55 <sup>d</sup> ±0.22	-46.73%	0.54 <sup>bc</sup> ±0.15	-29.87%
D + F 5%	1.56 <sup>d</sup> ±0.17	-46.39%	0.60 <sup>b</sup> ±0.12	-22.07%
F 2.5%	2.43 <sup>b</sup> ±0.12	-16.49%	0.72 <sup>a</sup> ±0.06	-6.49%
F 5%	2.15 <sup>c</sup> ±0.13	-26.11%	0.58 <sup>b</sup> ±0.12	-24.67%

Drug. :treatment with Levothyroxine 10mcg /kg

D+F 2.5%: drug (5mcg/kg)+ fucus( 25g/kg)

D+F 5% :drug (5mcg/kg)+fucus(50 g/kg)

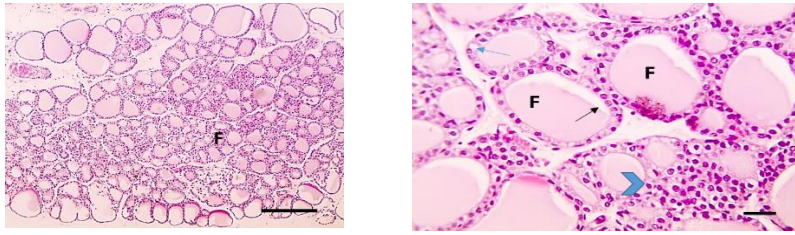
F 2.5%: focus ( 25g/kg)

F 5%: focus (50 g/kg)

Values are expressed as mean ± S. D

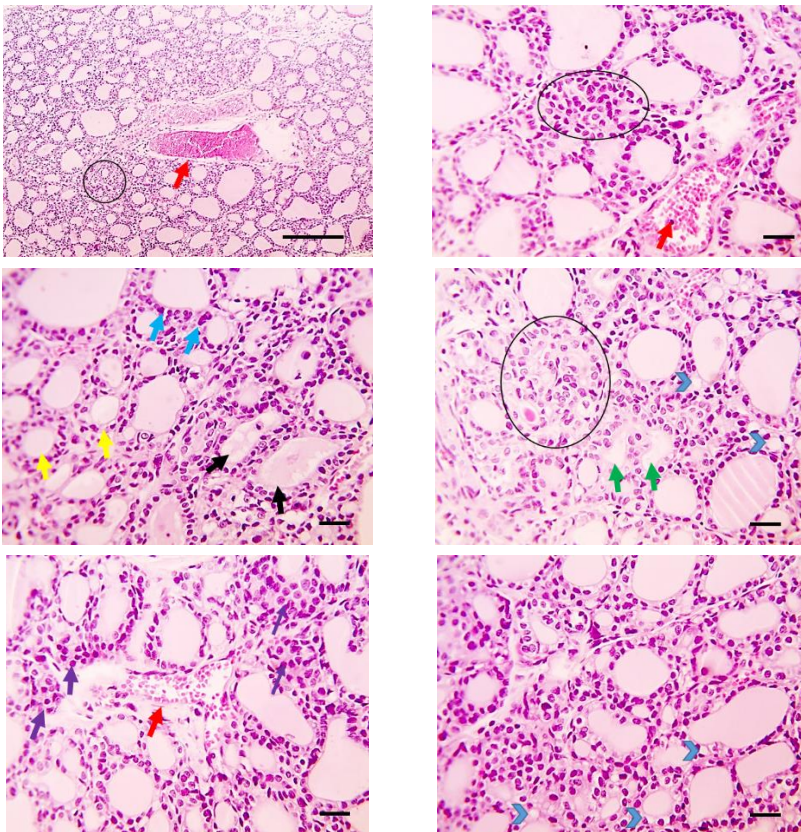
Significance is expressed at p<0.05 using one way ANOVA test and Duncan test.

Values which have different letters in each column differ significantly, while those with similar letters completely or partially is not significant.



**Photos (G1):**

cross-section of the thyroid gland of normal control group shows follicles size (F), well-formed and follicles epithelial cells (hematoxylin and eosin 400x).

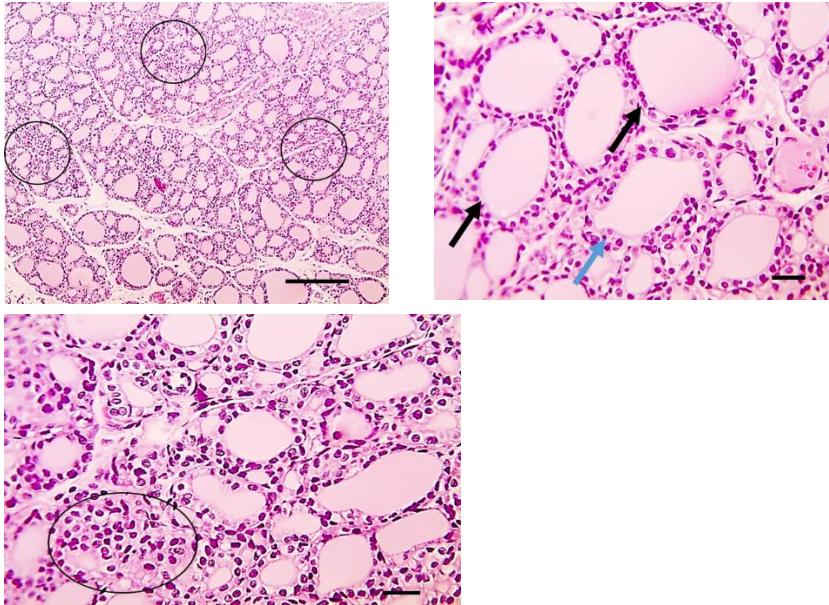


**Photos (G2):**

cross-section of the thyroid gland of the positive control group shows many histopathological changes including disorganized thyroid parenchyma (hematoxylin and eosin 400x).

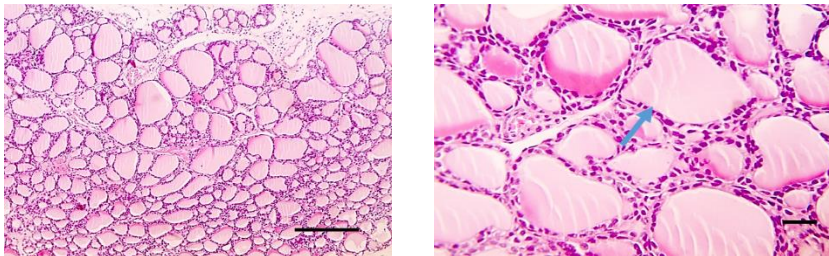
**Ghada Mohammed , Zainab Abdul-Wahhab Salem  
and Amira Lotfy Abd El-Raof Abd-Allah .**

---



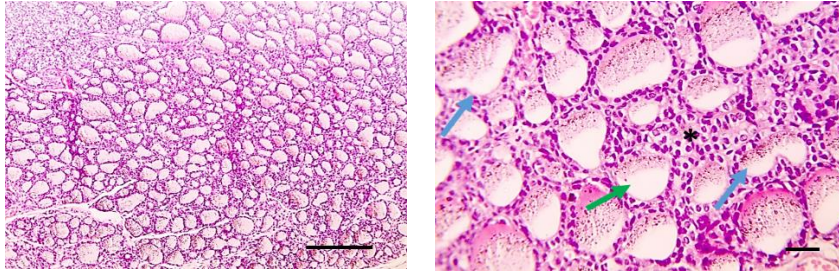
**Photos (G3):**

cross-section of the thyroid gland of the treated group with levothyroxine drug (3)  
showing larger follicles (black arrows) compared to untreated group (2)  
(hematoxylin and eosin 400x).



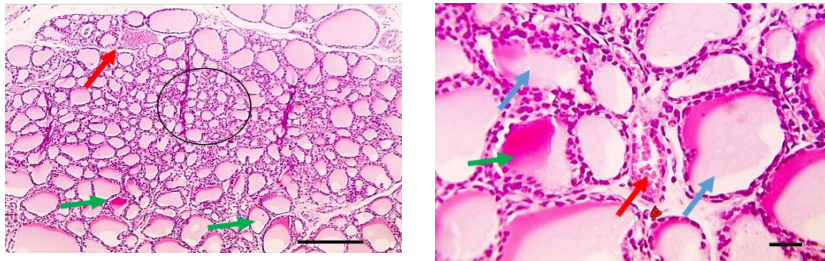
**Photos (G4):**

cross-section of the thyroid gland of the treated group with (D+F 2.5%) showing larger  
follicles than follicles in treated group 5 (hematoxylin and eosin 400x).



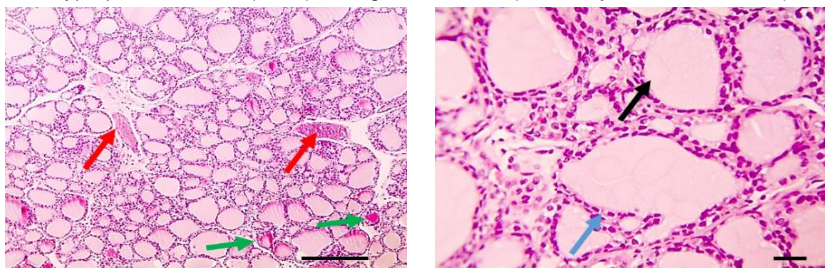
**Photos (G5):**

cross-section of the thyroid gland of the treated group with (D+F 5.0%) showing diffuse hyperplasia of follicular and interfollicular cells (asterisk). The follicles are smaller than follicles in treated groups with 3,6,7 (hematoxylin and eosin 400x).



**Photos (G6):**

cross-section of the thyroid gland of the treated group with (F 2.5%) showing some small hyperplastic follicles (circle) having small lumina (hematoxylin and eosin 400x).



**Photos (G7):**

cross-section of the thyroid gland of the treated group with (F 5.0%) showing larger follicles (black arrows) compared to untreated group (2) and moderately congested blood vessels (hematoxylin and eosin 400x).

## ***References***

- Abdelkadder, H. S.; Fathi, A. M.; and Adail, A. S .(2015):**  
Protective andtherapeutic effects of fucoidan, brown algae extract, againstmethotrexate hepatic toxicosis in albino rats. International Journal., 2015, 3(1): 504-514.
- Abid, M.SH .; Kapil ,K .; Ali, S. S. ; Chandra, Ph .; Verma, A. ; Kishore K. and Najam ,A. Kh. (2016):**  
Complication and management of hypothyroidism -a review. Indian Journal of Drugs, 4(2), 42-56 ISSN: 2348-1684.
- Afonso, N.C.; Catarino ,M.D.; Silva ,M.S.and Cardoso, S.M.(2019):**  
Brown macroalgae as valuable food ingredients. Antioxidants, 8(9), 365, doi:10.3390/ 8090365.
- Alfallouji, S; Ali ,R. K; Ali, W .J .(2012):**  
The Correlation between Oxidative Stress and Thyroid Hormones in Serum and Tissue Homogenized of Hypothyroidism Patients. Medical Journal of Babylon, 9 (4): 843-849.
- Ali ,W. J. H.; Ali ,R. K.andAlfallouji ,S. (2012):**  
The Correlation between Oxidative Stress and Thyroid Hormones in Serum and Tissue Homogenized of Hypothyroidism Patients. Medical Journal of Babylon, 9(4): 843-849.



**AlKahtane, A. A.; Abushouk, A. I.; Mohammed, E. T.; ALNasser, M.; Alarifi, S.; Ali, D. and Abdel-Daim, M. M. (2020):**

Fucoidan alleviates microcystin-LR-induced hepatic, renal, and cardiac oxidative stress and inflammatory injuries in mice. *Environmental Science and Pollution Research*, 27(3), 2935-2944. doi.org/10.1007/s11356-019-06931-z.

**Amisha, F. and Rehman, A.(2021):**

Propylthiouracil (PTU). Book from StatPearls Publishing, Treasure Island., PMID: 31751018 .

**Anaraki, P.V.;Aminorroaya, A.; Amini ,M.; Momeni ,F.; Feizi, A. and Iraj, B. (2017):**

Effect of Vitamin D deficiency treatment on thyroid function and autoimmunity markers in Hashimoto's thyroiditis: A double-blind randomized placebo-controlled clinical trial. *Journal of Research in Medical Sciences: The Official Journal of Isfahan University of Medical Sciences*,22:103. doi: 10.4103/jrms.JRMS\_1048\_16.

**Association of Official Analysis Chemists ( AOAC). (2000):**

Official Methods of Analysis of Association of Official Chemists . 18th Ed., Washington, D.C., USA.

**Balina, K.; Romagnoli, F. and Blumberga, D. (2016):**

Chemical composition and potential use of *Fucus vesiculosus* from Gulf of Riga. *EnergyProcedia*, 95,4349.doi.org/10.1016/j.egypro.2016.09.010

**Bogolitsyn ,K. ; Dobrodeeva ,L.; Parshina ,A. and Samodova ,A .(2020):**

In vitro and in vivo activities of polyphenol extracts from Arctic brown alga *Fucus vesiculosus*. *Journalof Applied Phycology*, 33(4),2597-2608.doi: /10.1007/s10811-021-02450.

**Ghada Mohammed , Zainab Abdul-Wahhab Salem  
and Amira Lotfy Abd El-Raof Abd-Allah .**

---

**Bradley, P.R.( 1992):**

British Herbal Compendium. 1. Bournemouth, England: British Herbal Medicine Association. ISBN 0-903032-09-0.

**Campbell, J.A. (1963):**

Methodology of Protein Evaluation RAG Nutr., Document R. 101 Ed., 37. June Meeting New York.

**Carleton, H. (1979):**

" Histological Technique". 4th Ed., London

**Catarino, M.D.; Silva, M.S. and Cardoso, S.M.(2018):**

Phytochemical constituents and biological activities of Fucus spp. Marine drugs, 16(8), 249. doi:10.3390/md16080249

**Chapman, D.G.; Castilla, R. and Campbell, J.A. (1959):**

"Evaluation of protein in food. LA. method for the determination of protein efficiency ratio". Can. J. Biochem. Physiol., 37: 679 - 686.

**Dean Green .(2012):**

" Bladderwrack" In book, Eat the weed and other things too, volume 1 pp 1-15.

**EL-Shaer, M. K.; Abd El\_Rahman, A. N.and Saleh, R. F. (2021) :**

The Effect of Bladder wrack algae on biomarkers of Obesity among experimental Rats. Journal of Home Economics, 31(1).

**Elst, J.; Heide, D. and Kohrle, J. (1991):**

In vivo effects of flavonoids EMD 21388 on thyroid secretion and metabolism. Am. J. Physiol. Endocrinol. Metabol. 261: E227-E232.

**EL-Tantawi, H. and Abozeid, F. S. (2019) :**

Impact of Spirulina on Propylthiouracil-Induced Hypothyroidism in Albino Rats, a histological, immunohistochemical and biochemical approach. Egyptian Journal of Histology, 42(4), 849-860.doi: 10.21608/ejh.2019.16398.1159.

**Ernst, E.(2005):**

The efficacy of herbal medicine—an overview. Fundamental & clinical pharmacology, 19(4), 405-409. doi: 10.1111/j.1472-8206.2005.00335.x.

**Faulkner, N.R. and King, J.W. (1976):**

"Fundamental of Clinical Chemistry". 2nd Ed. Tietz Editor. Saunders Philadelphia, 994-998.

**Fossati, P.; Prencipe, L. and Berti, G. (1980):**

"Enzymatic colorimetric method for determination of uric acid in serum". Clin. Chem., 26 (2) : 227-273.

**Gabbia, D.; Saponaro, M.; Sarcognato, S.; Guido, M.; Ferri, N.; Carrara, M. and De Martin, S. (2020):**

Fucus vesiculosus and Ascophyllum nodosum ameliorate liver function by reducing diet-induced steatosis in rats. Marine Drugs, 18(1), 62. doi.org/10.3390/md18010062.

**Gnocchi, D.;Steffensen, K. R.; Bruscalupi, G. and Parini, P. (2016):**

Emerging role of thyroid hormone metabolites. Acta physiologica, 217(3),184-216.doi: 10.1111/apha.12648.

**Ghada Mohammed , Zainab Abdul-Wahhab Salem  
and Amira Lotfy Abd El-Raof Abd-Allah .**

---

**Gorstein ,J.L .; Bagriansky ,J. and Zimmermann ,M.B .(2020):**

Estimating the health and economic benefits of universal salt iodization programs to correct iodine deficiency disorders. J.,Thyroid, 30(12),1802-1809 doi: 10.1089/.2019.0719.

**Goupy, P.; Hugues, M.; Biovin, P. and Amiot, M. (1999):**

"Antioxidant composition and activity of barley (Hordeumvulgare) and malt extracts of isolated phenolic compounds". J. Sci. Food Agric., 79:1625-1634.

**Gupta, S. and Abu-Ghannam, N.( 2011):**

Bioactive potential and possible health effects of edible brown seaweeds. Trends in Food Science & Technology, 22(6), 315-326, doi.org/10.1016/j.tifs.2011.03.011.

**Hameed, R.R.; Atea, K.F.andMohameed, M.A. (2014):**

Role of Fucus vesiculosus L. extract in theregulation of thyroid hormones status in adult male rabbits. Kerbala Journal of Pharmaceutical Science. Number7.

**Hameed, S. I.; Al-Shahwany, A. W. and Salih, S. J. (2020):**

Evaluation of the Activity of Some Plants Extracts on Thyroid Gland Regulation in Female Albino Rats. Iraqi Journal of Science, 254-265. doi.org/10.24996/ijjs.2020.61.2.3.

**Hatem, R. M. and AL-Mayali, H. K. (2018):**

The effect of fucus vesiculosus on the function and structure of the thyroid gland of male rats treated with propylthiouracil. J. Pharm. Sci. & Res. Vol. 10(10), 2669-2673.

**Hayashi, S.; Itoh, A.; Isoda, K.; Kondoh, M.; Kawase, M. and Yagi, K. (2008):**

Fucoidan partly prevents CCl<sub>4</sub>-induced liver fibrosis. *European Journal of Pharmacology*, 580(3), 380–384. doi.org/10.1016/j.ejphar.2007.11.015.

**Hegsted, A. (1941):**

"Salt mixture". *J. Biol. Chem.*, 138: 459.

**Ilyas, A. (2015):**

Effect of Experimentally Induced Hypothyroidism and its Treatment by Thyroxine on the Number of Follicles in an Ovary of Wistar Rats. *Journal of Rawalpindi Medical College*, 19(1), 84-88.

**Kirkbright, G.F. West; T.S. and Wilson, P.J. (1974):**

The determination of iodine by atomic absorption and emission spectrometry with a cathode sputtering cell. *Analytica Chimica Acta*.68(2); 462-465, doi.org/10.1016/S0003-2670(01)82603-9.

**Korukanti, V.P.; Ponnamp, H. and Akondi, B.R. (2013):**

Evaluation of antiobesity activity of *Fucus vesiculosus*. *Indian Journal of Research in Homoeopathy*, 7(3) : 126-132. doi/8080/xmlui/handle/123456789/1439.

**Küpper, F.C.; Feiters, M.C.; Olofsson, B.; Kaiho, T.; Yanagida, S.; Zimmermann, M.B.; Carpenter, L.J.; Luther, G.W.; Lu, Z and Jonsson, M. (2011):**

Commemorating two centuries of iodine research: an interdisciplinary overview of current research. *Angewandte Chemie International Edition*, 50(49), 11598-11620. doi.org/10.1002/anie.201100028.

**Ghada Mohammed , Zainab Abdul-Wahhab Salem  
and Amira Lotfy Abd El-Raof Abd-Allah .**

---

**Laekeman, G. (2014):**

Assessment Report on *Fucus vesiculosus* L., thallus Herbal Preparations in Solid Dosage form for Oral Use. European Medicines Agency: London, UK.,10-55.

**Li, J .; Chen, K .; Liu, T.; Wang, F.; Xia, Y.; Lu, J.; Zhou, Y. and Guo, C .(2016):**

Pretreatment with Fucoidan from *Fucus vesiculosus* Protected against ConA-Induced Acute Liver Injury by Inhibiting Both Intrinsic and Extrinsic Apoptosis. PLOS, ONE. 11(4):273-275. doi.org/10.1371/journal.pone.0152570.

**Lorenzo ,J.M; Agregán ,R.; Munekata ,E.S.; Franco ,D.; Carballo ,J.; Sahin ,S. , Lacomba ,R. and Barba,F.J.(2017):**

Proximate composition and nutritional value of three macroalgae: *Ascophyllum nodosum*, *Fucus vesiculosus* and *Bifurcariabifurcata*. Marine drugs, 15(11), 360 ;doi:10.3390/md15110360.

**Malyarenko, O. S.; Usoltseva, R. V.; Shevchenko, N. M.; Isakov, V. V.; Zvyagintseva, T. N. and Ermakova, S. P. (2017):**

In vitro anticancer activity of the laminarans from Far Eastern brown seaweeds and their sulfated derivatives. Journal of Applied Phycology, 29(1), 543-553. doi /10.1007/s10811-016-0915-3.

**Mayer, A. M.; Rodríguez, A. D.; Berlinck, R. G. and Fusetani, N. (2011):**

Marine pharmacology in 2007–8 Marine compounds with antibacterial, anticoagulant, antifungal, anti-inflammatory, antimalarial, antiprotozoal, antituberculosis, and antiviral activities; affecting the immune and nervous system, and other miscellaneous mechanisms of action. *Comparative Biochemistry and Physiology Part C: Toxicology & Pharmacology*, 153(2), 191–222. doi.org/10.1016/j.cbpc.2010.08.008.

**Mistry, D.; Atkin, S.; Atkinson, H.; Gunasekaran, S.; Sylvester, D. and Rigby, A.S. (2011):**

Predicting thyroxine requirements following total thyroidectomy. *Clinical endocrinology (Oxf.)*, 74(3):384–7. doi: 10.1111/j.1365-2265.2010.03940.

**Parys, S.; Kehraus, S.; Krick, A.; Glomitzka, KW.; Germali, S.; Klimo, K.; Gerhauser, C. and Kong, G M. (2010):**

In vitro chemopreventive potential of fucophloretols from the brown alga *Fucus vesiculosus* L. by anti-oxidant activity and inhibition of selected cytochrome P450 enzymes. *Phytochemistry*, 71(2-3), 221–229. doi.org/10.1016/j.phytochem.2009.10.020.

**Reeves, P.G.; Nielsen, F.H. and Fahmy, G.G. (1993):**

"AIN-93. Purified diets for laboratory rodents: final report of the American Institute of Nutrition ad hoc writing committee on the reformulation of the AIN-76A rodent diet". *J. Nutr.*, 123: 1939–1951.

**Ghada Mohammed , Zainab Abdul-Wahhab Salem  
and Amira Lotfy Abd El-Raof Abd-Allah .**

---

**Reitman, S. and Frankel, S. (1957) :**

"A colorimetric method for the determination of serum glutamic oxaloacetic and glutamic pyruvic transaminases".  
Am. J. Clin. Path. , 28 : 56 .

**Roy, S. E. (1970):**

"Colorimetric determination of serum alkaline phosphatase".  
Clin. Chem., 16:431-432.

**Sabr ,A.N. (2015):**

Effect of sodium benzoate in the level of thyroid stimulating hormone and the level of thyroxin hormone in mature albino male rats . journal of kerbala university ,13 (1) : 295-299.

**Saito, A.;Yoneda, M.; Yokohama, S.; Okada, M.;Haneda, M.and Nakamura, K. (2006):**

Fucoidan prevents concanavalin A-induced liver injury through induction of endogenous IL-10 in mice. Hepatology Research, 35(3), 190-198.  
doi.org/10.1016/j.hepres.2006.03.012.

**Sánchez-Bonet, D.; García-Oms, S.; Belda-Antolí, M.; Padrón-Sanz, C.; Lloris-Carsi, J. M. and Cejalvo-Lapeña, D.(2021):**

RP-HPLC-DAD determination of the differences in the polyphenol content of Fucus vesiculosus extracts with similar antioxidant activity. Journal of Chromatography B, 1184, 122978. doi.org/10.1016/j.jchromb.2021.122978.

**Snedcor, G. and Cochran, W. (1979):**

Statistical method 6th ed. Lowe state collage U. S. A. : 841.



**Sener,G.; Kabasakal,I.; Atasoy,B.M.; Erzik,C.; Velioglu,O.A.; Cetinel,S.; Cotuk,G.; Gedik,N.; and Yegen, B. C. (2006):**

Propylthiouracil-induced hypothyroidism protects ionizing radiation-induced multiple organ damage in rats. *Journal of endocrinology*, 189(2), 257-269. doi.org/10.1677/joe.1.06574.

**Shamsian, A.; Ghazvini ,K.; Sokhtanloo ,M.; Moghaddam M. and Vakili ,R. (2016):**

Which quantitative method in determination of the thyroid hormone levels is more consistent with the clinical symptoms of the thyroid disorders?. *Comparative Clinical Pathology*, 25(1), 101-106, doi 10.1007/s00580-015-2148-2.

**Singh, B.;Sundar, S. and Shukla, A.(2021):**

Herbal Medicines for Thyroid Diseases . In *Treating Endocrine and Metabolic Disorders With Herbal Medicines* .IGI Global, 256-277.doi: 10.4018/978-1-7998-4808-0.ch011.

**Song, J. Q. ;Xu, Y.T. and Zhang, H. K (2000):**

Immunomodulation action of sulfate polysaccharide of *Laminaria Japonica* on peritoneal macrophages of mice .*Chin. J. Immunol.*, 16, 70-70.

**Steinmaus, C.; Miller, M. D. and Howd, R. (2007):**

Impact of smoking and thiocyanate on perchlorate and thyroid hormone associations in the 2001–2002 National Health and Nutrition Examination Survey. *Environmental health perspectives*, 115(9), 1333-1338. doi.org/10.1289/ehp.10300.

**Ghada Mohammed , Zainab Abdul-Wahhab Salem  
and Amira Lotfy Abd El-Raof Abd-Allah .**

---

**Sumampouw ,G.A; Jacobsen,C.and Getachew ,A.T.(2021):**

Optimization of phenolic antioxidants extraction from *Fucus vesiculosus* by pressurized liquid extraction. *Journal of Applied Phycology*, 33(2), 1195-1207.  
doi.org/10.1007/s10811-020-02362-3.

**Truus ,K.; Vaher ,M.; Koel, M. ;Mahar ,A. and Taure,I.(2004):**

Analysis of bioactive ingredients in the brown alga *Fucus vesiculosus* by capillary electrophoresis and neutron activation analysis. *Analytical and bioanalytical chemistry*, 379(5), 849-852.doi 10.1007/s00216.

**Walkinson, J. H. (1966): a**

Fluorometric determination of selenium in biological material with 2,3-diaminonaphthalene. *Analytical-chemistry*, 38(1),92-97.doi.org/10.1021/ac60233a025.

**Wang, J.; Geng, L.; Yue, Y. and Zhang, Q. (2019):**

Use of fucoidan to treat renal diseases: A review of 15 years of clinic studies. *Progress in Molecular Biology and Translational Science*, 163, 95-111.doi.org/10.1016/bs.pmbts.2019.03.011.

**Yoo, S.; Kim, K.; Nam, H. and Lee, D. (2018):**

Discovering health benefits of phytochemicals with integrated analysis of the molecular network, chemical properties and ethnopharmacological evidence. *Nutrients*, 10(8), 1042.doi:10.3390/nu10081042.

## دور طحلب الفوقس الحويصلي في تعزيز وظائف الغدة الدرقية في فئران التجارب

غادة محمد الزيني المنسي\* - زينب عبد الوهاب سالم\*-  
أميرة لطفي عبد الرؤف عبد الله\*

\*قسم التغذية وعلوم الأطعمة - كلية الإقتصاد المنزلي - جامعة الأزهر

### الملخص العربي

الفوقس الحويصلي هو أحد الطحالب التي تنتمي إلى عائلة الأعشاب البحرية. له تاريخ طويل في استخدامه كغذاء ودواء بسبب خصائصه البيولوجية. تعتبر الطحالب مصادر غذاء ثمينة للغاية وذات قيمة غذائية عالية وقليلة السعرات الحرارية بسبب المحتوى المنخفض من الدهون والسكريات.

**الهدف:** أجريت الدراسة للتعرف على الدور الوقائي والتأثيرات الإيجابية للأعشاب البحرية (الفوقس الحويصلي) ودورها في تقليل الآثار الجانبية لعقار البروبييل ثيوراثيل على وظيفة الغدة الدرقية.

**المواد والطرق:** في هذه الدراسة، تم استخدام ٤٢ من ذكور الجرذان البيضاء. (وزن  $160 \pm 10$  جم) قسمت إلى مجموعتين رئيسيتين، المجموعة الأولى هي المجموعة الضابطة السالبة (عدادها ٦ فئران) تم تغذيتها على النظام الغذائي الاساسي لمدة (٣٥ يومًا) والمجموعة الرئيسية الثانية هي المجموعة التجريبية (عدادها ٣٦ فأر). وتم إطعام هذه المجموعة على النظام الغذائي الاساسي وتلقت جرعة فموية يومية من بروبييل ثيوراسيل (١٥ مجم / كجم من وزن الجسم) بواسطة الأنبوب المعدي لمدة (١٧ يومًا) للبحث على قصور الغدة الدرقية، ثم تم تقسيمها إلى ٦ مجموعات فرعية (٦ فئران/مجموعة)؛ المجموعة الفرعية الأولى (المجموعة الضابطة الموجبة) تم إطعامها على النظام الغذائي الاساسي لمدة (١٨ يومًا). المجموعة الفرعية الثانية (مجموعة عقار ليفوثيروكسين) تم إطعامها على النظام الغذائي الاساسي وتلقت جرعة فموية يومية من ليفوثيروكسين (١٠ ميكروغرام / كجم من وزن الجسم) عن طريق أنبوب المعدة لمدة (١٨ يومًا)؛ المجموعة الفرعية الثالثة (D + F 2.5%) تم إطعامها على نظام غذائي أساسي يحتوي على مسحوق طحلب الفوقس (٢٥ جم / كجم من وزن الجسم) وأعطيت جرعة فموية يومية من ليفوثيروكسين (٥ ميكروغرام / كجم من وزن الجسم) عن طريق الأنبوب المعدي لمدة (١٨ يومًا)؛ المجموعة الفرعية الرابعة (D

**Ghada Mohmmmed , Zainab Abdul-Wahhab Salem  
and Amira Lotfy Abd El-Raof Abd-Allah .**

F 5.0 +%) تم إطعامها على نظام غذائي أساسي يحتوي على مسحوق الفوقس (٥٠ جم / كجم من وزن الجسم) وتلقت جرعة فموية يومية من ليفوثيروكسين (٥ ميكروجرام / كجم من وزن الجسم) عن طريق الأنبوب المعدي لمدة (١٨ يوماً) ؛ المجموعة الفرعية الخامسة (2.5 F%) تم إطعامها على نظام غذائي أساسي يحتوي على مسحوق الفوقس (٢٥ جم / كجم من وزن الجسم) لمدة (١٨ يوماً): المجموعة الفرعية السادسة (5.0 F%) تم إطعامها على نظام غذائي أساسي يحتوي على مسحوق الفوقس (٥٠ جم / كجم من وزن الجسم لمدة) (١٨ يوماً). استمرت التجربة لمدة ٣٥ يوماً متتاليًا.

**النتائج:** أوضحت النتائج عدم وجود فرق معنوي بين مجموعة الفئران المعاملة بالفوقس (٥٠ جم / كجم) + عقار ليفوثيروكسين (٥ ميكروجرام / كجم) و مجموعة التحكم الطبيعية (الكنترول السالب) ( في زيادة الوزن. أظهرت نتائج اختبارات الهرمونات أن هناك زيادة معنوية في مستوى هرمونات (FT3 و FT4) وانخفاض في هرمون TSH في المجموعة التي عولجت بواسطة الفوقس الحويصلي ، كما أظهرت إنزيمات الكبد انخفاضاً معنوياً عند مقارنتها بالمجموعة الضابطة. وانخفضت مستويات وظائف الكلى في الفئران المعالجة بشكل ملحوظ عن القيم المقابلة لمجموعة التحكم الضابطة.

**الكلمات المفتاحية:** الطحالب ، غدة درقية ، بروبييل ثيوراسيل ، ليفوثيروكسين ، أعشاب بحرية ، قصور الغدة الدرقية.