

**Comparative Study of TI-RADS, Elasticity Score, Strain Ratio and Quantitative Diffusion MR Weighted Imaging in Characterization of Thyroid Nodules; Which Has the Best Diagnostic performance?**

**Ahmed M. Magdy<sup>a\*</sup>, Ahmed Adel Mahmoud<sup>a</sup>, Ashraf Talaat Youssef<sup>a</sup>**

<sup>a</sup>Department of Diagnostic Radiology, Faculty of Medicine, Fayoum University, Fayoum, Egypt.

### Abstract

**Background:** Thyroid nodules are common disorder of the thyroid gland. Early and precise diagnosis of malignant thyroid nodules is fundamental for effective treatment.

**Objectives:** The purpose of this study is comparative evaluation of the diagnostic performance of TI-RADS, elasticity score, strain ratio and quantitative diffusion-weighted MRI in characterization of malignant and benign thyroid nodules.

**Patients and methods:** Our study is prospective. 59 patients with 59 thyroid nodules were enrolled in this study. Conventional ultrasound with TI-RADS categorization, ultrasound strain elastography (elasticity score and strain ratio) as well as diffusion-weighted MR imaging and ADC value were evaluated for all cases. Histopathology results were the standard reference.

**Results:** TI-RADS score had (80 %) sensitivity, (89.8 %) specificity and (84.9 %) accuracy. Elasticity score using 4-points Asteria's criteria with cutoff value =3 had (70 %) sensitivity, (91.8 %) specificity and (80.9 %) accuracy. When a cutoff value of 1.65 was used for strain ratio; (90 %) sensitivity, (71.4 %) specificity and (91.8 %) diagnostic accuracy noted. When a cutoff value of  $1.45 \times 10^{-3}$  was used for ADC value; (80 %) sensitivity, (95.9 %) specificity and overall accuracy (98%) noticed. Multiparametric analysis enhanced the overall accuracy of TI-RADS scoring with the best diagnostic performance was achieved in our study by combining diffusion ADC value to the TI-RADS scoring with sensitivity 100%, specificity 95.9% and accuracy 98%.

**Conclusions:** Strain ratio and diffusion ADC value had higher diagnostic performance than US TI-RADS scoring in characterizing thyroid nodules. The best diagnostic performance in our study was achieved by combining diffusion ADC value to the TI-RADS scoring with overall accuracy of about 98%.

**Keywords:** Thyroid nodules, strain elastography, diffusion, TI-RADS, ADC.

**DOI:**10.21608/svuijm.2022.127300.1294

**\*Correspondence:** [drmagdy1982@yahoo.com](mailto:drmagdy1982@yahoo.com)

**Received:** 14 March,2022.

**Revised:** 28 March,2022.

**Accepted:** 12 April, 2022.

**Cite this article as:** Ahmed M. Magdy, Ahmed Adel Mahmoud, AshrafTalaat Youssef. (2022). Comparative Study of TI-RADS, Elasticity Score, Strain Ratio and Quantitative Diffusion MR Weighted Imaging in Characterization of Thyroid Nodules; Which Has the Best Diagnostic performance?. *SVU-International Journal of Medical Sciences*. Vol.5, Issue 2, pp: 159-172.

**Copyright:** © Magdy et al. (2022) Immediate open access to its content on the principle that making research freely available to the public supports a greater global exchange of knowledge. Users have the right to Read, download, copy, distribute, print or share link to the full texts under a [Creative CommonsBY-NC-SA 4.0 International License](https://creativecommons.org/licenses/by-nc-sa/4.0/).

## Introduction

Thyroid nodules are common disorder of the thyroid gland. Early and precise diagnosis of malignant thyroid nodules is fundamental for effective treatment (**Luguang et al, 2018**).

Conventional thyroid ultrasound (US) is a commonly used method for categorizing benign and malignant thyroid nodules. However; the overall diagnostic accuracy of conventional thyroid ultrasound alone seems to be limited with considerable overlap of US findings in benign and malignant thyroid nodules (**Mao et al. 2018**).

Strain elastography (SE) investigates tissue stiffness differences by applying an external force and detecting deformation response. Low relative tissue deformation is linked to reduced tissue elasticity and a higher potential of malignancy. Strain elastography scoring (qualitative assessment) used either five-point scales based on Ueno and Itoh's study (**Ueno and Itoh, 2004**) or four-point scales based on the criteria established by Asteria et al in 2008 (**Asteria C et al, 2008**).

Strain ratio (SR) is a semi-quantitative analytic method. It compares the strain of 2 different regions of interest (ROIs) applied manually on the screen; one on the targeted thyroid nodule and the other ROI on reference normal thyroid tissue; then the SR value is automatically calculated (**Kratky J et al, 2016**).

Ultrasound elastography is a promising technique for differentiation between benign and malignant thyroid nodules (**Okasha HH et al, 2021**).

MRI apparent diffusion coefficient (ADC) values could be used to distinguish malignant from benign thyroid nodules (**Luguang, et al, 2018**).

Diffusion-weighted MRI and its ADC value had higher diagnostic efficacy than American College of Radiology (ACR) TI-RADS scoring in differentiating benign from malignant

thyroid nodules (**Latif M, et al, 2021**).

The aim of our study is comparative evaluation of the diagnostic performance of TI-RADS, elasticity score, strain ratio and quantitative diffusion-weighted MRI in differentiating malignant from benign thyroid nodules.

## Patients and methods

This study is prospective. 59 patients (20 males and 39 females, mean age  $37.9 \pm 11.6$  years) with 59 thyroid nodules referred from the general surgery clinic for evaluation of thyroid nodules were included in this study during the period from April 2021 to February 2022. Conventional thyroid ultrasound with TI-RADS categorization, ultrasound strain elastography with elasticity score and strain ratio (SR), diffusion-weighted MR imaging with its quantitative parameter apparent diffusion coefficient (ADC) values were measured in all nodules included within the study. Histopathological results were the standard reference.

### *Inclusion criteria:*

- Patients referred from the general surgery clinic for evaluation of thyroid nodules.
- Patients with solid and partly solid nodules.
- Patients with solitary or multiple thyroid nodules. In case of multiple thyroid nodules, the most suspicious one (having highest TI-RADS score) has been selected for evaluation.
- Patients who consent.
- Any age and both genders.
- Patients with normal bleeding profile.

### *Exclusion criteria:*

- Patient with cystic and mainly cystic nodules (TI-RADS 1 nodules).
- Declined consent.
- Declined biopsy.
- Claustrophobia.
- MR-incompatible pacemakers.
- MR-incompatible prosthetic heart valves.

**All cases had been subjected to the following:**

- Clinical assessment sheet by the referral doctor.
- Revision of the radiological investigations previously done for the patients.
- Conventional ultrasound study with TI-RADS categorization.
- Ultrasound strain elastography.
- Diffusion weighted magnetic resonance imaging.
- Fine needle aspiration cytology /biopsy.

**Thyroid Ultrasound and Strain Elastography Methodology**

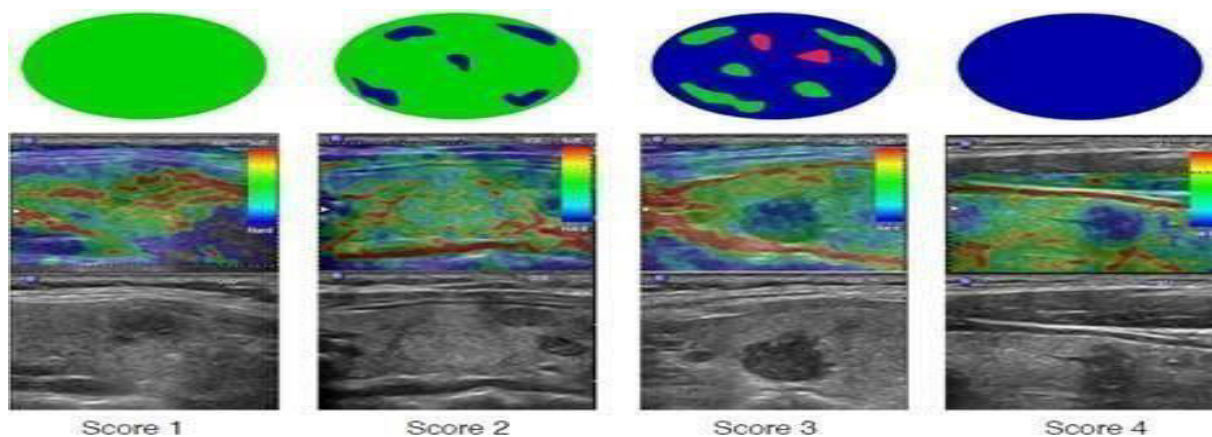
The same radiologist performed the conventional ultrasonography (US) and sonoelastography examinations by LOGIQ E9 with XD clear machine equipped with real-time elastography software and a L3-12 linear transducer. Patients were examined in the supine position with a 3-12 MHz US linear probe. At the start; conventional US was performed for all patients to assess the shape, size, echogenicity, border characteristics and presence of calcifications in the targeted nodules and were classified according to the ultrasound 'Thyroid imaging, report and data systems' (TI-RADS) categories. As regards ACR TI-RADS scoring system; TI- RADS score of 4 and 5 were regarded as more

suspicious for malignancy.

**Strain elastography** was performed instantaneously after conventional US. The ultrasound transducer was placed on the targeted thyroid nodule parallel to the long axis of the nodule. The operator placed the elastography box over the thyroid nodule to be examined after obtaining full ultrasonographic view of the thyroid nodule on the screen and performed 4-6 sequential compression-decompressions in antro-posterior direction.

**Elasticity score:**A chromatic scale was used to assign soft tissues which could be compressed/strained green color and hard tissues which were not compressed/strained blue color.

We used the four-point scales based on the criteria demonstrated by Asteria et al in 2008 (**Asteria C et al, 2008**) for assigning elasticity score of targeted thyroid nodules. Asteria's criteria classified a score 1 as elasticity that is totally soft in the nodule, score 2 as mostly soft in the nodule, score 3 as mostly hard in the nodule and score 4 as completely hard in the nodule (**Fig. 1**). Asteria scores of 3 and 4 were considered as suspicious elastography criteria for malignancy.



**Fig. 1. Strain elastography scores by Asteria et al (2008)**

**Strain ratio (SR):** A semi-quantitative ratio of tissue stiffness calculated for all thyroid lesions

by applying a region of interest (ROI) on the targeted thyroid nodule and another ROI placed

on the adjacent normal thyroid tissue (in few cases with large thyroid nodules and no available adjacent residual normal thyroid tissue in the field for comparison; the second ROI was placed over sternomastoid muscle). Using specific software; the SR value to be automatically calculated.

#### **Diffusion weighted magnetic resonance imaging methodology**

The MR protocol at our institution was performed using a 1.5-T unit (Toshiba

Vantage Titan closed machine). Patients were positioned in the supine position head first and ear plugs were offered. The head coil with neck extension was used for radio-frequency transmission and phased array surface coil for receiving signal.

Using the following pre-contrast MRI sequences (**Table 1**):

- Axial T1 and Axial T2.
- Coronal T2 and coronal STIR were not done routinely in all cases.

**Table 1. Parameters of T1 and T2WIs pulse sequences**

Sequence	TR (msec.)	TE (msec.)	FOV (cm)	Slicethickness (mm)	Gap
T1	520	14	14x20	5	0.4
T2	>4000	>100	15x20	5	0.4

**Diffusion study:** Diffusion MR imaging was performed using fat-suppressed single-shot spin echo-planar sequence. The acquisition parameters were: TR 300 msec, TE 60 msec, slice thickness 5 mm, slice gap 1, scan time 3.5min, fat suppression was added. B-value= 0 & 1000.

**Images post-processing:** Using post-processing software; ADC maps were automatically generated. ADC values were derived from the ADC maps. Circular ROIs (regions of interests) were cautiously placed on the lesions of interest on the ADC map (areas of necrosis, cystic formation, calcifications and hemorrhage were excluded). Three measurements were taken for each lesion; then the mean ADC value was recorded.

#### **Reference standard**

We used fine needle aspiration cytology (FNAC) or biopsy for histological analysis as the standard reference.

#### **Statistical analysis**

-Data analysis performed using the Statistical Package of Social Science (SPSS) software version 22 in windows 7

(SPSS Inc., Chicago, IL, USA).

-Simple descriptive analysis in the form of numbers and percentages of qualitative data, and arithmetic means as central tendency measurement, standard deviations as a measure of dispersion of quantitative parametric data.

-For quantitative parametric data: Independent samples t test was used to compare quantitative measures between two independent groups

-For qualitative data: Chi square and McNemar test used to compare between two or more than two qualitative groups.

- Bivariate Pearson correlation test to test the association between variables.

- Sensitivity and specificity test for testing a new test with ROC curve "Receiver Operating Characteristic".

-The P-value < 0.05 was considered as statistical significant.

#### **Results**

A total of 59 patients with 59 thyroid nodules were included in this study with the mean patient age was (37.9±11.6)

years old; ranged between 14 and 63 years. 20 of patients were males (33.9%) and 39 were females (66.1%). 49 of

nodules were benign (83.1%) and 10 were malignant (16.9 %) (**Table. 2**).

**Table 2. Description of pathology results in the study group**

Pathology	Number
<b>Benign</b>	
Nodular goiter	24
Adenomas	16
Hyperplastic nodules	9
Total	49
<b>Malignant</b>	
Papillary	7
Medullary	2
Undifferentiated	1
Total	10

The mean size of the thyroid lesions in our study was(3.77±1.6) cms; ranged between (0.7 and 5) cms.

Regarding TI-RADS score: 6 (10.2 %) of thyroid nodules in this study were score 2, 40 (67.8 %) were score 3, 10(16.9 %) were score 4, and 3 (5.1 %) were score 5. As regards the ACR TI-RADS scoring system; TI-RADS score of 4 and 5 were regarded as more suspicious for malignancy.

Regarding elastography score (ES): 28 (47.5%) of thyroid nodules were score 1, 20 (33.9 %) were score 2, 6 (10.2 %) were score 3 and 5 (8.5 %) were score 4. As regards Asteria's criteria defining elastography scores; Asteria scores of 3 and 4 were regarded as suspicious elastography features for

malignancy.

ES and TI-RADS scores were significantly higher in malignant thyroid nodules compared to benign nodules (P-value <0.0001).

In our study, 4 benign thyroid nodules gave high ES (3& 4) resulting in false positive results and 3 malignant nodules gave low ES (1&2) resulting in false negative results. Regarding TI-RADS score; we found 5 benign nodules that gave high scores (4&5) resulting in false positive results and 2 malignant nodules that gave low scores (2&3) resulting in false negative results. There was no statistical significant difference with p-value >0.05 between each of elastography score and TI-RADS score in characterizing thyroid nodules compared to pathology results (**Table 3**).

**Table 3. Comparison between elastography score and TI-RADS score in relation to histopathology results.**

Variables	Benign (N=49)		Malignant (N=10)	
	No.	%	No.	%
ES= 1&2	45	91.8%	3	30%
ES= 3&4	4	8.2%	7	70%
TI-RADS= 2&3	44	89.8%	2	20%
TI-RADS= 4&5	5	10.2%	8	80%

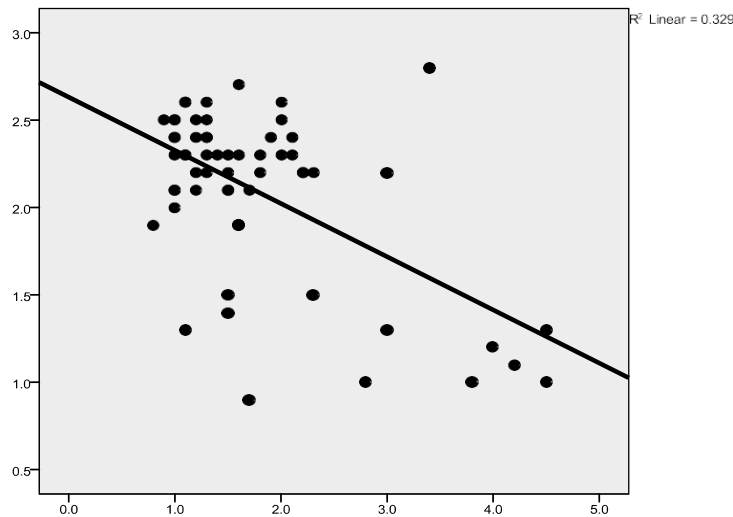
Regarding strain ratio (SR) and MRI-ADC value: Our study showed that the mean value of strain ratio for malignant lesions was (2.9±1.2) and that for benign lesions was (1.57±0.71). Regarding MRI-ADC value; this study showed that the mean ADC value for malignant lesions was (1.18

±0.22) and that for benign lesions was (2.27±0.27).

There was a statistical significant higher mean of SR and lower mean of ADC value with p-value <0.05 in malignant thyroid nodules compared to benign thyroid nodules(**Table 4**), (**Fig. 2**).

**Table4. Mean of SR and ADC value compared to histopathology results.**

Variables	Allnodules (N=59)		Benign (N=49)		Malignant (N=10)		P-value	Sig.
	Mean	SD	Mean	SD	Mean	SD		
Strainratio (SR)	1.79	0.93	1.57	0.71	2.90	1.2	<0.001	HS
ADCvalue	2.09	0.49	2.27	0.27	1.18	0.22	<0.001	HS



**Fig. 2. Distribution of SR and ADC values in the study group.**

***Diagnostic accuracy of TI-RADS, Elasticity score, Strain ratio and MRI-ADC value in differentiating malignant from benign thyroid nodules (compared to final histopathology results)***

The TI-RADS scoring system showed (80%) sensitivity, (89.8%) specificity, positive predictive value of about (61.5%) and negative predictive value of about (84.9%) with total accuracy of about (90%) when the cutoff point=4 used. The elasticity

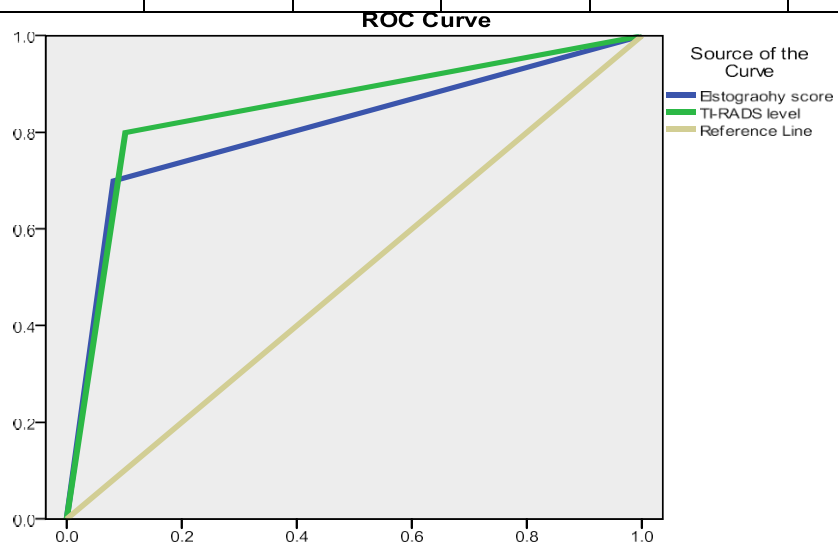
score (ES) showed (70 %) sensitivity, (91.8%) specificity, positive predictive value of about (63.6%) and negative predictive value of about (93.8%) with total accuracy of about (80.9 %) when the cutoff point=3 used. Strain ratio (SR) showed (90%) sensitivity, (91.4 %) specificity, positive predictive value of about (39.1) and negative predictive value of about (97.2 %) with total accuracy of about (91.8%) when the cutoff point=1.65 used. The MRI ADC

Value showed (80%) sensitivity, (95.9%) specificity, positive predictive value of about (80%) and negative predictive value of about (95.9%) with total accuracy of

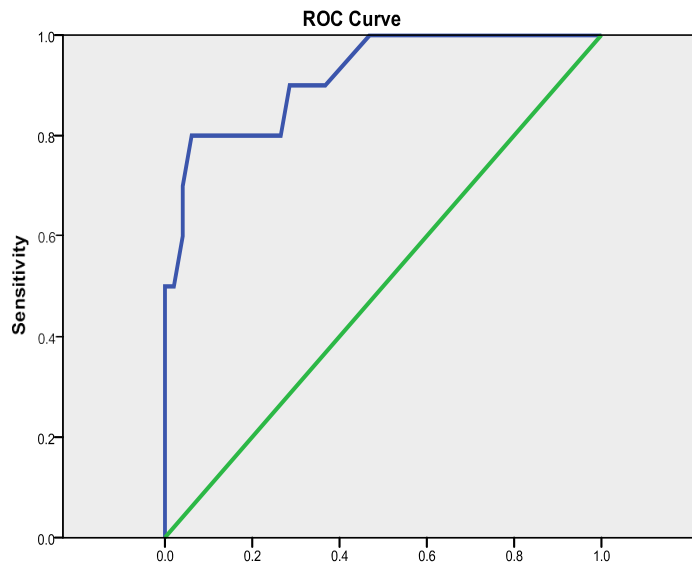
about (98%) when the cutoff point=1.45 used, P value = <0.0001 (Table 5) & ( Fig. 3, 4 & 5).

**Table5. Diagnostic performance of different modalities in characterizing thyroid nodules.**

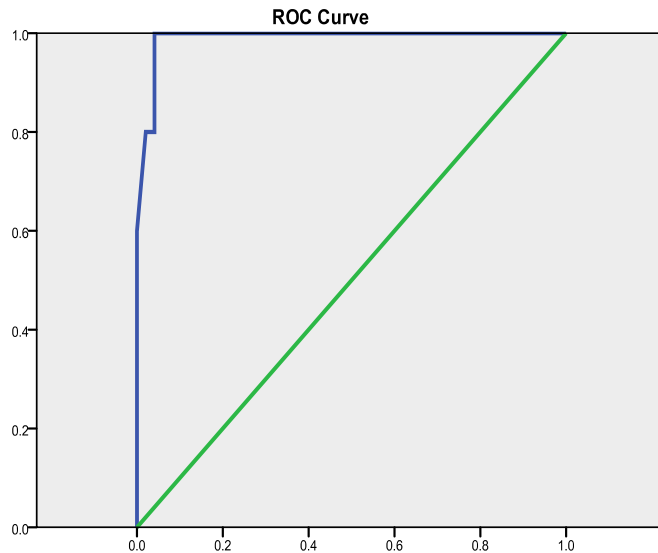
Variable	Sensitivity	Specificity	PPV	NPV	Accuracy	Cutoff point	p-value
ES	70%	91.8%	63.6%	93.8%	80.9%	Score3	0.002*
TI-RADS	80%	89.8%	61.5%	95.7%	84.9%	Score4	0.001*
SR	90%	71.4%	39.1%	97.2%	91.8%	1.65	<0.001*
ADCvalue	80%	95.9%	80%	95.9%	98%	1.45	<0.001*



**Fig. 3. ROC curve for diagnostic performance of TI-RADS (when the cutoff point = 4) and ES (when the cutoff point = 3); P value = 0.001\* & 0.002\* respectively.**



**Fig. 4. ROC curve for diagnostic performance of SR, when the cutoff point = 1.65; P value = <0.001\***



**Fig. 5. ROC curve for diagnostic performance of ADC value, when the cutoff point = 1.45; P value = <0.001\***

***Diagnostic performance of multi-parametric analysis (Strain ratio combined to TI-RADS scoring system) and (MRI ADC value combined to TI-RADS scoring system) in characterizing thyroid nodules***

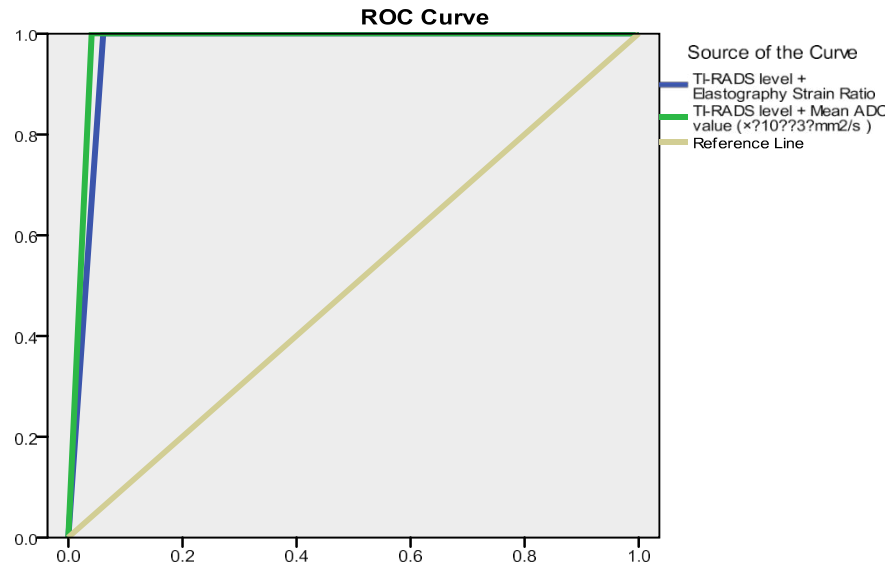
The combination of TI-RADS scoring and SR showed increased sensitivity to (100%), specificity to (93.9%), positive

predictive value to (76.9%) and negative predictive value to (100%) with total accuracy to (96.9 %). The best diagnostic performance was achieved in our study by combining MRI ADC value to TI-RADS scoring; increasing sensitivity to (100%), specificity to (95.9%), positive predictive value to (83.3%) and negative predictive value to (100%) with total accuracy of ( 98% ) (Table 6) & ( Fig. 6, 7, 8 & 9).

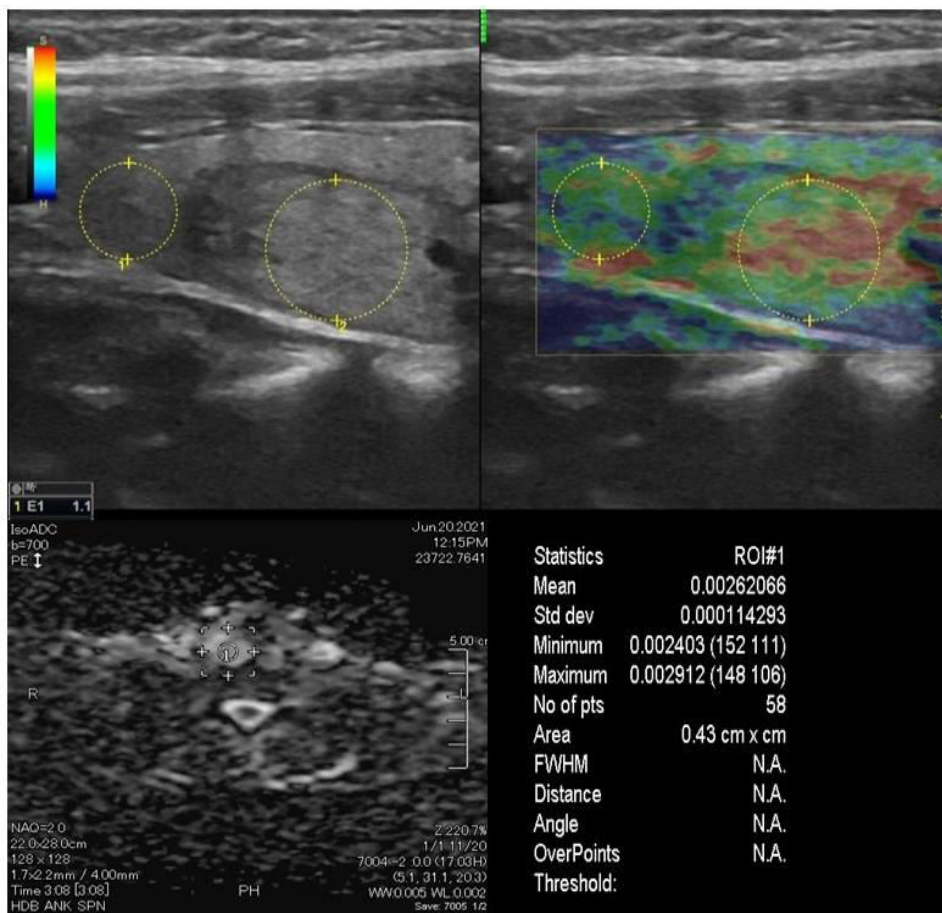
**Table 6. Diagnostic performance of multi-parametric analysis (TI-RADS+SR) & (TI-RADS+ADC value)**

Variable	Sensitivity	Specificity	PPV	NPV	Accuracy	p-value
<b>TI-RADS + SR</b>	100%	93.9%	76.9%	100%	96.9%	<0.001*
<b>TI-RADS + ADCvalue</b>	100%	95.9%	83.3%	100%	98%	<0.001*

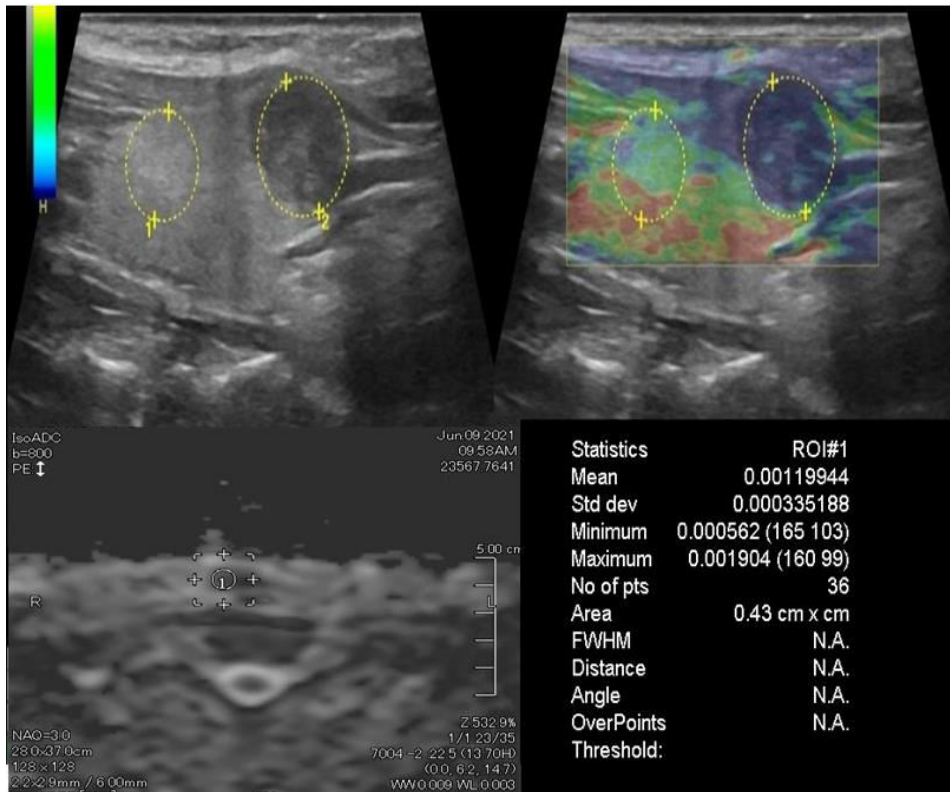




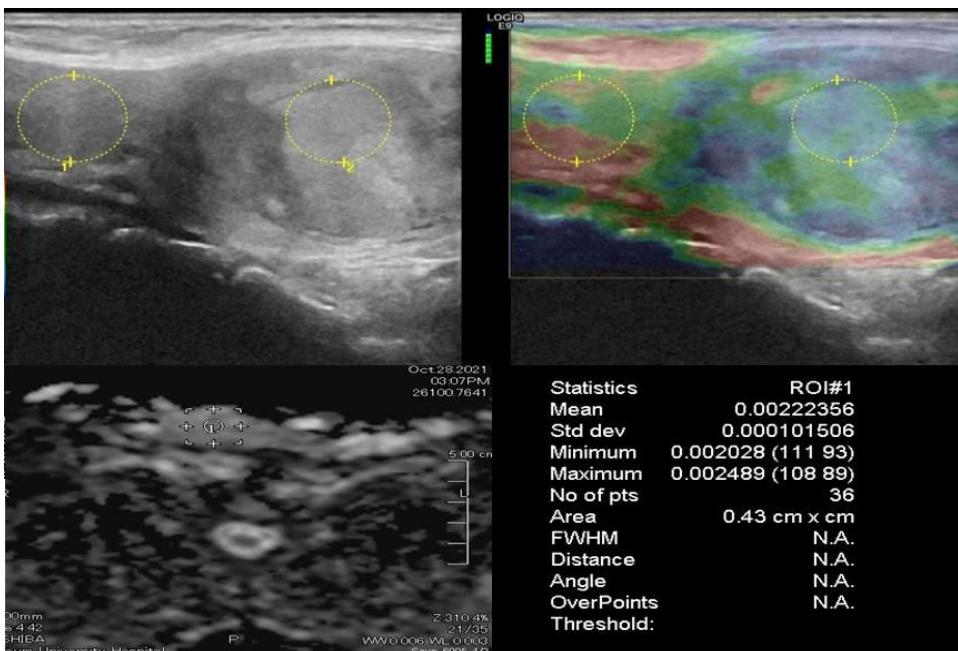
**Fig. 6. ROC curve for diagnostic performance of multi-parametric analysis (TI-RADS+SR) & (TI-RADS+ADC value); P value = <0.001\***



**Fig. 7. A 43 -year- old male with right thyroid nodule and normal thyroid profile.** Ultrasound shows right thyroid solid nodule with well-defined margin, iso echoic texture and no calcifications. It measures 2.5 x 2 cm. The nodule was given TI-RADS 3. ES was =1 and SR of about =1. The ADC value = 2.6 x10<sup>-3</sup>. Histopathology reveals benign thyroid nodule.



**Fig. 8.** A 45 -year- old female with right thyroid nodule and normal thyroid profile. Ultrasound shows right thyroid solid nodule with well-defined margin, iso to hypo echoic texture and no calcifications within. It measures 4 x 4 cm. The nodule was given TI-RADS 4. ES was = 3 and SR of about = 1.9. The ADC value =  $2.2 \times 10^{-3}$ . Histopathology reveals benign thyroid nodule.



**Fig. 9.** A 36 -year- old female with right thyroid nodule and normal thyroid profile. Ultrasound shows right thyroid solid nodule with well-defined margin, hypo echoic texture and no calcifications within. It measures 1.5 x 1 cm. The nodule was given TI-RADS 4. ES was = 4 and SR of about = 4.1. The ADC value =  $1.1 \times 10^{-3}$ . Histopathology reveals malignant thyroid nodule.

## Discussion

Thyroid nodules are the most common pathology involving the thyroid gland. Conventional thyroid ultrasound has been used as the first step in the evaluation of these nodules; but no single ultrasound criterion has been validated to precisely distinguish benign from malignant thyroid nodules (**Chen L, et al, 2016**).

The purpose of this study is comparative evaluation of the diagnostic performance of TI-RADS, elasticity score, strain ratio and quantitative diffusion MR weighted imaging (ADC value) in differentiating malignant from benign thyroid nodules.

This study is prospective. 59 patients (20 males and 39 females, mean age  $37.9 \pm 11.6$  years) with 59 thyroid nodules referred from the general surgery clinic for evaluation of thyroid nodules were included in this study. Conventional thyroid ultrasound with TI-RADS categorization, ultrasound strain elastography with elasticity score and strain ratio (SR), diffusion-weighted MR imaging with its quantitative parameter (ADC value) were measured for all nodules included in the study. The results were compared with the histopathology results, which were the standard reference.

Forty-nine patients (83.1%) had benign thyroid nodules (pathologically proven) and 10 patients (16.9%) had malignant lesions.

In this study; ACR TI-RADS scoring system was found to have (80%) sensitivity, (89.8%) specificity and (84.9%) accuracy in characterizing thyroid nodules. This agreed with the study done by **Kong W, et al, (2019)** on 137 thyroid nodules (86 benign and 51 malignant) which reported TI-RADS scoring to have

(84.2%) sensitivity, (80.4%) specificity and (86.9%) accuracy. Moreover; another study done by **Jabar A, et al, 2019** on 127 thyroid nodules found nearly similar results with (87.8%) sensitivity, (65.2%) specificity and (80%) overall accuracy for TI-RADS scoring system.

Using the 4-points Asteria's criteria for detection of elastography score (ES); we found that malignant nodules had statistically significant higher ES compared to benign nodules with (70%) sensitivity, (91.8%) specificity and (80.9%) accuracy when cutoff value=3 used. This is compatible with the study done by **Kyriakidou G, et al, 2018** on 84 thyroid nodules (73 benign and 11 malignant) and reported (73.0%) sensitivity, (87.8%) specificity and (79.9%) total accuracy for elasticity score in characterizing thyroid nodules.

The present study showed that the mean strain ratio (SR) for malignant nodules ( $2.9 \pm 1.2$ ) was significantly higher than that of benign nodules ( $1.57 \pm 0.71$ ). We also found that at a cutoff point of 1.65; the strain ratio had 90% sensitivity and 71.4% specificity with total accuracy of about 91.8%. **Latif M, et al, 2021** on 56 thyroid nodules (36 benign and 20 malignant) reported cutoff point for strain ratio=1.85 to differentiate malignant from benign thyroid nodules with sensitivity 80.0%, specificity 94.4% and overall diagnostic accuracy 89.3%; which agreed with our study results. **Lobna A, et al, 2016** also found that strain ratio at cutoff point=1.6 had sensitivity 89.0%, specificity 70% and overall diagnostic accuracy 86%.

We also found that the mean ADC value for malignant thyroid nodules ( $1.18 \pm 0.22 \times 10^{-3}$ ) was significantly lower than that for benign nodules ( $2.27 \pm$

0.27x10<sup>-3</sup>). At a cutoff point =1.45 x10<sup>-3</sup> for ADC value; the sensitivity was 80 %, specificity 95.9 % and total accuracy of about 98% in characterizing thyroid nodules. This agreed with the study of **Mohanty J, et al, 2019** on 50 thyroid nodules (30 benign and 12 malignant) which concluded that using cutoff value =1.3 × 10<sup>-3</sup> for MRI ADC had 100% sensitivity, 88.9% specificity and the overall accuracy was 95%. Furthermore; **Shokry A, et al, 2018** on 30 thyroid nodules (17 benign and 13 malignant) found that the use of cutoff value =1.15 × 10<sup>-3</sup> for ADC had sensitivity of about 88.2%, specificity 92.3% and overall accuracy of about 90%.

In the current study; we found that combination of US elastography and TI-RADS increased the diagnostic performance compared to elastography or TI-RADS alone. Adding the strain ratio (SR) to TI-RADS scoring increased the overall diagnostic accuracy to about (96.9%). This agreed with the study done by **Pei S, et al, 2020** which concluded that ultrasound elastography may be a valuable tool when combined with US TI-RADS scoring in distinguishing malignant from benign thyroid nodules; in their study SR had more accuracy than TI-RADS scoring (82% vs.75% respectively). Adding the strain ratio to the TI-RADS scoring increased overall diagnostic accuracy to about (86%). Our study results are also compatible with that of **Khalid E, et al, 2021** which stated that the strain ratio in combination with US TI-RADS scoring enhanced the overall accuracy of judging the risk of malignancy in thyroid nodules.

The best diagnostic performance in our study was achieved by adding diffusion ADC value to the ACR TI-RADS with sensitivity (100 %), specificity (95.9%) and

overall diagnostic accuracy (98%). This is compatible with the study done by **Latif M, et al, 2021** which concluded that adding diffusion-weighted MRI ADC value to the US TI-RADS scoring had the best diagnostic performance in characterization of thyroid nodules. In their study; they reported that diffusion-weighted MRI ADC value had higher diagnostic accuracy than TI-RADS scoring (96.4% vs. 82.1% respectively). Adding ADC value to the TI-RADS scoring enhanced the overall diagnostic performance and increased diagnostic accuracy to about (100%).

### Conclusion

Strain ratio and diffusion ADC value had higher diagnostic performance than US TI-RADS scoring in characterizing thyroid nodules. The best diagnostic performance in our study was achieved by combining diffusion ADC value to the ACR TI-RADS scoring with overall accuracy of about 98%.

### Study limitations

This study is a single-center study with a limited number of patients. Future large-scale multi-center studies are recommended to confirm the generalizability of this study results.

**Abbreviations:** ADC; Apparent Diffusion Coefficient, ACR TI-RADS; American College of Radiology Thyroid Imaging-Reporting and Data System, CUS; Conventional Ultrasound, FNAC; Fine Needle Aspiration Cytology, MRI; Magnetic Resonance Imaging, SR; Strain Ratio, US; Ultrasound, UE; Ultrasound Elastography, ES; Elasticity Score, ROI; Region Of Interest..

### Declarations

The study was approved by the Faculty of Medicine, Fayoum University Research Ethical Committee. Approval code number M533, Date 11/4/2021.

**Approval and consent to participate:** Informed written consent from patients who were invited to participate in the research were obtained.

**Consent for publication:** All authors have read and approved the final draft of the manuscript and approved the submission.

**Competing interests:** The authors declare they don't have a conflict of interest.

**Funding:** none

**Authors' contributions:** AM is the corresponding author, shared in conception, design of the work, analysis of the radiological findings, revised the statistics, results and discussion and drafting the initial manuscript. AA was responsible for data acquisition, analysis of the radiological findings, formulated the results and review search. AT was responsible for conception, design of the work and revising the final manuscript.

**Availability of data and materials statement:** The datasets used and/or analyzed during the current study are available from the corresponding author on reasonable request.

## References

- **Asteria C, Giovanardi A, Pizzocaro A, Cozzaglio L, Morabito A, Somalvico F, et al. (2008).** US-elastography in the differential diagnosis of benign and malignant thyroid nodules. *Thyroid*, 18(5):523-31. doi: 10.1089/thy.2007.0323. PMID: 18466077.
- **Chen L, Xu J, Bao J, Huang X, Hu X, Xia Y, et al. (2016).** Diffusion-weighted MRI in differentiating malignant from benign thyroid nodules: a meta-analysis. *BMJ Open*, 6:e008413. doi:10.1136/bmjopen-2015-008413.
- **Jabar A, Koteswara P, Andrade J (2019).** Diagnostic reliability of the thyroid imaging reporting and data system (TI-RADS) in routine practice. *Pol J Radiol*, 84:274–280.
- **Khalid Esmat, Sherihan Said, Noha Abdelrahman (2021).** Comparison between sensitivity and specificity of thyroid elastography and fine needle aspiration cytology in differentiating the nature of thyroid nodules, *QJM: An International Journal of Medicine*, 114(2, Supplement\_1): hcab106.051, <https://doi.org/10.1093/qjmed/hcab106.051>.
- **Kong W, Yue X, Ren J, Tao X (2019).** A comparative analysis of diffusion weighted imaging and ultrasound in thyroid nodules. *BMC Med Imaging*, 19:92.
- **Kratky J, Vitkova H, Bartakova J, Lukas J, Jiskra J (2016).** Neck muscles and content of carotid artery as reference tissue for strain ratio: a novel approach to improve the diagnostic performance of thyroid elastography. *Exp Clin Endocrinol Diabetes*, 124:192–19.
- **Kyriakidou G, Friedrich-Rust M, Bon D, Sircar I, Schrecker C, Bogdanou D, et al. (2018).** Comparison of strain elastography, point shear wave elastography using acoustic radiation force impulse imaging and 2D-shear wave elastography for the differentiation of thyroid nodules. *PLoS One*, 13(9):e0204095. doi: 10.1371/journal.pone.0204095. PMID: 30222755; PMCID: PMC6141102.
- **Latif M, El Rakhawy M & Saleh M (2021).** Diagnostic accuracy of B- mode ultrasound, ultrasound elastography and diffusion weighted MRI in differentiation of thyroid nodules (prospective study). *Egypt J Radiol Nucl Med*, 52:256 (2021). <https://doi.org/10.1186/s43055-021-00640-9>.
- **Lobna A, Ahmed M, Eman A, Yousra M (2016).** Role of ultrasound elastography in assessment of indeterminate thyroid nodules. *Egypt J Radiol Nucl Med*, 47(1):141-147, ISSN 0378603X, <https://doi.org/10.1016/j.ejrm.2015.11.002>.
- **Luguang C, Peipei S, Qiang H, Wei Y, Bing X, 1Chao M, et al. (2018).** Diffusion-weighted MRI in the evaluation of the thyroid nodule: Comparison between integrated-shimming EPI

and conventional 3D-shimming EPI techniques. *Oncotarget*, 9(40): 26209–26216.

• **Mao F, Xu HX, Zhou H, Bo XW, Li XL, Li DD, et al. (2018)**. Assessment of virtual touch tissue imaging quantification and the ultrasound thyroid imaging reporting and data system in patients with thyroid nodules referred for biopsy. *J Ultrasound Med*, 37:725–736.

• **Mohanty J, Mishra P (2019)**. Role of ACR-TIRADS in risk stratification of thyroid nodules. *Int J Res Med Sci*, 7(4):1039–1043.

• **Okasha H, Mansor M, Sheriba N, Assem M, Abdelfattah Y, Ashoush O, et al. (2021)**. Role of elastography strain ratio and TIRADS score in predicting malignant thyroid nodule. *Arch EndocrinolMetab*, 64(6):735-742. doi: 10.20945/2359-3997000000283. PMID: 34033283.

• **Pei S, Zhang B, Cong S, Liu J, Wu S, Dong**

**Y, et al (2020)**. Ultrasound Real-Time Tissue Elastography Improves the Diagnostic Performance of the ACR Thyroid Imaging Reporting and Data System in Differentiating Malignant from Benign Thyroid Nodules: A Summary of 1525 Thyroid Nodules. *Int J Endocrinol*, 2020:1749351. doi: 10.1155/2020/1749351. PMID: 32351557; PMCID: PMC7178472.

• **Shokry A, Hassan T, Baz A, Ahmed AS, Zedan M (2018)**. Role of diffusion weighted magnetic resonance imaging in differentiation of benign and malignant thyroid nodules. *Egypt J Radiol Nucl Med*, 49( 4): 1014-1021,ISSN 0378-603X,https://doi.org/10.1016/j.ejrm.2018.06.013.

• **Ueno E, Itoh A (2004)**. Diagnosis of breast cancer by elasticity imaging. *Eizo Joho Med*, 36(12):2-6.