

## PROSTHETIC COMPLICATIONS AND PERI-IMPLANT BONE LOSS OF SCREW- RETAINED IMPLANT-SUPPORTED FIXED HYBRID PROSTHESIS VERSUS IMPLANT RETAINED OVERDENTURE BY LOCATOR FOR REHABILITATION OF EDENTULOUS MAXILLA: A RANDOMIZED CLINICAL TRIAL

Mohamed Elgamal\*

### ABSTRACT

**Purpose:** This randomized controlled clinical trial study assessed prosthetic complications and peri-implant vertical bone loss (VBL) of screw retained fixed hybrid prostheses (FHP) and palate-less implant retained overdentures by locator (LOD) in patients with edentulous maxillae.

**Materials and methods:** Sixteen healthy completely edentulous patients were participated in this study. All patients were received four implants in maxillary arch in laterals and premolars areas and two implants in the mandibular canines regions. All patients received single design mandibular implant retained overdenture with locator attachment. According to the design of maxillary prosthesis there were two groups: 1) Group I (FHP, n=8): 2) Group II (LOD, n=8). Prosthetic complications were estimated after one year from prosthesis insertion. Digital radiography was used for VBL assessment around maxillary implants at insertion, 6 and 12 months. Statistical analysis was done by Chi-square test and Mann-Whitney.

**Result: Regarding prosthetic complication:** There was no statistically significance difference between FHP (Group I) and LOD (Group II) concerning the total frequency of prosthetic complications at prosthesis level ( $P=0.33$ ) and implant level ( $P=0.21$ ) for both types of restorations. **As regards VBL:** FHP (Group I) exhibited significantly higher VBL than LOD (Group II) at T12 ( $P=.031^*$ ).

**Conclusion:** Within the limits of this short term clinical trial, both FHP and LOD can be used successfully for rehabilitation of edentulous maxilla opposing mandibular implant overdenture with insignificant difference regard total frequency of prosthetic complications at prosthesis and implant level after one year. However, LOD was advantageous concerning reduced peri-implants VBL compared to the FHP.

**KEY WORDS:** Prosthetic complications, Implant overdenture, Locator attachment, Hybrid prosthesis, Peri-implant bone loss.

\* Lecturer of Prosthodontics Department, Faculty of Dentistry, Mansoura University, Mansoura, Egypt.

## INTRODUCTION

For majority of completely edentulous patients, when complaining about the palatal coverage and decreased retention and stability of their conventional maxillary denture, implant-assisted maxillary prosthesis is considered a valid option for edentulous patients as it enhances prosthesis masticatory efficiency, stability, satisfaction and oral health related quality of life in comparison to conventional dentures.<sup>1</sup>

Successful oral rehabilitation of edentulous maxilla with dental implants creates a great challenge<sup>2</sup>. Relying on the initial situation and mostly on the implants number installed, patients can be restored either with fixed or removable implant retained prosthesis<sup>3</sup>.

The full-arch fixed screw-retained hybrid prosthesis (FHP) was used with edentulous maxilla with deficient bone height in the posterior ridges above the maxillary sinus. Maxillary FHPs have been recommended originally by Brånemark for edentulous patients who had problems with conventional dentures<sup>4</sup>. Such prosthesis is fabricated on 4 or 5 implants installed parallel to each other's in the pre-maxillary region and composed of cast metal frameworks, denture bases, and denture teeth and retained by threading screws into the implant abutments. The prosthesis is fixed on implants in the anterior part while the posterior part is cantilevered from implants<sup>5</sup>. The FHP has fewer posterior teeth than a conventional complete denture<sup>6</sup>. The length of cantilever with 1.5 times the A/P spread were decided for such prostheses after clinical evaluation of initial situations that might biomechanically affect the biologic and/or prosthetic results of such cases<sup>7</sup>. As reported by other studies, full-arch FHPs are mostly used in implant treatment for edentulous patients and have established effective and a high success rate for long-term.<sup>8</sup>

On the other hand, implant retained maxillary overdentures could be effective treatment options

for patients suffering from poor retention and stability of conventional maxillary dentures<sup>9</sup>, such overdentures give acceptable phonetics, proper restoration of alveolar bone loss and lip support, satisfactory aesthetics and hygiene approach that is not achievable with a fixed maxillary prosthesis<sup>10</sup>. Compared with the mandible, implant-retained maxillary overdentures had many difficulties, like low bone volume and density, non-axial implants, and setting of teeth away from the implant axis, which rise stress transference to the implants<sup>11, 12</sup>. Thus, more implants numbers are required for maxilla than that of the mandible<sup>13</sup>, so at least a four implants agreement in the reviewed literature.<sup>10, 14-16</sup>

To retain overdentures to the implants many attachments can be used like non-splinted (ball, magnetic and stud) or splinted (bar/clip) attachments. The locator attachments are solitary, broadly used to retain overdentures, as they are resilient, self-seated, have valuable retentive forces<sup>17, 18</sup>. Locator attachments also are present in different heights, durable; and can be used with increased implant angulation<sup>19-22</sup>. Moreover, repair and resumption are quick and straightforward<sup>17, 23</sup>. Locator attachments revealed appropriate clinical and radiographic outcomes<sup>24</sup>, masticatory function<sup>25</sup>, and patient satisfaction<sup>26</sup> compared to other attachment systems. A little numbers of maintenance measures were needed for implant-retained overdentures retained by Locator® attachments than for those retained by ball and other types of attachments.

Dental implant success as a treatment option principally relies on the maintainable long-term health of hard and soft peri-implant tissues. Complications in implant prosthesis are divided into: biologic and mechanical complications. Biologic complications refer to interruptions in implant function that adversely affect the peri-implant tissues. These composed of early and delayed implant failures and unfavorable responses in the peri-implant soft and hard tissues. Mechanical complications refer

to mechanical deterioration of the implant, implant components, and suprastructures.<sup>27</sup>

Implant and prosthetic complications have been a persistent struggle for surgeons, restorative dentists, and patients alike. Implant-related problems can be specially challenging and frustrating, particularly given that an implant is thought to be a “lifetime” solution anticipated to produce minimal difficulties<sup>28</sup>. Prosthetic complications after the final prosthesis insertion may or may not result in implant failure but can lead to an increased need for repair and maintenance<sup>29</sup>. Relied on the results of preceding studies, both treatment options can therefore be represented as a well-accepted therapeutic choices that are accompanied with good biological and mechanical results. Up to now the frequency of complications and their recommendations of both FHP and LOD have been studied separately.

The aim of the present study was to compare the prosthetic complications and bone height changes around implant utilizing radiograph for full arch screw-retained implant supported fixed hybrid prosthesis versus implant-retained locator overdentures after 12 months follow-up during rehabilitation of edentulous maxilla opposing implant retained mandibular overdenture.

The hypothesis was that screw retained fixed hybrid prosthesis and overdenture retained with Locator® would not differ regard to prosthetic complications and peri-implant vertical bone loss (VBL).

## MATERIALS AND METHODS

This study was a randomized clinical trial (RCT) conducted on sixteen male patients presented on the outpatient clinic in Prosthodontics Department, Faculty of dentistry, Mansoura University, Egypt. The study was validated by the research ethical committee of Faculty of dentistry, Mansura University (01020418).

### Trial design

Parallel group, two arms, RCT with 1:1 allocation ratios.

### Selection criteria

**The inclusion criteria were** (1) completely edentulous patients have Angle Class I maxilla-mandibular relationship. (2) Age range between 45 and 60 years old. (3) Sufficient bone quantity in (class IV–VI) according to the classification suggested by (Cawood & Howell<sup>30</sup>) and quality (classes 1-3 according to Lekholm and Zarb<sup>31</sup>) in the interforaminal and premaxillary area to receive to receive standard implants of at least 11 mm length and 3.75 mm in diameter. (4) Maxillary and mandibular ridges with no history of current extraction. (5) Sufficient zone of keratinized attached mucosa >5mm over the crest of the upper and lower ridges. **The exclusion criteria were:** (1) Patients with any systemic diseases that could affect osseointegration of implants as uncontrolled diabetes, and osteoporosis ; (2) Patients with a past history of head and neck radiotherapy; (3) Heavy smokers patients who surpass 20 cigarette/ day ;(4) Para-functional habits like clenching or bruxism; (5) inadequate oral hygiene level.

### Patient examination

To decide that the patients were convenient with the inclusion criteria; a preliminary assessment was done. This evaluation involved a medical history form, a clinical evaluation, a radiographic examination (panorama and cone beam). The procedures were discussed with participants. If they accept to be included in the trial, written approval attained from them. For better participant’s communication Arabic versions of consent was printed.

### Patient grouping (randomization process)

Patients were randomly allocated to one of two parallel groups in 1:1 ratio where (Group I) included eight patients who received maxillary screw

retained fixed hybrid prosthesis and (Group II) included eight patients who received maxillary implant retained overdenture by locator. Both designs of maxillary prostheses opposed by mandibular implant retained overdenture by locator. The method used to make the random allocation series of the participants was a computer-created list of random numbers using a research randomizer (<https://www.randomizer.org/>). The randomization was done in manner that ensures equal distribution according to base characteristics in both groups.

The present study was a single blinded (Data analyst). The operator and patient are not blinded. Only the statistician was blind.

## **Surgical and prosthetic procedures**

### ***I- Surgical procedures:***

New dentures fabricated with the balanced occlusal scheme using semi-anatomic acrylic teeth were delivered to all participants. The participants were instructed to use the dentures for three months before implant placement to promote satisfactory neuromuscular control. The dentures duplicates were modified to a radiographic stents by preparing multiple holes (2mm depth and 2mm width) and filled with radiopaque gutta-percha in order to act as reference points during the construction of stereolithographic surgical guide and determine the amount of bone for implant placement<sup>32</sup>. Stereolithographic mucosal supported surgical guide was construction following dual scan technique using cone beam computerized tomography (CBCT, i- CAT Vision®, Imaging Sciences International, Hatfield, PA). Four parallel implants (at least 11 mm long and 3.75 mm wide) (TioLogic, Dentaurem) were installed in the maxilla. The planned implant sites were in the place of the lateral incisor and the premolar area just anterior to the wall of maxillary sinus and two implants with the same sizes placed in the mandible in canine regions, by means of guided surgery using submerged surgical approach and conventional delayed loading protocol. Implants

were installed by the same surgeon with a minimum torque of 35 Ncm to give high initial stability.

Participants were taken prophylactic antibiotic (875 mg Amoxicillin and Clavulanic acid 125 mg) one day before implant placement and continued after surgery for one week. Participants were asked to rinse their mouth with chlorohexidine mouthwash just before surgery and continue rinsing their mouth one week after surgery. During the osseointegration period, all participants used their dentures that had been relined with tissue conditioner (alpha-dent DENTAL TECHNOLOGIES. USA).

### ***II- Prosthetic procedures***

#### **Construction of mandibular implant retained overdenture:**

For all patients after osseointegration period, the locator attachments (tioLogic LOCATOR) were inserted and all patients were received single design of mandibular implant retained overdenture, where the mandibular complete denture was changed into implant retained overdenture by incorporating the housings of the locator attachments by direct pick up technique.

#### **According to design of maxillary prosthesis:**

##### ***A-For group I maxillary screw retained FHP was constructed as follows:***

After 3 months, the maxillary implants were uncovered. Straight multiunit abutments (AngleFix abutments, TioLogic, Dentaurem) were used and all abutments were torqued at 25Ncm. **fig 1**

Abutment level open tray impression procedure was made using a polyvinilsyloxane (Zhermack®, Badia Polesine, Rovigo, Italy). To minimize movement of the transfer coping during impression making, the copings were splinted with ligature wire and Duralay autopolymerized resin pattern (Duralay, Reliance Dental MFG Co, Worth, IL, USA) on the casts. The splinting resin bars between the implants were sectioned and assembled intraorally to



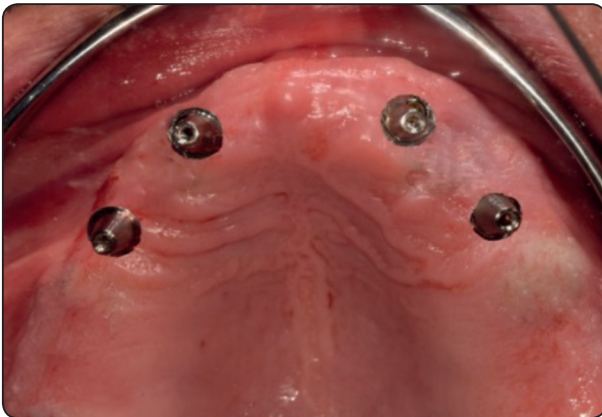


Fig (1): Multiunit abutments were screwed to the implants

obtain passive fit before making the impressions **fig 2 (A&B)**. On the cast, the plastic caps were connected to multiunit abutments. The caps were connected to each other's using a resin bar. Distal cantilevers were made (the length of each cantilever = anteroposterior spread distance<sup>33</sup>, mean cantilever length was  $14.2 \pm 2.1$  mm). The plastic cap-resin bar assembly was cast in a nonprecious cobalt-chromium alloy (Heraenium Pw, Heraeus-Kulzer GmbH, Hanau, Germany). The cast bar was tried intraorally for passivity using the single screw Sheffield test.

The cast bar was returned to the model and acrylic semi-anatomic artificial teeth were set at correct vertical dimension and centric relation. The

lost alveolar bone and gingival tissue were replaced by waxing up. The model was flaked, and the packing of acrylic resin was made in the usual manner. Finishing and polishing of the prosthesis after the restoration of access holes for prosthetic screws was made. The FHP has 12-unit artificial teeth<sup>6</sup> with cantilevers. The final prosthesis was delivered typically 3 months after surgery. The screws access holes were sealed with composite resin<sup>34</sup>. (**Fig 3**)

***B- For group II implant retained palateless maxillary LOD was constructed:***

A custom tray constructed over diagnostic cast was used to make the final impression using medium body rubber base impression material (Zhermack, Italy). The final impression was sent to the laboratory for fabrication of the palateless overdenture metal framework. After try in of the metal framework, jaw relation was registered. Final teeth set on the framework were tried in the patient's mouth then the final overdentures were processed, finished and polished.

The locator abutments were screwed in the internal hex of the implants using hex key at 25 Ncm torque (**fig 4**), the locator metal housing with black processing inserts were seated over the locator abutments after attaching the blocking white rings to the

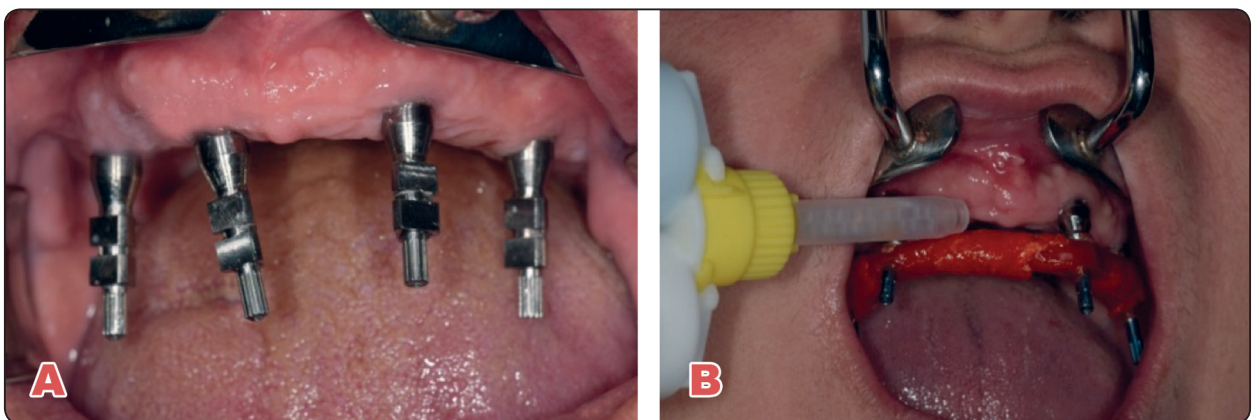


Fig. (2) (A&B). Abutment level impression was done: a) Screwing of transfer copings to the multiunit abutments. b-Injection of light body material around the copings after screwing the copings with attached resin bar segments to the multiunit abutments.

locator abutments the metal housings were picked up to the maxillary denture using self-cure acrylic resin after relieving the denture over the housings and the abutments while the patients holding the maxillary and mandibular dentures in centric occlusion and finally the black processing inserts were replaced by blue inserts (extra-light retention) and the dentures were delivered to the patients.

### Follow-up

#### I- Prosthetic complication:

During the 12-month follow-up period, prosthetic complications for FHP and LOD were recorded and calculated. Prosthetic complications related prosthesis and implant components were recorded by frequency of each event in both groups.

#### II- Radiographic evaluation

- Long-cone standardized periapical radiography was used for evaluation of peri-implant vertical bone resorption.
- A digital device (Digora, Soredex) was used to capture periapical x-rays.
- A film holder designed specifically for implant imaging (Rinn XCP, Rinn Co., dentsply, USA.) was used for intraoral radiograph.
- To detect magnification error implant dimensions in the radiographs were compared with the existing implant dimensions. This ratio allows us to obtain the real values of the bone changes.
- Crestal alveolar bone changes were determined along vertical plane as proposed by Elsyad et al.<sup>35-37</sup>
- Tracing of the digital images using the accompanying software (**fig5**) and measuring of bone height as the distance from implant-abutment junction to first bone- contact (A-B distance).
- Calculation of VBL by subtracting bone height values at T6 and T12 from values at T0.

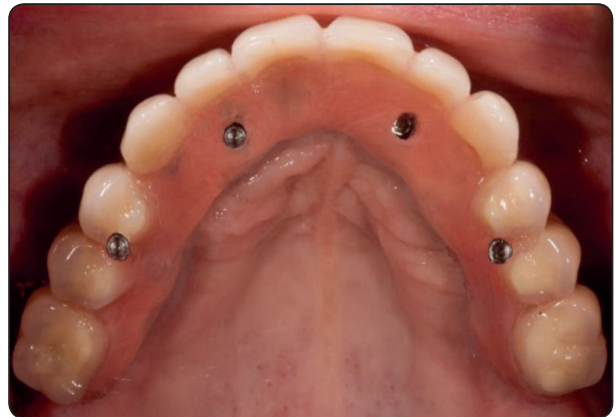

Fig. (3): Maxillary Final screw retained hybrid restoration in place during the follow up period

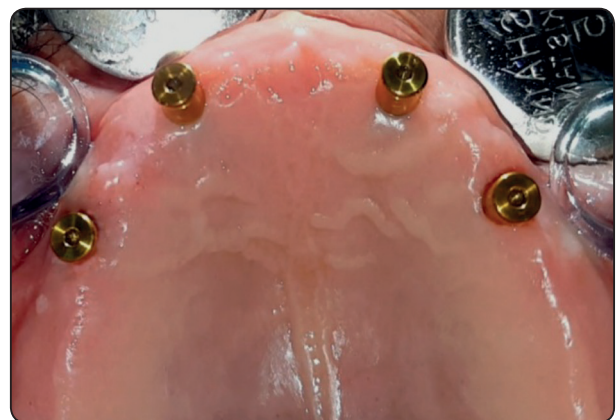

Fig. (4): locator abutments in place inserted intra orally after healing period.

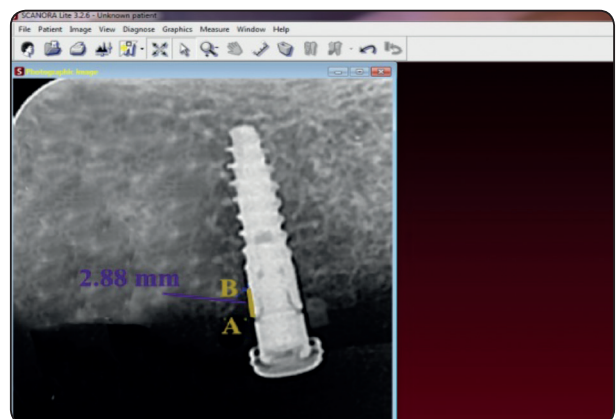


Fig (5) . Periapical X-ray with reference lines and points

### Statistical analysis

SPSS® software version 25 (SPSS Inc., Chicago, IL, USA) was used for data analysis. One-Sample Kolmogorov-Smirnov and Shapiro Wilk tests were used to diagnose normality of data distribution of all variables. The descriptive statistics of prosthetic complications for both groups were calculated in terms of frequency and percentages using frequency distribution (contingency) tables. To test the difference in proportions of prosthetic complications between groups, the Chi-square test was used. P-values <0.05 were considered to be significant.

Between-group comparisons of VBL were performed using Mann Whitney test. To detect significant differences between observation times for non-parametric data, Friedman test was used followed by Wilcoxon signed ranks test to compare between two times in the same group.

## RESULT

### *I- Prosthetic complications:*

In the present study 8 patients were included in FHP (Group I) and 8 patients were included in LOD (Group II). After the 12-month follow-up period, the results obtained from this study were tabulated and statistically analyzed.

**Regarding the frequency of prosthetic complications at prosthesis level according to the type of prosthesis are shown in table (1):** *In Group I:* the result of this study showed that acrylic tooth fracture in FHP occurred 3 times with a percentage of (37.5%). The fracture/ damage of acrylic flanges occurred one time with a percentage of (12.5%). Regarding the complications related to prosthesis in FHP, the acrylic tooth fracture showed the highest rate of complication (37.5%) during the follow up period. *In group II:* The result of this study showed that acrylic tooth fracture in LOD occurred 2 times with a percentage of (25%). The fracture or damage of acrylic parts occurred one time with a percentage

of (12.5%). Regarding the complications related to prosthesis in the LOD (Group II), the acrylic tooth fracture showed the highest rate of complication (25%) during the follow-up period. There were no prosthesis fractures occurred in both groups and the survival rate of the prosthesis was 100% in FHP and LOD groups. The result of this study revealed that there was no statistically significance difference between FHP (Group I), and LOD (Group II) regarding the total complications frequency related to prosthesis parts of both type of restorations (P = 0.33).

**Regarding the frequency of prosthetic complications related to the Implant components are shown in table (2):** *In group I,* the result of this study showed that the prosthetic screw loosening in FHP occurred 2 times during the follow-up period with a percentage of (25%). No abutment fracture, abutment or prosthetic screw fracture were occurred. *In group II,* the result of this study showed that locator nylon insert replacement in LOD due to wear and distortion with new one occurred two times with a percentage of (25%). The loosening of locator abutment occurred one time with a percentage of (12.5 %). Regarding the complications frequency of implant components in LOD (Group II), the need for locator nylon insert replacement showed the highest rate of complication (25%) during the follow-up period.

The result of this study revealed that there was no statistically significance difference between FHP (Group I) and LOD (Group II) regarding the total complications frequency of implant components of both type of restorations (P = 0.21)

### *II- Radiographic parameters: (VBL)*

- Descriptive statistics [mean (SD)] of VBL at different observation times for groups are shown in **table (3).**
- VBL significantly increased from T6 to T12 for both groups (p=0.042 and 0.005) for FHP and LOD respectively.

- **Comparison between observation times:**
- Multiple comparisons between each 2 observation times are presented in the same table. For both groups, VBL at T12 was significantly higher than T6.
- **Comparison between FHP and LOD groups**
- There was a significant difference in VBL between groups at T12 only ( $p=0.031^*$ ). FHP recorded higher VBL at T12 than LOD.

TABLE (1): Frequency of complications related to prosthesis (denture) in FHP (Group I) and LOD (Group II) during the follow up period.

Frequency of complications related to prosthesis (denture)				
	Without complications	With complications	chi square	P-value
FHP (Group I)	4 (50%)	4 (50%)	0.912a	0.33
LOD (Group II)	5 (62.5%)	3 (37.5%)		

\*Statistically significant at  $P \leq .05$ .

TABLE (2): Frequency of complications related to the implant components in FHP (Group I) and LOD (Group II) during the follow up period.

Frequency of complications related to the implant components				
	Without complications	With complications	chi square	P-value
FHP (Group I)	6 (75%)	2 (25%)	1.013a	0.21
LOD (Group II)	5 (62.5%)	3 (37.5%)		

\*Statistically significant at  $P \leq .05$ .

TABLE (3): Comparison of VBL between observation times and between groups.

	T6	T12	Wilcoxon signed ranks (p value)
Vertical bone loss (VBL)			
FHP (Group I) X±SD	0.71±.08b	0.99±.13a	0.005*
LOD (Group II) X±SD	0.68±.10b	0.79±.10c	0.042*
Mann-Whitney Test (p value)	0.10	*0.031	

X; mean, SD; standard deviation. \* P is significant at .05. Different letters in the same row indicate significant difference between each 2 observation times (Wilcoxon signed ranks test,  $p < .05$ )



## DISCUSSION

In the present study, there was insignificant difference in total prosthetic complications frequencies at prosthesis and implant levels in both treatment options either maxillary FHP or LOD prosthesis, thus, the hypothesis was accepted regarding prosthetic complications part. In contrast, the hypothesis was rejected in respect to VBL around implant as FHP (Group I) show significant higher amount of VBL compared to LOD (Group II).

Based on the results of earlier separate studies, prosthetic rehabilitation of maxilla either by screw-retained fixed restorations or locator overdentures were considered as a positive therapeutic options that are associated with favorable biological and mechanical results. Till now there are no ongoing studies in the dental literature that directly compare prosthetic complications and amount of VBL of both implant assisted complete screw-retained fixed restorations and locator overdentures simultaneously so we conduct our study.

Implant survival is not only the key of successful outcome of a specific type of rehabilitation, but also biological and prosthetic complications play a main role<sup>38</sup>. A follow-up of 12 months was chosen in the present study as specified by Johansson and Palmqvist,<sup>39</sup> as earlier studies have revealed that prosthetic complications took place both through the first year after treatment and in the long term, though it was revealed that the rate of complications decreases over time. Proper clinical and radiographic examination is needed for the noticing of such complications. This can be verified by certain criteria which involve VBL around peri-implant surfaces.

### **Regarding the frequency of prosthetic complications related to prosthesis parts (denture):**

The result of this study revealed that there was no statistically significance difference between FHP (Group I) and LOD (Group II) regarding the total frequency of complications of prosthetic parts of both

types of restorations ( $p=0.33$ ). Although, the acrylic tooth fracture showed the highest rate of complication in both groups, (37.5%) in FHP and (25%) in LOD group during the follow-up period. Comparably, McGlumphy et al,<sup>40</sup> reported that tooth fracture as the main prosthetic complication after a 10-year prospective study for implant-supported maxillary full-arch acrylic prostheses<sup>41</sup>. The increased acrylic teeth wear and fracture for both groups may be due to the decreased prosthetic space for acrylic resin resulted from the increased thickness of the metal substructure which may ease acrylic teeth separation and fracture. However, it was easy to solve the problem by adding new teeth of the same shade utilizing autopolymerized acrylic resin.<sup>42</sup>

There were no prosthesis fractures happened in both groups and the survival rate of the prosthesis was 100%. On the opposite, Zarb and Albrektsson noted that implant frameworks of cantilevered screw retained fixed hybrid prostheses were at risk of fracture, mainly at the junctions between distal abutments and cantilevered segments<sup>43</sup>. The lack of prosthetic fracture in both groups may be due to cushion effect to the applied load provided by the use of acrylic resin teeth. In addition, reinforcing the acrylic prosthesis by the increased thickness of the metal framework that prevents its fracture compared to the metal-ceramic prosthesis that shows tendency to fracture at the junction of distal abutments and cantilevers.

### **Regarding the frequency of prosthetic complications related to implant components:**

The result of this study revealed that there is no statistically significance difference between FHP (Group I) and LOD (Group II) regarding the total frequency of complications related to implant components in both type of restorations ( $P = 0.21$ ).

In the current study, prosthetic screw loosening showed the highest rate of complication in the FHP (Group I) with a percentage of (25%). This could be attributed to the adverse occlusal loading on the cantilever extension that was reported to cause

loosening of abutment and prosthetic screws. In this study, for FHP the mean length of the cantilever was 14.2mm which is quite high as it has been advocated that the extension from the midpoint of the most distal implant must not exceed 15 mm<sup>6</sup>. In line with our findings, McAlarney and Stavropoulos<sup>7</sup> reported that loading cantilevers increased loads distributed to implants in full-arch clinical cases which could lead to increased prosthetic screw loosening. Similarly, Baldin Able et al.<sup>44</sup> reported screw loosening is the common implant parts complications of cantilevered hybrid mandibular fixed complete-arch dental prostheses. However, they added that cantilever length was not linked with significant prosthetic complications. In a more recent study, the authors noted that complication-free prostheses were obtained when constructing the frameworks for screw retained hybrid prostheses with cantilever length/Antroposterior spread ratios less than 1.00<sup>45</sup>. Also many factors may cause screw complications such as deficient preload on the screws, over tightening of the screws may cause stripping and/or screw distortion.<sup>40</sup>

On the other hand, for LOD (Group II) the need for new locator nylon insert for in LOD (group II) showed the highest rate of complication (25%) through the follow-up period. Locator attachment due to wear and deformation of the nylon inserts which require replacement of the nylon male part. This coincides with Kleis et al<sup>23</sup> who concluded that follow-up for patients with locator attachment is required to manage distortion and damage of nylon inserts. Furthermore, it has been recently mentioned<sup>46</sup> that the uses of more implants lower the number of prosthetic complications, and deformity of the nylon inserts of the Locator attachment. However, the increased number of implants for maxillary overdentures in this study did not reduce the complications frequency of locator nylon insert. This could be attributed to the increased labial inclination of the implants in the premaxillary region due to the anatomy of the bone. This generates angula-

tion between anterior and posterior locator attachments. This angulation was reported to increase the wear and damage of the locator nylon inserts.<sup>21, 22, 47</sup>

No abutment fracture occurred in both groups or abutment and prosthetic screw fracture were recorded in FHP (Group I). Similar to our finding, no abutment or abutment screw fractures were recorded for implant-supported maxillary, full-arch acrylic prostheses<sup>41, 48</sup>. This may be attributed to the opposing dentition which is removable 2- implant retained complete overdentures in both groups thus transmitting reduced forces to the implant compared to natural dentition or fixed prosthesis during function and parafunction<sup>49</sup>. Also, the acrylic teeth had a cushion (shock-absorbing) effect. All these factors lead to a significant reduction of occlusal forces and the absence of abutment, and prosthetic screw fractures. Conversely, Hemmings et al, reported clinical problems that involved: abutment screw fracture, gold alloy retaining screw fracture that occurred especially with cantilevered portions of the hybrid prosthesis<sup>50</sup>. However, these complications are mostly linked with the existence of natural teeth in the opposing jaw or with increase occlusal force factor caused by increased strength of the masticatory muscles (young patients) or the incorporation of patients with bruxism.

#### **Regarding radiographic evaluation of peri-implant tissues**

Although, the result of the present study expressed significant VBL after 12 months from insertion for both FHP ( Group I):  $0.99 \pm 0.13$ mm and LOD ( Group II) :  $0.79 \pm 0.10$ mm, it is still within the allowable clinical range of VBL, which is comparable to other studies that concluded that VBL around peri-implant surfaces which should not be beyond 1–1.2mm during the first year of function and 0.2mm thereafter.<sup>51, 52</sup> Based on these criteria, all VBL in both designs was within the reasonable values for implant successful outcomes.

For both groups, VBL was significant higher at T12 compared to T6. In the same way Elsyad et

al.<sup>35</sup> found that the VBL increased after one year compared to values at 6 months for two implants retaining mandibular overdentures with locator and magnetic attachments. The authors attributed the increased loss of bone to the bone reaction to prosthesis loading and bone reorganization in addition to functional stresses.<sup>53</sup>

The results significantly revealed less VBL at the LOD (group II) than at the FHP (Group I). A comparable observation was also found in other studies<sup>54,55</sup>. The FHP (Group I) showed significantly higher bone loss than the LOD (Group II) ( $P < .001^*$ ). In line with this observation, van Zyl et al.,<sup>56</sup> reported that cantilever extension of fixed hybrid screw retained prosthesis beyond 14mm may cause increased stress in the buccal and lingual sides of the implants, which may cause microfracture of the bone, and/or bone resorption when the interfacial strain reach overload zone.<sup>57</sup> Also, Sertqoz and Guvener<sup>58</sup> reported that when increasing cantilever length, stresses significantly increased and they added that stresses at the bone/implant interfaces were maximized at the most distal bone/implant interface on the loaded sides. On the other hand, the decreased VBL with LOD (Group II) compared to FHP (Group I) may be attributed to the reduced vertical height of locator attachments compared to multiunit abutment. Another explanation is the vertical resiliency supplied by locator attachment. In addition, the facility of cleaning of these attachments reduced the gingival index and periodontal index which in turn reduces the VBL.<sup>35</sup>

We should acknowledge the small sample size and short-term follow-up as a limitation in this study. Therefore, a platform for future clinical research with larger cohorts and long-term follow-up is recommended to assess the prosthetic complications and peri-implant bone loss of various maxillary implant-assisted prostheses.

## CONCLUSION

**Within the limitations of this study when rehabilitating edentulous maxilla by 4 parallel implants it could be concluded that**

- Both FHP and LOD can be used successfully for rehabilitation of edentulous maxilla opposing mandibular implant overdentures with favorable prosthetic outcomes after one year as it was associated with non-significant difference in total frequencies of prosthetic complications at prosthesis level and implant level.
- LOD was advantageous regarding preservation of peri-implant bone as patients rehabilitated with LOD resulted in less VBL around implant than those with FHP.

## REFERENCES

1. Attard NJ, Zarb GA. Long-term treatment outcomes in edentulous patients with implant-fixed prostheses: the Toronto study. *Int J Prosthodont.* 2004;17:417-24.
2. Santagata M, Guariniello L, D'Andrea A, Tartaro G. A modified crestal ridge expansion technique for immediate placement of implants: a report of three cases. *J Oral Implantol.* 2008;34:319-24.
3. Krennmair G, Süt D, Seemann R, Piehslinger E. Removable four implant-supported mandibular overdentures rigidly retained with telescopic crowns or milled bars: A 3-year prospective study. *Clin Oral Implants Res* 2012;23:481-88.
4. Branemark. I, Zarb. G, Albrektsson. T. *Tissue Integrated Prostheses.* Chicago, Quintessence. 1985;pp 51-70, 117-128.
5. Adell R, Lekholm U, Rockler B, Branemark PI. A 15-year study of osseointegrated implants in the treatment of the edentulous jaw. *Int J Oral Surg.* 1981;10:387-416.
6. Jain AR, Nallaswamy D, Ariga P, Philip JM. Full mouth rehabilitation of a patient with mandibular implant screw retained Fp-3 prosthesis opposing maxillary acrylic removable over-denture. *Contemp Clin Dent.* 2013;4: 231-5.
7. McAlarney ME, Stavropoulos DN. Theoretical cantilever lengths versus clinical variables in fifty-five clinical cases. *The Journal of prosthetic dentistry.* 2000;83:332-43.

8. Ibrahim W, Kaddah A, ElKhadem A. Maintenance Requirements of Screw- Retained Implant Prosthesis versus Telescopic Overdenture: A Randomized Controlled Trial. *IJSR* 2016;5:1818-1823.
9. Emami E, De Souza R, Kabawat M, Feine J . The impact of edentulism on oral and general health. *Inter J of Dent.* 2013; 2013: 7.
10. Al-Zubeidi M, Alsabeeha N, Thomson W, Payne A. Patient satisfaction with maxillary 3-implant overdentures using different attachment systems opposing mandibular 2-implant overdentures. *Clin Impl Dent and Related Res.* 2012; 14:11–9.
11. Kronstrom M, Widbom C, Soderfeldt B. Patient evaluation after treatment with maxillary implant-supported overdentures. *Clin Implant Dent Relat Res.* 2006; 8:39–43.
12. Akca K, Akkocaoglu M, Comert A, Tekdemir I, Cehreli MC. Human ex vivo bone tissue strains around immediately loaded implants supporting maxillary overdentures. *Clin Oral Implants Res.* 2005; 16:715-22.
13. Zou D, Wu Y, Huang W, Wang F, Wang S, Zhang Z et al. A 3-year prospective clinical study of telescopic crown, bar, and locator attachments for removable four implant-supported maxillary overdentures. *Int J Prosthodont.* 2013; 26:566-73.
14. Kiener P, Oetterli M, Mericske E, Mericske-Stern R. Effectiveness of maxillary overdentures supported by implants: maintenance and prosthetic complications. *Int J Prosthodont.* 2001; 14:133-40.
15. Slot W, Raghoobar GM, Vissink A, Huddleston Slater JJ, Meijer HJA. A systematic review of implant-supported maxillary overdentures after a mean observation period of at least 1 year. *J Clin Periodontol* 2010; 37: 98– 110.
16. Andreiotelli M, Strub J-R. Prosthodontic complications with implant overdentures: a systematic literature review. *Int J Prosthodont* 2010; 23: 195– 203.
17. Chung KH, Chung CY, Cagna DR, Cronin RJ, Jr. Retention characteristics of attachment systems for implant overdentures. *J Prosthodont.* 2004; 13:221-6.
18. Evtimovska E, Masri R, Driscoll CF, Romberg E. The change in retentive values of locator attachments and hader clips over time. *J Prosthodont.* 2009; 18:479-8.
19. Ahuja S, Cagna DR. Classification and management of restorative space in edentulous implant overdenture patients. *J Prosthet Dent.* 2011; 105:332-37.
20. Mackie A, Lyons K, Thomson WM. Mandibular two-implant overdentures: three-year prosthodontic maintenance using the locator attachment system. *Int J Prosthodont.* 2011; 24:328-31.
21. Uludag B, Polat S, Sahin V. Effects of implant angulations and attachment configurations on the retentive forces of locator attachment-retained overdentures. *Int J Oral Maxillofac Implants.* 2014; 29:153-57.
22. Srinivasan M, Kalberer N, Maniewicz S. Implant overdentures retained by self-aligning stud-type attachments: a clinical report. *J Prosthet Dent.* 2020; 123:6-14.
23. Kleis WK, Kammerer PW, Hartmann S, Al-Nawas B, Wagner W. A comparison of three different attachment systems for mandibular two-implant overdentures: one-year report. *Clin Implant Dent Relat Res.* 2010; 12:209-18.
24. Abi Nader S, de Souza RF, Fortin D, et al. Effect of simulated masticatory loading on the retention of stud attachments for implant overdentures. *J Oral Rehabil.* 2011; 38:157-64.
25. Guédat C, Nagy U, Schimmel M, et al. Clinical performance of Locator attachments: a retrospective study with 1-8 years of follow-up. *Clin Exp Dent Res.* 2018; 4:132-45.
26. Scrascial R , Martinolli M, Venezia P, Casucci A, Ortensi L, Tallarico M . Feasibility of low profile attachments to improve quality of life on patients with implant-retained mandibular overdenture: 1-year preliminary results of a multicenter prospective case series study. *OHDM* 2018; 17:1-5.
27. Berglundh T, Persson L, Klinge B. A systematic review of the incidence of biological and technical complications in implant dentistry reported in prospective longitudinal studies of at least 5 years. *J Clin Periodontol* 2002;29:197-212.
28. Link-Bindo EE, Soltys J, Donatelli D, Cavanaugh R. Common Prosthetic Implant Complications in Fixed Restorations. *Compend Contin Educ Dent.* 2016;37:431-6;quiz9.
29. Pappaspyridakos, P., Chen, C. J., Chuang, S. K., Weber, H. P., & Gallucci, G. O. A systematic review of biologic and technical complications with fixed implant rehabilitations for edentulous patients. *The International journal of oral & maxillofacial implants* 2011; 2:102- 110
30. Cawood JI, Howell RA. A classification of the edentulous jaws. *Int J Oral Maxillofac Surg* 1988; 17: 232-236.



31. Lekholm U, Zarb G. Patient selection and preparation. In: Branemark PI, Zarb G, Albrektsson T, eds. *Tissue integrated prosthesis: osseointegration in clinical dentistry*. Chicago. Quintessence Publishing Co Inc. 1985:199-209.
32. Abdelhamid AM, Hanno KI, Imam MH. A prospective cross-over study to evaluate the effect of two different occlusal concepts on the masseter muscle activity in implant-retained mandibular overdentures. *Int J Implant Dent* 2015; 1: 32.
33. Mericske-Stern RD, Taylor TD, Belser U. Management of the edentulous patient. *Clin Oral Implants Res*. 2000;11 Suppl 1:108-25.
34. Sannino G, Bollero P, Barlattani A, Gherlone E. A Retrospective 2-Year Clinical Study of Immediate Prosthetic Rehabilitation of Edentulous Jaws with Four Implants and Prefabricated Bars. *J Prosthodont*. 2017;26:387-94.
35. Elsyad MA, Mahanna FF, Elshahat MA, Elshoukoui AH. Locators versus magnetic attachment effect on peri-implant tissue health of immediate loaded two implants retaining a mandibular overdenture: a 1-year randomised trial. *J Oral Rehabil*. 2016;43:297-305.
36. Elsyad MA, Elsayh EA, Khairallah AS. Marginal bone resorption around immediate and delayed loaded implants supporting a locator-retained mandibular overdenture. A 1-year randomised controlled trial. *J Oral Rehabil*. 2014;41:608-18.
37. Elsyad MA, Shoukoui AH. Resilient liner vs. clip attachment effect on peri-implant tissues of bar-implant-retained mandibular overdenture: a 1-year clinical and radiographical study. *Clin Oral Implants Res*. 2010;21:473-80.
38. Maló P, de Araújo Nobre M, Lopes A, Ferro A, Botto J. The All-on-4 treatment concept for the rehabilitation of the completely edentulous mandible: A longitudinal study with 10 to 18 years of follow-up. *Clin Implant Dent Relat Res*. 2019.
39. Johansson G, Palmqvist S. Complications, maintenance in edentulous arches with implant-supported fixed supplementary treatment, and prostheses. *Int J Prosthodont*. 1990; 3:89-92.
40. McGlumphy EA, Mendel DA, Holloway JA. Implant screw mechanics. *J Dent Clin North Am*. 1998; 42:71-89.
41. Fischer K, Stenberg T. Prospective 10-year cohort study based on a randomized, controlled trial (RCT) on implant-supported full-arch maxillary prostheses. part II: prosthetic outcomes and maintenance. *Clin Implant Dent Relat Res*. 2013;15:498-508.
42. Goodacre CJ, Bernal G, Rungcharassaeng K, Kan JY. Clinical complications with implants and implant prostheses. *J Prosthet Dent* .2003; 90:121-32.
43. Zarb GA, Albrektsson T. *Tissue-integrated prostheses: osseointegration in clinical dentistry*: Quintessence Pub Co; 1985.
44. Able FB, de Mattias Sartori IA, Thome G, Moreira Melo AC. Retrospective, cross-sectional study on immediately loaded implant-supported mandibular fixed complete-arch prostheses fabricated with the passive fit cementation technique. *J Prosthet Dent*. 2018;119:60-6.
45. Drago C. Ratios of Cantilever Lengths and Anterior-Posterior Spreads of Definitive Hybrid Full-Arch, Screw-Retained Prostheses: Results of a Clinical Study. *J Prosthodont*. 2018;27:402-8.
46. Stephens GJ, di Vitale N, O'Sullivan E. The influence of inter implant divergence on the retention characteristics of locator attachments, a laboratory study. *J Prosthodont* 2014; 23:467-75.
47. Rabbani S, Juszczak AS, Clark RK. Investigation of retentive force reduction and wear of the locator attachment system with different implant angulations. *Int J Oral Maxillofac Impl* 2015; 30:556-63.
48. Ragheb N, Abada H, Issa D. Prosthetic Maintenance And Peri- Implant Tissue Conditions Of Fixed Screw-Retained Implant Prosthesis Versus Implant-Retained Ball Overdentures: A randomized Clinical Trial. *Egypt. Dent. J*. 2021;67: 1-15.
49. Tashkandi EA, Lang BR, Edge MJ. Analysis of strain at selected bone sites of a cantilevered implant-supported prosthesis. *J Prosthet Dent*. 1996;76:158-64.
50. Hemmings KW, Schmitt A, Zarb GA. Complications and maintenance requirements for fixed prostheses and overdentures in the edentulous mandible: a 5-year report. *International Journal of Oral & Maxillofacial Implants*. 1994;9.
51. Kamburoğlu K., Gulsahi A, Genç Y, Paksoy CS. A comparison of peripheral marginal bone loss at dental implants. measured with conventional intraoral Im and digitized ra-diographs. *J Oral Implantol*.2012; 38: 211–19.
52. Kamburoğlu K, Murat S, KılıçÇ, Yüksel S, Avsever H, Farman A, Scarfe WC. Accuracy of CBCT images in the

- assessment of buccal marginal alveolar peri-implant defects: effect of field of view. *J DMFR*. 2014; 43:20130332.
53. Hohlweg-Majert B, Metzger MC, Kummer T, Schulze D. Morphometric analysis - Cone beam computed tomography to predict bone quality and quantity. *J Craniomaxillofac Surg*. 2011;39:330-4.
54. Eitner S, Schlegel A, Emeka N, Holst S, Will J, Hamel J. Comparing bar and double-crown attachments in implant-retained prosthetic reconstruction: A follow-up investigation. *J Clin Oral Implants Res*. 2008;19:530 – 537.
55. Elsyad MA, Khirallah AS. Circumferential bone loss around splinted and nonsplinted immediately loaded implants retaining mandibular overdentures: A randomized controlled clinical trial using cone beam computed tomography. *J Prosthet Dent*. 2016;116:741–748.
56. Zyl van PP, Grundling NL, Jooste CH, Terblanche E. Three-dimensional finite element model of a human mandible incorporating six osseointegrated implants for stress analysis of mandibular cantilever prostheses. *Int J Oral Maxillofac Implants*. 1995;10:51-7.
57. Malhotra AO, Padmanabhan TV. Load transfer in tilted implants with varying cantilever lengths in an all-on-four situation. *Australian dental*, 2012. 2012.
58. Sertgoz A, Guvener S. Finite element analysis of the effect of cantilever and implant length on stress distribution in an implant-supported fixed prosthesis. *J Prosthet Dent*. 1996;76:165-9.