

ASSESSMENT OF BONE DENSITY CHANGES AROUND TWO VERSUS FOUR IMPLANTS SUPPORTING TELESCOPIC RETAINED OVERDENTURES. A RADIOGRAPHIC EVALUATION

Khaled Aziz Abdelwahab*, Noha ElAdl** and Nesma Awaad***

ABSTRACT

Objectives: The aim of this study was to assess changes in bone density in patients received telescopic retained overdentures supported either by two or four dental implants placed inter-foraminally.

Methodology: Twenty patients were divided into two groups to receive telescopic retained overdenture supported either by two implants in the canine area or four implants placed in the inter-foraminal area. Bone density changes were assessed throughout the first year of service (0,3,6,12 months) in patients with an edentulous mandible receiving telescopic retained overdenture. Telescopic overdenture was designed to consist of a primary coping screwed to implant and a secondary coping attached to the fitting surface of the framework. Bone density was assessed using the Digora software.

Results: When comparing the bone density results throughout the study period (0,3,6,12 months), there was no statistically significant difference between (Two implants) and (Four implants) groups. When comparing the average values of bone density along the whole study period, it revealed a non-significant difference between the two groups.

Conclusion: Within the limitation of this study, the use of a properly distributed two or four inter-foraminal implants with telescopic attachments to support and retain an overdenture revealed good bone density results after a one-year follow-up.

KEY WORDS; Bone density, Telescopes, overdentures, Implant numbers

* Associate Professor, Department of Prosthodontics, Cairo University, New Giza University

** Researcher, Surgery and Oral medicine Department, National Research; Cairo, Egypt

*** Lecturer Department of Prosthodontics, Faculty of Dentistry, Cairo University

INTRODUCTION

The use of dental implants as a line of treatment for restoring missing teeth has been widespread considerably for the past two decades with promising outcomes.¹ In order to properly achieve these outcomes several factors should be considered, a combination of patient related and procedure factors including patient's general health condition, implants bio-compatibility, surface texture, surgical procedure, quantity and quality². Bone quality is equivalent in implant literature to bone density; which is defined as the amount of mineral per square centimeter of bone³. Completely edentulous patients exhibit difficulties especially with the mandibular denture due to; smaller areas for support, retention and stability. For restoring a completely edentulous mandible there are different treatment modalities depending on patient's oral situation. Mandibular implant overdenture retained by two implants was considered the minimum requirement for treatment of mandibular edentulous.⁴ However; recent studies are dealing with the increase in the number of the implants in order to improve patient satisfaction and quality of life, which may be attributed to the increase in retention, stability and Occlusal equilibrations. The controversy of using how many implants still under debate, which is affected by the anatomical variation oral condition patient finance and operator skills and preference.⁵ There are different attachment systems can be used in concern to the fabrication of removable implant retained overdentures, mostly used connection systems between implants and overdentures are: bars, balls with metal clips, locators, magnets, and telescopes.⁶

The Use of double crowns for bony support of removable partial dentures on implants (IRPDs) was proposed for the edentulous mandible from the mid-1990s⁷. Telescopic attachments have the advantage of the ease of insertion and removal which encourages the patient for repeated maintenance and hygienic measures. They have a self-seating mechanism which make the prosthesis insertion easier for geriatric patients or with those having

a serious systemic disease as in patients suffering parkinsonism⁸

The needed retention provided by the telescopic attachments especially gained with the parallel-sided type which depend on frictional fit, sufficient height for the abutment (primary coping) should be obtained which in turns necessitates the presence of enough inter-arch distance. When using telescopic attachment; Careful assessment of the inter-arch space is very critical; to have a sufficient space needed for the accommodation of primary and secondary coping in addition to enough denture base thickness to avoid fracture. Also, space needed for proper setting-up of artificial teeth to meet the esthetic requirements⁹. This study was made to assess the effect of telescopic implant retained overdenture retained by two or four implants on bone density after one year of loading.

MATERIALS AND METHODS

Patient selection

Patients were recruited to have completely edentulous maxillary and mandibular arches with Angle class I maxilla-mandibular relationship and sufficient restorative space not less than 15 mm. Adequate buccolingual bone width covered by firmly attached keratinized mucosa. All patient were selected with good physical and psychological condition to tolerate conventional implant surgical protocol. Patients were excluded if they had any systemic disease that may interfere with dental implants placement and/or osseointegration e.g., uncontrolled diabetes, hypertension, osteoporosis and irradiation. Heavy smoker (more than 20 cigarette / day). Additionally, patients with parafunctional habits (e.g., clenching or bruxism, etc.) or suffering from temporomandibular joint disorders were also excluded.

New complete dentures were fabricated to patient that don't already have dentures; those having old dentures; their dentures were assessed for proper retention, stability and condition of artificial teeth if found unsatisfactory new dentures

were fabricated. Dentures were fabricated following the conventional method and duplicated for constructing a radiographic stent to be used during CBCT imaging. A preoperative CBCT scan* was taken for the patient's mandibular arch with the scan appliance. The resultant image was obtained as DICOM (digital imaging and communications in medicine) data on a compact disc. Patients were randomly divided into two groups: Group I: patients receiving two implants at the canine area. Group II: patients receiving four implants distributed in the intra-foraminal area. After CBCT scan, the DICOM images were then imported to planning software** in order to plan for the implant placement.

For the patients receiving two implants the virtual planning was made to the area at the two canines; but for the patients receiving 4 implants, planning was made in the inter-foraminal area. Implants placed according to the virtual model planning following the protocol of two staged surgery. Root formed tapered implants*** were placed using sequential drilling recommended by the manufacturer. 3.5mm×10mm and 3.5mm×11.5mm were used for posterior and anterior implants respectively. Three months later second stage surgery was made and healing abutments were placed for proper gingival healing.

Two week later after proper soft tissue healing, impressions were made by using a splinted open tray implant level impression technique. Verification jig was constructed to ensure passivity and accuracy of the impression. Any discrepancy in passivity was treated by sectioning of the jig and reassembly then remaking the impression. Primary jaw relation was then recorded to mount the casts to a semi-adjustable articulator and trial setting up of teeth was made. Scores were done on the buccal aspect of the cast then an index was made with putty rubber base impression material to show the available space

for the primary copings occluso-gingivally and labio-lingually to estimate the exact space needed for the secondary copings and the framework to be constructed.

Primary copings were constructed using UCLA castable TI base abutments**** which were adjusted on the milling machine and was milled creating tapered abutments with its axial walls 2° in its taper and 5-6mm in its length with a deep chamfer finish line. Primary copings were then cast into cobalt chromium alloy, finished, polished, and tried inside the patient's mouth to ensure proper fit. Finally, the primary copings were placed on the cast and scanned, the secondary copings as well as the framework were designed and the milled using a CAD-CAM***** machine, then tried intraorally to verify the proper seating of the framework. Framework was designed to allow some degree of freedom in which it was fabricated to be fitted lingually without engaging the labial surface at all. (Figure 1&2).

Healing abutment were removed from patient mouth and the primary coping screwed in position by the use of an abutment jig and torqued to 25 N. Secondary copings were placed over the primary coping using another jig for the secondary coping for proper orientation, then the framework was tried and aligned in position with the primary and the secondary coping. (Figure 2)

In order to ensure proper passivity between the framework and the secondary coping, intra-oral luting technique using resin cement***** was performed followed by overall alginate impression picking up the secondary coping and the framework together (Figure 3). The obtained cast with proper attached assembly is now ready to construct a mandibular occlusion block to register jaw relation for mounting after attaching the whole assembly.

* PLANMECA Pro max 3D mid, Finland

** Blue sky Bio, LLC. Planning software

*** Neo Biotech Co. Ltd, Seoul, Korea

**** New Biotech ISUCH400, Korea

***** SHERA Werkstoff-Technologie GmbH & Co. KG, Germany

***** Nova resin cement

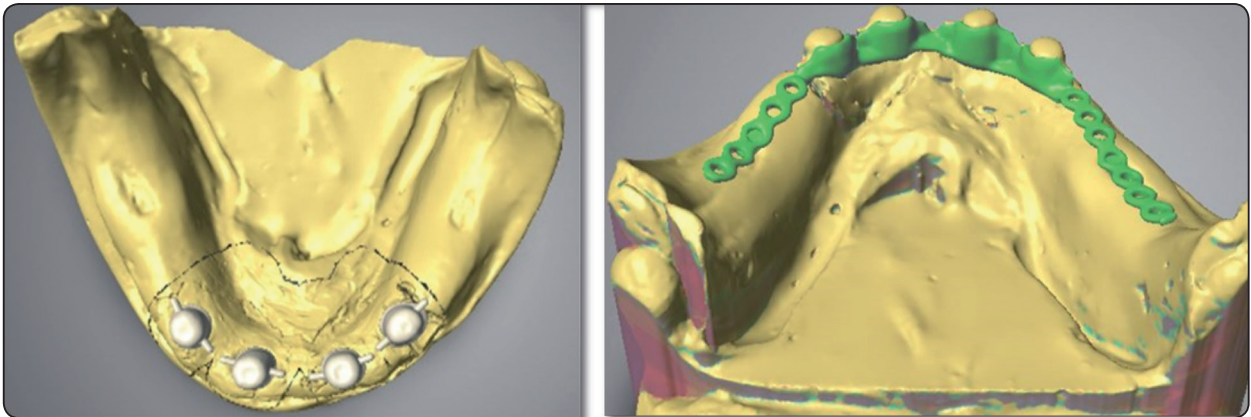


Fig. (1): Scanning of the primary copings & CADing of the secondary copings and the framework.

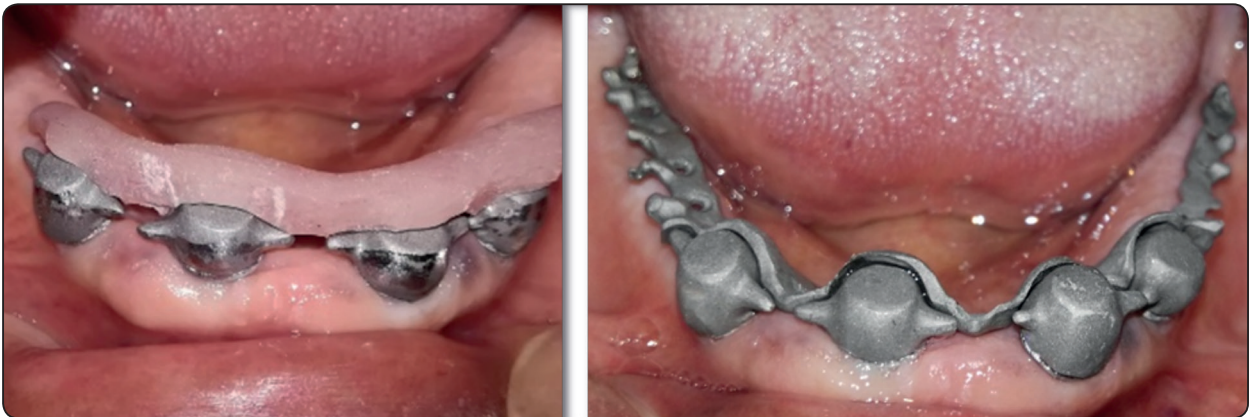

Fig. (2): The Jig for proper orientation of the secondary copings and the framework in place

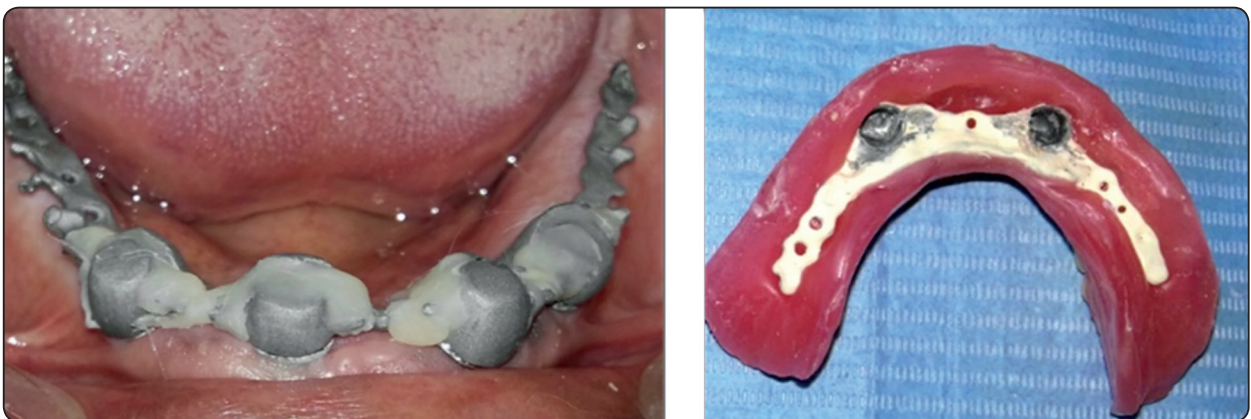


Fig. (3) A: Intra oral cementation of the secondary coping and the framework (B): waxing up of the denture and framework with opaque material

Try-in for the lower denture was made to evaluate the proper insertion of the denture containing the framework and secondary coping; with the primary coping. Waxed denture base including the framework and the secondary coping was then processed to the final prosthesis, finished and polished to be delivered to the patient. Lower denture was checked for proper insertion of the secondary coping in the fitting surface of the denture, with the primary telescopic abutment in patient's mouth.

The denture retention was evaluated and checked, occlusion was checked and verified by using articulating papers; high occlusal spots were identified and removed till equal Occlusal contacts occurred.

Bone density was measured using Digora digital radiographic system*. Radiographs were taken at the following intervals at the day of delivery of the final prosthesis (loading Day) and after 3, 6 and twelve months of delivery (one year). The long cone parallel technique was used for making a reproducible and standardized images during the follow-ups. At the time of the exposure the lower denture was removed to allow for proper film alignment in front of the target abutments. Rubber base index was made to allow for film stabilization against the upper denture in order to stabilize the film during exposure. Then, the film was removed

from film holder and placed inside Digora scanner opening. The images for each patient were saved in a separate files with the patient's name till the end of the follow-up periods for interpretation.

All baseline images were electronically stored into a computer's memory, and then projected onto a monitor as an array of 512 x 512 pixels with 256 gray levels to be assessed with the post-operative serial images at the end of the study period to eliminate any measurement errors.

Density measurement tool supplied by the Digora software offers assessment using point brightness in a grade from 0 to 254. These points are measured automatically in the area or line signed in the "Density Measurement Mode" of the Digora Software. The mean is calculated as well as a curve of the distribution of point density or brightness. For measuring bone density area measurement (area density index) was used A rectangular area was marked including the area of each implant apical, mesial and distal areas to measure the mean of density in the bone area. (Figure 4). As the applied software does not allow hands free measurement, only rectangular measurements for the sites were standardized for reproducibility of measurements on all serial images by using the "start and end" as well as the "x and y coordinate" options present within the Digora software tool box. (Fig.6)

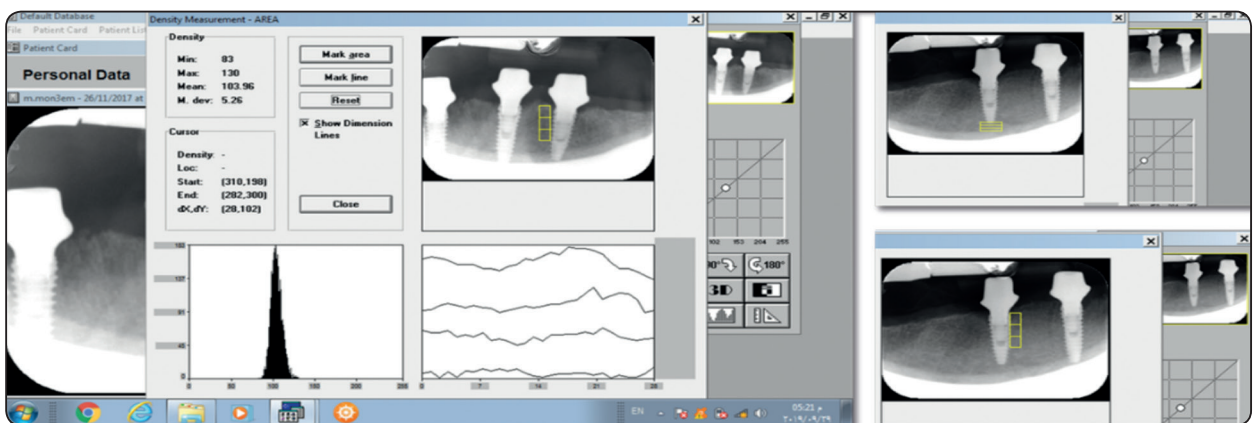


Fig. (4): Measurement & calculation of the mean bone density around implants

* Digora Computerized system, Helsinki, Finland

RESULTS

The mean and standard deviation values were calculated for each group in each test. Data were explored for normality using Kolmogorov-Smirnov and Shapiro-Wilk tests, data showed parametric (normal) distribution.

Independent sample t-test was used to compare between two groups in non-related samples. The significance level was set at $P \leq 0.05$. Statistical analysis was performed with IBM® SPSS® Statistics Version 20 for Windows.

When comparing the bone density results throughout the study period (0,3,6,12 months), There was no statistically significant difference between (Two implants) and (Four implants) groups. The highest mean values (Higher bone quality) were always found in group II (four-implant group at all time intervals

When comparing the average values of bone density along the whole study period, it revealed a non-significant difference between the two groups. The highest mean value (Higher bone quality) was again found in group II (four-implant group)

TABLE (1): representing bone density in two groups along the study period

Variables	Bone density							
	Baseline		After 3m		After 6m		After 12m	
	Mean	SD	Mean	SD	Mean	SD	Mean	SD
Two implants	167.78	9.43	159.38	10.37	165.88	11.78	172.58	9.43
Four implants	176.13	8.49	169.53	14.02	176.93	14.40	180.13	5.92
<i>p-value</i>	0.052^{ns}		0.082^{ns}		0.077^{ns}		0.050^{ns}	

ns; non-significant (p>0.05)

TABLE (2): The mean, standard deviation (SD) values of bone density in different groups.

Variables	Bone density	
	Mean	SD
Two implants	172.58 ^a	10.09
Four implants	185.13 ^a	7.77
<i>p-value</i>	0.058^{ns}	

ns; non-significant (p>0.05)

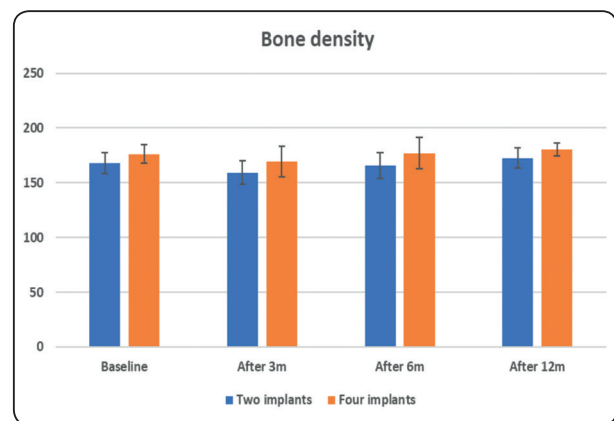


Fig. (5) Bar chart representing bone density in two groups along the study period

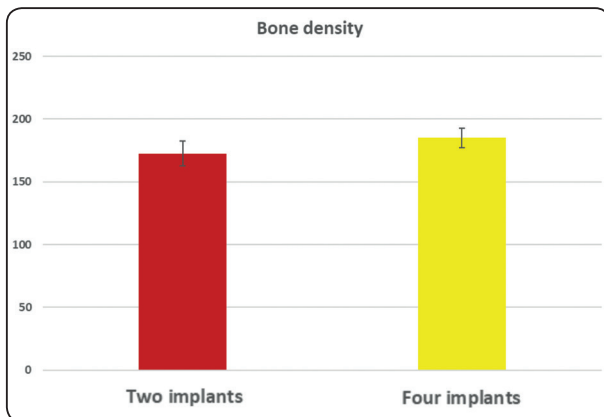


Fig. (6): Bar chart representing mean bone density results between the two groups.

DISCUSSION

Generally, all the patients who contributed in this study were happy with their implant supported overdenture. The prostheses were highly acknowledged by the patients, the enhanced retention and stability allowed quicker and convenient adaptation period with less post insertion complaints. They all accommodated well to their dentures and could use it effectively few days after delivery. The only complaint reported by most of the patients was that they became not pleased with the retention of their maxillary denture.

In this study the bone density was measured by using digital radiography (Digora) where Digital radiography was introduced into dental practice as an alternative to film-based radiography to reduce the radiation dose without compromising the image quality. Digora achieved the best contrast at lower exposure and demonstrated a better dose response.¹⁰

The results of bone density for this study showed to be satisfactory throughout the study period between the two groups. This may be attributed to many factors. First of all is the meticulous surgical approach and careful tissue handling, in addition to good surgical fit which provides good implant to bone contact and primary stability of implants during

placement. Second, the type of prosthesis which is an implant-tissues supported prosthesis that shares the load between the ridge and the implant, thus protecting the implants from unfavorable overload. Third, careful patient selection excluding those with ridge relation discrepancies (Angle's class II and III) and those with previous history of bruxism. This helped to avoid implant overload as much as possible. The selection of the anterior part of the mandible also allows for superior bone quantity and quality which made bone remodeling within the permissible range.^{11,12} It should be noticed that the opposing restoration was upper complete denture that exerts less load on opposite arch compared to natural dentition or fixed restorations.¹³ Finally, we should also mention that the direct intraoral luting technique between the secondary copings and the framework produced a totally passive superstructure that will not exert any unfavorable loads to the implants which is clearly reflected in the results of the current study¹⁴.

Bone density changes showed to be statistically insignificant between the two groups along study period. This might be attributed to reason that the nature and design of the prosthesis is using the implants as a source of support only and not retention. Additionally, the support of such type could be gained also from the posterior edentulous ridge. Moreover, the meticulous patient selection is also a factor as only patients with good bone quality and quantity were recruited in this study. All these factors diluted the effect of the number of used implants to support the overdenture.^{15,16}

In both groups, the bone density mean values decreased significantly at the 3-month interval and then increased again. This can be explained by the Bugee dip which is the drop in the implant stability that may have occurred after loading the implants due to the bone modeling/remodeling process and was reflected on the bone density values.^{17&18}

CONCLUSION

Within the limitation of this study, using a properly distributed two or four intra-foraminal implants and telescopic attachments to support and retain an over dentures revealed good bone density results after a one-year follow-up, taking in consideration meticulous surgical and the prosthetic procedure with good patient selection. More clinical studies are still needed to monitor the behavior of the pre-implant bone density in different clinical situations

REFERENCES

1. Brånemark PI: An introduction to osseointegration. Tissue-integrated Prostheses: Osseointegration in Clinical Dentistry. Edited by: Brånemark P-I, Albrektsson T. 1985, Chicago: Quintessence, 11-53.
2. Turkyilmaz, I., Tözüm, T.F., Tümer, C. (2007). Bone density assessments of oral implant sites using computerized tomography. *J Oral Rehabil*, 34, 267–72.
3. Molly L. Bone density and primary stability in implant therapy. *Clin Oral Implants Res* 2006 ;17(suppl 2):124–135
4. Fiene JS, Carlsson GE, Awad MA, Chehade A, Duncan WJ & Gizani S (2002). The McGill consensus statement on overdentures. Montreal, Quebec, Canada. *Int J Prosthodont*. 15 ; 413-414.
5. Rocuzzo M, Bonino F, Gaudio L, Zwahlen M, Meijer HJA (2012). What is the optimal number of implants for removable reconstructions? A systematic review on implant-supported overdentures. *Clin Oral Implants Res*. 23; 229–237.
6. Preoteasa E, Marin M, Imre M, Lerner H & Preoteasa CT. (2012). Patients' satisfaction with conventional dentures and mini-implant anchored overdentures, *Rev Med Chir Soc Med Nat Iasi*. 116; 310-316
7. Frisch E, Ratka-Krüger P & Lehmann KM (2014). Clinical outcomes of implant-supported and rigidly double crown-retained prostheses in edentulous mandibles: An 8-year retrospective study.
8. Beschnidt SM, Chitmongkolsuk S, Prull R (2001). Telescopic crown retained removable partial dentures: Review and Case report. *Compend Contin Educ Dent*. 22; 927-928.
9. KunWarjeet S, NiDhi G (2012). Telescopic Denture-A Treatment Modality for Minimizing the Conventional Removable Complete Denture Problems: A Case Report *Journal of Clinical and Diagnostic Research*. 6; 1112-1116.
10. Comparison of imaging characteristics of Digora fmx and Digora Optime storage phosphor plate systems Erinc, Önem, Elif Sogur, B. Gu'niz Baksi (2012). *Journal of dental science*. 7; 43-47
11. Akca, K., A. Eser and S. Canay (2010). Numerical simulation of the effect of time-to-loading on peri-implant bone. *Med Eng Phys* 32;7-13.
12. Anitua, E., R. Tapia, F. Luzuriaga and G. Orive (2010): Influence of implant length, diameter, and geometry on stress distribution: a finite element analysis. *Int J Periodontics Restorative Dent* 30; 89-95.
13. Olate S, Lyrio MC, de Moraes M, Mazzonetto R, Moreira RW (2010): Influence of diameter and length of implant on early dental implant failure. *J Oral Maxillofac Surg*. 68;414-9.
14. Baig MR, Gunaseelan R (2012). Intraoral framework pick-up technique to improve fit of metal resin implant prosthesis. *Indian J Dent Res*. 23;435-6.
15. Pérez-Pevida E, Cherro R, Camps-Font O, Piqué N (2020). Effects of Drilling Protocol and Bone Density on the Stability of Implants According to Different Macro geometries of the Implant Used: Results of an In Vitro Study. *Int J Oral Maxillofac Implants*. 35;955-964
16. Romanos G, Lau J, Zhang Y, Hou W, Delgado-Ruiz R (2021). Macro geometry and Bone Density Control Over the Primary Stability of 6-mm Implants: An In Vitro Study. *Int J Oral Maxillofac Implants*. 36;322-326.
17. Rosen, P. S. (n.d.). Measurement of the "Bungee Dip" in Implant Stability Using Resonance Frequency Analysis: Two Case Reports. *Compendium of Continuing Education in Dentistry* (Jamesburg, N.J. : 1995), 39(10), 706–712.
18. van Eekeren, P., Said, C., Tahmaseb, A., & Wismeijer, D. (2015). Resonance Frequency Analysis of Thermal Acid-Etched, Hydrophilic Implants During First 3 Months of Healing and Osseointegration in an Early-Loading Protocol. *The International Journal of Oral & Maxillofacial Implants*, 30(4), 843–850.