

BIOLOGICAL AND PROSTHETIC COMPLICATIONS OF OVERDENTURES HAVING TELESCOPIC ATTACHMENTS MADE FROM PEKKTON® IVORY/ ZIRCON VS SCREW RETAINED HYBRID PROSTHESIS IN THE REHABILITATION OF COMPLETELY EDENTULOUS MANDIBLE USING FOUR WIDELY DISTRIBUTED IMPLANTS. A RANDOMIZED CLINICAL TRIAL

Osama Askar* and Mai Ahmed Haggag**

ABSTRACT

Purpose: This clinical trial was conducted to evaluate the biologic and prosthetic complications that may occur after one year of using either telescopic PEKK/Zircon overdentures (TOD) or fixed screw retained hybrid prosthesis (FHP) in completely edentulous lower cases that have four widely distributed implants.

Materials and methods: Ten participant received four parallel implants in the canine and first molar areas. They were divided randomly into two groups: Group 1 received FHP and Group 2 received TOD. Biological and prosthetic complications were measured immediately and after one year from prosthesis insertion for comparison. Chi-square test was used to compare between groups.

Results: In both groups no implant failure reported. There was no significant difference regarding implant failure, implant survival, pain, swelling, abscess, fistula formation, peri-implantitis, peri-implant mucositis, bleeding on probing between groups. There was no complication reported regarding cylinder fracture nor abutment fracture or prosthetic screw fracture. But screw loosening of the telescopic abutment and prosthetic screw in the TOD and FHP respectively was noticed. In the prosthetic level, a significant ($P=0.010$) complication was reported in the form of wear in opposing complete dentures teeth in the FHP group.

Conclusion: FHP and TOD can be used successfully for rehabilitation of completely edentulous mandible treated with four widely distributed implants with favorable biologic and prosthetic outcomes after one year. Telescopic implant overdentures have superior soft tissue condition related to easy hygiene accessibility by patients. Using PEKK is a promising choice in the construction of implant supported fixed or removable prosthesis.

KEYWORDS: Telescopic overdenture, poly-ether-ketone-ketone, hybrid prosthesis

* Assistant Professor, Department of Prosthodontics, Mansoura University, Faculty of Dentistry

** Assistant Professor, Department of Oral and Maxillofacial Surgery, Mansoura University, Faculty of Dentistry.

INTRODUCTION

Dental implants are considered as a successful treatment option for many years in solving the problems of losing stability, poor retention, poor masticatory efficiency and patient's dissatisfaction in the conventional complete dentures wearers especially in the lower jaw.⁽¹⁾ Lower completely edentulous residual ridge have some inherent factors like smaller supporting area, mobility of the floor of the mouth, proximity to tongue, thin mucosal coverage, thin knife edge residual ridges, superficial mylohyoid ridge or mental nerves, the movable nature of the lower jaw and if the maxillary teeth exist or fixed restorations, which increases the complains from lower complete dentures.^(2,3)

In order to consider all the previous factors during the rehabilitation of lower completely edentulous ridge, a total implants supported prosthesis of four or more implants is indicated to construct prosthesis without loading the mucosa and alveolar ridge.⁽⁴⁾ The totally implant supported prosthesis can provide less mucosal pressure and irritation⁽⁵⁾, increased support, retention, stability, and decreased bone resorption due to reduction of forces transmitted to the residual ridges⁽⁶⁾.

Implant distribution play an important role in the biomechanics of prosthesis which may effect on the long term success of treatment. Increasing the anteroposterior spread of implants and decreasing the cantilever length of prosthesis is biomechanically advantageous and produce nearly prosthetic complication free prosthesis.⁽⁷⁾ That can be achieved in cases treated with All- on-four concept or four parallel implants with the posterior implants placed in the molar area.

PEKK (Pektkon®ivory) was introduced more recently and it stands at the apex of the polyararyl-ether-ketone PAEK family, it has high wear resistance and high compressive, flexural, and tensile strength, it is 80% higher in compressive strength than *PEEK*. And it has better long-term

fatigue properties than unreinforced *PEEK*. Which may be related to the addition of titanium dioxide (TiO₂) and the second ketone group that increased bonding strength of polymer and backbone rigidity with increased hardness and wear resistance, and increase in glass transition and melting temperature⁽⁸⁾ *PEKK* has a similar compressive strength (246 MPa) to that of bone and tooth dentine (297 MPa)⁽⁹⁾, shock absorption, and it is the material of choice for the construction of the framework for implant supported full arch prosthesis because of its light weight and compatibility with different veneering materials, in addition it can be milled or heat-pressed, and it was used successfully in implant overdenture attachments.^(8,9)

Two main prosthetic options are available for the total implant supported prosthesis either removable (removed by patient) or fixed (removed by dentist). The fixed screw retained hybrid prosthesis option was firstly constructed by Brånemark back in the eighties to solve the problems from the conventional complete dentures.⁽¹⁰⁾

The fixed prosthesis attached to implants either by screw or by cement. Screw retained restorations have shown over the years' successful results, regarding load distribution and irretrievability but their construction is very sensitive and requires high accuracy during all steps of construction in order to obtain passivity in the final restoration.⁽⁷⁾

Removable option for implant supported prosthesis have many different mechanisms of attachments that allows patients removal and insertion of the prosthesis by their own selves without the need to visit doctor, and practice their own oral hygiene measures daily in home below the prosthesis and around implant abutments. One of the most successful options of attachments is the telescopic attachment which is considered as an evidence based treatment modality with high success rate with variable options of materials and taper design.⁽¹¹⁾

Telescopic attachments are composed of primary (inner) and secondary (outer) crowns. According to

the design and taper of the primary and secondary Copings. They are either *resilient*, conical design of primary coping with occlusal and axial gap between primary and secondary copings which allows movements between them, retention was gained through wedging action after complete seating between the copings, the other form is *rigid* telescopic attachment with parallel wall design of the primary coping with no gap between the primary and secondary copings retention was gained from frictional contact between precisely milled parallel walls. ⁽¹²⁾

Different materials combination can be used in the construction of telescopic primary and secondary copings, like stainless steel, Titanium, Zirconia, Electric gold plated surfaces, *PEEK*. Using zirconia as a primary coping was tested by many authors(9, 13, 14) and proved to be a successful material in telescopic attachments.

Telescopic attachments have many advantages including easy hygiene, self- insertion ability easy patient handling, high retention, high stability, small size not utilize space in the overdenture with minimal interference to tongue space or affection on comfort, eating or pronunciation of sounds. ^(15, 16)

The use of high performance polymers in the telescopic crown construction showed superior results and maintenance of retention forces for longer time^(14, 17), and solved the problem of metal show through the overdenture in metallic secondary crowns⁽¹⁸⁾. On the other hand, Zirconium oxide (Zirconia) showed mechanical and biological properties that overcome gold alloy material.^(19, 20)

We have two forms of implant supported complication that may occur which can be used in the comparison and follow up of prosthesis. They are either *biologic complications* of the peri-implant soft and hard tissues. Or *Prosthetic complications* in the form of mechanical injuries to implants and their prosthetic parts and superstructure and the demand of repair and services which in turn affect implants' rehabilitation success. ^(21, 22)

According to the knowledge of the authors, there were limited studies to date compared clinically between selecting the combination between Zirconia primary coping and PEKK secondary telescopic coping over four widely distributed implants in the rehabilitation of completely edentulous mandible cases and comparing it to the screw retained total implant supported fixed prosthesis with frame work constructed from PEKK, which it is the aim of our work.

MATERIALS & METHODS

This study was carried on ten patients from the outpatient clinic of prosthodontic department in Faculty of Dentistry, Mansoura University, Egypt. All participants were complaining from lower complete denture and seeking for more stability and retention. Their old dentures were evaluated to have balanced occlusal scheme using semi-anatomic acrylic teeth otherwise, new denture was constructed and delivered to all participants. They were Healthy with no systemic disease related to bone resorption and their age was ranged between 50 and 60 years with mean age of 55year. Completely edentulous residual alveolar ridges covered with healthy mucosa. They had sufficient bone height anteriorly and posteriorly which can facilitate the placement of four implants, two at canine area with 3.5 mm diameter and 12 mm length and two at first molar area 4 mm diameter and 10mm length, (blueSky. Bredent. Germany) which was confirmed by cone beam computed tomography (CBCT). They have sufficient restorative space not less than 15mm⁽²³⁾ for the lower prosthesis with normal maxillomandibular relation (class I) as detected by evaluating their lower complete denture dimensions. The participant who had one of the following was excluded from the study 1) serious problems of coagulation, 2) diseases of the immune system or long term immunosuppressive drugs and corticosteroid drug therapy 3) uncontrolled diabetes, 4) metabolic diseases affecting bone, 5) irradiation

of the head or neck region in the last 2 years, and 6) inadequate oral hygiene level. 7) hepatic patients 8) osteoporotic patients. 9) Abnormal detrimental habits, e.g. bruxism, clenching or heavy Smoking. The patients were instructed about the treatment protocol and objectives prior to obtain an informed consent. The research followed the declaration of Helsinki of ethical principles for medical research involving human subjects.

All participants received four parallel implants two at the canine area and two at the first molar area. They were randomly sub divided into two groups using a quasi-random method by random generated numbers generated in Excel sheet. Each group had 5 participants. The participants in **group one** were received screw retained fixed hybrid prosthesis (FHP) constructed from Poly-ether-ketone-ketone (PEKK) Pekkton® ivory (Pektkon Ivory; Cendres+Métaux) frame work with solitary jacket crowns from zolid restoring teeth and pink light cured composite that take the shape of gingiva. While in **group two** the participants received telescopic complete implant overdenture. The telescopic attachment was formed from Zircon/PEKK combination.

Surgical and prosthetic procedures

All participants had conventional complete dentures. The lower denture was modified by adding radiopaque reference points made of composite which helped in superimposition in the dual scan technique using cone beam device (CBCT, i-CAT Vision®, Imaging Sciences International, Hatfield, PA, USA). The resulting image was found as DICOM (digital imaging and communications in medicine). The first scan was made to the modified lower denture using lower radiation dose in order to digitize the denture. While the second scan was made to the patient while wearing the lower denture and closing on putty rubber base occlusal registration block over the maxillary denture in order to preserve the biting relation and force distribution

between dentures with stabilization over the mucosa in a fixed position during CBCT exposure. This bite can be repeated later on, during the surgical guide fixation and implant insertion in the pre planed position. After dual scanning the digitized lower denture can be placed over the bone of the lower jaw virtually guided by the radiopaque marks that were clear in the second scan. The resulted 3D model was complete denture over the lower jaw which allowed us to evaluate bone height, thickness, and mucosal thickness in areas of canine and first molar areas and the relation to anatomical structures like the mental foramen and inferior alveolar canal in areas where implant will be inserted.

Virtual model planning software (Blue Sky Plan®) was used to design surgical guide for the insertion of four implants, two at canine area and two at first molar area, with anchor pins for fixation. After approval of design rapid prototyping of surgical guide was done using stereolithographic rapid prototyping machine (In2Guide)

Surgical procedures

The Implant technique used in this study followed two stage implant surgery according to (Palmer et al.,1999). The sizes of these implants was standardized between patients as follow: two implants inserted in the canine area with 3.5mm diameter and 12 mm length and two at first molar area 4.5 mm diameter and 10mm length. A universal digital surgical kit was used with the Stereolithographic surgical guide.

Surgical stent was fixed in the patient's mouth by screwing the anchor pins to engage in the underlying bone after biting on the rubber base bite block used during CBCT in order to ensure seating the guide in the correct position. Tissue bunch instrument was used to remove the mucosa overlay the implant sites. In order to avoid overheating the bone during osteotomy the following precautions were considered: intermittent drilling, sharp drills,

light hand pressure, slow-speed (800-900 rpm) high torque hand piece, cold irrigation.

Implant osteotomy was done by penetration of the outer cortex with a small round bur (pilot drill) followed by drills of increasing diameter (2mm, 2.5mm, 2.8mm, 3.2mm, 3.65mm). The final drill for the anterior implants was 3.2mm and for the posterior implants was 3.65mm. The implant fixture was unmounted from its sterile container and screwed in place manually using an adaptor that attached to hand ratchet wrench until complete implant insertion in the prepared osteotomy.

Cover screw was screwed in implant fixture. After implant installation the mucosa surrounding the implant was undermined and sutured to cover the implant cover screw. the patient's existing mandibular dentures were relieved over implant sites and refitted to the mucosa using a tissue conditioner.

All patients were sedated with diazepam prior to surgery. Antibiotics (amoxicillin 625 mg + clavulanic acid 125 mg, Augmentin® 1gm) were given 1 hour prior to surgery and daily for 6 days thereafter. Cortisone medication (Dexamethazone®) was given. Anti-inflammatory medication (ibuprofen®, 600 mg) was administered for 4 days postoperatively. Analgesics (Ketolac® 10mg) were given on the day of surgery and postoperatively for the first 4 days.

Prosthetic steps

After three months of implant insertion, patients were recalled for implants exposure using lancet guided by surgical stent to determine implants locations. The cover screws were unscrewed and healing abutments were screwed in and left for 10 days to allow gingival healing. The dentures were relieved and relined with soft liner to adapt the healing abutments.

After 10 days the patients recalled for impression step. Open tray splinted impression (Implant level

or Abutment level for multiunit abutments) was made. Splinting to transfer copings was done using ligature wire connecting between the transfer coping which acted like a mesh that carry the Duralay autopolymerized resin pattern (Duralay, Reliance Dental MFG Co, Worth, IL, USA) or flowable composite that act as splinting material (fig. 1-B). After setting of splinting material passivity single screw test of Sheffield was done in order to evaluate passive splinting before impression. If passivity was lost, the splinting bar was sewed and rejoined intra orally and evaluated again till reach passive fit. A modified tray with holes corresponding to the connecting screws of the transfer coping was filled with putty form addition silicon at the same time light body addition silicon material (Ghenesyl. Lascod / Firenze / Italy) was injected below and around the splinting bar. The tray was inserted in the correct orientation guided by the holes till the heads of the connecting screws appear through the holes. After setting of the impression material the screws were untightened allowing removal of the impression. (fig. 1-C)

After making the impression analogues were connected to the transfer copings. Gingival mask (Xilgum, Lascod, Italy) was applied around the analogues after application of separating medium. The impression then was ready to be poured with extra hard stone (ZETA, Orthodontic Stone; WhipMix. Corp, Louisville, Ky). The master cast was obtained and ready to be digitized using scan bodies (fig. 2-C), for multiunit abutments or for implants according to case, scanned by 3D scanner (Ceramill Map400, Amann Girrbach AG. Koblach, Austria). An impression to the upper complete denture was done using hydrocolloid alginate impression material (Cavex Holland) in order to have opposing cast which was scanned to be digitized then mounted on semi adjustable articulator (Bio-Art-A7 Plus. Brazil) which had a virtual copy in the designing software (Exocad dental Db version 2.3 Matera). Face bow record (Elite Model

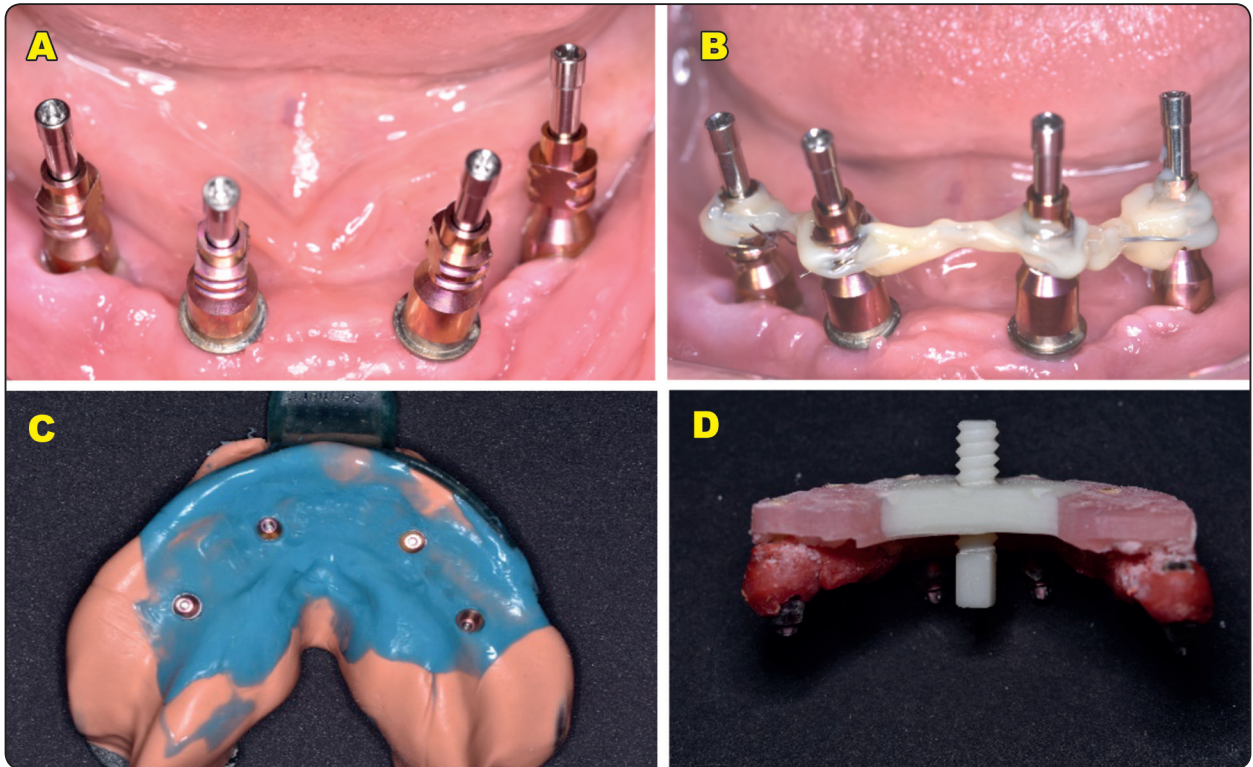


Fig. (1) A. Transfer copings. B. Splinted transfer copings. C. Final impression. D. Screw retained bite block with central bearing device

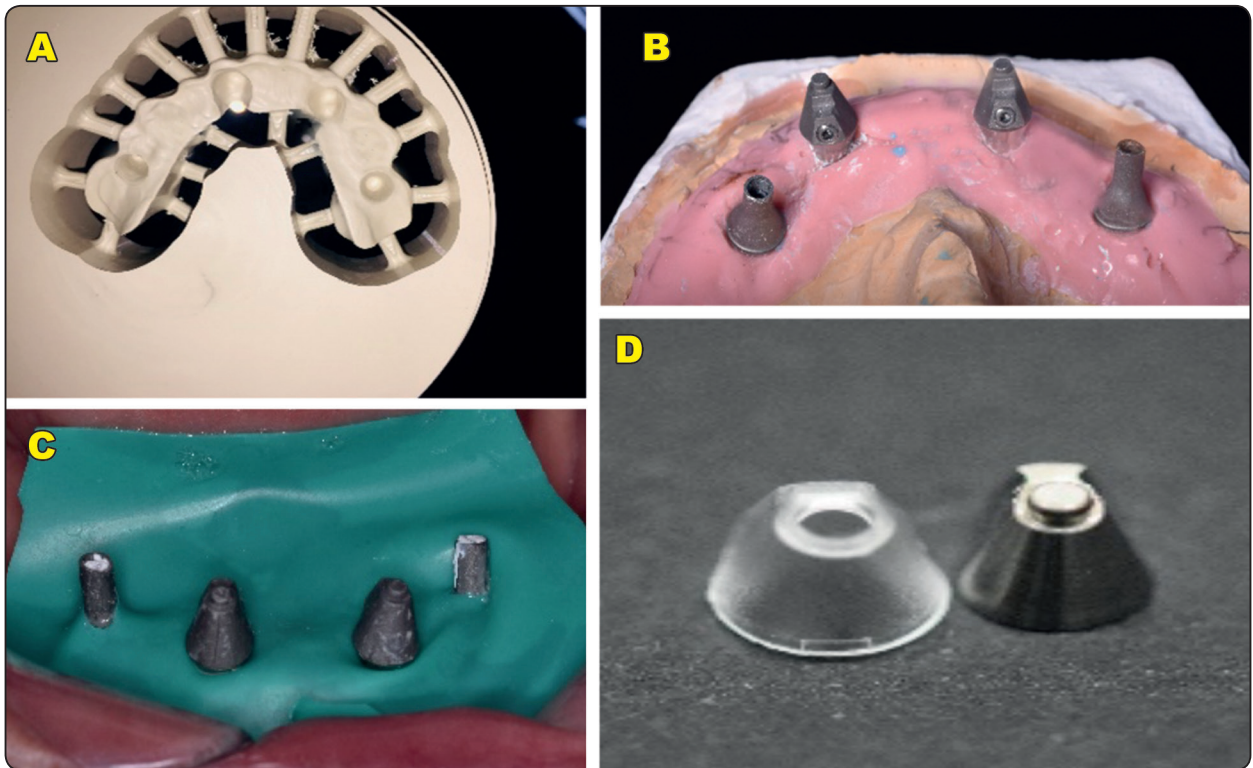


Fig. (2): A. Milled PEKK frame work. B. Multi unit abutment with transverse anchor screw. C. Sand plastered abutments. D. Intra oral prepared abutments ready for direct pickup cementation

facebow- Bio-Art. Brazil) was used to mount the upper cast, then the lower master cast was mounted opposing to the upper one using screw retained bite block with central bearing device (Fig. 1-D) in the correct vertical and horizontal relation followed by injecting bite registration material. Protrusive record was made and the sagittal condylar guidance was adjusted. The lateral condylar guidance was gained from Hanaue equation $L+H/8+12$ to be nearly 15degrees in almost all cases. The recorded degrees were fed to the digital articulator which allowed it to move like the actual one.

For group 1. Fixed hybrid prosthesis (FHP)

PEKK (Pekkton® ivory, Cendres + Métaux SA, Biel/Bienne, Switzerland) frame work was designed with recess in the fitting surface corresponding to the multiunit metal abutments, and with prepared teeth on the top to allow room for the full jacket Zircon crowns (Ceramill Zolid HT/ Austria). anterior multiunit abutments with transverse anchor screw (SKY fast & fixed. prosthetic coping transversally screwed/ Bredent / Germany) (fig. 2-B) was used in order to avoid axis screw on the incisal or labial surface of anterior teeth. The frame work was milled using wet five axis milling machine (Redon GTR / Aydınlı Tuzla, Istanbul - Turkey) (fig. 2-A). The solitary zircon crowns were constructed and fitted over the PEKK frame work (fig. 3). The gained frame work and multiunit abutments were sand blasted, steamed and cleaned with alcohol then direct pickup cementation process by methacrylate cement (Premier Implant Cement; Premier Dental Products Co) in the patient's mouth was done after profound isolation during occluding on the opposing arch. (fig. 2-D) composite primer (Visio.Link/ Bredent GmbH & Co.KG. Germany) then pink colored composite (Crea. Lign/ Bredent GmbH & Co.KG. Germany) was added to contour the gingival portion on the base to simulate gingiva. The FHP was inserted in the patient's mouth and evaluated. (fig. 3)

For group 2. Telescopic complete implant overdenture (TOD)

Primary conical telescopic zircon copings (6mm in height and 5mm in diameter and 2° taper) were designed on the CAD system to allow single path of insertion and removal. Scan bodies of the implant system were connected to the analogues and bench scanned. On the CAD software Tie base of the system was determined. The produced zircon abutments were cemented to the Tie bases using DTK (DTK-Adhesive – Bredent UK) of each analogue in the correct orientation in order to maintain the selected path of insertion then inserted in the patient's mouth (fig. 4-A) 2ry impression was made (fig. 4-B) to the delivered 1ry copings to have master cast which was digitized in order to design the secondary PEKK copings with minimal thickness of 0.5mm and 0.3 mm axial clearance. The secondary copings were designed to be connected with bar in order to keep their orientation to each other facilitating easy manipulation and at the same time reinforce the overdenture (fig. 4-C). The secondary copings were milled and tried in on the 1ry copings in the patient's mouth (fig. 4-E). A relieved lower complete denture was adapted over the copings which then picked up directly using cold cured pink resin material (Qu. Repair resin pink. Bredent GmbH & Co. Germany) while the patient closed. The denture was removed for finishing and polishing to be inserted in the patient's mouth for evaluation (fig. 4-F,G).

Evaluation of biologic and prosthetic complications

The following biological complications (on the implant level) were measured⁽²¹⁾: Implant loss, implant survival and success, Pain, swelling, abscess, fistulae formation, peri-implantitis, peri-implant mucositis., mucosal bleeding, pocket depths >5 mm, and mean vertical bone change of all surfaces if > 2 mm using CBCT (fig. 5). Prosthetic complications on implant level which includes: Cylinder fracture, Abutment fracture, Abutment screw loosening, Prosthetic screw loosening and Prosthetic screw fracture. While complications on the

prosthesis level included: Prosthesis fracture, Jacket crown fracture, Acrylic crown fracture, artificial gingiva fracture, and Opposing teeth wear (21) Both biological and prosthetic complications were measured after one year from prosthesis insertion.

CBCT Scan parameters were standardized with the following parameters: 120 kVp, 5 mA, voxel size of 0.25 mm, acquisition time of 8.9 seconds, field of view 8 cm high × 16 cm wide. The level (878) and width (4340) of the images.

Statistical analysis

Statistical analysis was done by using SPSS® version 25 (SPSS Inc., Chicago, IL, USA). The data of both biologic and prosthetic complications were collected after one-year evaluation and calculated in the form of frequency and percentages by using frequency distribution (contingency) tables. Chi-square test was used between groups for each item to test significance if ≤ 0.05 .

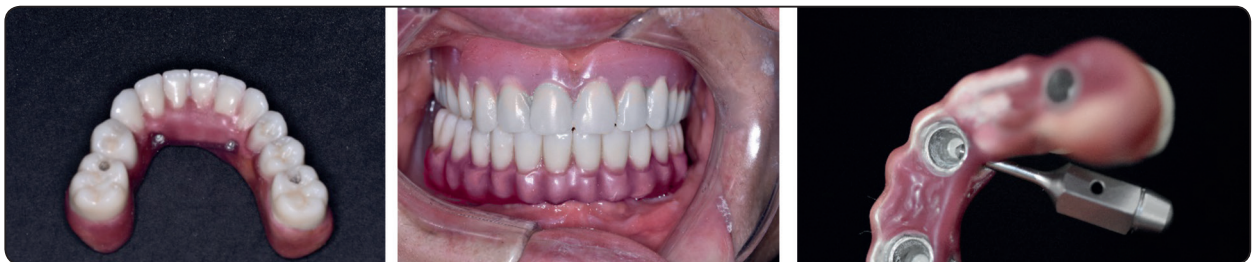

Fig. (3): Group 1 final screw retained fixed prosthesis

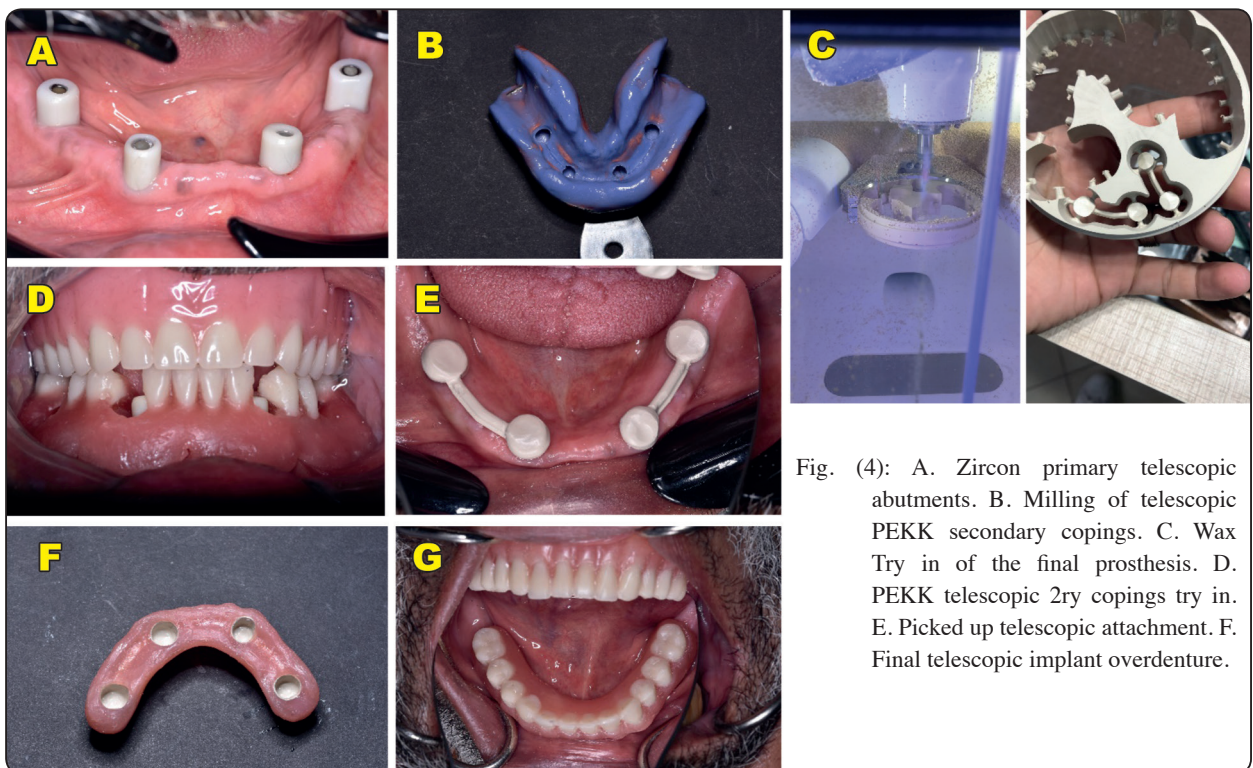


Fig. (4): A. Zircon primary telescopic abutments. B. Milling of telescopic PEKK secondary copings. C. Wax Try in of the final prosthesis. D. PEKK telescopic 2ry copings try in. E. Picked up telescopic attachment. F. Final telescopic implant overdenture.

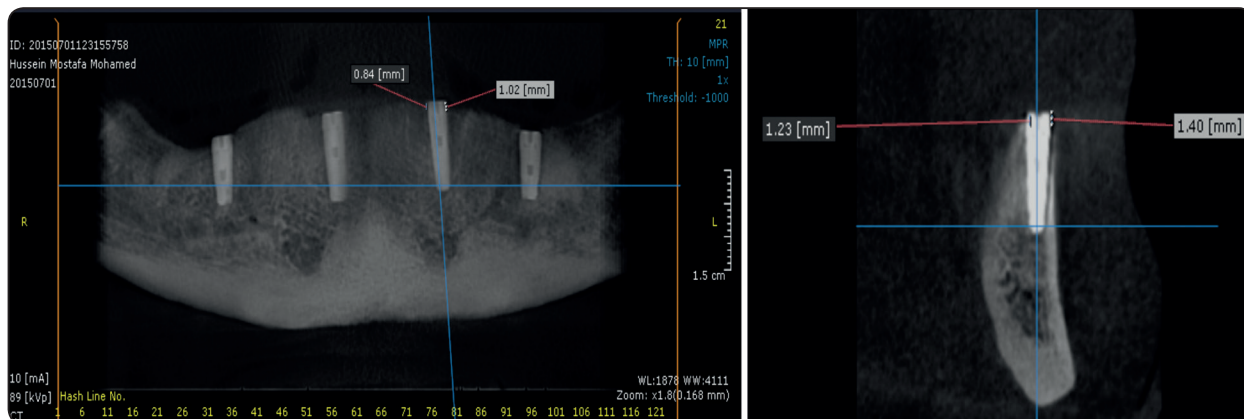


Fig. (5): CBCT peri-implant vertical bone loss measurements

RESULTS

After one year of clinical evaluations on the base of biological complications on the implants' levels of using either fixed hybrid prosthesis or telescopic complete implant overdenture we found that (table:1). In both groups implant success rate was 100% with no failure. Seven implants of 40 showed pain and swelling (5 in FHP and 2 in TOD) with no significant difference (P=0.212). No

abscess or fistula formation was noticed in both groups but peri-implant mucositis was noticed more insignificantly in the FHP group (P=0.212) which may be related to difficult hygiene measures in the first group. No significant pocket depth greater than 5mm was detected between the groups (P= 0.548). And no mean vertical bone loss greater than 2 mm was found in all implants after one year of CBCT evaluation to the mean of peri-implant bone change for each implant.

TABLE (1) Biological complications (on the implant level) of Screw retained fixed hybrid prosthesis and Telescopic complete implant overdenture

Parameter	Group I (FHP)		Group II (TOD)		P value
	Incidence	Percentage	Incidence	Percentage	
Implant failure	0	0	0	0	1.00
Implant survival	20	100%	20	100%	1.00
Pain, swelling	5	25%	2	10%	0.212
Abscess, fistulae formation	0	0	0	0	1.00
Peri-implantitis	1	5%	2	10%	0.548
Per-implant mucositis	5	25%	2	10%	0.212
Bleeding on probing	6	30%	2	10%	0.114
Peri-implant pockets >5 mm	2	10%	1	5%	0.548
Mean vertical bone change of all surfaces if > 2 mm	0	0	0	0	1.00

* P-value ≤0.05 was considered to be significant

Prosthetic complications on the implant level were evaluated for both groups and we found that (Table:2) there was no complication reported regarding cylinder fracture nor abutment fracture or prosthetic screw fracture. But we noticed screw loosening of the telescopic abutment in the TOD group and the FHP group showed prosthetic screw loosening after one year of use which needed retightening of screws.

On the prosthetic level, complications were evaluated (table: 3) and we founded no prosthetic fracture was reported. But significant ($P=0.038$) prosthetic crown fracture was reported in three cases for the TOD group which repaired by teeth replacements. Another significant ($P=0.010$) was

reported in four opposing complete dentures teeth wear was noticed in the FHP group which repaired by teeth replacements. A non-significant ($P=0.114$) increase in the artificial teeth wear of the TOD compared to the FHP. Artificial gingival replacement fracture was noticed in one case where the temporary cemented jacket crown that cover the axis screw was detached fracturing with it the gingival layer in the FHP which treated with gingival layer addition and permanent cementation to the jacket crown with access hole preparation through it. While in the TOD group three cases showed fracture in the gingival layer due to thin base thickness of denture base covering the telescopic but the difference was non-significant difference ($P=0.197$).

TABLE (2) Prosthetic complications of Screw retained fixed hybrid prosthesis and Telescopic complete implant overdenture on Implant level

Parameter	On Implant Level				
	Group I (FHP)		Group II (TOD)		P value
Cylinder fracture	0	0	0	0	1.00
Abutment fracture	0	0	0	0	1.00
Abutment screw loosening	-	-	4	20%	-
Prosthetic screw loosening	4	20%	-	-	-
Prosthetic screw fracture	0	0	-	-	-

* P -value ≤ 0.05 was considered to be significant.

TABLE (3): Prosthetic complications of Screw retained fixed hybrid prosthesis and Telescopic complete implant overdenture on patient level

Parameter	On Patient level				
	Group I (FHP)		Group II (TOD)		P value
Prosthesis fracture	0	0	0	0	1.00
Crown fracture	0	0	3	60%	*0.038
Teeth wear	0	0	2	40%	0.114
Gingiva fracture	1	20%	3	60%	0.197
Opposing teeth wear	4	80%	0	0	*0.010

* P -value ≤ 0.05 was considered to be significant.

DISCUSSION

In this study a trial to compare the biologic and prosthetic complications was done between two prosthetic options, either screw retained fixed hybrid prosthesis or telescopic implant supported overdenture restorations in cases that have four widely distributed implants in the lower jaw.

The implants were inserted in the canine and first molar areas in order to provide wide supporting frame with increased anterior posterior spread in addition to avoiding cantilevers in the prosthesis to minimize the biomechanical draw backs and to have complication free restorations as much as possible. Which it was in line with what was reported by Horita, et al. (2017).⁽²⁴⁾ About mandibular fixed full-arch prostheses without cantilevers that may result in a favorable reduction of the peri-implant bone strain compared with cantilevers.⁽²⁵⁾

There were no implant failures occurred in both groups and the survival rate was 100% in both groups due to following the delayed loading protocol which avoided implant overloading in the critical healing period which allows more bone to implant contact to be established without disturbance and increase the success rate. In addition to the reduced muscle strength and bite force of the edentulous patient in the elderly patients included in this study. Which in turn transmitted a reduced occlusal force to the prosthesis and may contribute to an increased survival rate. In addition to, using flapless surgical technique, which has several advantages including preservation of circulation, soft tissue architecture, and hard tissue volume at the surgery site, decreased surgical time and improved patient comfort^(26,27)

PEKK material played a major role in this study. As it was used in the construction of the secondary copings over zircon primary copings of telescopic attachments in the overdenture group. And it was used in the construction of the framework of the screw retained group.^(7, 11, 13, 15, 28) PEKK provided damping action to the loads transferred to the peri-

implant bone in both groups which was noticed in decreasing number of implants with mean alveolar bone loss greater than 2 mm after one year of use in our study.

The use of CAD/CAM technology in the design and construction of telescopic elements provided accurate selection of common path of insertion during designing between the primary zircon abutments and the corresponding secondary copings of PEKK. The primary zircon abutments were designed with axis hole opening to the implant abutment connection screw, which allowed us to unscrew or tighten the Zircon abutment after cementation. Computer aided milling from blocks of readymade PEKK maintain equal quality of material through the entire thickness. CAD/CAM system provide the ability to save the blueprint models in the system allowing to the construction of any component if needed in the future based on the initial design.^(29,30) In our study the primary coping of zircon implant abutment was designed following the design recommendations of study made by Brandt. S et al. (2019), they constructed custom abutments of Zirconia primary crowns for implants to support the prosthesis they were created with ≥ 0.3 mm in wall thickness, 6 mm in height, 2° taper, smooth surface.⁽¹³⁾ Another study reported that 1° taper provided the maximum retention compared to 0° and 2°⁽¹⁷⁾ but we followed 2° taper as it can allow more freedom in insertion and removal of prosthesis especially in wide distributed implant condition.

In the TOD group zirconia primary telescopic coping was used which was indicated as a successful material by many studies^(9,13,31). As it was confirmed that, the application of wear resistant and hard material like zirconia (210 GPa) as a primary coping against a less harder material like PEKK (4 GPa) for secondary coping could be beneficial as minimal alterations will happen in the primary coping and the adaptation between both copings will be accomplished by the alterations in

the secondary coping which was in line with⁽¹⁴⁾. Also^(32, 33) found primary crowns of zirconia to offer better stability and more reliable retention. Also, telescopes combining zirconia primary crowns with electro-formed secondary copings did not develop any signs of wear, which highlights the durability of the materials⁽³⁴⁾.

In this study after 12 months of biological evaluations for the two groups on the implant level we found that There was no significant difference in the incidence of prosthetic complications in the current study between both groups which make the two treatment options are close to each other.

In the present study, there were no significant difference in many prosthetic complication parameters between telescopic overdentures and the screw retained prosthesis in points of prosthetic cylinder fracture, prosthetic abutment fracture, prosthetic screw fracture, prosthesis fracture, teeth wear and gingival fracture. Which is consistent with study made by⁽²⁶⁾. Also another study (Hemmings, et al. 1994) compared overdentures retained by bar or magnetic attachment with that of screw-retained restorations which showed less complications related to the removable option compared to the fixed one after 5 years of evaluation. On the opposite side another study⁽³⁵⁾ reported more complications in the removable overdentures using other attachments compared to the fixed one due to the periodic service needed to the attachment.

In this study we noticed a significant difference ($P= *0.038$) in terms of prosthetic complications between the two groups toward the telescopic overdenture in the form of crown fracture and with a non-significant prosthetic gingival fracture ($PO=0.197$) especially over the telescopic attachment which may be related to reduced thickness of the overlaying acrylic denture base and tooth. Which it was in line with findings reported by Brandt S. et al⁽¹³⁾ Repairs were performed on 48 of the 126 dentures, most often to replace denture teeth after loss or

chipping. On another study made by Khairallah A. et al. they reported teeth wear and gingival acrylic fracture occurred which was easy repaired by addition of new teeth of the same shade using autopolymerized resin.⁽²⁸⁾

In this study, we noticed prosthetic screw loosening in FHP group and abutment screw loosening of the TOD group after 6 months of use which was in accordance to the findings reported by study made by Ibrahim W. et al. (2016) and McGlumphy et al. whom reported that, the screw fracture and loosening were the most common screw complications (McGlumphy, et al. 1998) (W, & 2016) which may be related to many factors like: insufficient preload on the screws, overtightening of the screws leading to stripping and/or screw deformation, and/or occlusal overload from parafunction, occlusal interferences, or extremely long cantilevers (McGlumphy, et al. 1998) (A, et al. 2021). In another study made by Frisch, et al. (2015)⁽³⁶⁾ they considered screw loosening as rare complication that showed incidence of 1.2% within 5 years. They related the low incidence to the Morse taper connection design between the abutment and implant which reduced the screw loosening problem.

Telescopic complete overdenture showed superior advantages over screw retained completed implant supported prosthesis in terms of easy and fast retrievability and hygiene thanks to the self-finding mechanism that help elderly people with decreased manual dexterity and systemic diseases. As dentists or dental hygienists can easily remove the prosthesis at every maintenance and easy accessibility of the hygiene measures around each implant which improved peri-implant condition and improve peri-implant alveolar bone height.⁽¹⁵⁾ opposite to the sensitive construction technique of the screw retained prosthesis which demand passive fit for complete seating of prosthesis, and the difficult accessibility below the prosthesis to perform oral hygiene and subsequent plaque accumulation and

gingivitis. Which was noticed in the present study by the non-significant increase in some biological complications toward the FHP group like in pain and swelling ($P=0.212$), peri-implant mucositis ($P=0.212$) and bleeding on probing ($P=0.114$).

In both groups, no implant showed mean alveolar bone loss after one year of loading greater than 2 mm using CBCT evaluation. Which it is coincident to the study made by Oda, et al. 2021 whome found that marginal bone loss of implants for fixed screw retained prosthesis and Telescopic full arch prosthesis showed 0.60 ± 0.51 and 0.41 ± 1.03 mm, with no significant difference after 7–13 years of follow-up.⁽¹¹⁾

In the present study, we noticed significant wear in the opposing conventional complete denture in FHP group ($P=0.010$) which may be related to the different tooth material between the opposing arches acrylic vs zircon crowns.

Within the limitation of the present study of small sample size and short evaluation period we found that, using telescopic implant overdenture in the rehabilitation of completely edentulous mandible is comparable to the screw retained fixed prosthesis after 12 months of prosthetic and biologic evaluation as we found that. **1.** Telescopic implant overdentures have superior soft tissue condition related to easy hygiene accessibility by patients. **2.** Acrylic teeth and gingival base chipping may occur which need repair which indicate more considerations during construction to have sufficient thickness of prosthesis especially over telescopic attachments. **3.** Using PEKK is a promising choice in the construction of implant supported fixed or removable prosthesis.

Recommendations

Farther investigations are needed in the future on larger sample size and longer evaluation period with addition to other parameters like retention force and wear of PEKK after use.

REFERENCES

1. Attard NJ, Zarb GA. Long-term treatment outcomes in edentulous patients with implant-fixed prostheses: the Toronto study. *Int J Prosthodont.* 2004;17(4):417-24.
2. Santagata M, Guariniello L, D'Andrea A, Tartaro G. A modified crestal ridge expansion technique for immediate placement of implants: a report of three cases. *J Oral Implantol.* 2008;34(6):319-24.
3. Heckmann SM, Schrott A, Graef F, Wichmann MG, Weber HP. Mandibular two-implant telescopic overdentures. *Clin Oral Implants Res.* 2004;15(5):560-9.
4. Awaad NM, Eladl NM, Abbass NA. Assessments of Bone Height Loss in Telescopic Mandibular Implant-Retained Overdentures Retained by Two and Four End - Osseous Implants: A Randomized Clinical Trial. *Open Access Maced J Med Sci.* 2019;7(4):623-37.
5. Cordaro L, di Torresanto VM, Petricevic N, Jornet PR, Torsello F. Single unit attachments improve peri-implant soft tissue conditions in mandibular overdentures supported by four implants. *Clin Oral Implants Res.* 2013;24(5):536-42.
6. de Jong MH, Wright PS, Meijer HJ, Tymstra N. Posterior mandibular residual ridge resorption in patients with overdentures supported by two or four endosseous implants in a 10-year prospective comparative study. *Int J Oral Maxillofac Implants.* 2010;25(6):1168-74.
7. Abdelwahab K, MA. Evaluation of Patient Satisfaction with Mandibular Screw Retained Hybrid Prosthesis Versus Mandibular Implant Over-Dentures Retained by Telescopic Attachments. *Egypt Dent J.* 2021(4): 3457-63
8. Alqurashi H, Khurshid Z, Syed AUY, Rashid Habib S, Rokaya D, Zafar MS. Polyetherketoneketone (PEKK): An emerging biomaterial for oral implants and dental prostheses. *Journal of Advanced Research.* 2021;28:87-95.
9. Kotthaus M, Hasan I, Keilig L, Gruner M, Bourauel C, Stark H. Investigation of the retention forces of secondary telescopic crowns made from Pekkton(R) ivory in combination with primary crowns made from four different dental alloys: an in vitro study. *Biomed Tech (Berl).* 2019;64(5):555-62.
10. Jain AR, Nallaswamy D, Ariga P, Philip JM. Full mouth rehabilitation of a patient with mandibular implant screw retained Fp-3 prosthesis opposing maxillary acrylic removable over-denture. *Contemp Clin Dent.* 2013;4(2):231-5.
11. Oda Y, Mori G, Honma S, Ito T, Iijima T, Yajima YJCOIR. Marginal bone loss and the risk indicators of fixed screw-retained implant-supported prostheses and fixed telescopic-retained implant-supported prostheses in full arch: A retrospective case-control study. 2021.

12. Heckmann SM, Winter W, Meyer M, Weber HP, Wichmann MG. Overdenture attachment selection and the loading of implant and denture-bearing area. Part 2: A methodical study using five types of attachment. *Clin Oral Implants Res.* 2001;12(6):640-7.
13. Brandt S, Winter A, Weigl P, Brandt J, Romanos G, Lauer HC. Conical zirconia telescoping into electroformed gold: A retrospective study of prostheses supported by teeth and/or implants. *Clin Implant Dent Relat Res.* 2019;21(2):317-23.
14. Emera R, Askar O, Ahmed WS, Eskander S. Two Implants Retained Complete Mandibular Overdenture with Zirconia-PEEK Telescopic Attachment: Radiographic Evaluation of Peri-implant Bone Level Changes. *Oral Health Dental Sci.* 2020;4(1):1-7.
15. A.S KA, SAF. Milled Bar Versus Rigid Telescopic Attachment For Mandibular Implant Supported Overdentures. A Study Of Patients; Satisfaction And Oral Health Quality Of Life. *Egypt Dent J.* 2020;66:1183:93.
16. Hoffmann O, Beaumont C, Tatakis DN, Zafirooulos GG. Telescopic crowns as attachments for implant supported restorations: a case series. *J Oral Implantol.* 2006;32(6):291-9.
17. Elkabbany A, Kern M, Elkhadem A, Wille S, Amer A, Chaar S. Retention of metallic and non-metallic double-crown-retained mandibular overdentures on implants: An in-vitro study. *Journal of Prosthodontic Research.* 2019.
18. Hakkoum MA, Wazir G. Telescopic Denture. *Open Dent J.* 2018;12:246-54.
19. Beuer F, Edelhoff D, Gernet W, Naumann M. Parameters affecting retentive force of electroformed double-crown systems. *Clin Oral Investig.* 2010;14(2):129-35.
20. M ER. All-Zirconia double crowns for retaining complete mandibular overdenture. Clinical and microbiological evaluation of natural abutments. *EDJ.* 2016(62):1959-72.
21. Maló P, de Araújo Nobre M, Lopes A, Ferro A, Botto J. The All-on-4 treatment concept for the rehabilitation of the completely edentulous mandible: A longitudinal study with 10 to 18 years of follow-up. *Clin Implant Dent Relat Res.* 2019;21(4):565-77.
22. Paspaspyridakos P, Chen CJ, Chuang SK, Weber HP, Gallucci GO. A systematic review of biologic and technical complications with fixed implant rehabilitations for edentulous patients. *Int J Oral Maxillofac Implants.* 2012;27(1):102-10.
23. Carpentieri J, Greenstein G, Cavallaro J. Hierarchy of restorative space required for different types of dental implant prostheses. *J Am Dent Assoc.* 2019;150(8):695-706.
24. Horita S, Sugiura T, Yamamoto K, Murakami K, Imai Y, Kirita TJJopr. Biomechanical analysis of immediately loaded implants according to the “All-on-Four” concept. 2017;61(2):123-32.
25. Drago C. Ratios of Cantilever Lengths and Anterior-Posterior Spreads of Definitive Hybrid Full-Arch, Screw-Retained Prostheses: Results of a Clinical Study. *J Prosthodont.* 2018;27(5):402-8.
26. W I, KA, EA. Maintenance Requirements of Screw-Retained Implant Prosthesis versus Telescopic Overdenture: A Randomized Controlled Trial. *International Journal of Science and Research (IJSR).* 2016:78.96.
27. Sclar AGJJoo, surgery m. Guidelines for flapless surgery. 2007;65(7):20-32.
28. Khairallah A. S, O. HM. Biological and Prosthetic Complications of Cantilevered and Non-Cantilevered Fixed Hybrid Metal Acrylic Prostheses Used For Vertical and Inclined Implants in Atrophied Mandible. A Randomized Clinical Trial. *Egypt Dent J.* 2021; 67 717:28
29. Emera R. All-Zirconia Double Crowns For Retaining Complete Mandibular Overdenture. *Clinical and Microbiological Evaluation of Natural Abutments. Egypt Dent J.* 2016;62(2):1959:72.
30. Groesser J, Sachs C, Heiß P, Stadelmann M, Erdelt K, Beuer FJCoI. Retention forces of 14-unit zirconia telescopic prostheses with six double crowns made from zirconia—an in vitro study. 2014;18(4):1173-9.
31. Mohamed AMA, Nawar NH. Strain Gauge Analysis of the Stresses Induced by Different Secondary Coping Materials in Tooth Supported Telescopic Overdentures. *Eur J Prosthodont Restor Dent.* 2022.
32. Bayer S, Zuziak W, Kraus D, Keilig L, Stark H, Enkling N. Conical crowns with electroplated gold copings: retention force changes caused by wear and combined off-axial load. *Clin Oral Implants Res.* 2011;22(3):323-9.
33. Bayer S, Kraus D, Keilig L, Gözl L, Stark H, Enkling N. Changes in retention force with electroplated copings on conical crowns: a comparison of gold and zirconia primary crowns. *Int J Oral Maxillofac Implants.* 2012;27(3):577-85.
34. Weigl P, Hahn L, Lauer HC. Advanced biomaterials used for a new telescopic retainer for removable dentures. *J Biomed Mater Res.* 2000;53(4):320-36.
35. Brennan M, Houston F, O’Sullivan M, O’Connell B. Demographics of implant placement and complications of a patient subgroup in a dental hospital population. 2010.
36. Frisch E, Ziebolz D, Ratka-Krüger P, Rinke SJCid, research r. Double crown-retained maxillary overdentures: 5-year follow-up. 2015;17(1):22-31.