

Protective Effect of Vitamin E & C and Silymarin Against Paracetamol Toxicity on the Liver of Adult Male Albino Rat

Aladdin S. El Sagheer,¹ MD, Mahmoud I. El Najjar,¹ MD, Kamal R. El Baz,¹ MD.

* Corresponding Author:

Aladdin S. El Sagheer

alaasemary2013@yahoo.com

Received for publication February 3, 2022; **Accepted** April 13, 2022; **Published online** April 13, 2022.

Copyright The Authors published by Al-Azhar University, Faculty of Medicine, Cairo, Egypt. Users have the right to read, download, copy, distribute, print, search, or link to the full texts of articles under the following conditions: Creative Commons Attribution-Share Alike 4.0 International Public License (CC BY-SA 4.0).

doi: 10.21608/aimj.2022.117054.1805

¹Anatomy and Embryology Department, Faculty of Medicine, Al-Azhar University, Cairo, Egypt.

ABSTRACT

Background: Paracetamol, an analgesic, is safe at therapeutic dose. Its overdose causes hepatotoxicity. Silymarin is hepatoprotective, capable of stabilizing cell membranes. Vitamins E and C (VEC) have hepatoprotective effects due to their antioxidant role.

Aim of the study: to investigate protective effects of silymarin, vitamins E and C on the paracetamol hepatotoxicity.

Patients and Methods: Forty adult male albino rats were used in this experiment, divided into 4 groups, 10 rats each, Group I (Control) given normal saline orally, Group II: given paracetamol (PC), once daily orally, Group III: given Silymarin, once daily orally with PC once daily orally, Group IV: given (vitamin E, vitamin C, once daily intraperitoneally, with PC once daily orally. Livers of rats were examined by light and electron microscopy. The experiment extended for two weeks and was done in faculty of medicine, Al-Azhar university.

Results: Light microscopy: Group II showed diffuse cytoplasmic vacuolations. The nuclei appeared eccentric and pyknotic. Focal necrosis was observed. Marked cellular infiltration was noted around congested central veins. Group III marked improvement was noticed. Group IV, some hepatocytes showed vacuolations, while the remaining restored their normal structure. Electron microscopy: Group II showed some nuclei without nucleolus, intracytoplasmic vacuolations and decrease in the number of organelles, mitochondria, and endoplasmic reticulum. In Group III and Group IV, the ultra-structural changes in the liver sections disappeared in spite of persistence of some lipid droplets and cytoplasmic vacuoles.

Conclusion: This study proved the hepatoprotective effects of silymarin and vitamins E and C, against paracetamol hepatotoxicity.

Keywords: Paracetamol hepatotoxicity; Silymarin; Vitamin E; Vitamin C.

Disclosure: The authors have no financial interest to declare in relation to the content of this article. The Article Processing Charge was paid for by the authors.

Authorship: All authors have a substantial contribution to the article.

INTRODUCTION

Liver diseases are serious health problems and is still considered as a great challenge to deal with in the practice of modern medicine.¹ paracetamol or N-acetyl-p-aminophenol (APAP) is a derivative of para-aminophenol. It is widely used as a safe analgesic and antipyretic drug. It is metabolized in the liver to excretable glucuronide and sulphate conjugates. High doses of paracetamol can cause nephrotoxicity² and hepatotoxicity mainly due to the formation of a highly reactive metabolite, namely N-acetyl-p-benzoquinone imine (NAPQI).³ Paracetamol-related hepatotoxicity is one of the commonest causes of liver failure. Most of such cases are the result of ingestion of large paracetamol doses.⁴

Vitamin E is a naturally occurring lipid soluble antioxidant scavenging free radicals.⁵ Free radical damage was implicated in a number of degenerative states including carcinogenesis, arthritis, platelet hyperaggregability, ischemia and reperfusion of injury, cataract and lung injury caused by pollutants.⁶

Vitamin C is a widely known vitamin abundant in different kinds of fruits and vegetables and is available as an OTC (over the counter) supplement.⁷ It plays an important physiological role in cells as a reducing agent, antioxidant and free radical scavenger. It protects the cells from reactive oxygen species and hence prevents oxidative damage to the different biological macromolecules, such as proteins, DNA, and lipids.⁸

Silymarin is a flavonoid extracted from the seed of *Silybum marianum Gaetm* (milk thistle plant)

which is a member of the aster family (*Asteraceae*). Owing to the plant's antioxidant role, its seeds have been used to treat a range of liver and gallbladder disorders. Silymarin was proved to inhibit fibrogenesis and stabilize the lipid structures in the hepatocellular membrane.⁹

The aim of this work is to study the possible protective effects of vitamins E, C and silymarin, on the hepatotoxicity induced by paracetamol.

PATIENTS AND METHODS

Experimental animals:

Forty adult male albino rats were used in this experiment. Their weight ranged from 200-250gm. They were housed in a plastic cage in an environmentally controlled animal facility (room temperature, 12 h light: 12 h dark cycle). The rats were kept under the same circumstances and fed on normal diet and water throughout the experiment. The experiment was conducted for

a period of 14 days. The experiment was done in Faculty of Medicine, Al-Azhar University.

Chemical materials:

Paracetamol was obtained from Pharco Company, in the form of tablets (500mg/ tab). Silymarin was obtained from Sedico Company, in the form of packs. (140mg/pack). Vitamin E was Obtained from Pharco Company, in the form of gelatinous capsules. (400mg/cap). Vitamin C: Obtained from Memphis company, in the form of ampule. (1000mg/amp).

The rats were divided in a random manner into four groups, (each group consisted of ten rats); Group I (Control group): The rats were given 10 ml 0.9% NaCl orally daily for 14 days; Group II: The rats were given paracetamol (PC) from the 8th to the 14th day of the experiment, in a dose of 1g/kg orally by gastric tube once daily.¹⁰ Group III: The rats were given silymarin + paracetamol as follows: Silymarin, in a dose of 25mg/kg orally by gastric tube, once daily for 14 days.¹¹ and paracetamol (1g/kg orally by gastric tube once daily from the 8th to the 14th day of the experiment. Group IV: The rats were given vitamins E and C together with paracetamol as follows:

Vitamins E and C (VEC) for two weeks and paracetamol was given orally (1g/kg) by gastric tube once daily from the 8th to the 14th day of the experiment. The dose of vitamin E was 50 mg/kg.¹² The dose of vitamin C was 100mg/kg, by intraperitoneal injection once daily.¹³

After 48 hours from the last day of the experiment, the animals were sacrificed under ether anesthesia. Then the livers were carefully extracted and processed for light microscopy (LM) (hematoxylin and eosin stain) and transmission electron microscopy (EM).

RESULTS

Light Microscopic Examination

Group I (Control group):

The hepatocytes of different sections appeared normal in their structure. They were arranged in cords and radiating from the central vein towards the periphery. The blood sinusoids appeared separating the hepatic cords. They were lined with endothelial cells that appeared flat with appearance of few Kupffer cells. The cytoplasm of the hepatocytes appeared acidophilic with rounded and vesicular nuclei (Fig.1).

Group II:

There was loss of the normal architecture of the hepatic cords. The hepatocytes appeared with vacuolations in the cytoplasm of most of them. Some nuclei of the hepatocytes appeared became eccentric and other nuclei appeared small and pyknotic. Some hepatocytes showed areas of focal necrosis. There were marked cellular infiltration. The central vein appeared dilated and congested. (Fig. 2 and 3)

Group III:

Restoration of the normal hepatic architecture was obvious. The arrangement of the hepatic cords all around the central vein was normal. The hepatic cords appeared radiating from the central vein towards the periphery. Most of the hepatocytes appeared normal with acidophilic cytoplasm. The nuclei appeared rounded and vesicular with intact nuclear membrane. In some sections the central vein appeared congested and dilated (Fig. 4).

Group IV:

Normal structure of the hepatocytes was preserved. The arrangement of the hepatic cords appeared normal. The central vein and its associated sinusoids appeared intact in all sections. Most of the hepatocytes appeared with acidophilic cytoplasm. The nuclei appeared intact, with intact nuclear membrane. Some hepatocytes contain vacuolated cytoplasm (Fig 5).

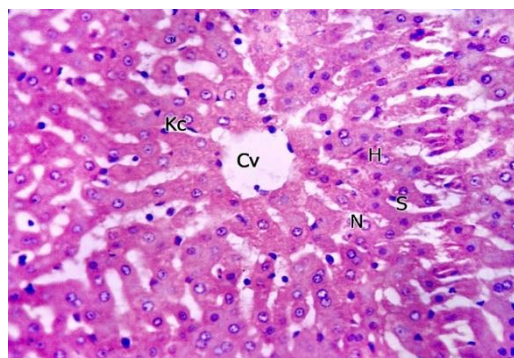


Fig 1: Photomicrograph of liver of a control rat shows: The central vein (Cv), hepatocytes (H) with the nuclei appear rounded and intact (N) the hepatocytes appeared radiating from the central vein towards the periphery. The hepatic cords appear separated from each other by blood sinusoids (S), lined by kupffer cells (Kc) (Hx & E×400).

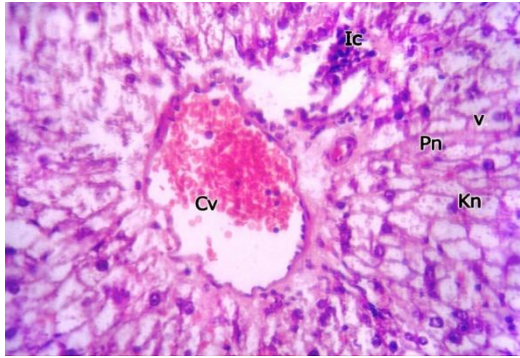


Fig 2: Photomicrograph of liver of rat treated with paracetamol shows, dilated and congested central vein (Cv) with signs of degeneration in the form of vacuolated liver cells (V), inflammatory cellular infiltration (IC), pyknotic nuclei (Pn), karyolitic nuclei (Kn) (Hx & E×400).

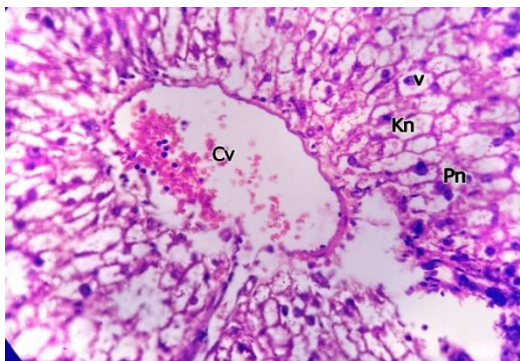


Fig 3: Photomicrograph of liver of rat treated with paracetamol shows, marked hepatic vacuolations (V), dilated congested central vein (CV) and small dark pyknotic nuclei (Pn) and karyolitic nuclei (Kn) of hepatocytes (Hx & E×400).

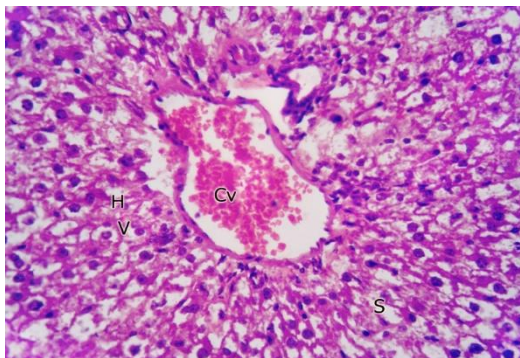


Fig 4: Photomicrograph of liver of rat treated with paracetamol and silymarin shows congested central vein (Cv), some hepatocytes (H) appear intact, others are vacuolated (v). Cords of hepatocytes appeared separated by sinusoids(S) (Hx & E×400).

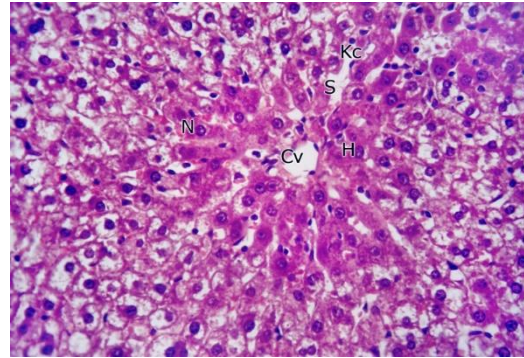


Fig 5: Photomicrograph of liver of rat treated with paracetamol and vit. E and C showing preserved hepatic architecture, central vein (CV) appears of normal diameter, not dilated, not congested with its associated sinusoids (S) appearing intact. Most of hepatocytes (H) have acidophilic cytoplasm and intact nuclei (N) and lined by Kuffer cells (kc) (Hx & E×400).

Electron microscopic examination

Group I (Control group):

Normal ultrastructural features of the hepatocytes were observed. The nuclei appeared rounded with condensed chromatin. The cytoplasm and the cell organelles appeared intact. The mitochondria were intact and numerous. (Fig. 6 and Fig. 7).

Group II:

Many abnormal findings were observed. The hepatocytes appeared vacuolated. Some nuclei were without nucleolus with intranuclear and intracytoplasmic vacuolations (cloudy swelling). The cytoplasm of most of the hepatocytes showed few numbers of mitochondria and endoplasmic reticulum. (Fig. 8 and Fig. 9).

Group III:

The hepatocytes appeared normal in their structure. The nucleus appeared rounded with intact membrane. The cytoplasm contains numerous organelles. The mitochondria appeared numerous and intact. The endoplasmic reticulum appeared preserved. (Fig.10 and Fig.11).

Group IV:

The hepatocytes appeared intact. The nuclei appeared normal rounded and contains normal nucleoli and the nuclear membranes appeared intact. The cytoplasm contained numerous and intact mitochondria and endoplasmic reticulum (Fig. 12 and Fig. 13).

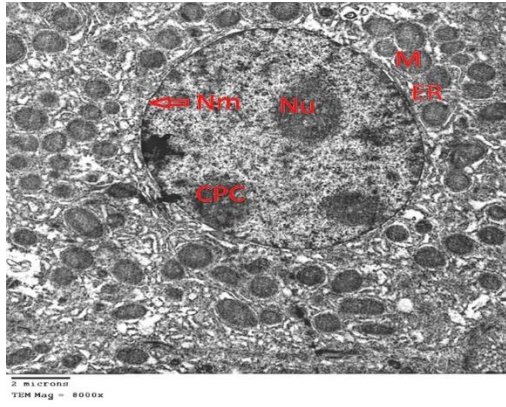


Fig 6: Electron photomicrograph of the liver of control rat: The nucleus of the hepatocyte appeared rounded with intact nuclear membrane (Nm) and condensed peripheral chromatin (CPC) and normal nucleolus (Nu). The cytoplasm contains many mitochondria (M) and endoplasmic reticulum (ER), (EM × 8000).

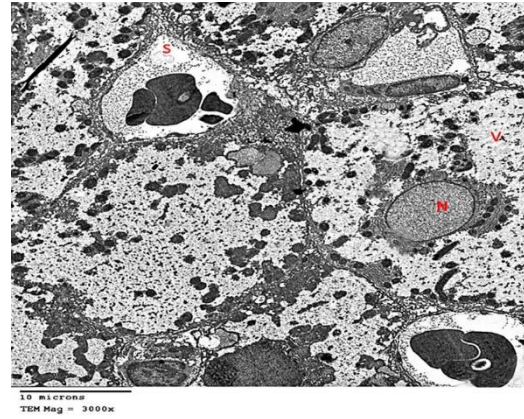

Fig 9: Electron photomicrograph of the liver of rat treated with paracetamol shows: Nucleus(N) without nucleolus, congested blood sinusoid (S), Vacuolated hepatocytes (V) (EM × 3000).

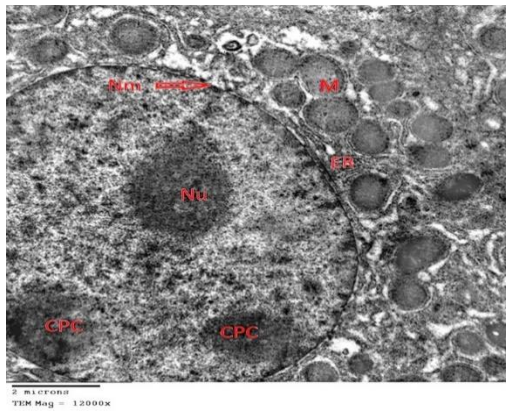


Fig 7: Electron photomicrograph of the liver of control rat: A higher magnification of the previous section showing: The hepatocyte with rounded nucleus (N) with nuclear membrane (Nm), mitochondria (M), and endoplasmic reticulum (ER), condensed peripheral chromatin (CPC). (EM × 12000).

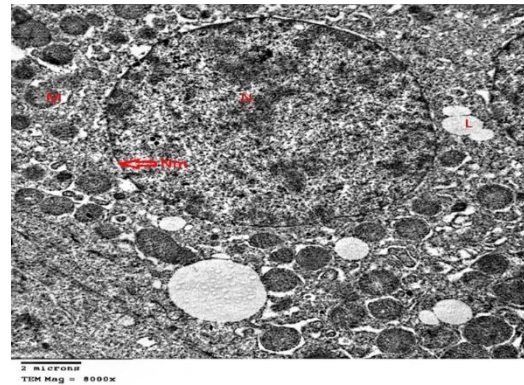


Fig 10: Electron photomicrograph of the liver of rat treated with paracetamol and silymarin shows: The hepatocyte with rounded nucleus (N) and nuclear membrane (Nm). The cytoplasm contains intact mitochondria (M) preserved endoplasmic reticulum (ER), lipid droplets (L). (EM × 8000).

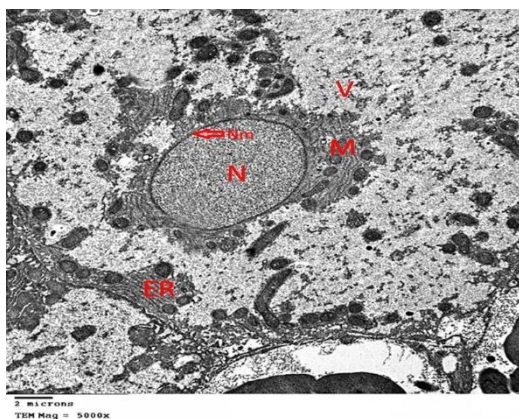


Fig 8: Electron photomicrograph of the liver of rat treated with paracetamol shows: signs of degeneration: Nucleus (N) with no nucleolus, nuclear membrane (Nm) appeared intact. Few mitochondria. (M), vacuolated hepatocyte, (V) (cloudy swelling) (EM × 5000).

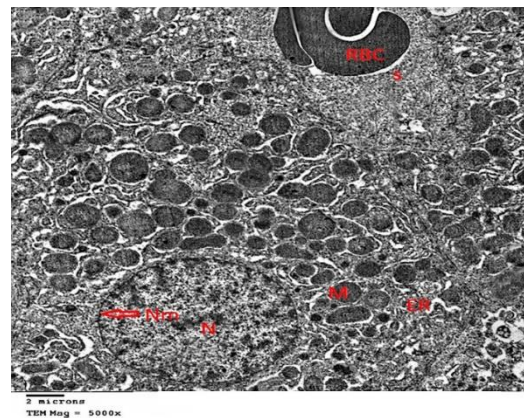


Fig 11: Electron photomicrograph of the liver of rat treated with paracetamol and silymarin shows: The hepatocytes with rounded nucleus (N) and nuclear membrane (Nm) with intact endoplasmic reticulum (ER), intact mitochondria (M) and congested sinusoids (S) with red blood cells (RBC) (EM × 5000).

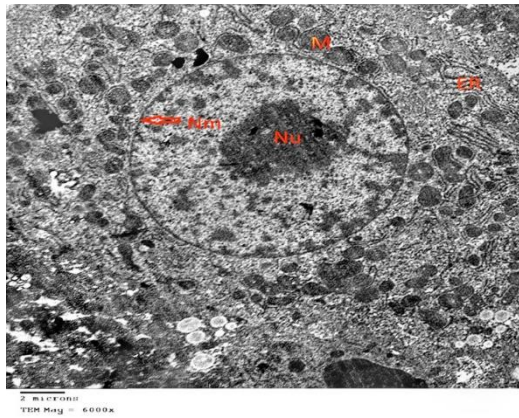


Fig 12: Electron photomicrograph of the liver of rat treated with paracetamol and vit. E and C shows: Normal rounded nucleus with prominent nucleolus (Nu). the nuclear membrane is preserved (Nm). The cytoplasm contains numerous and intact mitochondria (M) and endoplasmic reticulum (ER). (EM × 6000).

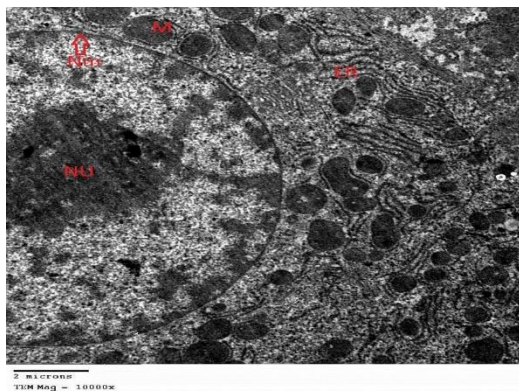


Fig 13: Electron photomicrograph of the liver of rat treated with paracetamol and vit. E and C: higher magnification of previous section Showing: Normal rounded nucleus with prominent nucleolus (Nu) and nuclear membrane (Nm). The cytoplasm contains numerous mitochondria (M) and endoplasmic reticulum (ER). (EM × 10000).

DISCUSSION

The liver performs a fundamental role in the regulation of many physiological processes, and its activity is related to different vital functions, such as metabolism, secretion, and storage. It detoxifies endogenous (waste metabolites) and/or exogenous (toxic compounds) substances or organisms and synthesizes many useful substances.¹⁴

The hepatic diseases are of the most common threats to the public health, and they are distributed all over the world.¹⁵

Paracetamol is considered safe at therapeutic doses. Overdoses of paracetamol cause severe nephrotoxicity³ and hepatotoxicity.¹⁶

In this study, it was found that, vitamins E and C performed a hepatoprotective effect against the

harmful effects induced by paracetamol. Many researches were in agreement with that they reported that Vitamin C decreased and treated hepatic damage that was produced by many chemical agents. This is greatly in agreement with the work of Bashandy and Alwasel.¹⁷

Vitamin C is well known to make synergy with many other anti-oxidants. One of the common and proved synergies is between vitamin C and vitamin E.¹⁸

The results proved by the present study showed that livers of rats received paracetamol suffered from loss of normal appearance of hepatocytes with appearance of focal necrosis of hepatocytes. Some hepatic nuclei became eccentric and other nuclei appeared pyknotic and others were karyolytic. There was mitochondrial dysfunction in paracetamol hepatotoxicity.¹⁹

These results are in agreement with results by Reham and Mohammad²² who found that the livers of the rats were greatly affected with loss of their normal appearance.

Also, in the present study there was marked cellular infiltration and diffuse cytoplasmic vacuolations. It correlates with results found by Manov et al²⁰ who found necrosis of some hepatocytes, focal chronic inflammatory cellular infiltration, and evidence of vacuolation.

The results of the present study correlate with the results found by Saheed et al²¹ that noticed vacuolated cytoplasm, area of necrosis and infiltration by inflammatory cells.

Electron microscopic examination of hepatocytes of rat received paracetamol only showed many abnormalities. There was many cytoplasmic vacuolations. Mitochondria and endoplasmic reticula markedly decreased.

These results go in agreement with Reham and Mohammad²² who found disintegration and loss of the normal structure of most of cellular contents.

In our study, administration of silymarin showed marked improvement, where the hepatocytes appeared normal with their nuclei appeared intact and rounded. The cytoplasm contains many intact organelles. Mitochondria were numerous and intact with preserved endoplasmic reticula.

Reham and Mohammad²² found that, liver tissues of mice treated with silymarin and paracetamol appeared intact with intact nuclei and numerous mitochondria.

Padmanabhan and Jangle²³ said that silymarin reduced hepatic sinusoidal congestion, cloudy swelling and fatty changes in rats treated with alcohol.

Similar results were reported by Wu et al.²⁴ who showed that silymarin restored normal appearance of

the liver tissue specially in the early stages of liver damage.

In the present study light microscopic examination of rat's liver treated by paracetamol and vitamin-E and vitamin-C showed improvement. The hepatic architecture appeared intact with normal arrangement of the hepatic cords and the central vein.

These results were in full agreement with the results found by Ganesh et al ²⁵ who noticed absence of any signs of necrosis. The structure of the hepatic lobules appeared normal after hepatotoxicity introduced by paracetamol when rats were treated with vitamin-E.

These results came in agreement with Fatma et al ²⁶ when rats given a combination of both vitamins, C and E, 15 minutes prior to daily paracetamol administration. They found marked decrease of vacuolar degeneration and fatty changes.

CONCLUSION

Paracetamol has harmful effects on the hepatic tissues in the form of focal necrosis and loss of normal structure of hepatocytes. Silymarin, vitamins E and vitamin C markedly decreased these effects and restored the normal appearance of the hepatic tissues.

REFERENCES

- Pal Rk and Manoj k. Hepatoprotective activity of alcoholic and aqueous extracts of fruits of *Luffa cylindrical* Linn in rats. *Ann Biol Res.* 2011; 2(1): 132-41.
- Hegazy AA, Abd Al Hameed EA, El-Wafaey DI, et al. Potential role of *Moringa Oleifera* in alleviating paracetamol-induced nephrotoxicity in rat. *Eur. J. Anat.* 2020;24(3):179-91.
- Hegazy A, Abd Al Hameed EA, El-Wafaey D, Khorshed O. et al, Effect of Paracetamol administration on the Rat kidney structure: A Morphological Study. *Zagazig University Medical Journal.* 2021; 27(4):567-76.
- Makin AJ and Williams R. Paracetamol hepatotoxicity and alcohol consumption in deliberate and accidental overdose. *Q. J. Med.* 2000; 93: 341-9.
- Biri H, Ozturk HS, Buyukkocak C, et al. Antioxidant defense potential of rabbit tissues after Eswi: Protective effects of antioxidants vitamins. *Nephron.* 1998; 79 (2): 181-5.
- Gohil K, Vasu V.T. Cross, C, et al. Dietary alpha tocopherol and neuromuscular health: search for optimal dose and molecular mechanisms. *mol nutr food res.* 2010; 54 (5): 693-709.
- Anmar M, Mujtaba B, Omar G, et al. Hepatoprotective Actions of Ascorbic Acid, Alpha Lipoic Acid and Silymarin or Their Combination Against Acetaminophen-Induced. *Hepatotoxicity in Rats.* 2019; 55(5): 181.
- Konopacka M. Role of vitamin C in oxidative DNA damage. *Postepy Hig. Med. Dosw.* 2004; 58:343-8.
- Jeong DH, Lee GP, Jeong WI, et al. Alterations of mast cells and TGF-beta1 on the silymarin treatment for CCI (4) – induced hepatic fibrosis. *World J Gastroenterol.* 2005; 11: 1141 – 8.
- Vogel HG and Vogel WH. Drug Discovery and Evaluation. *New York, Springer.* 1997; 531– 2.
- Patel RK, Patel MM, Patel MP, et al. Hepatoprotective activity of *Moringa oleifera* Lam. fruit on isolated rat hepatocytes. *Pharmacogn Mag;* 2008; 4: 118-23
- Ajith T, Usha S, Nivitha V, et al. Ascorbic acid and alpha tocopherol protect anticancer drug cisplatin-induced nephrotoxicity in mice: a comparative study. *Clin Chim Acta.* 2008; 13: 82-6.
- Nurten A, Huseyin V, Tevfik S, et al. Beneficial effects of vitamins C and E against oxidative stress in diabetic rats. *Nutrition Research.* 2005; 25: 625–30.
- Adewusi EA and Afolayan AJ. A review of natural products with hepatoprotective activity. *J Med Plants Res.* 2010; 4: 1318-34.
- Asha VV and Pushpangadan P. Preliminary evaluation of the anti-hepatotoxic activity of *Phyllanthus kozhikodanus*, *Phyllanthus maderaspatensis* and *Solanum indicum*. *Fitoterapia;* 1998; 59: 255-9.
- Jaeschke H, Williams CD, McGill MR, et al. Herbal extracts as hepatoprotectants against acetaminophen hepatotoxicity. *World J Gastroenterol.* 2010;16: 2448 – 50.
- Bashandy S and Alwasel S. Carbon Tetrachloride-Induced Hepatotoxicity and Nephrotoxicity in Rats: Protective Role of Vitamin C. *Journal of Pharmacology and Toxicology.* 2011; 6: 283-92.
- Oyinbo CA, Dare WN, Okogun G, et al. The Hepatoprotective Effect of Vitamin C and E on Hepatotoxicity Induced by Ethanol in Sprague Dawley Rats. *Pakistan Journal of Nutrition;* 2006; 5: 507-11.
- Laura R and Nikolaos P. Liver injury induced by paracetamol and challenges associated with intentional and unintentional use. *World J Hepatol.* 2020;12(4): 125–36.
- Manov I, Motanis H, Frumin I, et al. Hepatotoxicity of anti-inflammatory and analgesic drugs: ultrastructural aspects. *Acta Pharmacol Sin.* 2008; 27(3):259-72.
- Saheed S, Taofik O S, Emmanuel O A, et al. Combined administration of silymarin and vitamin C stalls acetaminophen-mediated hepatic oxidative insults in Wistar rats a Phytomedicine, Food Factors and Toxicology Research Laboratory, Biochemistry Unit, Department of Biosciences and Biotechnology, Kwara State University, Malete, Ilorin, Nigeria. *Revista Brasileira de Farmacognosia.* 2015; 25:29–34.

22. Reham ZH and Mohammad SA. Amelioration of paracetamol hepatotoxicity and oxidative stress on mice liver with silymarin and *Nigella sativa* extract supplements, *Asian Pac J Trop Biomed.* 2015; 5(7): 515-24.
23. Padmanabhan P and Jangle SN. Alcohol induced hepatotoxicity in mice. Department of Biochemistry, Rural Medical College, Pravara Institute of Medical Sciences (DU), Loni 413736, Ahmednagar, Maharashtra. *Int J Appl Sci Biotechnol.* 2014; 2(1): 50-8.
24. Wu YF, Fu SL, Kao CH, et al, Chemopreventive effect of silymarin on liver pathology in HBV x protein transgenic mice. *Cancer Res.* 2008; 68: 2033-42.
25. Ganesh E, Chowdhury A, Malarvani T, et al, Hepatoprotective effect of Vitamin – E & C in Albino rats. *IJALS.* 2012; 3:21-6
26. Fatma AM, Amina Gamal el Din, Nermeen MSh, et al, Histopathologic study of the Antiestrogenic Nolvadex Induced Liver Damage in Rats and Vitamins Ameliorative Effect. *Nature and Science* 2010; 8:5-7.