

Management of Acute Appendicitis during Pregnancy

Mohamed Sobhy Teamma, Hamada Rashad Abdel-Kader, Wael Soliman Taha and Mohamed Atef Radi Ahmed

Department of General Surgery, Faculty of Medicine, Al-Azhar University, Cairo, Egypt

Corresponding author: Mohamed Atef Radi Ahmed, **Mobile:** 00201118443529, **E-Mail:** mohammedatefradijahmed@yahoo.com

Abstract

Background: Appendicitis is inflammation of the appendix. Symptoms commonly include right lower abdominal pain, nausea, vomiting, and decreased appetite. However, approximately 40% of people do not have these typical symptoms. Severe complications of a ruptured appendix include widespread, painful inflammation of the inner lining of the abdominal wall and sepsis. Appendectomy is the most common abdominal operation performed as an emergency basis.

Objective: The aim of the study was to evaluate the management of acute appendicitis during different stages of pregnancy as regard the diagnosis, operation time, operative and post-operative complications and pregnancy outcome.

Subjects and Methods: This prospective study included a total of 20 pregnant women who had signs and symptoms of acute appendicitis which admitted at Al-Azhar University Hospitals and Elmenia General Hospital from March 2018 till November 2018. All patients were subjected to open appendectomy under spinal anesthesia.

Results: Abdominal pain, nausea, vomiting, leucocyte count, CRP and body temperature were not helpful in establishing the correct diagnosis. There was no maternal morbidity related to the appendectomy. We found no increase in pregnancy complications in cases with appendicitis.

Conclusion: Accurate and prompt diagnosis of acute appendicitis should be done to avoid un-necessary exploration and to aim for timely surgical intervention in pregnant women suspected of having appendicitis.

Keywords: Appendicitis, Pregnancy

Introduction

Acute abdomen is generally described as a sudden onset of severe abdominal pain with associated findings of tenderness, guarding, and abdominal muscle rigidity on physical examination. The pathology of the acute abdomen encompasses inflammatory, infectious, vascular, mechanical, traumatic, and neoplastic etiologies. The reason we, as medical providers are so concerned with the acute abdomen is that there is classically several etiologies that require emergent surgical intervention⁽¹⁾.

The vermiform appendix is considered by most to be a vestigial organ; its importance in surgery results only from its propensity for inflammation, which results in the clinical syndrome known as ‘acute appendicitis’. Acute appendicitis is the most common cause of an ‘acute abdomen’ in young adults and, as such, the associated symptoms and signs have become a paradigm for clinical teaching. Appendicitis is sufficiently common that appendectomy (termed

‘appendectomy’ in North America) is the most frequently performed urgent abdominal operation and is often the first major procedure performed by a surgeon in training. Advances in modern radiographic imaging have improved diagnostic accuracy, however the diagnosis of appendicitis remains essentially clinical, requiring a mixture of observation, clinical acumen and surgical science and as such it remains an enigmatic challenge and a reminder of the art of surgical diagnosis⁽²⁾.

Acute appendicitis can occur at any time during pregnancy, although it occurs most often during the second trimester (45%) and (30%) during the first trimester and the remaining (25%) in the third trimester. The overall incidence being 0.15 to 2.10 per 1000 pregnancies .it is the most common reason for acute abdominal surgery seen in the 15–40 age groups in all communities and sexes; if it occurs during pregnancy, non-obstetrical surgery is require. It is easier to diagnose patients with a history of typical acute appendicitis. Furthermore,

20–33% of patients have atypical clinical and laboratory findings. The clinical findings of acute appendicitis seen during pregnancy are generally atypical, and pregnancy makes it more difficult to make a diagnosis. The anatomical and physiological changes that occur during pregnancy change both the clinical symptoms and the physical examination findings of the clinical table that requires surgical intervention. These problems experienced in the diagnosis and treatment phase can lead to an increase in both maternal and fetal morbidity and mortality⁽³⁾.

Surgery has been the method of choice for treating appendicitis for over 100 years. During the last few years, conservative treatment has been in focus, as treatment with antibiotics offers a low-cost option. The safety of antibiotic treatment is still under debate, and more studies are needed to assess its value in relation to operative treatment of appendicitis⁽⁴⁾.

Appendectomy has been a safe operation, associated with low mortality and morbidity. The decision to undertake surgery is most often based on clinical suspicion of appendicitis, and a relatively

The aim of this study was to evaluate the management of acute appendicitis during different stages of pregnancy as regard the diagnosis and operation time, operative, post-operative complication and pregnancy outcome.

Patients and Methods

This prospective study included a total of 20 pregnant women who had signs and symptoms of acute appendicitis which admitted at Al-Azher University Hospitals and Elmenia General Hospital. All patients were subjected to open appendectomy under spinal anesthesia. Approval of the ethical committee and a written informed consent from all the subjects were obtained. This study was conducted between March 2018 till November 2018.

Time to surgery was defined as the period from onset of symptoms till surgery. A diagnosis of acute appendicitis based on clinical presentation, laboratory and radiological findings. For patients in earlier weeks of pregnancy, patient followed up till 30th postoperative day after appendectomy. A surgical outcome was recorded during that period. After that the patients followed up on pregnancy outcome in obstetric department. In case of the patients who had true labor pain shortly after appendectomy, she was shifted to obstetric unit at

high rate of negative appendectomies is commonly accepted⁽⁵⁾.

Rate of perforation during pregnancy is reported to be as high as 43% compared to 19% in the population. Treatment of acute appendicitis in pregnant patients is surgical intervention i.e. either with open or laparoscopic appendectomy, similarly to the general population. As laparoscopic technique less postoperative pain, shorter length of hospital stay, decreased incidence of thromboembolic events, faster recovery, improved cosmetic outcome, and decreased rates of postoperative ileus is the preferred method for treating appendicitis in the general population a due to its numerous advantages over the open technique, i.e. Despite the initial absolute or relative contraindication of laparoscopic surgical procedures during pregnancy, in the last decade LA has been performed in pregnant women. Although there have been no prospective randomized controlled trials studying LA in pregnant women, several reports have documented the feasibility, safety and effectiveness of LA in this population⁽³⁾.

the hospital and was managed according to gestational age if it more than 37 weak it was terminated otherwise the patient was treated with Tocolytics agent and followed up with obstetrics and gynecology department. Coordination with the obstetric team for follow up of these patients during perioperative period. The patient's preoperative, operative details, postoperative outcomes, and pregnancy related outcomes were analyzed.

Patients included in this study had signs and symptoms of acute appendicitis in different stages of pregnancy. Patient demographics, presenting signs and symptoms, laboratory values, imaging results, details of the surgical intervention, total length of hospital stay, and maternal and fetal outcome were documented.

Abdominal ultrasonography was generally performed as the initial imaging test. Ultrasonography (US) and magnetic resonance imaging (MRI) scans were recorded. Pre- and post-operative patient care was provided by the departments of general surgery and obstetrics. Final diagnosis was based upon macroscopic findings during surgery. A negative appendectomy was defined as surgical resection of an appendix without histological confirmation of appendicular inflammation. Non-perforated appendicitis was defined as an inflamed appendix without signs of

perforation. Complicated appendicitis was defined as appendicitis with evidence of perforation, appendicular abscess, and/or (generalized) peritonitis.

The main outcome variables were maternal and fetal morbidity and mortality. Postoperative complications were detected. Spontaneous abortion is defined as the spontaneous, premature expulsion of a non-viable embryo or fetus from the uterus before 20 weeks of gestation. Fetal loss is defined as the spontaneous loss of pregnancy after 20 weeks of gestation. Preterm delivery is defined as delivery

before the gestational age of 37 weeks. Perinatal mortality is defined as fetal loss and early neonatal mortality, which is defined as death of a live-born baby within the first seven days of life. Relevant variables were analyzed using descriptive statistics. Fetal and maternal outcomes were stratified by pre surgical time and final diagnosis (non-inflamed appendix, non-perforated appendicitis, and perforated appendicitis). Moreover, our patients were classified according to gestational age, namely first (0e12 weeks), second (13e27 weeks), and third trimester (28e42 weeks).

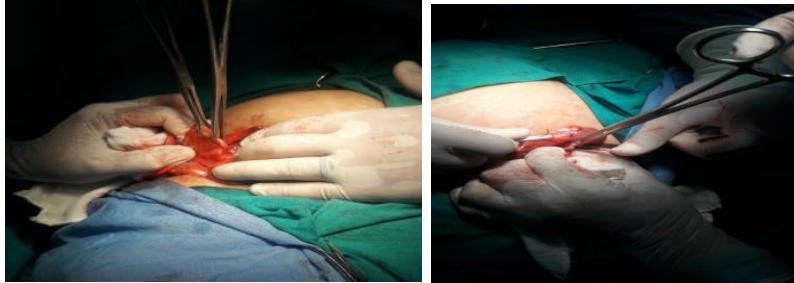


Figure (1): Identification and ligation of inflamed appendix in 35 weeks pregnant women.

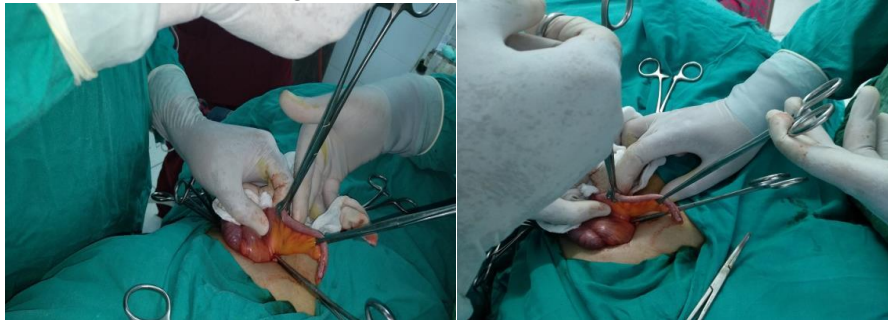

Figure (2): Inflamed appendix in 24 weeks pregnant women.

All the patients involved in the study was subjected to the following:

Clinical history: Detailed history was obtained.

Personal history: includes age, occupation, and special habits of medical importance.

History of present illness: including analysis of the complaint; onset, duration, aggravating & relieving factors, and a review of other body systems specially chest complaints and urinary problems as dysuria or history of renal stone.

Past history: of medical diseases, drug allergy, previous blood transfusion, previous operations and previous complications of previous surgery.

Obstetric history: the previous pregnancy, the LMP caesarean section, abortion, history of preterm labour trouble during pregnancy or during delivery.

Clinical examination: General examination: including vital data; chest examination for signs of chronic disease; abdominal examination for abdominal masses.

Local examination: of the abdomen to confirm the diagnosis of appendicitis, and for the presence of complications.

Routine investigations: were requested for all patients, including complete blood picture, coagulation profile, liver and kidney function tests, fasting blood sugar and pelvi-abdominal U/S to confirm the diagnosis and ensure viability.

Special investigations: pregnancy test for female in early pregnancy.

Preoperative management: Resuscitation with fluids, antibiotic and analgesia. The patient will be reviewed at the Department of Obstetrics and Gynecology for evaluation and add Tocolytics pre-operative.

Intraoperative management: All patients was be subjected to open appendectomy as seen in figure (2).

Postoperative follow up: Early postoperative follow up: For early postoperative wound complications, short hospital stay, early recovery.

Late postoperative follow up: Until the end of pregnancy for any complication.

Item to study: Study different intraoperative and postoperative variables in pregnant patients as mean operative time, rate of perforated appendicitis, the rate of complications, and negative appendectomy. The overall postoperative complications will be observed .Surgical site infection. Duration of hospital stay, Mortality rate, Preterm labor, postoperative fetal loss and patients time to surgery (onset of symptoms to surgery) risk factors for appendicular perforations and for postoperative complications. Signs and symptoms, laboratory values, imaging results, details of the surgical intervention, total length of hospital stay, and maternal and fetal outcome were documented .main outcome variables were maternal and fetal morbidity and mortality.

Results

This study was conducted on 20 pregnant women presenting with symptoms of acute appendicitis. All of them underwent an open appendectomy Overall, 16 women (80%) had acute non-complicated appendicitis, (twelve women (60%) from all sixteen had non-perforated appendicitis and four women (20%) had perforated appendicitis). The negative appendectomy rate was

(20%). Demographic characteristics of the study population are shown in (Table 1).

(Table 1): Demographic characteristics of the entire study population (N=20).

Items	Median (range)
Patient characteristics:	Median (range):
Patient age (years)	26.5 (19.8 - 37.1)
Time interval between onset of symptoms and appendectomy (hours)	54.15 (13 - 223)
Surgical details:	Median (range):
Gestational age at the time of surgery(weeks)	19 (4 - 38)
Duration of operation (minutes)	52.05 (24 - 123)
Length of hospital stay (days)	5.5 (1 - 16)
Obstetrical details:	Median (range):
Gestational age at delivery (weeks)	37.9 (34 - 41)
Birth weight (grams)	3520 (2350 - 4800)
Parity:	No. of women (%):
Primiparous	12 (60%)
Multiparous	8 (40%)

Symptoms:

As shown in (Table 2), the most frequent presenting symptom was pain located in the right lower abdominal quadrant (80%). Other common presenting symptoms were nausea (75%), vomiting (50%), and loss of appetite (45%). A classical history of Paraumbilical pain migrating to the right lower abdominal quadrant occurred in eight out of twenty women (40%), of whom two turned out to have a normal appendix.

(Table 2): Presenting symptoms of the entire study population related to final diagnosis (N=20).

Symptoms	Final diagnosis (number of cases)		
	Normal appendix (N - 4)	Non-perforated Appendicitis (N - 12)	Perforated appendicitis (N - 4)
Abdominal pain:			
Right Lower Quadrant	3	11	2
Right upper Quadrant	1	1	0
Diffuse	0	0	2
Migration of pain	2	4	2
Gastric upset:			
Nausea	3	9	3
Nausea and vomiting	1	6	3
Appetite:			
Loss of appetite	1	5	3
Normal appetite	3	7	1
Defecation abnormality:			
Diarrhea	3	3	2

Signs:

Upon physical examination right, lower quadrant abdominal pain or diffuse abdominal tenderness was seen in the majority of our study population (**Table 3**). Fifteen women showed signs of rebound tenderness (75%) of whom two did not have appendicitis. Three of all women showed signs of involuntary guarding. Six of sixteen women with confirmed appendicitis developed fever (30%).

(Table 3): Signs during physical examination of women suspected of having appendicitis related to final diagnosis (N=20).

Signs	Final diagnosis (number of cases)		
	Normal appendix (N - 4)	Non-perforated Appendicitis (N - 12)	Perforated appendicitis (N - 4)
Generally looks unwell	1	2	3
Tender upon palpitation	4	11	4
Rebound tenderness	2	10	3
Flank tenderness	1	3	3
Rovsing's sign positive	1	8	1
Psoas sign positive	0	5	1
involuntary guarding	0	1	2
abdominal rigidity	0	0	1
Painful digital examination: (rectal/vaginal)	(0/1)	(0/1)	(1/1)
Temperature (C):			
Fever (≥ 38 C)	2	3	3
Afebrile (< 38 C)	2	9	1

Investigation:

Infection markers such as leucocyte count and C - reactive protein (**Table 4**) were not significantly raised in pregnant women with appendicitis compared to pregnant women with a normal appendix. Of note is that a normal C - reactive protein value (10 mg/L) was seen in five out of twelve pregnant women with non-perforated appendicitis.

(Table 4): Laboratory findings in women suspected of having appendicitis related to final diagnosis (N=20).

Laboratory values	Final diagnosis (number of cases)		
	Normal appendix (N - 4)	Non-perforated appendicitis (N - 12)	Perforated Appendicitis (N - 4)
Leucocyte count (cells/mm3):			
Within normal limits (<10.000 cells/mm3)	1	2	0
Elevated (≥ 10.000 & < 16.000 cells/mm3) Or (10.000)	3	8	2
Elevated (≥ 16.000 cells/mm3)	0	2	2
C-reactive protein(mg/L):			
Within normal limits (≤ 10 mg/L)	1	5	2
Elevated (> 10 mg/L)	3	7	2

Abdominal US was performed in all cases. In twelve cases from total twenty cases the appendix could not be visualized during US, of whom eight women were diagnosed with non-perforated

appendicitis, one with perforated appendicitis and three with normal appendix. Following non-visualization of the appendix during US, MRI was used as a secondary diagnostic imaging modality in

Management of Acute Appendicitis during Pregnancy

two patients (both in third trimester of pregnancy). Radiology reports of the MRI scans mentioned that both appendices showed signs of inflammation, which confirmed later during appendectomy that the appendix was inflamed but not perforated.

The appendix was adequately visualized during US in eight cases (40%). The sonographer reported obvious signs of inflammation in six of the eight cases, from whom three confirmed as perforated appendicitis, four with non-perforated appendicitis and one with normal appendix.

Complication:

All cases underwent an open appendectomy. Eight women (40%) underwent surgical intervention during the first trimester, five women (25%) during the second trimester, and seven women (35%) during the third trimester. Intraoperative, a perforated and/or gangrenous appendix was macroscopically seen in four patients (20%) and a peri-appendiceal or pelvic abscess was seen in four of them (20%). **(Table 5)** shows maternal and fetal outcome after and during surgical intervention, final diagnosis, gestational age, patient delay until appendectomy. Delay in treatment seems to be associated with a higher rate of maternal and fetal complications **(Table 5)**.

(Table 5), shows that three women whom underwent an open appendectomy for a perforated appendicitis from total four with perforated appendicitis experienced a postoperative complication. Illustrative, one patient developed intra-abdominal abscess requiring a relaparotomy and she simultaneously underwent a caesarean section she was 36 weeks Gestational age. The other two shows postoperative wound infection one of them one week later gives birth for immature baby

she was 33 weeks gestational age. Two patients were conservatively treated for a postoperative ileus (one with non-perforated appendicitis and the other one with normal appendix). Maternal mortality did not occur. The majority of women carried their pregnancy to term (except three women delivered premature babies) and all delivered viable infants. Nine women (45%) underwent a caesarean section. three women delivered prematurely, of whom one was following a negative appendectomy (25% of negative appendectomy cases) and two following an open appendectomy of a perforated appendicitis (50% of perforated appendicitis cases).

Outcome:

This study shows the incidence of surgical site infection post-operative was two women from all twenty women the two of them diagnosed with perforated appendicitis from whom one was grid iron incision and one median laparotomy. The mortality rate was zero for the mother and the fetus. The incidence of preterm labour which defined as delivery before the gestational age of 37 weeks was three patients two with perforated appendicitis and one after negative appendectomy.

All twenty women included in this study underwent open appendectomy under spinal anesthesia except for one case due to patient refusal in this case the operation done under general anesthesia; six from twenty women developed a postoperative headache relieved by analgesia.

From all twenty the appendectomy was done in seventeen women through grid iron incision, two with lenz incision and one with median laparotomy this was diagnosed with perforated appendicitis preoperative.

(Table 5): Maternal and fetal outcome related to final diagnosis, and gestational age, patient delay until presentation and hospital delay until appendectomy.

Items	Maternal and fetal outcome		
	Uncomplicated	Maternal complication	Fetal Complication
Delay before operation:			
Less than 24 h	7	0	0
24-47 h	3	1	0
48-71 h	2	2	1
More than 72 h	1	2	2
Final diagnosis:			
Normal appendix	2	1	1
Non-perforated appendicitis	11	1	0
Perforated appendicitis	1	3	2
Trimester of pregnancy:			
First	6	2	0
Second	4	1	0
Third	2	2	3

Discussion

Appendectomy is the most common surgical procedure performed in general surgery with a life-time risk about 6% ⁽⁶⁾.

Managing abdominal pain in the gravid patient presents a dilemma in which the clinician must consider the risks and benefits of diagnostic modalities and therapies to both the mother and the fetus, "Earlier diagnosis means better prognosis" ⁽⁷⁾.

Certain anatomic and physiologic changes specific to pregnancy may make the cause of the abdominal pain difficult to ascertain in pregnant patients. The uterus becomes an abdominal organ at around 12 weeks' gestation and compresses the underlying abdominal viscera. This enlargement may make it difficult to localize the pain and may also mask or delay peritoneal signs. The laxity of the anterior abdominal wall may also mask or delay peritoneal signs. The ureters become dilated as early as the first trimester and remain dilated into the postpartum period. This distension may lead to urinary stasis, increasing not only the risk of urolithiasis, but also infection. Increasing progesterone increases respiratory drive. Functional residual capacity decreases. Hemostatic changes also add to the challenge of evaluating and caring for pregnant women. Pregnancy produces a thrombogenic state, with two-to-three-fold increase in fibrinogen levels. In pregnancy, physiologic leukocytosis occurs, and in our study, all patients had leukocytosis ⁽⁸⁾.

Anatomical changes related to the gravid uterus, gestational symptoms, the physiological inflammatory response, and a wider differential diagnosis in pregnant women result in poor diagnostic accuracy, reported to range from 36% to 86%. Acute appendicitis has a peak incidence in the second and third decades coinciding with the childbearing years, and the incidence in pregnancy appears broadly the same as in the non-pregnant, whereas the rate of perforation and subsequent complications are greater ⁽⁸⁾.

In pregnant women with abdominal pain, fetal outcome depends on the outcome of the mother. Optimal maternal outcome may require radiologic imaging, sometimes with ionizing radiation. A risk benefit discussion with the patient should occur prior to any diagnostic study ⁽⁹⁾.

The need for prompt surgical intervention in case of suspected appendicitis to avoid adverse outcome related to appendiceal perforation has to be

balanced with the need for additional imaging to enhance preoperative diagnostic accuracy to avoid mortality and morbidity associated with unnecessary surgical intervention, we found that negative appendectomies are associated with a high rate of fetal morbidity. concluded that it appears that the greatest opportunity to improve fetal outcomes is by improving diagnostic accuracy and reducing the rate of negative appendectomy in pregnant women ⁽¹⁰⁾.

It has been nearly 100 years since Balber stated that 'the mortality of appendicitis complicating pregnancy is the mortality of delay'. The wisdom of this statement has been repeatedly demonstrated. According to study done by **Kapan and Selin** ⁽⁶⁾; delay in the diagnosis of appendicitis is associated with significant complications. Delay to surgery is equally risky, with rates of fetal loss reported to be 1.5-4% in uncomplicated appendicitis compared with 21-35% in the presence of ruptured appendicitis. A fetal loss rate of 3-5% is observed with an unruptured appendix; this rate increases up to 20% if the appendix is ruptured. The risk of preterm labor is greatest during the first week after surgery, but preterm delivery is rare. Furthermore, increasing gestational age reduces diagnostic accuracy and is associated with increased rates of appendiceal perforation and hence complications. We operated the patients in our series within 12 hours. Contrary to the literature, in our study, there was no fetal loss or appendiceal perforation. The reason for this difference was the short time period between consultation and operation in our study ⁽¹¹⁾.

Brown et al. specified that negative laparotomy in the pregnant patients, who were operated due to acute appendicitis, was about 25-50%. Negative laparotomy was not observed in any of our cases ⁽⁸⁾.

Giorgakis et al. specified that fetal mortality that developed due to acute appendicitis in pregnant women was 5% and maternal mortality was approximately 1% and if perforation had occurred, these numbers increased to 20% and 4%, respectively. Perforation or mortality was not observed in any of our patients ⁽¹²⁾.

To date in our study, the optimal clinical approach to the management of pregnant women suspected of having acute appendicitis is subject to debate. In this prospective study, we evaluated twenty pregnant patients whom underwent appendectomy for suspected appendicitis aiming to

be able to provide recommendations for prospective clinical management. A considerable number of studies on appendicitis during pregnancy have been reported but are often limited based upon the generally low prevalence of appendicitis during pregnancy.

These physical alterations result in a diminished response to peritoneal irritation and reference of pain perception. Physiological leucocytosis associated with pregnancy can obscure an increased leucocytic count related to disease. Consistent with previous literature, there were no significant differences between patients with and without appendicitis regarding frequency of presenting symptoms or laboratory results. Noticeable, in our study pain in the right lower quadrant of the abdomen was present in all cases with pathologically proven appendicitis, which is mentioned in 76% -82.4% of cases in previous. Only 53% of our patients with pathologically proven appendicitis reported a classic history of diffuse or periumbilical pain migrating to the right lower abdominal quadrant (versus 29%-48% reported). Furthermore, numerous pregnancy-related, gynaecological and other abdominal differential diagnoses must be taking into account when trying to establish the correct diagnosis during pregnancy.

Currently, the optimal surgical technique to be used to treat acute appendicitis during pregnancy is yet to be established. Presently, the choice of surgical approach is possibly based upon trimester of pregnancy and surgeon's preference. In this study open appendectomy were performed under spinal anesthesia.

Our study shows that delay in surgical treatment of appendicitis during pregnancy seems to be associated with a higher rate of maternal and fetal complications. Furthermore, this study confirms that both a negative appendectomy and perforated appendicitis during pregnancy result in increased rates of prematurity. These results indicate that prompt and accurate diagnosis is extremely important. In accordance with other studies, the diagnosis of appendicitis during pregnancy remains inaccurate based upon the combination of history of presenting complaint, physical examination, laboratory results, and ultrasonography. Based upon current clinical literature, MRI must be second choice investigation when appendicitis is suspected during pregnancy.

Appendectomy should be performed as soon as possible when MRI is suggestive of appendicitis.

Conclusion

According to this prospective study on 20 pregnant women who had appendicitis and open appendectomy, both (perforated) appendicitis and negative appendectomy during pregnancy are associated with a high risk of premature delivery. Clinical presentation and imaging remain vital in deciding whether surgical intervention is indicated. US must be done for all cases even MRI may be needed to decrease of appendiceal perforation and the risk of unnecessary surgical intervention.

Accurate and prompt diagnosis of acute appendicitis should be done to avoid unnecessary exploration and to aim for timely surgical intervention in pregnant women suspected of having appendicitis.

References

1. **Baer JL, Reis RA and Arens RA (1975) :** Appendicitis in pregnancy: with changes in position and axis of the normal appendix in pregnancy. *Obstetrics & Gynecology*, 46: 655-662.
2. **Brown J, Wilson C, Coleman S et al. (2009) :** Appendicitis in pregnancy: an ongoing diagnostic dilemma. *Colorectal Disease*, 11: 116-122.
3. **Eyvazzadeh AD and Levine D (2006) :** Imaging of pelvic pain in the first trimester of pregnancy. *Radiologic Clinics*, 44: 863-877.
4. **Giorgakis E, Karydakis V and Farghaly A (2012):** Perforated endometrial appendicitis in pregnancy. *Hippokratia*, 16: 181-186.
5. **Guller U, Hervey S, Purves H et al. (2004) :** Laparoscopic versus open appendectomy: outcomes comparison based on a large administrative database. *Annals of Surgery*, 239: 43-52.
6. **Kapan S, Bozkurt MA, Turhan AN et al. (2013) :** Management of acute appendicitis in pregnancy. *Ulus Travma Acil Cerrahi Derg*, 19: 20-24.
7. **Mahadevan V (2017) :** Anatomy of the caecum, appendix and colon. *Surgery (Oxford)*, 35: 115-120.
8. **Markar S, Karthikesalingam A, Cunningham J et al. (2011) :** Increased

use of pre-operative imaging and laparoscopy has no impact on clinical outcomes in patients undergoing appendectomy. <https://publishing.rcseng.ac.uk/doi/full/10.1308/003588411X13165261994076>

9. **Mcgory ML, Zingmond DS, Tillou A *et al.* (2007)** : Negative appendectomy in pregnant women is associated with a substantial risk of fetal loss. *Journal of the American College of Surgeons*, 205: 534-540.
10. **Rocha LL, Rossi FM, Pessoa CM *et al.* (2015)** : Antibiotics alone versus appendectomy to treat uncomplicated acute

appendicitis in adults: what do meta-analyses say? *World Journal of Emergency Surgery*, 10: 51-58.

11. **Silen W and Cope Z (2005)** : Cope's early diagnosis of the acute abdomen, oxford university press, <https://global.oup.com/.../copes-early-diagnosis-of-the-acute-abdomen-97801997304>
12. **Tatli F, Yucel Y, Gozeneli O *et al.* (2017)** : The alvarado score is accurate in pregnancy: a retrospective case-control study. *European Journal of Trauma and Emergency Surgery*, 15: 1-6.