

Clinical significance of turbid amniotic fluid on peripartum outcome**Mona Gad Mohammed^{a*}, Mahmoud S. Iwes^a, Mahmoud Almolakab B Alrashedy^a**^aDepartment of Obstetrics and Gynecology, Faculty of Medicine , South Valley University., Qena , Egypt**Abstract**

Background: The fluid that envelops a growing fetus in the amniotic sac is called amniotic fluid (AF), many maternal and fetal components share in composition of amniotic fluid, in the last three months of pregnancy, AF turbidity increases and was associated with the appearance of vernix caseosa and meconium.

Objectives: To estimate the nature of the echogenic amniotic fluid and to overcome unnecessary intervention due to turbid amniotic fluid.

Patients and Methods: A total of 116 Pregnant women (near or full term) who delivered at emergency unit of Obstet. and Gynecol, South Valley University with reliable dates of LMP and delivered after normal vaginal delivery or by CS. full history, clinical examination, US findings (echogenic amniotic fluid), gestational age, and investigations were recorded. also neonatal weight, APGAR Score and nature of amniotic fluid after delivery were recorded.

Results: The current study showed that regarding nature of amniotic fluid after delivery, (0.9%) had bloody, (4.3%) had meconium and (94.8%) had vernix caseosa. According to US, AFI was Average in (90.5%), Decreased in (7.8%) and increased in (1.7%). Mean of gestational age at time of termination was (38.29 ± 1.37). Our results showed that according to mode of delivery (55.2%) were NVD and (44.8%) were CS. The median of APGAR score of neonate was (8.00).

Conclusions: echogenic amniotic fluid had clinical significance and 94.8% of pregnant women (near or full term) with turbid amniotic fluid showed presence of vernix caseosa.

Key words: turbid; amniotic fluid ; US.

DOI: 10.21608/svuijm.2022.125376.1291

***Correspondence:** monaalrayan90@gmail.com

Received: 5 March, 2022.

Revised: 5 March, 2022.

Accepted: 19 April, 2022.

Cite this article as: Mona Gad Mohammed, Mahmoud S. Iwes, Mahmoud Almolakab B Alrashedy. (2022). Clinical significance of turbid amniotic fluid on peripartum outcome. *SVU-International Journal of Medical Sciences*. Vol.5, Issue 2, pp: 181-188.

Copyright: © Mohammed et al. (2022) Immediate open access to its content on the principle that making research freely available to the public supports a greater global exchange of knowledge. Users have the right to Read, download, copy, distribute, print or share link to the full texts under a [Creative Commons BY-NC-SA 4.0 International License](https://creativecommons.org/licenses/by-nc-sa/4.0/).

Introduction

The fluid that envelops a growing fetus in the amniotic sac is called amniotic fluid (AF), many maternal and fetal components share in composition of amniotic fluid. The structure of the AF varies according to age of pregnancy (**Pillitteri, 2007**).

Amniotic fluid echogenicity relatively demonstrate the density and number of free-floating matter in amniotic fluid and then turbidity of the fluid. This would make ultrasound revelation of free-floating echogenic matter, which is called amniotic fluid sludge (**Johnson et al., 1998**).

Echogenic matter in AF is seen in the first six months of pregnancy by ultrasound in about 4% , It is also associated with intraamniotic haemorrhage (**Cafici and Sepulveda, 2003**).

In the last three months of pregnancy, the appearance of AF turbidity increases and was associated with the appearance of vernix caseosa and meconium (**Tam and AL-Dughaishi, 2013**).

Main composition of vernix caseosa is fatty substance which is a mix of the shedded epithelial cells and sebum secreted by the sebaceous glands (**Hill and Breckle, 1986**).

The presence of a multiplicity of echogenic matter in the amniotic fluid makes AF turbid that it is an unusual finding. vernix caseosa is the leading cause, but, meconium could be the cause (**Kaluarachchi et al., 2018**). We aimed in this work to estimate the nature of echogenic amniotic fluid and to overcome unnecessary intervention due to turbid amniotic fluid and to assess neonatal outcome in patient with turbid amniotic fluid.

Patients and methods

The study was conducted on 116 Pregnant women (near or full term) who delivered at emergency unit of Obstet. and Gynecol, South Valley University with reliable dates of LMP and delivered after normal vaginal delivery or by CS. full history, clinical examination, US findings (echogenic amniotic fluid), gestational age, and

investigations were recorded. also neonatal weight, APGAR Score and nature of amniotic fluid after delivery were recorded. Clear verbal counseling and written consent were obtained from all participants in the research according to the committee of Medical Ethics of Faculty of Medicine, South Valley University.

Inclusion criteria; Pregnant women (near or full term) who delivered at emergency unit of Obstet. and gynecol, South Valley University and delivered after spontaneous onset of labor or by CS.

Exclusion criteria; pregnant women who had high risk factor (maternal and fetal) such as hypertension with pregnancy , preeclampsia, gestational diabetes mellitus, endocrinal disorders, renal disease , intra-uterine growth retardation or macrosomic fetuses , Fetal malformations ,Multiple pregnancies.

Methodology: The following steps were done for all patients included in this study

1. Detailed history and clinical examination.
2. Routine investigations (Complete blood count, blood grouping, liver function tests , kidney function tests , prothrombin time , prothrombin concentration , serum blood sugar).
3. Ultrasonographic revelation of turbid amniotic fluid particles:

The turbid amniotic fluid matter was measured in pregnant women (near or full term) who came to emergency unit of Obstet. and gynecol, South Valley University and planned for termination of pregnancy by normal vaginal delivery or by CS after initial assessment and fulfillment the inclusion criteria.

Transabdominal ultrasonography (5 MHz) showed turbid amniotic fluid in different pictures in the form of echogenic minute dots, scanty scattered particles, dense clusters of particles.

4. Biophysical profile was performed
5. CTG was performed for fetal monitoring if indicated.
6. After delivery of the fetus (vaginal delivery or by CS) amniotic fluid was assessed by direct visualization for sings of

maturity(vernix caseosa) ,meconium , blood or other component.

7.Neonatal assessment using Apgar score.

Ethical consideration: Clear verbal counseling and written consent were obtained from all participants in the research according to the committee of Medical Ethics of Faculty of Medicine, South Valley University.

Ethical approval code: SVU-MED-OBG024-1-20-12-107.

Statistical analysis:The qualitative data were presented as number and percentages while quantitative data were presented as mean, standard deviations and ranges when their distribution found parametric by using the Statistical Program for Social Sciences (SPSS Inc., Version 21.0, Chicago, IL, USA).

Results

This study was conducted on 116 Pregnant women, the mean age was 26.99 ± 6.06 (16-41).

As regard mode of previous deliveries 59 (50.9%) of them delivered by spontaneous vaginal delivery, 36 (31.0%) of them delivered by CS and 21 (18.1%) of them had no previous deliveries **Table.1**

The vernix caseosa was statistically significant in cases with echogenic amniotic fluid by US, The current study showed that

regarding nature of amniotic fluid after delivery, (0.9%) had bloody, (4.3%) had meconium and (94.8%) had vernix caseosa.

Table.2 and Fig. 1

Our results showed that according to mode of delivery (55.2%) were NVD and (44.8%) were CS. **Table.2 and Fig. 2**

Table.3 showed that mean of gestational age at time of termination was (38.29 ± 1.37) , The median of APGAR score of neonate after delivery was (8.00) and median birth weight was 3.06 ± 0.18 .

Table.4 and Table.5 showed ultrasonographic criteria of studied women. AFI was Average in (90.5%), Decreased in (7.8%) and Increased in (1.7%).

As regard ultrasonographic picture of echogenic amniotic fluid and comparing it with nature of amniotic fluid after delivery, amniotic fluid particles appeared as minute dots by us in 49 cases, vernix caseosa present in 97.9% of cases after delivery.

In 62 cases, amniotic fluid particles appeared by us as scanty scattered particles, 98.3% of them showed vernix caseosa and 1.7% showed meconium after delivery.

Five cases showed dense clusters of particles by US , 60% showed meconium , 20% showed vernix caseosa and 20% showed blood stained amniotic fluid after delivery.

Table 1. Distribution of cases according to Age, Parity and Previous deliveries.

Variables		No.= 116
Age	Mean \pm SD	26.99 ± 6.06
	Range	16 – 41
Parity	I	34 (29.3%)
	II	18 (15.5%)
	III	33 (28.4%)
	IV	8 (6.9%)
	V	1 (0.9%)
	VI	1 (0.9%)
	Primigravida	21 (18.1%)
Previous deliveries	No	21 (18.1%)
	NVD	59 (50.9%)
	CS	36 (31.0%)

Table 2. Distribution of cases according to route of delivery, nature of amniotic fluid after delivery.

Variables		No.= 116
Route of delivery	CS	52 (44.8%)
	NVD	64 (55.2%)
Nature of amniotic fluid after delivery	Bloody	1 (0.9%)
	Meconium	5 (4.3%)
	Vernix caseosa	110 (94.8%)

Table 3. Distribution of the cases according to pregnancy age at time of delivery (week), neonatal weight (Kg) and APGAR score of neonate.

Variables		No.= 116
Pregnancy age at time of delivery (week)	Mean \pm SD	38.29 \pm 1.37
	Range	34 – 41
Neonatal weight (Kg)	Mean \pm SD	3.06 \pm 0.18
	Range	2.5 – 3.5
APGAR score of neonate	Median (IQR)	8.00 (8 – 8)
	Range	6 – 10

Table 4. Distribution of the studied cases according to US and CTG.

Variables		No.	%
Cardiotocography (CTG)	Non Reactive	3	2.6%
	Reactive	113	97.4%
Fetal presentation	Breech	2	1.7%
	Cephalic	114	98.3%
AFI	Average	105	90.5%
	Decreased	9	7.8%
	Increased	2	1.7%

Table 5. Ultrasonographic picture of echogenic amniotic fluid

Variables		No.	%
Minute dots	Vernix caseosa	48	97.9%
	Meconium	1	2.1%
	bood	0	0%
Scanty scatterd particles	Vernix caseosa	61	98.3%
	Meconium	1	1.7%
	bood	0	0%
Dense clusters of particles	Vernix caseosa	1	20%
	Meconium	3	60%
	bood	1	20%

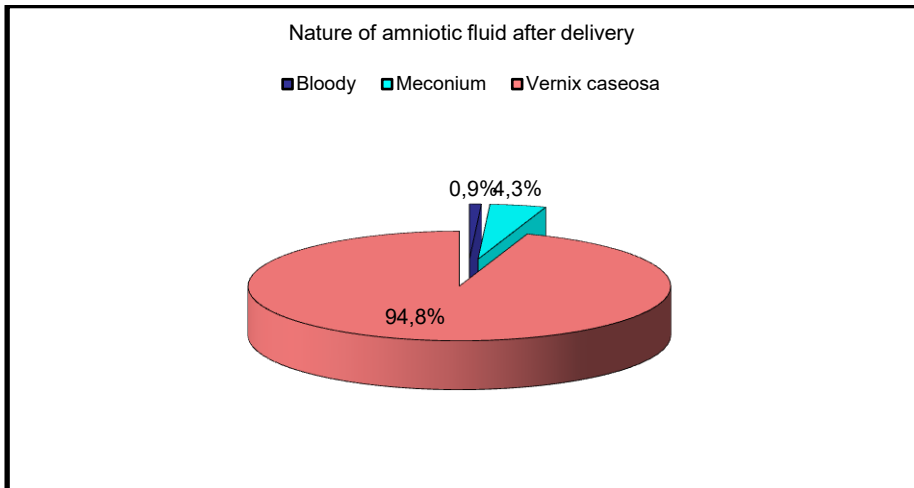


Fig1. Distribution of the cases according to Nature of amniotic fluid after delivery.

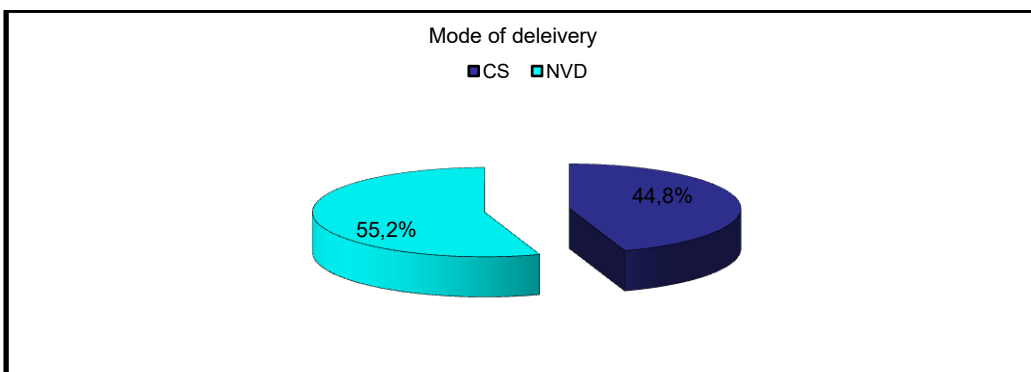


Fig.2. Distribution of the cases according to route of delivery.

Discussion

The fluid that envelops a growing fetus in the amniotic sac is called amniotic fluid (AF), many maternal and fetal components share in composition of amniotic fluid. The structure of the AF varies according to age of pregnancy (Pillitteri, 2007).

Amniotic fluid echogenicity relatively demonstrate the density and number of free-floating matter in amniotic fluid and then turbidity of the fluid. This would make ultrasound revelation of free-floating echogenic matter, which is called amniotic fluid sludge (Johnson et al., 1998).

Echogenic matter in AF is seen in the first six months of pregnancy by ultrasound in about 4% , It is also associated with intraamniotic haemorrhage (Cafici and Sepulveda, 2003).

In the last three months of pregnancy, the appearance of AF turbidity increases and was associated with the appearance of vernix caseosa and meconium (Tam and AL-Dughaiishi, 2013).

Main composition of vernix caseosa is fatty substance which is a mix of the shedded epithelial cells and sebum secreted by the sebaceous glands (Hill and Breckle, 1986).

The presence of a multiplicity of echogenic particles in the fluid makes AF turbid that it is an unusual finding. vernix caseosa is the leading cause, but, meconium could be the cause (Kaluarachchi et al., 2018).

This study aimed to know the nature of turbid amniotic fluid , overcome unnecessary intervention due to turbid amniotic fluid , assess neonatal outcome and estimate gestational age at time of delivery in patient with turbid amniotic fluid

It was a cross section study, it was performed from January 2021 to December 2021 conducted on Pregnant women (near or full term) who delivered at emergency unit of Obstet and gynecol, South Valley University, Egypt.

Our results revealed that according to US, AFI was Average in (90.5%), Decreased in (7.8%) and Increased in (1.7%).

In a study by Mehra et al., (2015) showed

that a shorter cervical length and an Amniotic Fluid Index (AFI) 5 cm and cervical length > 2 cm highly expect to remain undelivered at 7 days with a negative predicting value (NPV) of 93%. But, this ultrasound picture gave a weak positive predictive value (PPV) in expecting an imminent delivery and their diagnostic reliability was dependent from gestational age at p-PROM.

Echogenic amniotic fluid is frequently seen during ultrasound examination and it has been reported in about 4% of pregnant women during transvaginal ultrasound at early second trimester (Ventura et al.,2011). This ultrasonographic picture has also been seen in women with intra-amniotic haemorrhage (Vengalil et al., 1998).

Mean of gestational age at time of termination was (38.29 ± 1.37) .

In a study the mean gestational age at time of delivery was 39 weeks for late trimester pregnant women with turbid amniotic fluid (Buyuk et al.,2021).

The current study showed that regarding nature of amniotic fluid after delivery, (0.9%) had bloody, (4.3%) had meconium and (94.8%) had vernix caseosa. Buyuk et al., (2021) showed that vernix caseosa was the most common matter present in the amniotic fluid. Sherer et al., (1991) revealed that very echogenic amniotic fluid made a specificity of 69%, sensitivity of 100% and it also made a negative predictive value of 100% and a positive predictive value of 10% for presence meconium in amniotic fluid. Espinoza et al., (2005) indicated that debris from intra-amniotic bleeding in the index pregnancy may not contribute to the AF 'sludge'. Indeed, the proportion of discolored AF, an index of earlier intra-amniotic bleeding

Petrikovsky et al., (1998), studied 19 twin pregnancies, with one sac contained echogenic amniotic fluid and another sac contained anechoic amniotic fluid , nature of amniotic fluid was assessed from samples collected by amniocentesis or after delivery within 2 days of sonographic examination vernix was present in 63% of cases, meconium was present in 5% of the cases

and no abnormalities present in 32% of cases, The net result conducted that ultrasonographic picture of echogenic amniotic fluid before delivery was not predictive of meconium.

Shirazi et al., (2016) reported that vernix caseosa is the major cause of highly echogenic amniotic fluid found by sonographic examination rather than meconium, and when the nonstress test and biophysical profiles are promising, unneeded intervention for termination of pregnancy should not be done.

In late pregnancy, free-floating matter in AF has been associated with the presence of vernix and meconium (**DeVore and Platt, 1986**) and is found in about 88% in late trimester (**Parulekar, 1983**). Evaluation of amniotic fluid clinically using amniocentesis or after delivery, 5 – 11% of turbid amniotic fluid had meconium (**Malinowski, 2002**).

Mungen et al., (2005) conducted a large study considering turbidity of amniotic fluid in about thousand of single term pregnancies, echogenic amniotic fluid was present in 6.95% (66) of cases, meconium found in AF at time of delivery in women with echogenic amniotic fluid in 10.61% (7) and found in women without echogenic amniotic fluid in 9.62% (85), with no statistically significant difference ($p = 0.79$).

Our results showed that according to mode of delivery (55.2%) were NVD and (44.8%) were CS. In a study by **Buyuk et al., (2021)** showed that the rate of caesarean section was higher in women with echogenic amniotic fluid. The median of APGAR score of neonate was (8.00 (8 – 8)).

According to **Buyuk et al., (2021)** reported that the 1st and 5th min Apgar scores were assessed; significantly neonates delivered to mothers with echogenic amniotic particles had lower Apgar scores (< 7).

Conclusion

Based on the results of the current study it can be concluded that: echogenic amniotic fluid had clinical significance and 94.8% of cases of turbid amniotic fluid showed presence of vernix caseosa.. This issue should be considered during

ultrasonographic assessment of women during third trimester to overcome unnecessary intervention due to turbid amniotic fluid after good assessment of fetus by fetal wellbeing tests. Study on large number of patients is needed to support our results.

Conflict of interest

The authors of this study have no conflict of interest related to this publication.

References

- **Buyuk GN, Oskovi-Kaplan ZA, Kahyaoglu S, Engin-Ustun Y (2021).** Echogenic particles in the amniotic fluid of term low-risk pregnant women: does it have a clinical significance? *Journal of Obstetrics and Gynaecology*, 1–5.
- **Cafici D, Sepulveda W (2003).** First-trimester echogenic amniotic fluid in the acrania-anencephaly sequence. *J Ultrasound Med*,22:1075–9.
- **DeVore GR, Platt LD (1986).** Ultrasound appearance of particulate matter in amniotic cavity: vernix or meconium? *J Clin Ultrasound* ,14(3):229-230.
- **Espinoza J, Gonçalves LF, Romero R, Nien JK, Stites S, Kim YM, et al. (2005).** The prevalence and clinical significance of amniotic fluid ‘sludge’ in patients with preterm labor and intact membranes. *Ultrasound obstet. gynecol*, 25(4): 346–352.
- **Hill LM, Breckle R (1986).** Vernix in amniotic fluid: Sonographic detection. *Radiology*,158:80
- **Johnson MP, McCarty DR, Velayo NL, Markgraf CG, Chmielewski PA, Ficorilli JV, et al (1998).** MDL 101,002, a free radical spin trap, is efficacious in permanent and

- transient focal ischemia models. *Life Sci*, 63:241–53.
- **7. Kaluarachchi A, Jayawardena GRMUGP, Ranaweera AKP, Rishard MRM (2018).** Hyperechoic amniotic fluid in a term pregnancy. *J Family Med Prim Care*, 7(3):635-637.
 - **Malinowski W (2002).** Clinical significance of echogenic amniotic fluid at term pregnancy. *Ginekol Pol* 73: 120–123
 - **Mehra S, Amon E, Hopkins S, Gavard JA, Shyken J (2015).** Transvaginal cervical length and amniotic fluid index: can it predict delivery latency following preterm premature rupture of membranes? *Am J ObstetGynecol* ,212:400e1-9.
 - **Müngen E, Tütüncü L, Muhcu M (2005).** Pregnancy outcome in women with echogenic amniotic fluid at term gestation. *Int J GynaecolObstet*, 88:314–315.
 - **11. Parulekar SG (1983).** Ultrasonographic demonstration of floating particles in amniotic fluid. *J Ultrasound Med*,2(3):107-10.
 - **12. Petrikovsky B, Schneider EP, Gross B (1998).** Clinical significance of echogenic amniotic fluid. *J Clin Ultrasound*,26:191–3.
 - **13. Pillitteri A (2007).** *Maternal & Child Health Nursing: Care of the Childbearing & Childrearing Family*. 7th ed. Philadelphia, PA: Lippincott Williams & Wilkins; p. 193.
 - **14. Sherer DM, Abramowicz JS, Smith SA, Woods JR (1991).** Sonographically homogeneous echogenic amniotic fluid in detecting meconium-stained amniotic fluid. *Obstet Gynecol*,78:819–22.
 - **15. Shirazi M, Niroomanesh S, Rahimi Shaarbaf F, Rabiei M, Eftekhariyazdi M (2016).** Very Echogenic Amniotic Fluid and Its Clinical Significance: A Case Report. *J Obstet Gynecol Cancer Research*,1(1)
 - **16. Tam G, AL-Dughaishi T (2013).** Case report and literature review of very echogenic amniotic fluid at term and its clinical significance. *Oman Medical J*, 28:461–3.
 - **17. Vengalil S, Santolaya-Forgas J, Meyer W, Myles T (1998).** Ultrasonically dense amniotic fluid in early pregnancy in asymptomatic women without vaginal bleeding. A report of two cases. *J Reprod Med* ,43:462–464.
 - **18. Ventura W, Nazario C, Ingar J, Huertas E, Limay O, Castillo W (2011).** Risk of impending preterm delivery associated with the presence of amniotic fluid sludge in women in preterm labor with intact membranes. *Fetal Diagnosis and Therapy*, 30(2):116-21.