

Efficacy of intra Pleural streptokinase injection in Post traumatic Clotted Hemothorax

Mohammed A. Elgazzar, Hany M. AlRakhawy, Noha A. Nabeh, Ashraf M. Elnahas, Mahmoud A. ElShafiey

Department of cardiothoracic surgery, Benha faculty of medicine, Banha University, Egypt.

Correspondence to: Noha A. Nabeh, Department of cardiothoracic surgery, Benha faculty of medicine, Banha University, Egypt.

Email:

abdelkader_noha@yahoo.com

Received: 2 August 2020

Accepted: 25 April 2022

Abstract

Background: Post traumatic clotted hemothorax is a serious problem associated with fluid loculation by fibrous adhesions, trapped lungs and increase the risk of infection and empyema. Intrapleural instillation of streptokinase may dissolve fibrin clots and membranes, break down adhesions and facilitate complete evacuation of residual blood clots and loculated effusions especially if given in the 1st 7days post trauma. **The aim** of this study is to evaluate the effect of streptokinase injection as a fibrinolytic drug treating patients with clotted hemothorax within and after 1-week post trauma. **Methodology** of this study included 60 patients divided randomly into 2 groups. Group A: include 30 patients with clotted hemothorax receiving streptokinase from 3rd to 7th day post trauma.

Group B: include 30 patients with clotted hemothorax receiving streptokinase after 1-week post trauma. **Results** of this study revealed no difference between both groups regarding age, gender, side of affection or number of SK injection doses. There were a significant reduction in surgical intervention post SK injection ($P = 0.004$), period between trauma and SK use ($P < 0.001$) and failure of SK injection ($P = 0.002$) and total hospital stay ($P < 0.001$) and CT results post SK injection ($P = 0.001$) in group A against group B. **Conclusion:** Intrapleural streptokinase injection could be an ideal option for post-traumatic clotted hemothorax before the decision is made to proceed to VATS or thoracotomy especially if given in the 1st 7 days post trauma.

Keywords: Clotted hemothorax, Intrapleural streptokinase injection, Time of chest trauma.

Introduction

Hemothorax defined as bleeding into pleural cavity which contains a hematocrit value of at least 50% of the hematocrit of peripheral blood. Hemothorax caused by spontaneous, iatrogenic or post traumatic.⁽¹⁾

Thoracic trauma occurs in 60% of the polytraumatic cases in which the occurrence of hemothorax related to trauma approaches 300,000 cases per year. Moreover, 25% of traumatic deaths are related to post traumatic hemothorax caused by intra pleural or extra pleural injuries.⁽²⁾

Tube thoracostomy is commonly adequate for the initial management of hemothorax. However, failure of tube thoracostomy causes clotted hemothorax in 5% to 30% of cases.⁽³⁾

The clotted hemothorax should be evacuated within 7 to 10 days of injury. However, if not evacuated after the 10th day, clotted blood cannot be easily removed and the decortication will be required at later days (within 4th or 5th weeks).⁽⁴⁾

The complications of non-treated hemothorax are associated with fibrin threads formation on the surface of pleura with an obvious proliferation of fibroblastic and angioblastic cells and transformation to

fibrothorax due to inflammatory exudates covering of visceral and parietal pleura and reduces the lung volumes.⁽⁵⁾

Streptokinase (SK) is anti-thrombotic drug that acts on the fibrinolytic system. Streptokinase was obtained naturally from Beta hemolytic streptococci and was used to break down clots in some cases of myocardial infarction, pulmonary embolism.⁽⁶⁾

Administration of intrapleural SK in clotted hemothorax has high success rate about 92-94% as it helps in rapid removal of clot before formation of pleural thickening and adhesion leading to avoidance of surgical decortication. Complete response (CR) was defined as resolution of symptoms with complete drainage of fluid and no residual space radio graphically. Partial response (PR) was defined as resolution of symptoms with a small pleural cavity. Non responders (NRs) were patients who underwent decortication.⁽⁷⁾

Patients and Methods

This study is a prospective single blinded randomized study conducted on 60 patients with post traumatic clotted hemothorax between April 2019 to April 2020 at

Cardiothoracic Surgery Department in Benha University Hospitals.

Patients in this study were divided into 2 groups. Group A: include 30 patients with clotted hemothorax receiving streptokinase from 3rd to 7th day and Group B: include 30 patients with clotted hemothorax receiving streptokinase after 1 week.

Inclusion criteria were as follows: Patients at any age of both genders, patients with thoracic trauma < 10 days, patients with post traumatic hemothorax who failed complete pleural drainage after 3 days by chest tube. patients with post-operative residual hemothorax > 3 days and CT chest showing retained hemothorax after initial placement of tube thoracostomy > 3days.

Exclusion criteria were as follows: patients sensitive to streptokinase, significant associated intra-abdominal or another organ disease, patients with coagulopathy, patients with severe medical diseases like liver cirrhosis, chronic obstructive pulmonary disease, and multi-organ failure, patients with renal failure and patients with bronchopleural fistula.

The procedure was done through tube thoracostomy under complete aseptic conditions by small incision at 5th space mid

axillary line, dissection by Hilton method then insertion of ICT of large caliber connected to under water seal.

This study was conducted in two groups with injection of streptokinase. Streptokinase (SK) was given as 250,000 IU for adults and 15000 IU/kg for pediatric patients diluted in 50 mL of saline solution followed by 50 mL saline through the intercostal tube with sterile injection .After that, the tube was clamped for 1-2 hours with frequent postural change of the patients every 15 minutes then the clamp was removed and the tube placed back on negative suction allowing the dissolved clots to be drained in the underwater seal. The amount of drain was calculated daily. Chest X-ray was done after the 2nd dose if there was residual of the clotted Hemothorax and a third dose was given. This maneuver was repeated for 2-3 successive days with recording the data in patients' charts with chest x-ray finding and CT Chest. The chest tube was removed when pleural drainage <50 mL serous fluid within 24h, lung fully expanded and no pleural effusion.

Ethical consideration: An approval from Research Ethics Committee in Benha faculty of medicine was obtained.

Results

The current study showed that the mean age of patients in group A was 34 years while those in group B, the mean age was 31 years. Also, it showed that the majority of the patients in both groups were males **as shown in (Table 1).**

This study showed that the incidence of complicated clotted hemothorax was higher in group B (30%) than in group A (3.3%) with a statistically significant difference between both groups (P value = 0.006) **as shown in (Fig. 1).**

This study revealed that the mean period between trauma and SK use was higher in group B (13 days) than in group A (5 days) and this was statistically highly significant (P value <0.001). Also, it showed that the mean number of doses used in both groups was almost equal and this was insignificant statistical difference (P value = 0.14) **as shown in (Table 2).**

Also, this study showed that the failure of SK injection was higher in group B (63.3%) than in group A (23.3%) and this was statistically highly significant (P value = 0.002) **as shown in (Fig 2).**

This study showed that CT improving results post SK injection in group A were statistically higher than that of group B (P value = 0.001) and no improvement post SK injection was higher in group B than that of group A with a statistically highly significant (P value = 0.001) **as shown in table (3).**

Also, this study showed that total hospital stay post SK injection in group B was statistically higher than that of group A (P value < 0.001) **as shown in (Fig. 3).**

This study revealed that Decortication post SK injection in group B was statistically higher than that of group A either by surgical thoracotomy or VATS (P value = 0.004) **as shown in (table 4).**

Table (1): Distribution of the studied groups regarding their age and sex

		Group A (n = 30)	Group B (n = 30)	P value	Significant
Age	Mean ±SD	34 ±9	31 ±9	0.303	NS
Gender	Males n (%)	28 (93.3)	25 (83.3)	0.424	NS
	Females n (%)	2 (6.7)	5 (16.7)		

Independent t test was used for age. Fisher's exact test was used for gender (NS= Non significant).

Table (2): Distribution of the studied groups regarding to period between trauma, Streptokinase use and number of doses used.

		Group A	Group B	P value	Significant
		(n = 30)	(n = 30)		
Period between trauma & SK use	Mean ±SD	5 ±1	13 ±6	<0.001	HS
Number of doses used	Mean ±SD	3 ±1	3 ±1	0.14	NS

Independent t test was used. (HS= highly significant, NS= non-significant).

Table (3): Distribution of the studied groups regarding to CT results post Streptokinase injection.

			Group A (n = 30)	Group B (n = 30)	P value	Significant
CT post SK	CR	n (%)	18 (60.0)	4 (13.3)	0.001	HS
	PR	n (%)	5 (16.7)	11 (36.7)		
	NR	n (%)	7 (23.3)	15 (50.0)		

Chi-square test was used. (HS= highly significant) (CT= computerized tomography)

(CR= complete response, PR= partial response, NR= no response)

Table (4): Distribution of the studied groups regarding to surgical intervention post Streptokinase injection.

			Group A	Group B	P value	Significant
			(n = 30)	(n = 30)		
Surgical intervention	Decortication	n (%)	5 (16.7)	15 (50.0)	0.004	HS
	Thoracotomy	n (%)	4(13.3)	13 (43.3)	0.005	HS
	VATS	n (%)	1 (3.3)	2 (6.7)	0.15	NS

Chi-square or Fisher's exact test was used. (HS= highly significant, NS= non-significant, VATS= video assisted thoracoscopic surgery).

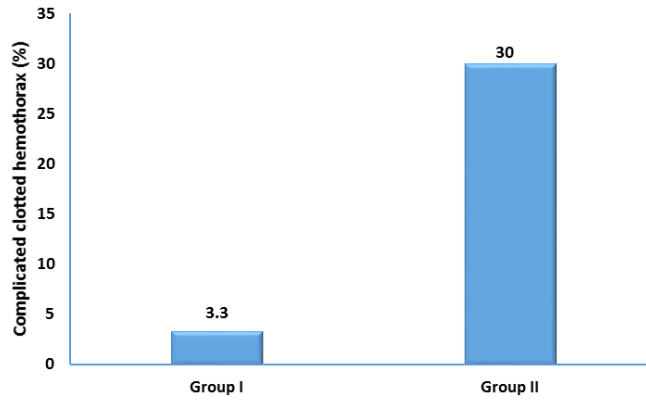


Fig (1): shows the incidence of complicated clotted hemothorax in both groups.

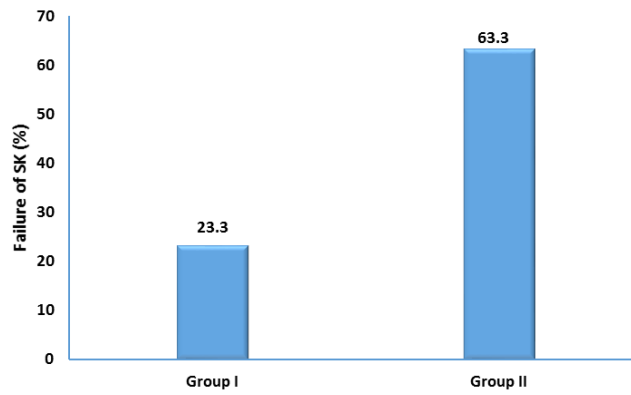


Fig (2): shows the failure of SK injection in both groups.

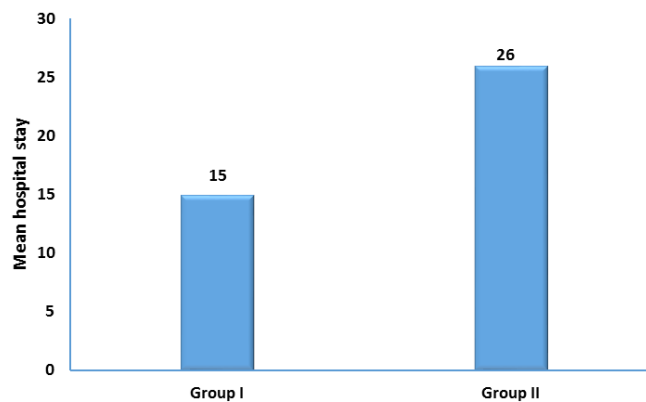


Fig (3): shows the total hospital stay post Streptokinase injection in both groups.

Discussion

Thommiet al., had reported that the effect of treatment with IPFT vary within the 1st week and the 2nd week post traumatic hemothorax. Most cases in our study, treatment with intra pleural fibrinolytic therapy (IPFT) in the 1st week lead to complete resolution through evacuation of blood clots and loculated effusion. ⁽⁸⁾

Although, the use of IPFT generally causes no systemic coagulation effects, Tierney et al., had reported that there was a single case of a major hemorrhage following intrapleural streptokinase injection after 2 weeks post trauma attributed with systemic side effects such as arthralgia, nausea, malaise, headache and fever, but this was against our study. ⁽⁹⁾

Tomaselli et al., had reported that there was a highly significant difference in the total amount of ICT drainage and period between trauma and SK injection. During the 2nd week of post trauma there was larger amount of ICT drainage than the 1st week of post trauma and this was similar to our study. ⁽¹⁰⁾

Battistella and Benfield had reported that post traumatic clotted hemothorax should be evacuated within a week after injury to

avoid the complication of fibrinothorax and empyema. Therefore, SK instillation in ICT is better to be given within 1st week than 2nd week and this was similar to our study. ⁽¹¹⁾

Kimbrell et al., had reported the effectiveness of intra pleural streptokinase instillation during the 1st week of post traumatic clotted hemothorax which played an important role in minimizing the needs to decortication either by open thoracotomy or VATS and this was similar to our study. ⁽¹²⁾

Oguzkaya et al., had reported highly statistically differences for the length of hospital stay and number of thoracotomies when intra pleural streptokinase injected within one week or two weeks post trauma. For sure SK injection during 1st week post trauma had been given the excellent results and this was similar to our study. ⁽¹³⁾

However, Smith et al., reported that VATs was more effective and safe method in management of clotted hemothorax than IP SK injection especially after 2weeks post trauma and this was against of our study. ⁽¹⁴⁾

Conclusions

This study showed that intrapleural streptokinase injection could be an ideal

option for post-traumatic clotted hemothorax before the decision is made to proceed to VATS or open surgical techniques especially when administered early in the 1st 7 days post trauma.

References

- 1- Morley EJ, Johnson S, Leibner E, Shahid J. Emergency department evaluation and management of blunt chest and lung trauma. *Emerg Med pract*,2016;18(6):1-20
- 2- Ota K, Fumimoto S, Lida R, Nakamura R, Inage Y, Tobita R, et al. Massive hemothorax due to two bleeding sources with minor injury mechanism: a case report. *J Med case Rep*,2018;12(1):291
- 3- Han GM, Newmyer A, Qu M. seatbelt use to save money: impact on hospital costs occupants who are involved in motor vehicle crashes. *Int Emerg Nurs*.2017; 31:2-8.
- 4- Carver DA, Bressan AK, Schieman C, Grondin SC, Kirkpatrick AW, Lall R, et al. Management of hemothoraces in blunt thoracic trauma: study protocol for randomized controlled trial. *BMJ open*.2018;8(3):203-78
- 5- DuBose J, Inaba K, Okoye O, Teixeira PG, Pepe A, Dunham MB, et al. Development of posttraumatic empyema in patients with retained hemothorax: results of a prospective, observational AAST study. *J Trauma Acute Care Surg*. 2012; 73(3): 752-7.
- 6- Soni NJ, Franko R, Velez MI, Schnobrich D, Dancel R, Restrepo MI, et al. Ultrasound in diagnosis and management of pleural effusions. *J Hosp Med*.2015; 10(12)811-6.
- 7- Chiumello D, Umbrello M, Sferazza Papa GF, Angileri A, Gurgitano M, Formenti P, et al. Global and Regional Diagnostic Accuracy of Lung Ultrasound Compared to CT in Patients with Acute Respiratory Distress Syndrome. *Crit Care Med*, 2019; 47:1599.
- 8- Thommi G, Nair CK, Aronow WS, Shehan C, Meyers P, McLeay M. Efficacy and safety of intrapleural instillation of alteplase in the management of complicated pleural effusion or empyema. *Am J Ther* .2007; 14(4):341-345.
- 9- Tierney DM, Huelster JS, Overgaard JD, Plunkett MB, Boland LL, St Hill CA, et al. Comparative Performance of Pulmonary Ultrasound, Chest Radiograph, and CT Among Patients with Acute Respiratory Failure. *Crit Care Med* 2020; 48:151.
- 10-Tomaselli F, Maier A, Renner H, Smolle-Ju'ttner FM. Thoracoscopic water jet lavage in coagulated hemothorax, *Eur J Cardiothorac Surg*. 2003;23: 424-425.
- 11-J Battistella FD, Benfield JR. Blunt and penetrating injuries of the chest wall, pleura and lungs. In: Shields TW, LoCicero III, Ponn RB, editors, *General thoracic surgery*, 5th ed. Philadelphia, Lippincott Williams and Wilkins. 2000; 815-831.
- 12-Kimbrell BJ, Yamzon J, Petrone P, Asensio JA, Velmahos GC. Intrapleural thrombolysis for the management of undrained traumatic hemothorax: a prospective observational study. *J Trauma*. 2007; 62(5): 1175-8:1178-9.
- 13-Oguzkaya, F., Akcali Y, Bilgin M. Video thoracoscopy versus intrapleural streptokinase for management of post traumatic retained

hemothorax: a retrospective study of 65 cases.
Injury. 2005; 36: 526-9.

14-Smith, J.W. Fong-Dee Huang, Wen-Bin Yeh, Sheng-Shih Chen, Yuan-Yuarn Liu, Yin Lu, et al. Early VATS for blunt chest trauma: a management technique underutilized by acute care surgeons. J Trauma, 2011; 71(1): 102-5.

To cite this article: Mohammed A. Elgazzar, Hany M. AlRakhawy, Noha A. Nabeih, Ashraf M. Elnahas, Mahmoud A. ElShafiey. Efficacy of intra Pleural streptokinase injection in Post traumatic Clotted Hemothorax. BMFJ2022;39(2):409-417. DOI: 10.21608/bmfj.2022.37822.1299