



A Novel Protocol For CBCT 3D Volume Rendering Noise and Artifacts Reduction In Cases of Impacted Mandibular Third Molars

Ali Fahd^{1*}, Abdel Aziz Baiomy Abdullah^{*2}, Mohamed T. Ellabban³, Sarah Mohammed Kenawy⁴

Codex : 09/2022/04

Aadj@azhar.edu.eg

KEYWORDS

CBCT, 3D model, artifacts,
impacted mandibular third molars,
DICOM.

1. Department of Diagnostic Science and Oral & Maxillofacial Radiology, Faculty of Dentistry, Sinai University, Kantara, Egypt
2. Department of Oral and maxillofacial surgery, Faculty of Dental Medicine, Al-Azhar University, Assuit, Egypt.
3. Department of Orthodontics and Dentofacial Orthopedics, Faculty of Dentistry, Assiut University, Assiut, Egypt
4. Department of Oral and Maxillofacial Radiology, Faculty of Dentistry, Cairo University, Egypt.

* Corresponding Author e-mail:
abdellazizbaiomy@azhar.edu.eg

ABSTRACT

Aim: This study was carried out to introduce and evaluate a fast, simple user-friendly protocol for improving the quality of CBCT based 3D volume and producing a 3D model that can be used effectively in multiple dental applications **Subjects and methods:** 40 DICOM files of small field of view (FOV) for patients with impacted lower third molars were used in the present study. The 3D Volume style was changed into black and white with modification in contrast and transparency then “clean rendering tool” was used before returning to the default style. Volume quality was recorded before and after applying the proposed protocol and was compared for data matching with the corresponding axial, reformatted panoramic and cross-sectional images. Moreover, a survey for dentists was collected regarding the ease of application, satisfaction with the modified volume and suggested applications. **Results:** The results showed that all the tested volumes were improved with reduced noise and artifacts. **Conclusion:** the proposed protocol was successful and easy to use. The improved volume was suggested to be used for the patient communication, surgical planning, dental education and furthermore applications.

Introduction

Cone beam computed tomography (CBCT) is now considered as a cornerstone in oral and maxillofacial radiology for providing low radiation dose to the patients and cost effective clinically important data⁽¹⁾. CBCT based 3D volume rendering is used in diagnostic and treatment planning tasks as in maxillofacial surgery, dental implantology and orthodontics⁽²⁻⁴⁾. Besides to its rule in comparative follow up for morphological, dimensional and positional changes analysis⁽⁵⁾. Moreover, it is an essential tool for the analysis of facial deformities and asymmetries⁽⁶⁾.

High quality noise free images are not only essential for clinical intervention but also for academic teaching and effective patient communication that have a direct effect on the level of health care quality and patient commitment while low quality images are considered barriers for effective patient communication ^(7,8).

Volume rendering is initially done automatically and can also be done or modified manually⁽⁹⁾. Manual segmentation may be considered as the gold standard for volume rendering but it is a very time consuming and technique sensitive procedure^(9,10), thus finding an alternative is an important research attractive topic. The accuracy of volume rendering is affected by multiple factors as artifacts and noise⁽¹⁰⁾. CBCT is associated with more noise than multi-slice computed tomography (MSCT) and many approaches were introduced to overcome this problem⁽¹⁰⁻¹²⁾.

In this respect, the aim of the present study was to introduce and evaluate a simple protocol for improving the quality of CBCT dental 3D volume rendering based on surface cleaning tool to overcome the effect of artifacts and noise found in the automatic default 3D volume rendering.

MATERIALS AND METHODS

40 retrieved DICOM files of impacted lower third molars were included in the present study. CBCT imaging was acquired by Planmeca® system (Promax 3D Classic, Helsinki, Finland) with operating parameters: 90 kV, 6 mA, and a voxel size of 0.2 mm. The used software was Planmeca Romexis® 5.3.

Inclusion criteria:

1. Quadrant or segment imaged FOV
2. Separated upper and lower arches
3. Clearly displayed impacted lower third molar in the FOV
4. Presence of noise and artifacts in the default 3D volume
5. Occurrence of data loss and false bone fenestrations when threshold adjustment for noise correction was applied

The default 3D x-ray shaded rendering volumes were evaluated and images were captured from different views for later comparison (figure 1A).

3D Volume style was changed into black and white style then rendering transparency was adjusted to level ten while the rendering contrast was decreased to zero (figure 1B). Using the clean rendering tool, the outer noise and artifact space was cleaned by moving the active tool near the remaining volume of interest (VOI) without touching the outer surface of the volume. A large tool size was used for initial massive cleaning (figure 1C), followed by a small tool size for fine tuning (figure 1C). This cleaning method was performed from different perspectives as buccal, lingual, occlusal, and oblique views (figure 1C). After finishing, 3D rendering was changed back to the default X-ray shaded style (figure 1D). Quality scores were recorded and compared.

The proposed protocol was performed by two operators who applied it together to the present study samples and another two operators together observed and evaluated the results. The observers could rotate and zoom the 3D volume for improving the visibility of any needed anatomy but were not allowed to adjust the threshold, density, contrast, or transparency. The observers scored the quality of the volume and the data matching with the corresponding slice images from the implant modules (axial, cross section, and reformatted panoramic images) with reference color coded plane shown in the 3D volume (figure 2). Five-point scale was used depending on five factors, each for one point (verified by correlation with other images):

- Bone status: no data loss or erroneous dehiscence or noised surface
- Teeth surfaces: clear occlusal topography and detection of coronal destruction if present
- Alveolar crest level: true crestal bone level
- Impaction status: showing information helpful in treatment planning
- Overall volume quality: the view was good enough to show information to patients or for medical education



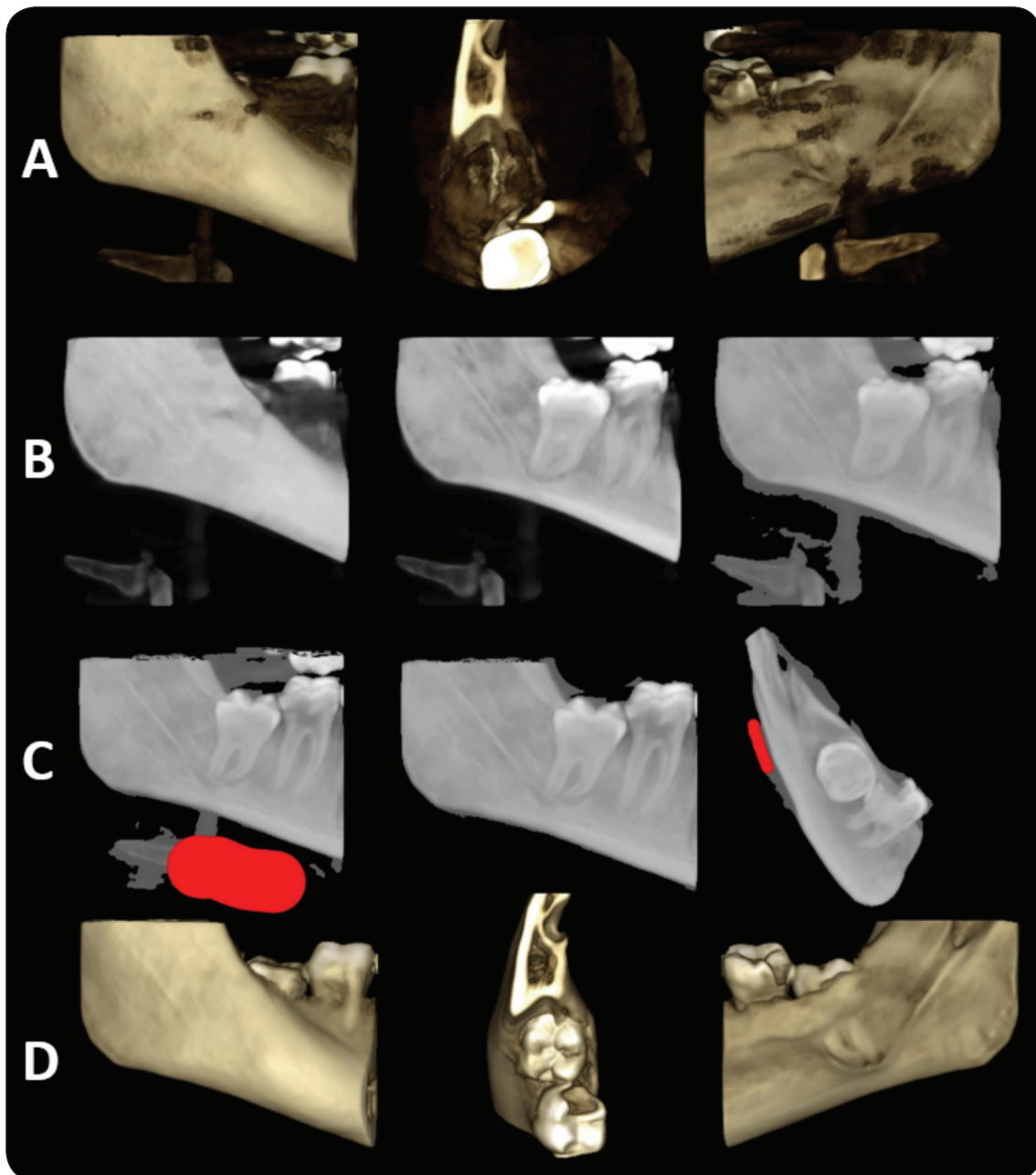


Fig. (1) (A) 3D default volume before protocol application from buccal (left), occlusal (middle) and lingual (right). (B) Black and white style (left), volume after increasing transparency (middle) and volume after decreasing contrast (right). (C) Active large cleaning tool (left), the result after initial cleaning (middle), and active small tool applied on another perspective (right). (D) 3D volume after cleaning. Note the clear surface topography (middle) that can be used in registration procedures.

A survey for dentists was collected during a scientific meeting. The survey was composed of three parts; the first part was asking about the ease of application of the protocol using 1 to 10 scale where 1 was “very easy” and 10 was “very difficult”. The second part evaluated the satisfaction

with the improved volume using a satisfaction scale from 1 to 10 where 10 was “totally satisfied” and 1 was “totally dissatisfied”. Finally, the third part was inquiring if the dentists recommend the new model to be included as a routine view for each case and why (suggested uses).

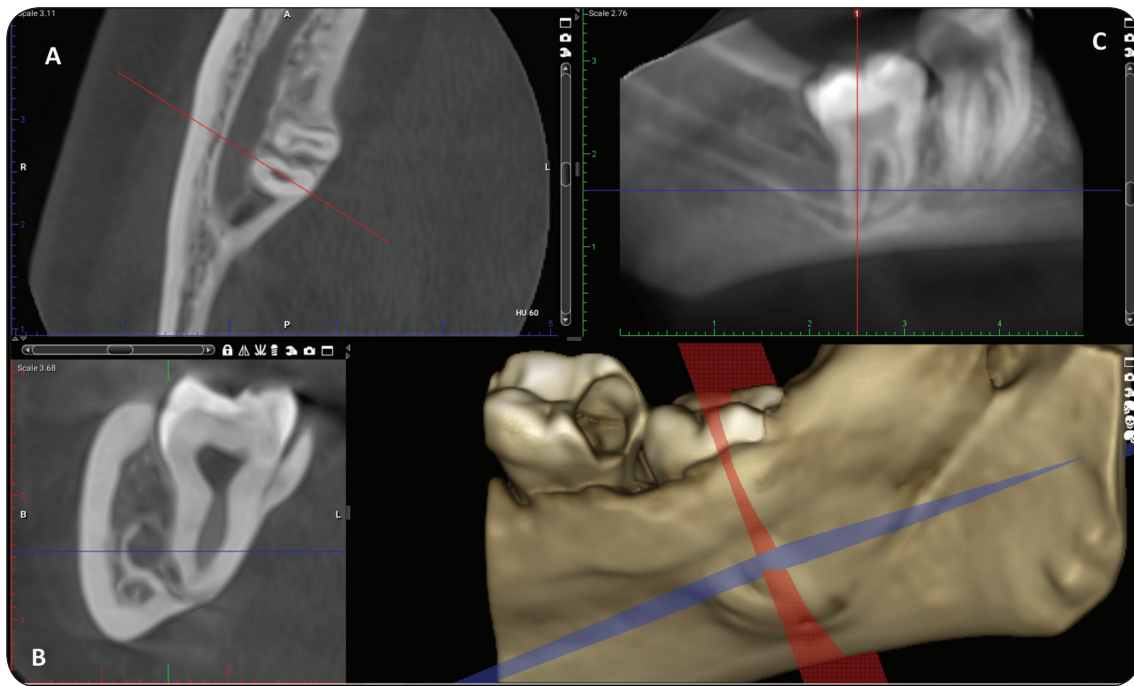


Fig. (2) 3D volume after cleaning with reference planes for verification and correlation with axial (A), cross section (B), and reformatted panoramic (C) images. Note the clear coronal decay in second molar that can be used for patient motivation, the bone covering the distal part of impaction and the lingual root bulging with bone thinning that can be used in dental education and treatment planning.

Data in the present study were presented as mean, standard deviation (S.D.) and Confidence Interval (C.I.) values. For Descriptive data, results were presented as median, standard deviation (S.D.), Confidence Interval (C.I.) values and percentage. Wilcoxon signed-rank test was used to evaluate the quality difference before and after applying the protocol. The significance level was set at $P \leq 0.05$. Statistical analysis was performed with IBM SPSS Statistics Version 22 for Windows.

RESULTS

The overall image noise was managed in all cases of the present study. The cleaned 3D volume showed important data that can be used for multiple purposes.

Descriptive findings:

- Complete and enough upper and lower arch separation is essential to segment the needed

arch from the opposing and any touching points can lead to altered data and errors in occlusal topography.

- Volume after modification showed clear teeth occlusal topography that may be of benefit for cast model registration (figure 1).
- During application, after adjusting transparency, remaining roots were easily detected.

Statistical findings:

Results of Shapiro-Wilk tests showed that the data was not normally distributed so non-parametric Wilcoxon signed-rank was used to evaluate the quality difference before and after applying the cleaning protocol while median was used for the descriptive data.

The statistical test of the data showed that the quality scores were significantly increased after applying the protocol (table 1).



Table (1) Results of Wilcoxon signed-rank test for the quality difference before and after applying the cleaning protocol.

| Parameter | Time points | Mean | S.D. | Mean diff. | S.D. | 95% CI | | Z | P value |
|-----------|-------------|------|------|------------|------|--------|-------|-------|---------|
| | | | | | | Lower | Upper | | |
| Lower jaw | Before | 2.0 | 0.64 | 2.7 | 0.46 | 2.55 | 2.84 | -5.77 | 0.00* |
| | After | 4.7 | 0.46 | | | | | | |

* Significant at $P \leq 0.05$

The number of dentists who participated in the survey was 53. Survey results showed that regarding ease of application the median was 2 (easy) while for satisfaction score it was 10 (totally satisfied) (table 2). They recommended the new model to be included as a routine view for each impaction case and they provided suggested applications. The main suggested applications were categorized as effective patient communication (96%), surgical planning (75%) and medical education (17%). Other applications (less than 10%) were models' manipulation, marketing, digital dentistry, and the use of the same protocol in other cases like implant planning, surgical guide procedures and periodontal diseases.

Table (2) Descriptive statistics of survey regarding ease of application and satisfaction score

| Parameters | Median | S.D. | 95% CI | |
|---------------------|--------|------|--------|-------|
| | | | Lower | Upper |
| Ease of application | 2 | 1.60 | 1.43 | 2.31 |
| Satisfaction score | 10 | 1.41 | 9.12 | 9.90 |

DISCUSSION

CBCT is widely used in dentistry by radiology specialists and non-specialists. Many attempts have been made to ease its use and make it a non-technique sensitive⁽¹³⁾. Unfortunately, some application protocols such as manual segmentation, are not specifically designed for non-specialists and involve complex time-consuming procedures, also require special software to be performed⁽¹³⁾. Thus,

the present study aimed to introduce and evaluate a user-friendly protocol for improving the quality of 3D volume rendering.

The quality of 3D volume rendering is very significant for the diagnosis, treatment planning, outcome evaluation and 3D printing applications^(2,6,11,14). Additionally, 3D reconstruction is important for patient communication and more than two thirds of USA dentists implement radiographic images as a way to communicate with their patients⁽¹⁵⁾. The proposed protocol produced a reliable high-quality 3D reconstruction that can be used for multiple applications and in effective patient communication.

Manual slice by slice segmentation and threshold adjustment may be an accurate methodology for producing high quality volumes, however the technique is sensitive and time-consuming. Therefore, alternative solutions should be found⁽¹⁶⁻¹⁹⁾. In the present study, fast and simple technique was proposed for this mission and the results of dentist survey showed that the protocol was easy for them and they were satisfied with the enhanced volume.

Dentists can benefit from 3D volume rendering using inexpensive available personal computer based software which expands the merits of the CBCT technology⁽²⁰⁾. This work was done using Planmeca romexis software that is readily available without additional cost and can be used on personal computers.

The accuracy of volume rendering is affected by multiple factors as voxel size, FOV, artifacts and the beam inhomogeneity of CBCT scanners⁽¹⁰⁾.

A point of strength in the present study is the standardization where all images were taken by the same machine and same parameters so that any variations can be excluded. The used small FOV had the benefits of not only improving image quality but also reducing the radiation dose. Also, small FOV allowed easy manipulation of the volume to be cleaned from different perspectives without affection of other parts of the scan.

In the same context, mandibular impactions were the choice rather than the maxillary ones because of many factors as the lesser maxillary bone density and the variations in bone thickness and shape of the maxilla in addition to the presence of an air-filled structures like maxillary sinuses making the 3D volume manipulation more difficult ^(4, 10). Fortunately, the 3D volume rendering of the lower jaw has a broad range of clinical applications, as in orthodontics and maxillofacial surgeries ^(21, 22).

An important recommendation is to compare the effect of this protocol on the accuracy of other dependent or related further applications as an approach for verification of its accuracy and reliability.

CONCLUSION

The introduced new protocol improved the quality of CBCT dental 3D volume by minimizing any artifacts or noises. Moreover, most of dentists involved in the survey were greatly satisfied from this quality improvement and found that the protocol was very easy to apply. The introduced protocol is promising, and further studies are needed to study the suggested uses as patient communication, dental education, and surgical planning and to evaluate the work accuracy when used in other further procedures like registrations. Finally, the findings of the present study may have important implications if a reconstruction algorithm can be applied to reconstruct other slices without the removed artifacts which is an important point of recommendation for researchers working on artificial intelligence.

REFERENCES

1. Iskanderani D, Nilsson M, Alstergren P, Shi X-Q, Hellen-Halme K. Evaluation of a low-dose protocol for cone beam computed tomography of the temporomandibular joint. *Dentomaxillofacial Radiology*. 2020;49(6):20190495.
2. Almqarami B-S, Alhammadi M-S, Cao B. Three dimensional reliability analyses of currently used methods for assessment of sagittal jaw discrepancy. *Journal of clinical experimental dentistry*. 2018;10(4):e352.
3. Pelo S, Correria P, Gasparini G, Marianetti TM, Cervelli D, Grippaudo C, et al. Three-dimensional analysis and treatment planning of hemimandibular hyperplasia. *Journal of Craniofacial Surgery*. 2011;22(6):2227-34.
4. Fourie Z, Damstra J, Schepers RH, Gerrits PO, Ren Y. Segmentation process significantly influences the accuracy of 3D surface models derived from cone beam computed tomography. *European journal of radiology*. 2012;81(4):e524-e30.
5. Leonardi R, Muraglie S, Lo Giudice A, Aboulazm K, Nucera R. Evaluation of mandibular symmetry and morphology in adult patients with unilateral posterior crossbite: a CBCT study using a surface-to-surface matching technique. *European journal of orthodontics*. 2020;42(6):650-7.
6. Muraglie S, Leonardi R, Aboulazm K, Stumpo C, Loreto C, Grippaudo C. Evaluation of structural skeletal asymmetry of the glenoid fossa in adult patients with unilateral posterior crossbite using surface-to-surface matching on CBCT images. *The Angle Orthodontist*. 2020;90(3):376-82.
7. Tseng W, Pleasants E, Ivey SL, Sokal-Gutierrez K, Kumar J, Hoeft KS, et al. Barriers and Facilitators to Promoting Oral Health Literacy and Patient Communication among Dental Providers in California. *International journal of environmental research public health*. 2021;18(1):216.
8. Tamura-Lis W. Teach-Back for quality education and patient safety. *Urologic nursing*. 2013;33(6).
9. Fastuca R, Lorusso P, Lagravère MO, Michelotti A, Portelli M, Zecca PA, et al. Digital evaluation of nasal changes induced by rapid maxillary expansion with different anchorage and appliance design. *BMC Oral Health*. 2017;17(1):1-7.
10. Engelbrecht WP, Fourie Z, Damstra J, Gerrits PO, Ren Y. The influence of the segmentation process on 3D measurements from cone beam computed tomography-derived surface models. *Clinical oral investigations*. 2013;17(8):1919-27.



11. Lo Giudice A, Ronsivalle V, Grippaudo C, Lucchese A, Muraglie S, Lagravère MO, et al. One step before 3D printing Evaluation of imaging software accuracy for 3-dimensional analysis of the mandible: A comparative study using a surface-to-surface matching technique. *Materials*. 2020;13(12):2798.
12. Nicolielo LFP, Van Dessel J, Shaheen E, Letelier C, Codari M, Politis C, et al. Validation of a novel imaging approach using multi-slice CT and cone-beam CT to follow-up on condylar remodeling after bimaxillary surgery. *International journal of oral science*. 2017;9(3):139-44.
13. Li C, Lin L, Zheng Z, Chung C-H. A User-Friendly Protocol for Mandibular Segmentation of CBCT Images for Superimposition and Internal Structure Analysis. *Journal of Clinical Medicine*. 2021;10(1):127.
14. Nucera R, Lo Giudice A, Bellocchio M, Spinuzza P, Caprioglio A, Cordasco G. Diagnostic concordance between skeletal cephalometrics, radiograph-based soft-tissue cephalometrics, and photograph-based soft-tissue cephalometrics. *European journal of orthodontics*. 2017;39(4):352-7.
15. Rozier RG, Horowitz AM, Podschun G. Dentist-patient communication techniques used in the United States: the results of a national survey. *The Journal of the American Dental Association*. 2011;142(5):518-30.
16. Wang L, Chen KC, Gao Y, Shi F, Liao S, Li G, et al. Automated bone segmentation from dental CBCT images using patch-based sparse representation and convex optimization. *Medical physics*. 2014;41(4):043503.
17. Gkantidis N, Schauseil M, Pazera P, Zorkun B, Katsaros C, Ludwig B. Evaluation of 3-dimensional superimposition techniques on various skeletal structures of the head using surface models. *PloS one*. 2015;10(2):e0118810.
18. Halazonetis D. From 2-dimensional cephalograms to 3-dimensional computed tomography scans. *American Journal of Orthodontics Dentofacial Orthopedics*. 2005;127(5):627-37.
19. Friedli L, Kloukos D, Kanavakis G, Halazonetis D, Gkantidis N. The effect of threshold level on bone segmentation of cranial base structures from CT and CBCT images. *Scientific reports*. 2020;10(1):1-11.
20. Scarfe WC, Farman AG, Sukovic P. Clinical applications of cone-beam computed tomography in dental practice. *Journal-Canadian Dental Association*. 2006;72(1):75.
21. Nucera R, Lo Giudice A, Bellocchio AM, Spinuzza P, Caprioglio A, Perillo L, et al. Bone and cortical bone thickness of mandibular buccal shelf for mini-screw insertion in adults. *The Angle orthodontist*. 2017;87(5):745-51.
22. Guerrero ME, Jacobs R, Loubele M, Schutyser F, Suetens P, van Steenberghe D. State-of-the-art on cone beam CT imaging for preoperative planning of implant placement. *Clinical oral investigations*. 2006;10(1):1-7.



طريقة مبتكرة لتقليل تشوهات المجسم ثلاثي الأبعاد الناتج عن تصوير الأشعة المقطعية مخروطية الشعاع في حالات ضروس العقل السفلية المطمورة

علي فهد¹, عبدالعزيز بيومي عبدالله^{2*}, محمد طه اللبان³, سارة محمد قناوي⁴

1. قسم علم التشخيص وأشعة الفم والوجه والفكين, كلية طب الأسنان, جامعة سيناء, القنطرة, مصر
 2. قسم جراحة الفم والوجه والفكين, كلية طب الأسنان, جامعة الأزهر, أسيوط, مصر
 3. قسم تقويم الأسنان, كلية طب الأسنان جامعة أسيوط, أسيوط, مصر
 4. قسم أشعة الفم والوجه والفكين, كلية طب الأسنان, جامعة القاهرة, القاهرة, مصر
- * ABDELAZIZBAIOMY@AZHAR.EDU.EG البريد الإلكتروني:

الملخص:

الهدف: من هذه الدراسة هو تقديم وتقييم طريقة سريعة ومبسطة لتحسين جودة المجسم ثلاثي الأبعاد الناتج عن تصوير الأشعة المقطعية مخروطية الشعاع وتخويله الى نموذج يمكن استخدامه في التواصل مع المرضى وفي التعليم الطبي ووضع الخطة العلاجية.

المواد والأساليب: اشتملت الدراسة على مستخرج ملفات أشعة رقمية ثلاثية الأبعاد لعدد عشرين حالة مشخصة بوجود ضروس عقل مطمورة تم تصويرهم بمجال التصوير الصغير. غير نوع النموذج القياسي الى النموذج الأبيض والأسود والذي تم التلاعب في درجة شفافيته وتباينه واستخدام أداة التنظيف قبل ارجاع النموذج الى صورته الأولى. تم مقارنة جودة الصورة قبل وبعد استخدام الطريقة المقترحة ومقارنة المعلومات المستخرجة من المنتج النهائي مع الصور القياسية.

النتائج: أظهرت نتائج الدراسة أن هناك فروق ذات دلالة إحصائية فيما يتعلق بالتقييم الإشعاعي في مجموعة الدراسة. الخلاصة: تدل النتائج على نجاح الطريقة في تحسين جودة النموذج ثلاثي الأبعاد وتقليل تشوّهاته وبالتالي يمكن استخدامه في الأغراض المستهدفة.

الكلمات المفتاحية: الأشعة المقطعية المخروطية, نموذج ثلاثي الأبعاد, تشوهات, ضرس عقل السفلى مدفون, افلام ادبكوم.