

Significance of Cluster of Differentiation 10 (CD10) and Cyclooxygenase-2 (COX-2) in Differentiation between Keratoacanthoma and Squamous Cell Carcinoma: An Immunohistochemical Study

ZEINAB I. ELSHAWARBY, M.D. and NAGLAA H. SHALAN, M.D.

The Department of Pathology, Faculty of Medicine, Benha University, Qalioubia

Abstract

Background: Keratoacanthoma (KA) is a common, unique benign keratinocytic neoplasm, that mostly develops within 6-8 weeks, with spontaneous regression after 3-6 months and shares features with squamous cell carcinomas (SCCs). It is critical to recognize these neoplasms since they exhibit markedly distinct clinical characteristics. There are no criteria that are sensitive enough to discriminate reliably between KA and SCC. The purpose of this research is to determine the possible role of COX2 and CD10 in the distinction of KA and SCC.

Material and Methods: This is a retrospective, controlled, selected study conducted on paraffin blocks including: 20 cases of squamous cell carcinoma, Twelve cases of keratoacanthoma and five cases of normal skin tissue as control from plastic surgery. Cases were retrieved from the histopathologic archives of the Pathology Department, Faculty of Medicine, Benha University, between 2016 and 2019. Immunohistochemical staining for CD10 and COX2 was performed and the pattern of expression was examined, analyzed, correlated with clinicopathologic data and statistically studied.

Results: Expression of CD10 was almost absent in the stromal component of KA cases (91.7%) while its expression in the stromal component of SCC was in all cases (100%) with statistically highly significant difference ($p < 0.001$). Expression of COX2 was within 50% of KA cases while in SCC, it was expressed in 95% examined cases with a significant statistical correlation ($p < 0.005$).

Conclusion: The current research shown that CD10 and COX-2 may be useful in differentiating keratoacanthomas from squamous cell carcinoma.

Key Words: CD10 – COX-2 – KA – SCC – Immunohistochemistry.

Introduction

KERATOACANTHOMA (KA), also known as molluscum sebaceum, is a quickly developing and locally damaging tumour on hair-bearing skin [1].

Correspondence to: Dr. Zeinab I. Elshawarby, The Department of Pathology, Faculty of Medicine, Benha University, Qalioubia

However, it is presently believed that they originate from the pilosebaceous unit. Although not an epidermal tumour, KA has numerous histological characteristics with squamous cell carcinoma (SCC). It is also a precancerous lesion, with a 3.6-13.9 percent chance of becoming SCC depending on age group [2]. Thus, distinguishing KA from SCC is a diagnostic challenge [3]. The expression of immune-histochemical markers and/or gene expression is used to distinguish it from regressive squamous cell carcinoma [4].

Nodules with keratin plugs and crater-like shapes which appear firm and reddish in color are often the presentation of keratoacanthoma (KA), which usually resolves spontaneously. The frequency of keratoacanthoma seems to be greater in whites, compared to Asians and dark-skinned people, and very uncommon in children [5].

Cutaneous squamous cell carcinoma (SCC) is an epidermal keratinocyte derived skin tumor, which considered as one of the most malignant cancers worldwide having a significant risk of metastasis and eventually ends with death [6].

Histopathological differentiation between (KA) and (SCC) is difficult. It is occasionally impossible to distinguish between these lesions by histopathological and clinical examination, especially in small biopsy specimens [7]. Therefore, many immunohistochemical markers have been studied to overcome this dilemma.

CD 10, or neutral endopeptidase (NEP), is a 90-110 kDa integral membrane protein found on the cell surface of type II cells. It is expressed in immature lymphoid progenitor stages, suggesting

that it has a possible role in lymphoid cell formation and differentiation. Because it was first discovered on acute lymphoblastic leukaemia cells, it was given the name common acute lymphoblastic leukaemia antigen (CALLA) [8] and expressed in a wide range of cells, including the prostate, the adrenal glands, the gut, the endometrium of the kidney, and the lung [9]. CD 10 immunopositivity has been found in the hair matrix, the inner sheath of hair follicles, and the perifollicular fibrous sheath of normal adult skin. CD10 is expressed in dermatofibrosarcoma protuberans and melanoma

[10].

COX is a housekeeping enzyme that catalyses the conversion of free arachidonic acid to prostaglandins. It has two isoforms known as COX-1 and COX-2. COX-1 is found in most normal tissues and is required for normal physiological function [11]. COX-2 is expressed in only with pathological conditions as oncogene activation and hypoxia, but it is not detected under normal conditions. COX-2 is expressed in many neoplastic processes through activation of cell division, angiogenesis, and inhibition of apoptosis [12].

Aim of the work: This study aimed at investigating the role of CD 10 and COX2 in differentiation between KA and SCC.

Table (1): The antibodies used in the current study.

Antibody	Source	Cat No	Dilution	Incubation period	Positive control
CD10	USA, Neo-Markers	MS-363-R7	Ready to use	90min.	Normal intestinal epithelium
COX2	USA, Neo-Markers	RB-9072-R7	Ready to use	60min.	Colorectal carcinoma

Immunohistochemistry interpretation:

CD10 positivity was considered as brown cytoplasmic and/or membrane staining. Each case was examined with 40 high power fields (x400) and mean percentage of positive cells were calculated according to Sivrikoz et al., [11].

COX2 positivity was considered as brown cytoplasmic staining. The extent of immunoreactivity was graded and scored according to Putti et al., [15].

Statistical study:

SPSS Statistics version 16.0.1 was used for statistical analysis (SPSS Inc., Chicago, Illinois, USA). The variables' descriptive analysis and the statistical significance of the tests were reported in *p*-values. A correlation with a *p*-value less than

Material and Methods

This is a retrospective controlled study carried upon formalin-fixed, paraffin blocks including: 20 SCC cases, 12 KA cases, and 5 normal skin cases acquired following cosmetic surgery. Cases were retrieved from histopathologic archives of files of Pathology Department, Faculty of Medicine, Benha University in the period 2016-2019. Hematoxylin and Eosin sections were reviewed with consideration to histopathological criteria to confirm diagnosis Ackerman et al., [13] and Cribier et al., [14].

Immunohistochemical staining: Four μ m thickness sections were placed on positively-charged slides by the standard avidinbiotin complex (ABC) procedure according to manufacturer's data in the Ultra Vision Detection System (Anti-polyvalent, HRP/DAB, ready-to-use, Lab Vision corporation). Microwave antigen retrieval treatment was done in 1 0mM citrate buffer (Neo-Markers, Cat. # AP-9003), pH 6.0. Sections were immunostained with mouse monoclonal CD 10 and rabbit monoclonal for COX-2 as shown in Table (1). The freshly prepared DAB-substrate-chromogen solution was used and finally counterstained with Mayer's hematoxylin, dehydrated alcohols, cleared in xylene, and cover slipped. For negative controls, the primary antibody was replaced with phosphate-buffered saline.

0.05 is considered significant. Receiver Operator Characteristic (ROC) curve was carried on to determine validity of CD 10 and COX2 in diagnosis of SCC.

Results

A- Histologically KA. (Fig. 1) and SCC (Fig. 2).

Immunohistochemical results of CD10 staining:

In control normal skin, the basal layer of epidermis, inner root sheath, hair matrix, and perifollicular fibrous sheath showed positive immunostaining to CD10. Sebaceous lobules were weak positive cytoplasmic and/or membranous staining.

All cases of SCC (100%) showed CD10 immunostaining within stromal cells while it was only

expressed in 8.3% in the stromal component of KA cases. This was statistically highly significant difference ($p < 0.001$) (Fig. 4, Table 2).

Regarding the tumor cells of SCC, all cases of SCC were negative for CD10 staining while in KA cases, 16.6% of tumor cells were positive for CD 10 immunostaining within basal cell layer. This was unsignificant statistically (p -value < 0.05) (Fig. 3, Table 2).

Immunohistochemical results of COX2 staining:

In control normal skin, cytoplasmic COX2 expression was detected in epidermal keratinocytes of granular and spinous layers of the epidermis.

In KA, 6 cases (50%) out of 12 studied cases displayed cytoplasmic COX2 staining. While COX2 expression was detected in 19 cases (95%) out of 20 studied SCC cases. This was statistically significant ($p=0.005$), as described in Table (2) (Figs. 5,6). The current study showed that there was a significant statistical correlation between CXO2 and CD10 expression ($p=0.001$). Table (3).

Roc curve showed that was CD10 is more accurate than COX2 in diagnosis of SCC as AUC (0.875 and 0.742 respectively), and CD10 stromal is more specific (91.7%) than COX2 (83.3%) as shown in Table (4) and Graph (1).

Table (2): Immunohistochemical expression of CD 10 and COX2 in studied cases of KA and SCC.

	SCC (20)		KA (12)		Statistical test	p-value
	No.	%	No.	%		
COX2:						
0	1	5.0	6	50.0	FET=10.31	0.005 *
1	6	30.0	4	33.3		
2	13	65.0	2	16.7		
CD10 tumour:						
0	20	100	10	83.3	FET=3.32	0.13
1	0	0.0	1	8.3		
2	0	0.0	1	8.3		
CD10 stromal cell:						
0	0	0.0	11	91.7	FET=29.11	<0.001 **
1	9	45.0	1	8.3		
2	11	55.0	0	0		

Abbreviations:
 KA : Keratoacanthoma.
 SCC : Squamous cell carcinoma.
 * Significant.
 **Highly significant.

Table (3): The correlation between COX2 and CD10 expression in studied cases.

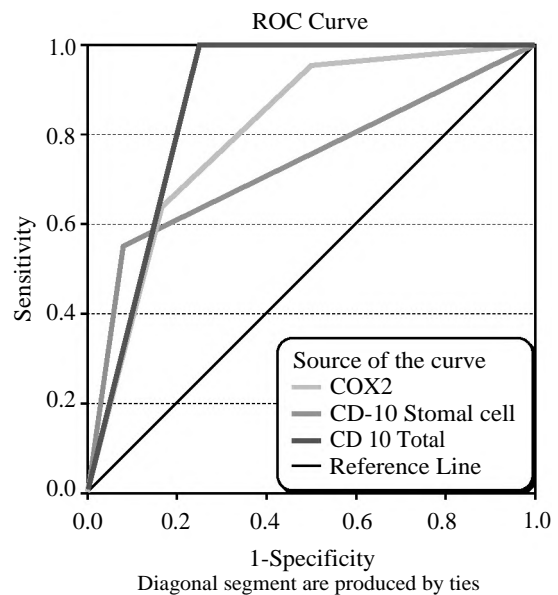
	Total	Cox2		p-value
		Negative No. (%)	Positive No. (%)	
SCC (n=20)				
CD10:				
Negative	0	0	0	<0.001 **
Positive	20	1 (5%)	19 (95%)	
Total		1	19	
KA (n=12)				
CD10:				
Negative		8 (95%)	1 (5%)	>0.05 *
Positive		1 (50%)	2 (75%)	
Total		9	3	

Abbreviations:
 KA : Keratoacanthoma. * Significant.
 SCC : Squamous cell carcinoma. **Highly significant.

Table (4): Validity of COX2 and CD10 in diagnosis of SCC in studied cases.

	COX2	CD10 Stromal cell	CD10 Total
AUC	0.742 (0.563-0.920)	0.733 (0.558-0.909)	0.875 (0.722-1.0)
Sensitivity	65.0	55.0	100
Specificity	83.3	91.7	75.0
PPV	86.7	91.7	87.0
NPV	58.8	55.0	100
Accuracy	71.9	68.8	90.6

AUC : Area Under Curve.
 PPV : Positive Predictive Value.
 NPV : Negative Predictive Value.



Graph (1): Receiver Operator Characteristic (ROC) curve for validity of CD10 & COX2 in diagnosis of SCC in studied cases.

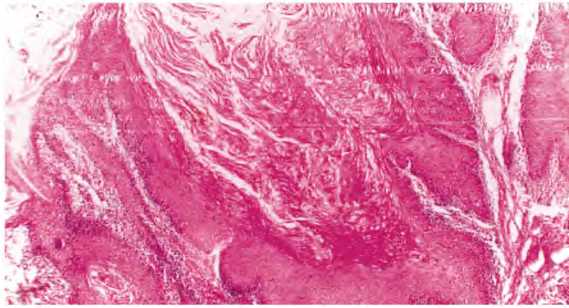


Fig. (1): A case of Keratoacanthoma, shows central crater with large, well differentiated squamous cells. (H&E X40).

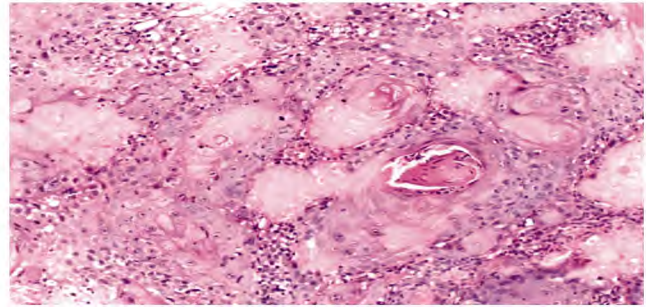


Fig. (2): A case of Squamous cell carcinoma, moderately differentiated shows nests of atypical squamous cells with keratin pearls. (H&E X100).

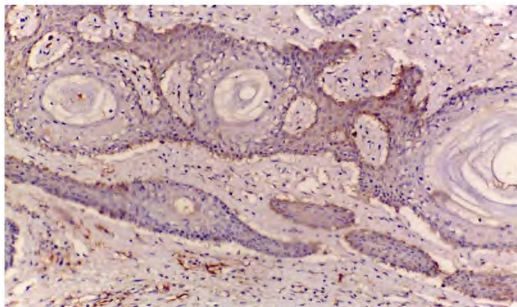


Fig. (3): A case of Keratoacanthoma with positive weak cytoplasmic CD 10 expression detected in keratinocytes at the basal layer in the periphery of the lesion while stromal cells showed weak positive cytoplasmic expression. (ABC X200).

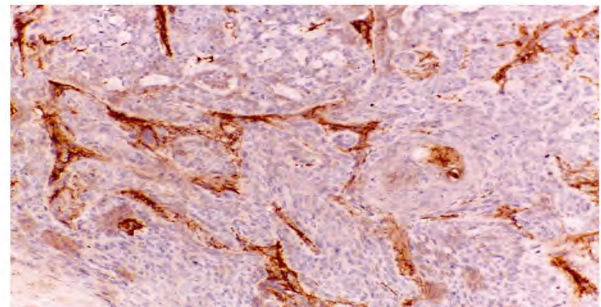


Fig. (4): A case of Squamous cell carcinoma with positive strong cytoplasmic CD10 expression in the stroma in between cell nests while tumor cells showed negative expression (ABC X200).

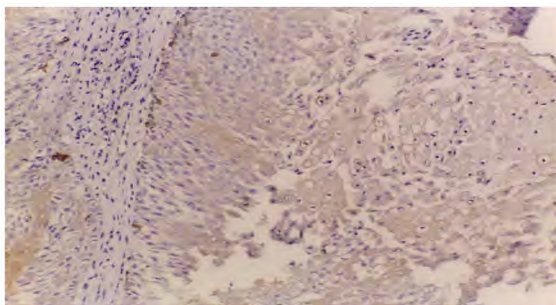


Fig. (5): A case of Keratoacanthoma with positive weak cytoplasmic Cox2 expression (ABC X200).

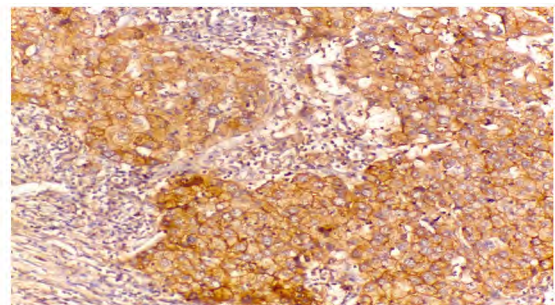


Fig. (6): A case of Squamous cell carcinoma with positive strong cytoplasmic Cox2 expression in the malignant cells (ABC X200).

Discussion

There is a debate as to whether keratoacanthoma is a separate entity or a subtype of cutaneous squamous cell carcinoma [16]. Several studies reported different histologic criteria to differentiate keratoacanthoma from squamous cell carcinoma such as Cribbier et al., [14] who determined that the differentiation between them is impossible to be based on histologic criteria alone.

No reported criteria are sensitive enough to differentiate between KA and SCC, as well as it is critical to distinct between them because of the

more metastatic potential and aggressive behavior of SCC. Consequently, there is a clinical need for discriminating markers to distinguish between the two entities; especially immunohistochemistry has become important adjunct tool in the diagnosis neoplastic skin diseases [17].

CD 10 expression in stromal cells may be a sign of tumour invasiveness, whereas its expression in tumour epithelium may be a follicular differentiation marker [18].

In the current study, CD 10 immuno positivity were detected in stromal cells of all studied SCC

cases (100%) compared to low expression of stromal component of studied KA (8.3%) with a significant statistical difference ($p < 0.001$). That supports the prevalent invasive potential of SCC compared by KA. That is similar to previous studies of skin and oral SCC [19,20].

Parallel to the current results, studies done by Aiad and Hanout [20], Heidarpour et al., [21] and Takahara et al., [22]. Reported that SCC cases showed weak to high CD 10 expression within stromal cells, while tumor cells of SCC cases failed to be stained with CD 10.

Studies of Aslani et al., [10] and Sabeti et al., [23] come in harmony with our current results as Aslani et al., [10] found that stromal CD 10 positivity was present in all SCC patients, with high expression in 70% of cases and Sabeti et al., [23] registered that 71% of his SCC patients had a positive expression in stromal cells and just 11.8% of SCC cases demonstrated weak localised positivity within tumour cells.

In contrast, Wagoner et al., [24] study reported negative CD 10 expression within tumor cells in all invasive SCCs and weak CD10 expression in the stromal cells surrounding two of thirteen SCCs. This dispute may be a result of the use of various antibody clones and immunostaining methods.

It has been reported that COX-2 expression in normal skin may be undetectable [25] or just detectable in some cells in the granular and spinous epidermal layers [26] or confined to the epidermal basal layer [27]. Nijsten et al., [28]. Found COX-2 expression only in the granular cell layer.

Concerning COX2 data analysis, this study demonstrated COX2 in granular and spinous layer of normal skin that is similar to finding of Leong et al., [26] within control cases.

Well known possible causes of such discrepancies may be due to differences in antibodies used, embedding to antigen retrieval and processing of the material from fixation [29].

The present results showed COX2 cytoplasmic expression in 50% of KA cases and 95% of SCC cases, with a statistically significant correlation ($p = 0.005$).

Parallel to our results, studies of Chan et al., [29], Kagoura et al., [30], Hua HK et al., [31], Voge et al., [32], and Kuz'bicki [33] found stronger COX2 expression in SCC than adjacent normal skin and reported that the expression of COX-2 in squamous

cell carcinoma was significantly higher than that in keratoacanthoma with significant difference.

In contrast to our findings, Kagoura et al., [30] and An KP et al., [25] have documented comparable (or slightly increased) COX-2 expression in SCCs compared to KA. Additionally, Kim et al., [34] discovered Cox2 expression in only five (50%) of ten SCC patients investigated, which contradicts our findings. This difference may be due to genetic variation or limited number of cases in their researches.

The finding of strong expression of COX2 in all skin layers of SCC demonstrates that COX2 is a sensitive and specific molecular marker for SCC identification, although CD 10 was more accurate than COX2 and stromal CD 10 was more specific.

Higashi et al., [35] stated that inhibiting COX-2 expression resulted in the growth suppression of SCC cells and also added that use of a COX-2 inhibitor as (diclofenac) may be effective to treat SCC and associated precancerous lesions. This finding agreed our conclusion that COX2 overexpression in SCC supported the fact that up-regulated COX-2 increases prostaglandin production, which promotes cell proliferation and angiogenesis and provides the possibility of increased COX-2 expression is required for the development of SCC.

In conclusion, the current study showed that CD 10 and COX-2 may have a great value in differentiating keratoacanthomas from squamous cell carcinoma. The overexpression of CD 10 in stromal cells in SCC versus its weak and low expression in the same compartment of KA demonstrates the opposite biological activity between them.

References

- 1- MISAGO N., INOUE T., KOBAYASHI S. and NARISAWA Y.: Keratoacanthoma and other types of squamous cell carcinoma with crateriform architecture: Classification and identification. *The Journal of Dermatology*, Jun. 40 (6): 443-52, 2013.
- 2- WEEDON D.D., MALO J., BROOKS D. and WILLIAMSON R.: Squamous cell carcinoma arising in keratoacanthoma: A neglected phenomenon in the elderly. *The American Journal of Dermatopathology*, Jul. 1; 32 (5): 423-6, 2010.
- 3- SAVAGE J.A. and MAIZE Sr J.C.: Keratoacanthoma clinical behavior: A systematic review. *The American Journal of Dermatopathology*, May 1; 36 (5): 422-9, 2014.
- 4- GLEICH T., CHITICARIU E., HUBER M. and HOHL D.: Keratoacanthoma: A distinct entity?. *Experimental Dermatology*, Feb. 25 (2): 85-91, 2016.
- 5- Manstein C.H., Frauenhoffer C.J. and Besden J.E.: Keratoacanthoma: Is it a real entity?. *Annals of Plastic Surgery*, May 1; 40 (5): 469-72, 1998.

- 6- RA S.H., SU A., LI X., ZHOU J., COCHRAN A.J., KULKARNI R.P. and BINDER S.W.: Keratoacanthoma and squamous cell carcinoma are distinct from a molecular perspective. *Modern Pathology*, Jun. 28 (6): 799-806, 2015.
- 7- LEBLEBICI C., PASAOGLU E., KELTEN C., DARAKCI S. and DURSUN N.: Cytokeratin 17 and Ki-67: Immunohistochemical markers for the differential diagnosis of keratoacanthoma and squamous cell carcinoma. *Oncology Letters*, Apr. 1; 13 (4): 2539-48, 2017.
- 8- ICHII M., ORITANI K., YOKOTA T., ZHANG Q., GARRETT K.P., KANAKURA Y. and KINCADE P.W.: The density of CD 10 corresponds to commitment and progression in the human B lymphoid lineage. *PLoS One*, Sep. 23; 5 (9): e12954, 2010.
- 9- MISHRA D., SINGH S. and NARAYAN G.: Role of B cell development marker CD 10 in cancer progression and prognosis. *Molecular Biology International*, 2016.
- 10- ASLANI F.S., AKBARZADEH-JAHROMI M. and JOWKAR F.: Value of CD10 expression in differentiating cutaneous basal from squamous cell carcinomas and basal cell carcinoma from trichoepithelioma. *Iranian Journal of Medical Sciences*, Jun. 38 (2): 100, 2013.
- 11- SIVRIKOZ O.N., UYAR B., DAG F., TASLI F. and SANAL S.M.: CXCR-4 and COX-2 expression in basal cell carcinomas and well-differentiated squamous cell carcinomas of the skin; their relationship with tumor invasiveness and histological subtype. *Turk Patoloji Derg.*, Jan. 1; 31 (1): 30-5, 2015.
- 12- FOSSLIEN E.: Molecular pathology of cyclooxygenase-2 in neoplasia. *Annals of Clinical & Laboratory Science*, Jan. 1; 30 (1): 3-21, 2000.
- 13- ACKERMAN A.B., MENDONCA A.M.N. and GUO Y.: Keratoacanthoma vs squamous cell carcinoma. In: *Differential Diagnosis in Dermatopathology I*, 6nd ed. Lea & Febiger: Philadelphia/London, 2014.
- 14- CRIBIER B., ASCH P.H. and GROSSHANS E.: Differentiating squamous cell carcinoma from keratoacanthoma using histopathological criteria. *Dermatology*, 199 (3): 208-12, 1999.
- 15- PUTTI T.C., TEH M. and LEE Y.S.: Biological behavior of keratoacanthoma and squamous cell carcinoma: Telomerase activity and COX-2 as potential markers. *Modern Pathology*, Apr. 17 (4): 468-75, 2004.
- 16- LEBOIT P.E.: Is keratoacanthoma a variant of squamous cell carcinoma. New insights into an old controversy. soon?. *The American Journal of dermatopathology*, Aug. 1; 17 (4): 319-20, 1995.
- 17- LI J., WANG K., GAO F., JENSEN T.D., LI S.T., DEANGELIS P.M., KØLVRAA S., PROBY C., FORSLUND O., BOLUND L. and CLAUSEN O.P.: Array comparative genomic hybridization of keratoacanthomas and squamous cell carcinomas: Different patterns of genetic aberrations suggest two distinct entities. *Journal of Investigative Dermatology*, Aug. 1; 132 (8): 2060-6, 2012.
- 18- YADA K., KASHIMA K., DAA T., KITANO S., FUJIWARA S. and YOKOYAMA S.: Expression of CD 10 in basal cell carcinoma. *The American Journal of Dermatopathology*, Dec. 1; 26 (6): 463-71, 2004.
- 19- PIATTELLI A., FIORONI M., IEZZI G., PERROTTI V., STELLINI E., PIATTELLI M. and RUBINI C.: CD10 expression in stromal cells of oral cavity squamous cell carcinoma: A clinic and pathologic correlation. *Oral Diseases*, May 12 (3): 301-4, 2006.
- 20- AIAD H.A. and HANOUT H.M.: Immunohistochemical expression of CD10 in cutaneous basal and squamous cell carcinomas. *J. Egypt Nat. Cancer Inst.*, 19: 195-201, 2007.
- 21- HEIDARPOUR M., RAJABI P. and SAJADI F.: CD10 expression helps to differentiate basal cell carcinoma from trichoepithelioma. *Journal of research in medical sciences: The official journal of Isfahan University of Medical Sciences*, Jul. 16 (7): 938, 2011.
- 22- TAKAHARA M., CHEN S., KIDO M., TAKEUCHI S., UCHI H., TU Y., MOROI Y. and FURUE M.: Stromal CD 10 expression, as well as increased dermal macrophages and decreased Langerhans cells, are associated with malignant transformation of keratinocytes. *Journal of Cutaneous Pathology*, Jun. 36 (6): 668-74, 2009.
- 23- SABETI S., MALEKZAD F., NEISHABOORI N., POUR-ABDOLLAH TOUTKABONI M. and BIDARIZEREH-POOSH F.: The usefulness of CD10 in distinguishing between cutaneous basal cell carcinoma and squamous cell carcinoma. *Iranian Journal of Pathology*, Oct. 1; 9 (4): 245-50, 2014.
- 24- WAGONER J., KEEHN C. and MORGAN M.B.: CD-10 immunostaining differentiates superficial basal cell carcinoma from cutaneous squamous cell carcinoma. *The American Journal of Dermatopathology*, Dec. 1; 29 (6): 555-8, 2007.
- 25- AN K.P., ATHAR M., TANG X., KATIYAR S.K., RUSSO J., BEECH J., ASZTERBAUM M., KOPELOVICH L., EPSTEIN Jr. E.H., MUKHTAR H. and BICKERS D.R.: Cyclooxygenase-2 Expression in Murine and Human Nonmelanoma Skin Cancers: Implications for Therapeutic Approaches¶. *Photochemistry and Photobiology*, Jul. 76 (1): 73-80, 2002.
- 26- LEONG J., HUGHES-FULFORD M., RAKHLIN N., HABIB A., MACLOUF J. and GOLDYNE M.E.: Cyclooxygenases in human and mouse skin and cultured human keratinocytes: Association of COX-2 expression with human keratinocyte differentiation. *Experimental Cell Research*, Apr. 10; 224 (1): 79-87, 1996.
- 27- ABD-EL-ALEEM S.A., FERGUSON M.W., APPLETON I., BHOWMICK A., MCCOLLUM C.N. and IRELAND G.W.: Expression of cyclooxygenase isoforms in normal human skin and chronic venous ulcers. *The Journal of Pathology: A Journal of the Pathological Society of Great Britain and Ireland*, Dec. 195 (5): 616-23, 2001.
- 28- NIJSTEN T., COLPAERT C.G., VERMEULEN P.B., HARRIS A.L., VAN MARCK E. and LAMBERT J.: Cyclooxygenase-2 expression and angiogenesis in squamous cell carcinoma of the skin and its precursors: A paired immunohistochemical study of 35 cases. *British Journal of Dermatology*, Oct. 151 (4): 837-45, 2004.
- 29- CHAN G., BOYLE J.O., YANG E.K., ZHANG F., SACKS P.G., SHAH J.P., EDELSTEIN D., SOSLOW R.A., KOKI A.T., WOERNER B.M. and MASFERRER J.L.: Cyclooxygenase-2 expression is up-regulated in squamous cell carcinoma of the head and neck. *Cancer Research*, Mar. 1; 59 (5): 991-4, 1999.

- 30- KAGOURA M., TOYODA M., MATSUI C. and MORO-HASHI M.: Immunohistochemical expression of cyclooxygenase-2 in skin cancers. *Journal of Cutaneous Pathology*, Jul. 28 (6): 298-302, 2001.
- 31- HUA H.K., JIN C., YANG L.J., TAO S.Q. and ZHU X.H.: Expression of cyclooxygenase-2 in squamous cell carcinoma and keratoacanthoma and its clinical significance. *Cell Biochemistry and Biophysics*, Jun. 72 (2): 475-80, 2015.
- 32- VOGT T., MCCLELLAND M., JUNG B., POPOVA S., BOGENRIEDER T., BECKER B., RUMPLER G., LANDTHALER M. and STOLZ W.: Progression and NSAID-induced apoptosis in malignant melanomas are independent of cyclooxygenase II. *Melanoma Research*, Dec. 1; 11 (6): 587-99, 2001.
- 33- KUZ'BICKI L., LANGE D., STANEK-WIDERA A. and CHWIROT B.W.: Different expression of cyclooxygenase-2 (COX-2) in selected nonmelanocytic human cutaneous lesions. *Folia histochemica et cytobiologica*, 49 (3): 381-8, 2011.
- 34- KIM K.H., PARK E.J., SEO Y.J., CHO H.S., KIM C.W., KIM K.J. and PARK H.R.: Immunohistochemical study of cyclooxygenase-2 and p53 expression in skin tumors. *The Journal of Dermatology*, May 33 (5): 319-25, 2006.
- 35- HIGASHI Y., KANEKURA T. and KANZAKI T.: Enhanced expression of cyclooxygenase (COX)-2 in human skin epidermal cancer cells: Evidence for growth suppression by inhibiting COX-2 expression. *International Journal of Cancer*, Jun. 1; 86 (5): 667-71, 2000.

أهمية مجموعة الانتشار (سى دي ١٠) وانزيمات الأكسدة الحلقية (كوكس ٢) في التمايز بين الورم الشائكى المتقرن وسرطان الخلايا الحرشفية : دراسة كيميائية نسيجية مناعية

المقدمة: الورم الشائكى المتقرن هو ورم كيراتينى حميد شائع فريد من نوعه، يتطور غالباً في غضون ٦ إلى ٨ أسابيع، مع انحدار تلقائى بعد ٣ إلى ٦ أشهر ويشارك ميزات مع سرطان الخلايا الحرشفية. ومن المهم التمييز بين هذين نوعين لأن لكل منهما سلوك سريرى مختلف. لا توجد معايير حساسة بما يكفى للتمييز بشكل موثوق بينهما.

الهدف من البحث: وقد استهدفت هذه الدراسة دور كلا من سى دي ١٠ وكوكس ٢ في التفرقة بين الورم الشائكى المتقرن وسرطان الخلايا الحرشفية.

طرق البحث: قد اشتملت هذه الدراسة على ٢٠ حالة من سرطان الخلايا الحرشفية و ١٢ حالة من ورم شائكى متقرن بالإضافة إلى ٥ حالات من الخلايا الحرشفية الطبيعية كمجموعة ضابطة. وأخذت العينات على شرائح موجبة من البلوكات الشمعية المختارة من قسم الباثولوجى - جامعة بنها من الفترة ٢٠١٥ وحتى ٢٠١٨ وتمت صبغة كل حالة بصبغة كيمياء المناعة النسيجية لدراسة ظهور دلالات كلا من سى دي ١٠ وكوكس ٢.

نتائج البحث: سجلت الدراسة علاقة إحصائية عالية بين ظهور دلالة سى دي ١٠ للتفرقة بين الورم الشائكى المتقرن حيث ظهرت في ١٤.٣٪ فقط منه وبين سرطان الخلايا الحرشفية الذى ظهرت دلالة سى دي ١٠ في كل حالاته. وعلى نفس المنوال سجل ظهور دلالة كوكس ٢ علاقة إحصائية عالية للتفرقة بين الورمين.

مضمون البحث: المعايير النسيجية المختلفة التى كانت تستخدم عادة في تمايز الورم القرني من سرطان الخلايا الحرشفية ليست موثوقة تماماً. أثبتت الدراسة الحالية باستخدام سى دي ١٠ وكوكس ٢ أنها بالتأكيد مفيدة في التمييز بين الأورام القرنية والأورام السرطانية التى تصيب الخلايا الحرشفية، والتي تتقارب عن كذب في التشكل النسيجي وتوضح أيضاً التباين البيولوجى بينها.