

Advanced-Platelet-Rich Fibrin Combination with Metformin for Surgical Correction of Periodontal Intrabony Defects: A Randomized Double Blinded Clinical Trial

Asem M. Kamel¹, Ahmed O. A. Abdelrahman², Hany G. Gobran³, Hesham A . Dameer⁴, Mohamed Badawy⁴, Ahmed M. Hussein⁵

Original
Article

*Oral Medicine, Periodontology, Oral Diagnosis, and Dental Radiology, Faculty of Dental Medicine, Al-Azhar University (Assiut branch), Assiut, Egypt*¹. *Oral and Maxillofacial Surgery, Faculty of Dental Medicine, Al-Azhar University (Assiut branch), Assiut, Egypt*². *Faculty of Dental Medicine – Al azhar university – cairo branch for boys Dental and oral Biology department*³ *Oral Biology Department, Faculty of Dentistry, Assiut University, Assiut, Egypt*⁴. *Department of Oral and Maxillofacial Pathology, Faculty of Dentistry, Assiut University, Assiut, Egypt*⁵.

ABSTRACT

Objective: This trial preformed to evaluate clinically and radiographically, the efficacy of growth factors producing/inducing materials; Advanced-Platelet-Rich Fibrin (A-PRF) and Metformin (MF) respectively, in the surgical treatment of intrabony periodontal defects.

Methods: Forty-eight systemically healthy chronic periodontitis patients with intrabony defect were divided equally into 4 groups. First Group, patients treated by open flap debridement (OFD). Second Group, patients treated by OFD + 1% MF gel. Third Group, patients treated by A-PRF, which inserted into the intra bony defect (IBD). Fourth Group treated by (1% MF + A-PRF). Parameters were gathered at baseline 6 and 9 months.

Results: The reduction in probing depth (PD) and clinical attachment level (CAL) was greater in the A-PRF + 1% MF patients group than other groups. Combination of A-PRF + 1% MF showed statistically significant reduction of IBD greater than all other groups.

Conclusions: Usage of combination of A-PRF + 1% MF seems to be superior in gaining bone than surgical treatment by OFD, OFD + A-PRF or OFD + MF only.

Key Words: Advanced-Platelet-Rich Fibrin, Metformin, Periodontitis, Intrabony Defects, Regeneration, Randomized Clinical Trial.

Received: 21 March 2022, **Accepted:** 11 April 2022.

Corresponding Author: Ahmed M. Hussein, Lecturer at Department of Oral and Maxillofacial Pathology, Faculty of Dentistry, Assiut University, Assiut, Egypt., **Tel :** +2 01110100380, **Mobile:** 01003864692, **E-mail:** aattay1@gmail.com, ahmedattay@dent.aun.edu.eg

ISSN: 2090-097X, July 2021, Vol. 12, No. 4

INTRODUCTION

Bone resorption with intrabony defects are signs of periodontal disease progression. Various methods, involving resective and regenerative procedures, have been applied for the treatment of periodontal intrabony defects. Resective techniques remove granulation tissues without regenerating the periodontium. The aim of periodontal therapy is to regenerate the damaged periodontal structures.^[1] The production of an ideal bone graft for regeneration purposes and xenografts became the main focus for treating periodontal disease.^[2] These different bone grafts can be used alone, can also be mixed with each other or with growth factors such as platelet-rich fibrin (PRF).^[3]

Periodontal bone defects require treatments which involve the use of cells, growth factors and bone substitutes, as biomaterials/scaffolds, with biocompatibility, osteoinductive, and osteoconductive properties. Generally, the three key elements in tissue engineering fields are stem cells, biomaterials and growth factors.^[4] The incorporation of growth factors is a very promising option in bone healing and/or stems cells that capable

of reconstructing bone and marrow structures.^[5] However, there are controversial results in the supportive role of bone morphogenic proteins in alveolar bone regeneration and the quantity of the mesenchymal stem cells required for optimum bone tissue regeneration. Further materials will be likely to develop on innovative polymeric platforms with controlled biophysical, biomechanical and biological properties that target in the delivery of growth factors and cells.^[6]

The PRF exhibits a slow and sustained release of growth factors, such as transforming growth factor- β 1, platelet-derived growth factor, and vascular endothelial growth factor which all have been proven to promote the wound healing and tissue regeneration.^[7] To generate a solid fibrin clot, a high relative centrifugation force (RCF=708g), is required. In this RCF range, the fibrin network exhibits a dense structure with minimal interfibrillar space.^[8] Modification of the preparation protocol by reducing the applied RCF resulted in an improved preparation protocol for advanced solid PRF (A-PRF) using 208g. The advanced fibrin clot showed a more porous structure with

a larger interfibrous space compared to that of PRF. Furthermore, inflammatory cells and platelets, were observed in even distributions.^[9] In vivo pre-clinical investigations showed the role of the clot structure in the vascularization and regeneration processes.^[10] Comparative histological analysis demonstrated that, porous structure of A-PRF significantly facilitated the cellular penetration into the fibrin scaffold, the low-speed centrifugation concept and enhancing the growth factor release.^[11]

Metformin (MF), 1, 1-dimethylbiguanide, is a second class biguanide, used to manage type II diabetes mellitus.^[12] The MF has the osteogenic effect through two mechanisms of action. Firstly, increased proliferation of osteoblasts and reduction of osteoclast activity. Secondly, MF decrease the production of receptor activator of nuclear factor kappa B ligand and increase the production of osteoprotegerin from osteoblasts in turn decreases the osteoclast activity, thereby inducing bone formation and inhibiting bone resorption.^[13] ^[14] Metformin has the ability to diminish intracellular reactive oxygen species and advanced glycation end-products and ability to lower levels of insulin-like growth factors were beneficial for bone formation.^[15] MF used as a local delivered adjunct to non-surgical periodontal therapy, or graft material in surgical periodontal therapy with open flap debridement (OFD) alone or as combination with other substances. Different clinical studies have shown that metformin improves clinical and radiological parameters of chronic periodontitis, and metformin gel is a promising option for improving the prognosis of periodontal treatment.^[16-18]

The aim of this clinical trial is study the efficacy of A-PRF and MF in the surgical treatment of intrabony periodontal defects. To the best of our knowledge, no clinical and radiographic study assesses the regenerative potential of A-PRF alone or in combination with MF in treatment of intrabony defect within chronic periodontitis patients.

MATERIALS AND METHODS

2.1. Patients Setting and Population

This study was designed as randomized double-blinded (patient, clinician) clinical study, included 48 systemically healthy chronic periodontitis patients with pocket depth more than 5 millimeters. Patients classified randomly into the following equal groups using online software (<https://www.randomizer.org>); numbers were concealed in closed envelopes. Neither the patient nor the assessor was aware of the type of surgery done. First Group, treated by open flap debridement (OFD). Second Group, treated by OFD and 1% MF gel. Third Group, treated by OFD and advanced platelet-rich fibrin (A-PRF) and last group treated by OFD and 1% MF gel with A-PRF. Inclusion criteria included; all patients should be free from any

systemic disease; all patients have severe chronic periodontitis with pocket depth ≥ 5 mm with intrabony defect and successfully maintenance proper oral hygiene after phase I therapy. Exclusion criteria included patients with other conditions affecting periodontal tissue such as aggressive periodontitis, systemic diseases or conditions, and medications. Patients with unacceptable oral hygiene after phase I therapy were excluded, also smokers' patients.

2.2. Sample Size Calculation and Power Analysis

For the sample size calculation, the power analysis was performed using G Power system (Ver. 3.192 copy right 1992-2020) for a one-way fixed effect analysis of variance (ANOVA). A power calculation was performed to determine the sample size. The criterion for significance was set at $\alpha = 0.05$ (type I error) and $\beta = 0.20$ (type II error) to recognize significant difference (g) of 1 mm between groups considering the change in intrabony bony depth (IBD) as the primary outcome variable, with a 95% confidence interval. Therefore, the required sample size was found to be 12 patients in each group with 0.99 % actual power of this trial was obtained.

2.3. Formulation of Metformin Gel

Preparation of MF gel was performed as described by Mohapatra et al. experiment.^[19] All ingredients required for the formulation were weighed accurately. Dry gellan gum powder was dispersed in distilled water maintained at 95°C. The dispersion was stirred at 95°C for 20 minutes to facilitate hydration of gellan gum. Mannitol was added to the gellan gum solution with continuous stirring and the temperature was maintained above 80°C. A weighed amount of MF was added with stirring. Then sucralose, citric acid, and preservatives (methylparaben, propylparaben) were added with stirring. Finally, sodium citrate was dissolved in 10mL distilled water and added to the mixture. The mixture could be cooled to room temperature to form gel 1% (Figure 1).

2.4. Advanced-Platelet Rich Fibrin Preparation

A-PRF prepared as Ghanaati et al. technique.^[20] Pre-operatively, intravenous blood was collected by venipuncture of the antecubital vein in two 10mL sterile plain glass-based vacuum tubes without anticoagulant and immediately placed in a preprogrammed centrifuge (Low Speed PRP Centrifuge TD4®, Labwe Scientific, Hunan, china) at 1500 rpm for 14 minutes. After centrifugation, the resultant product consists of 3 layers. The topmost layer consisting, of a cellular platelet poor plasma, PRF clot in the middle, and RBCs at the bottom of the test tube. The middle layer PRF was removed and placed in a sterile dappen dish (Figure 2).

2.5. Nonsurgical Periodontal Therapy and Preliminary Maintenance

At the initial visit, each patient underwent a full-mouth supra and subgingival surgical root planning. In the first visit, all patients were given careful instructions regarding proper oral hygiene maintenance. Four to six weeks after surgical root planning, a periodontal evaluation was done to examine the desired sites for the trial.

2.6. Surgical Protocol

Before surgery, patients rinsed with 0.12% chlorhexidine digluconate (Hexitol®, The Arab Drug Company (adco), Egypt). Intracrevicular incisions were made and this was followed by the reflection of mucoperiosteal flaps. Thorough defect debridement and root planning were performed using ultrasonic instrumentation and area-specific curettes. No osseous recontouring was performed. First Group, treated by OFD only, without addition of any regenerative material in the bone defect. Second Group, treated by OFD + 1% MF gel into the IBD. Third Group, treated by A-PRF, which inserted into the IBD after OFD. Fourth Group, treated by OFD + (1% MF + A-PRF), equal amounts of A-PRF and MF gel were mixed and inserted into the IBD after OFD. Compressed A-PRF membranes (two A-PRFs used to make one A-PRF membrane) were adapted over the defects to protect the A-PRF + 1% MF in the defect space. Patients were masked for grouping and treatment.

2.7. Postsurgical Follow-Up

Patients were advised with repeated application of an ice pack over the area of the face related to the surgery for one day to avoid postsurgical edema. Patients were asked to avoid sticky, spicy, hard and crispy food in the 1st week post surgically. Systemic antibiotic therapy such as; Amoxicillin/clavulanic acid (Augmentin®625mg, Glaxo-SmithKline Pharmaceutical company, Fifth district, New Cairo, Cairo, Egypt) 3/times daily for a week. Chlorhexidine 0.12% digluconate (Kenara® mouth wash, Macro Group Pharmaceuticals, Egypt) twice daily for 4 weeks. Analgesic and anti-inflammatory (Cataflam®50mg, Novartis Pharma, Heliopolis, Cairo, Egypt) twice/daily for a week. Follow-up was carried out every week in 1st month then at 3, 6 and 9 months post surgically in order to implement the importance of oral hygiene.

2.8. Clinical and Radiographic Assessment

All patients will be evaluated at baseline, 6 and 9 months after treatment using the following clinical parameters; plaque index (PI), gingival index (GI), probing depth (PD), clinical attachment level (CAL). Standardized radiographic assessment for IBD (the distance from the crest of the alveolar bone to the base of the defect) was performed. For achieving standardization, bite registration block was made for each patient to adjust film position at different intervals. Radiographs were taken by parallel technique using film holder (Figure 3).

2.9. Statistical Analysis

Data were recorded, computed, tabulated and analyzed at a significance level of $P < 0.05$ by GraphPad Prism (version 8, San Diego, California). The mean and standard deviation values were calculated for each group in each test. For parametric data; repeated measure ANOVA was used to compare between more than two groups in related samples. Graphs were performed using the Microsoft Excel program.

RESULTS

This randomized clinical trial was performed in 48 patients whom treated by either open flap debridement/metformin/A-PRF/metformin + A-PRF. patients were divided to 19 females and 29 males; their age ranged from 21 to 49 years with a mean age of 32 years. A reduction in both PI and GI was observed in all study groups at 6 and 9 months, postoperatively. The reduction of PI was statistically significant among treatment intervals within each group while its reduction was not statistically significant among the 4 groups. The reduction of GI was not statistically significant among treatment intervals within each group nor among the study groups. This reduction was indicated to successful maintenance periodontal therapy during observation time. (Table 1) Comparison of mean PD and CAL showed differences between the study groups from baseline to 9 months by repeated measurement ANOVA test. When comparing between groups at each period of investigation, there were significant differences between the groups at 6 and 9 months (Table 2,3). The reduction in PD was greater in the A-PRF + 1% MF group ($T_0=5.2 \pm 0.32$ mm, $T_1=3.8 \pm 0.52$ mm, $T_2=3.5 \pm 0.49$ mm) and MF ($T_0=5.6 \pm 0.08$ mm, $T_1=4.4 \pm 0.24$ mm, $T_2=3.9 \pm 0.24$ mm) compared to A-PRF ($T_0=5.5 \pm 0.15$ mm, $T_1=4.3 \pm 0.16$ mm, $T_2=3.9 \pm 0.32$ mm), and OFD ($T_0=5.6 \pm 0.21$ mm, $T_1=4.8 \pm 0.43$ mm, $T_2=4.6 \pm 0.29$ mm) groups. CAL reduction was greater in the A-PRF + 1% MF group ($T_0=4.5 \pm 0.32$ mm, $T_1=3.0 \pm 0.18$ mm, $T_2=2.9 \pm 0.07$ mm), and A-PRF group ($T_0=4.3 \pm 0.18$ mm, $T_1=3.2 \pm 0.16$ mm, $T_2=2.9 \pm 0.12$ mm), compared to 1% MF group ($T_0=4.4 \pm 0.30$ mm, $T_1=3.2 \pm 0.24$ mm, $T_2=3.0 \pm 0.09$ mm), and OFD group ($T_0=4.4 \pm 0.22$ mm, $T_1=3.7 \pm 0.21$ mm, $T_2=3.4 \pm 0.23$ mm) (Table 2, 3).

Reduction of IBD in all studied groups was statistically significant at end of observation period. When comparing between groups, this study showed that there was not statistically significant difference between OFD and 1% MF nor between OFD and A-PRF, while comparing between OFD and MF + A-PRF showed statistically significant difference. No statistically significant difference between 1% MF and A-PRF. Combination of A-PRF + 1% MF showed statistically significant reduction of IBD greater than all other groups (Table 4, Figure 4).

Figure 1: (A) showing gel formation of metformin in bottle, (B) metformin gel injected form syringe needle, and (C) application of metformin gel in intrabony defect.



Figure 2: (A) showing preprogrammed centrifuge, (B) showing A-PRF clot in the middle of the test tube, (C) showing A-PRF was removed and placed in a sterile dappen dish, and (D) showing application of A-PRF within and over intrabony defect.

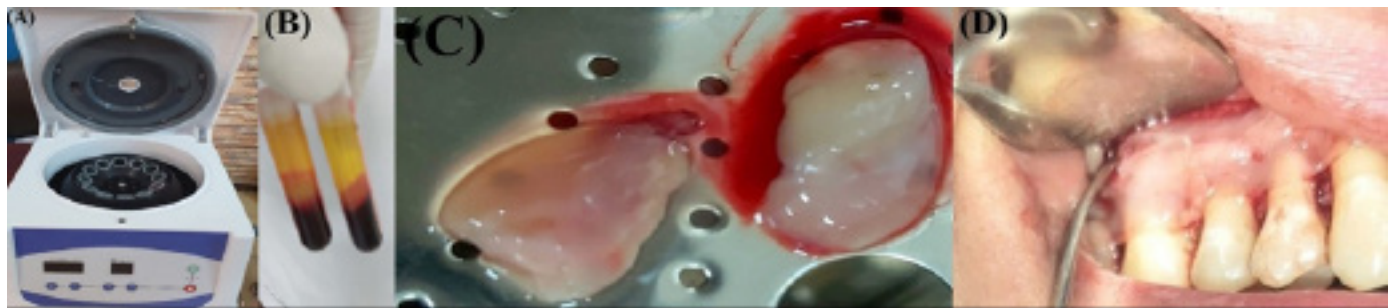


Figure 3: Radiographic pictures showing the radiographic variation in patients from tested group before and after the procedure treatments

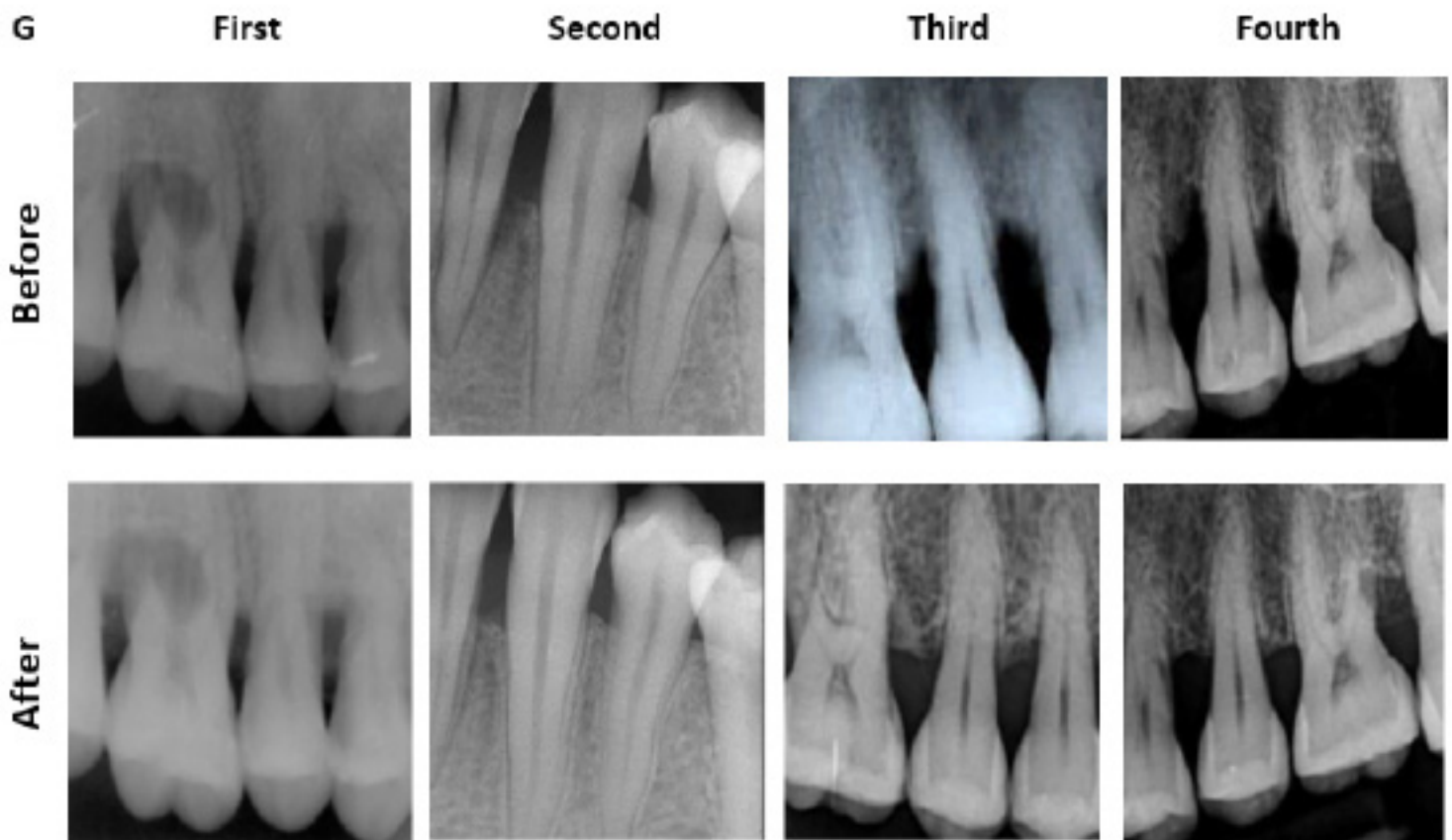


Figure 4: Column chart showing means of IBD of treatment groups at interval periods

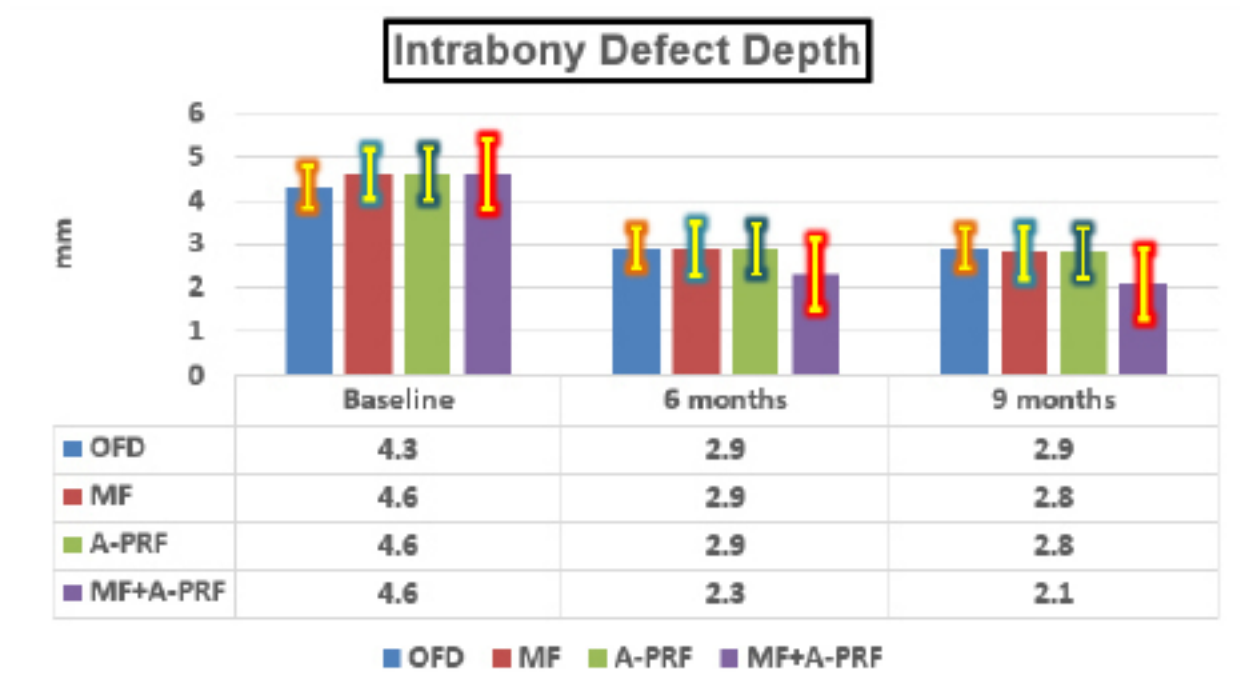


Table 1: First ANOVA test for comparison Plaque index and Gingival index between treatment intervals within each group and second ANOVA test for comparison between studied groups within each interval. ($P \leq 0.05$) T0 = baseline, T1= 6 months, T2 = 9 months. (** = statistical significant differences).

Plaque index					
Follow up periods	Baseline	6 Months	9 Months	Comparison between treatment intervals within each group	
Studied groups	Mean ± SD	Mean ± SD	Mean ± SD	By First ANOVA test	
Group I	0.37±0.07	0.34±0.07	0.27±0.04	p	0.00**
Group II	0.41±0.05	0.33±0.02	0.30±0.05	p	0.000**
Group III	0.40±0.06	0.36±0.03	0.31±0.05	p	0.00**
Group IV	0.41±0.03	0.37±0.03	0.30±0.03	p	0.000**
Comparison between studied groups within each interval By second ANOVA test	T0 p 0.30	T1 p 0.25	T2 p 0.27		
Gingival index					
Follow up periods	Baseline	6 Months	9 Months	Comparison between treatment intervals within each group	
Studied groups	Mean ± SD	Mean ± SD	Mean ± SD	By First ANOVA test	
Group I	0.32±0.04	0.30±0.05	0.29±0.04	p	0.22
Group II	0.34±0.02	0.33±0.02	0.32±0.02	p	0.08
Group III	0.35±0.02	0.33±0.02	0.32±0.02	p	0.12
Group IV	0.34±0.03	0.33±0.03	0.31±0.02	p	0.32
Comparison between studied groups within each interval By second ANOVA test	T0 p 0.38	T1 p 0.21	T2 p 0.05		

Table 2. First ANOVA test for comparison Pocket Depth between treatment intervals within each group and second ANOVA test for comparison between studied groups within each interval. ($p \leq 0.05$) T0 = baseline, T1= 6 months, T2 = 9 months. (** = statistical significant differences)

Pocket Depth					
Follow up periods	Baseline	6 Months	9 Months	Comparison between treatment intervals within each group By ANOVA test	
Studied groups	Mean± SD	Mean± SD	Mean± SD		
Group I	5.6±0.21	4.8±0.43	4.6±0.29	p	0.000**
Group II	5.6±0.08	4.4±0.24	3.9±0.24	p	0.000**
Group III	5.5±0.15	4.3±0.16	3.9±0.32	p	0.000**
Group IV	5.2±0.32	3.8±0.52	3.5±0.49	p	0.000**
Comparison between studied groups within each interval By ANOVA test	T0	T1	T2		
	p 0.000**	p 0.000**	p 0.000**		

Table 3. First ANOVA test for comparison Clinical Attachment Loss between treatment intervals within each group and second ANOVA test for comparison between studied groups within each interval. ($p \leq 0.05$) T0 = baseline, T1= 6 months, T2 = 9 months. (** = statistical significant differences)

Clinical Attachment Loss					
Follow up periods	Baseline	6 Months	9 Months	Comparison between treatment intervals within each group By ANOVA test	
Studied groups	Mean± SD	Mean± SD	Mean± SD		
Group I	4.4± 0.22	3.7± 0.21	3.4±0.23	p	0.000**
Group II	4.4±0.30	3.2±0.24	3.0±0.09	p	0.000**
Group III	4.3±0.18	3.2±0.16	2.9±0.12	p	0.000**
Group IV	4.5±0.32	3.0±0.18	2.9±0.07	p	0.000**
Comparison between studied groups within each interval By ANOVA test	T0	T1	T2		
	p 0.35	p 0.00**	p 0.00**		

Table 4. First ANOVA test for comparison intrabony Defect Depth between treatment intervals within each group and second ANOVA test for comparison between studied groups within each interval. ($P \leq 0.05$) T0 = baseline, T1= 6 months, T2 = 9 months. (** = statistical significant differences)

Intrabony Defect Depth						
Follow up periods	Baseline	6 Months	9 Months	First ANOVA test		
Studied groups	Mean± SD	Mean± SD	Mean± SD			
Group I	4.3±0.17	2.9±0.20	2.9±0.21	p		0.000**
Group II	4.6±0.28	2.9±0.25	2.8±0.30	p		0.000**
Group III	4.6±0.06	2.9±0.30	2.8±0.33	p		0.000**
Group IV	4.6±0.06	2.3±0.18	2.1±0.10	p		0.000**
Second ANOVA test	T0	T1	T2			
All Groups	p 0.01**	p 0.000**	p 0.000**			
OFD vs. MF	p 0.02**	p 0.21	p 0.92			
OFD vs. A-PRF	p 0.03**	p 0.20	p 0.97			
OFD vs. MF+A-PRF	p 0.03**	p 0.000**	p 0.000**			
MF vs. A-PRF	p 0.99	p 0.99	p 0.99			
MF vs. MF+A-PRF	p 0.99	p 0.000**	p 0.000**			
PRF vs. MF+A-PRF	p 0.99	p 0.000**	p 0.000**			

DISCUSSION

There is respectable clue to support the opinion, that residual pockets of ≥ 5 mm after phase I periodontal therapy exemplify a risk factor for further disease progression and therefore constitute a clear indication for periodontal surgery.^[21] There is more attention regarding the treatment of intrabony defects, which states that such defects should be grafted, but very less attendance to horizontal bone loss; because data indicate that, if vertical defects were be left untreated, they are more prone to periodontal disease progression than horizontal bone defect.^[22]

In this clinical trial some exclusions criteria were implied, these criteria in line with those mentioned in Shukla et al. trial^[23] they stated that some important rules to be considered prior any periodontal surgery are systemic health of the patient and common diseases such as diabetes and blood disorders should be within normal limits or excluded. Periodontal surgery is never a

motivation for smokers to stop their habit, such patients can be asked to quit for a period of 3-4 weeks, which sometimes becomes impossible for chronic smokers.^[24] Phase I periodontal therapy was performed and followed by 4-6 weeks maintenance to detect acceptable plaque control level of patients included in this study; this in accordance with pie opinion^[25] who mentioned that plaque is considered the most important factor in the inception, advancement, and intensity of periodontal infection and also a major risk factor to fiasco of periodontal therapy.

Different authors reported that the efficacy of varying concentrations of subgingival delivered metformin in the treatment of chronic periodontitis resulted in a significant increase in PD reduction, CAL gain and intrabony defect depth.^[16, 18, 26] In the present study also 1% metformin was used. Results of this clinical study showed that improvement in plaque control and gingival tissue health in all groups from the start to the end of observation period; this reduction of PI and GI was not statistically significant when comparing between groups. These readings agreed with results obtained by Khalifehzadeh et al. study^[27]

and Pradeep et al. trial.^[28] they stated that improvement occurred due to oral prophylaxis was done for all the patients before starting the study, and similar oral hygiene instructions were given to patients from all four groups. Current investigations showed that PD and CAL improvement were statistically significant with better results appeared in A-PRF + MF group; On the contrary Khalifehzadeh et al. study^[27] showed no significant improvement as they used PRGF + MF. On the other hand, the present PD and CAL improvement were corresponded with study of Pradeep et al. trial^[28] as they used PRF + MF and they mentioned that The greater PD reduction and RAL gain seen in the PRF + 1% MF group signifies the enhanced combined efficacy of growth factors released by PRF and bone-forming activity of MF. In present study, intrabony defect depth was reduced significant when comparing A-PRF+MF group against other groups only. These results were coincided with Khalifehzadeh et al. study^[27] as they reported that significant improvements were shown in MF + PRGF group; however, most of the defects in the MF and PRGF groups had no radiographic changes and two defects in the control group showed radiolucency, which might be the reason for the significance of radiographic changes unlike the clinical parameters. Also, Pradeep et al.^[28]

study showed that The IBD reduction in PRF, MF, and PRF + MF groups was significantly greater than in the OFD-only group, showing the benefit of the use of growth factors in periodontal regeneration. A statistically significant greater reduction in the PRF + MF group than PRF or 1% MF also signifies the additional efficacy of use of multiple approaches serving growth factors for regeneration. Better combination of A-PRF with metformin may be due to elevation of the expression of different types of growth factor inside A-PRF network which promote osteogenesis by stimulating effects of metformin.^[29, 30]

To our limited acquaintance, advanced PRF alone or in combination with MF were used in the present study as growth factors producing / inducing materials for surgical periodontal therapy of intrabony defect. Also, very little clinical trials applied MF formulation in treatment in intrabony periodontal defects. Forthcoming studies should employ A-PRF + MF combination or A-PRF with other bone grafts to evaluate its effects on growth factors production/induction in periodontal defects and implant bony sites. More radiographic analysis of periodontal bony defects by CBCT will be required in further trials to accurate assessments of effects of A-PRF + MF combination or A-PRF with other bone grafts on bone wall topography.

CONCLUSION

With some limitations in the current study, A-PRF + MF combination showed a greater improvement in IBD reduction when compared with OFD only, 1% MF or A-PRF alone.

CONFLICT OF INTEREST

The authors declare no conflict of interest.

Data Availability

The data are available upon request

Ethical Statement

The study protocol was approved by the ethical committee, Faculties of Dental Medicine, Al-Azhar University in Scientific Department Council No. (12/2018) as trial number (AUAREC202220053-12). All eligible patients were thoroughly informed of the nature, potential risks and benefits of their participation in the study and signed their informed consent documents.

Author Contribution

Asem M. Kamel: conceptualization; data curation; formal analysis; investigation; methodology; project administration; resources; visualization; writing-original draft; writing review & editing. Ahmed O. A. Abdelrahman: formal analysis; investigation; methodology; resources; writing-review. Hany G. Gobran: data curation; investigation; resources; writing review & editing. Hesham A. Dameer: formal analysis; methodology; project administration; supervision; writing-review. Mohamed Badawy: formal analysis; investigation; methodology; resources; writing-review. Ahmed M. Hussein: data curation; formal analysis; investigation; methodology; project administration; resources; supervision; writing-review & editing.

REFERENCES

1. Sculean A, Stavropoulos A, Bosshardt DD. Self-regenerative capacity of intraoral bone defects. *J Clin Periodontol*. 2019;46:70-81.
2. Kadkhodazadeh M, Amid R, Shirvan HP, Namdari M. Clinical efficacy of gingival thickening following the use of allogeneic acellular and xenogeneic collagen matrix: A 12-month randomized clinical trial. *Int J Periodontics Restorative Dent*. 2021;41:e63-71.
3. Karayürek F, Kadiroğlu ET, Nergiz Y, Coşkun Akçay N, Tunik S, Ersöz Kanay B, et al. Combining platelet rich fibrin with different bone graft materials: An experimental study on the histopathological and immunohistochemical aspects of bone healing. *J Craniomaxillofac Surg*. 2019;47:815-25.
4. Kolk A, Handschel J, Drescher W, Rothamel D, Kloss F, Blessmann M, et al. Current trends and future perspectives of bone substitute materials—from space holders to innovative biomaterials. *J Cranio-Maxillofacial Surg*. 2012;40:706-18.
5. Chen F-M, Zhang M, Wu Z-F. Toward delivery of multiple growth factors in tissue engineering. *Biomaterials*. 2010;31:6279-308.

6. Miron RJ, Moraschini V, Fujioka-Kobayashi M, Zhang Y, Kawase T, Cosgarea R, et al. Use of platelet-rich fibrin for the treatment of periodontal intrabony defects: A systematic review and meta-analysis. *Clin Oral Investig*. 2021;25:2461-78.
7. Al-Namnam N, Jayash SN. Recent advances in bone graft substitute for oral and maxillofacial applications: A review. *Int J Biosci*. 2019;15:70–94.
8. El Bagdadi K, Kubesch A, Yu X, Al-Maawi S, Orłowska A, Dias A, et al. Reduction of relative centrifugal forces increases growth factor release within solid platelet-rich-fibrin (PRF)-based matrices: a proof of concept of LSCC (low speed centrifugation concept). *Eur J Trauma Emerg Surg*. 2019;45:467-79.
9. Saini K, Chopra P, Sheokand V. Journey of platelet concentrates: a review. *Biomed Pharmacol J*. 2020;13:185–91.
10. De Melo BAG, Jodat YA, Cruz EM, Benincasa JC, Shin SR, Porcionatto MA. Strategies to use fibrinogen as bioink for 3D bioprinting fibrin-based soft and hard tissues. *Acta Biomater*. 2020;117:60-76.
11. Al-Maawi S, Herrera-Vizcaino C, Dohle E, Zrnc TA, Parvini P, Schwarz F, et al. Homogeneous pressure influences the growth factor release profiles in solid platelet-rich fibrin matrices and enhances vascular endothelial growth factor release in the solid platelet-rich fibrin plugs. *Int J Growth Factors Stem Cells Dent*. 2018;1:8-16.
12. Bailey CJ. Metformin: historical overview. *Diabetologia*. 2017;60:1566–76.
13. Zhao X, Pathak JL, Huang W, Zhu C, Li Y, Guan H, et al. Metformin enhances osteogenic differentiation of stem cells from human exfoliated deciduous teeth through AMPK pathway. *J Tissue Eng Regen Med*. 2020;14:1869–79.
14. Rathinavelu S, Guidry-Elizondo C, Banu J. Molecular modulation of osteoblasts and osteoclasts in type 2 diabetes. *J Diabetes Res*. 2018;2018.
15. Shaik AR, Singh P, Shaik C, Kohli S, Vohora D, Ferrari SL. Metformin: Is it the well wisher of bone beyond glycemic control in diabetes mellitus? *Calcif Tissue Int*. 2021;1-15.
16. Rao NS, Pradeep AR, Kumari M, Naik SB. Locally delivered 1% metformin gel in the treatment of smokers with chronic periodontitis: a randomized controlled clinical trial. *J Periodontol*. 2013;84:1165-71.
17. Pankaj D, Sahu I, Kurian IG, Pradeep AR. Comparative evaluation of subgingivally delivered 1.2% rosuvastatin and 1% metformin gel in treatment of intrabony defects in chronic periodontitis: A randomized controlled clinical trial. *J Periodontol*. 2018;89:1318–25.
18. Kamel A, Gobran H, Abdelrahman A, Hussein A. Clinical and biochemical analysis for the adjunctive effects of simvastatin and metformin in the treatment of chronic periodontitis patients. *Egypt Dent J*. 2021;67:465-74.
19. Mohapatra A, Parikh RK, Gohel MC. Formulation, development and evaluation of patient friendly dosage forms of metformin, Part-II: Oral soft gel. *Asian J Pharm*. 2008;2:172-6.
20. Ghanaati S, Booms P, Orłowska A, Kubesch A, Lorenz J, Rutkowski J, et al. Advanced platelet-rich fibrin: a new concept for cell-based tissue engineering by means of inflammatory cells. *J Oral Implantol*. 2014;40:679-89.
21. Citterio F, Gualini G, Chang M, Piccoli GM, Giraudi M, Manavella V, et al. Pocket closure and residual pockets after non-surgical periodontal therapy: A systematic review and meta-analysis. *J Clin Periodontol*. 2022;49(1):2-14.
22. Woo HN, Cho YJ, Tarafder S, Lee CH. The recent advances in scaffolds for integrated periodontal regeneration. *Bioact Mater*. 2021;6(10):3328–42.
23. Shukla S, Chug A, Lanka Mahesh SS, Singh K. Optimal management of intrabony defects: current insights. *Clin Cosmet Investig Dent*. 2019;11:19.
24. Mittal S, Komiyama M, Ozaki Y, Yamakage H, Satoh-Asahara N, Yasoda A, et al. Gingival bleeding and pocket depth among smokers and the related changes after short-term smoking cessation. *Acta Odontol Scand*. 2021;10:1-6
25. Pei X. New surgery approaches preserving entire papilla to treat isolated interdental intrabony defects: A narrative review. *Clin Exp Dent Res*. 2021;7(5):719-25.
26. Pradeep AR, Rao NS, Naik SB, Kumari M. Efficacy of varying concentrations of subgingivally delivered metformin in the treatment of chronic periodontitis: a randomized controlled clinical trial. *J Periodontol*. 2013;84:212-20.
27. Khalifehzadeh S, Haghanifar S, Jenabian N, Kazemi S, Hajiahmadi M. Clinical and radiographic evaluation of applying 1% metformin biofilm with plasma rich in growth factor (PRGF) for treatment of two-wall intrabony periodontal defects: A randomized clinical trial. *J Dent Res Dent Clin Dent Prospects*. 2019;13(1):51.

28. Pradeep AR, Nagpal K, Karvekar S, Patnaik K, Naik SB, Guruprasad CN. Platelet-rich fibrin with 1% metformin for the treatment of intrabony defects in chronic periodontitis: A randomized controlled clinical trial. *J Periodontol.* 2015;86(6):729–37. al. Homogeneous pressure influences the growth factor release profiles in solid platelet-rich fibrin matrices and enhances vascular endothelial growth factor release in the solid platelet-rich fibrin plugs. *Int J Growth Factors Stem Cells Dent.* 2018;1:8-16.
29. Moreno-Rodríguez JA, Ortiz-Ruiz AJ. Papilla preservation periodontal surgery in periodontal reconstruction for deep combined intra-suprabony defects. Retrospective analysis of a registry-based cohort. *J Clin Exp Dent.* 2021;13:e769-75.
30. Mamajiwala AS, Sethi KS, Raut CP, Karde PA, Mamajiwala BS. Clinical and radiographic evaluation of 0.8% hyaluronic acid as an adjunct to open flap debridement in the treatment of periodontal intrabony defects: randomized controlled clinical trial. *Clin Oral Investig.* 2021;25:5257-71.