

## Clinical and Radiological Diagnosis of Talar Fractures: Review Article

Mohsen Mohamed Abdo Mar'ei, Reda Hussien El-kady,

Ali Adyaab Ali Adyaab, Mohamed Abdelaziz Mohamed Gaith

Department of Orthopedic Surgery, Faculty of Medicine, Zagazig University, Egypt.

**Corresponding Author:** Ali Adyaab Ali Adyaab, **E- Mail:** alawei4u@gmail.com, **Mobile:** (+20) 01110489874

### ABSTRACT

**Background:** Less than one percent of all foot and ankle fractures are caused by talar neck fractures. Arthritis, osteonecrosis, and fractures due to malunion were also common. High suspicion is needed to identify talar process fractures, especially in the context of ankle sprain-like processes including inversion and/or eversion, as these injuries are difficult to detect on routinely radiographs.

**Objective:** This review article aimed to characterize talus neck fractures and their clinical and radiological diagnosis.

**Methods:** These databases were searched for articles published in English in 3 data bases [PubMed – Google scholar-science direct] and Boolean operators (and, OR, not) had been used such as [Talar fractures, foot & ankle fractures] and in peer-reviewed articles between May 1977 and January 2021, no language limitations, and filtered in selected data basis. However, the range of time interval for researches was wide as there was scarcity of data on the particular reviewed, accurate and depth in the retrieved literature. Documents in a language apart from English had been excluded as sources for interpretation. Papers apart from main scientific studies had been excluded (documents unavailable as total written text, conversation, conference abstract papers and dissertations).

**Conclusion:** In some cases, talar fractures are accompanied by soft tissue envelope damage (A common link between open talus fractures). Talar body extrusion and deltoid ligament encirclement are two distinct features of Hawkins type III fracture dislocations. It is typically possible to detect talar neck or body fractures by taking routine ankle radiographs.

**Keywords:** Talar fractures, Foot and ankle fractures.

### INTRODUCTION

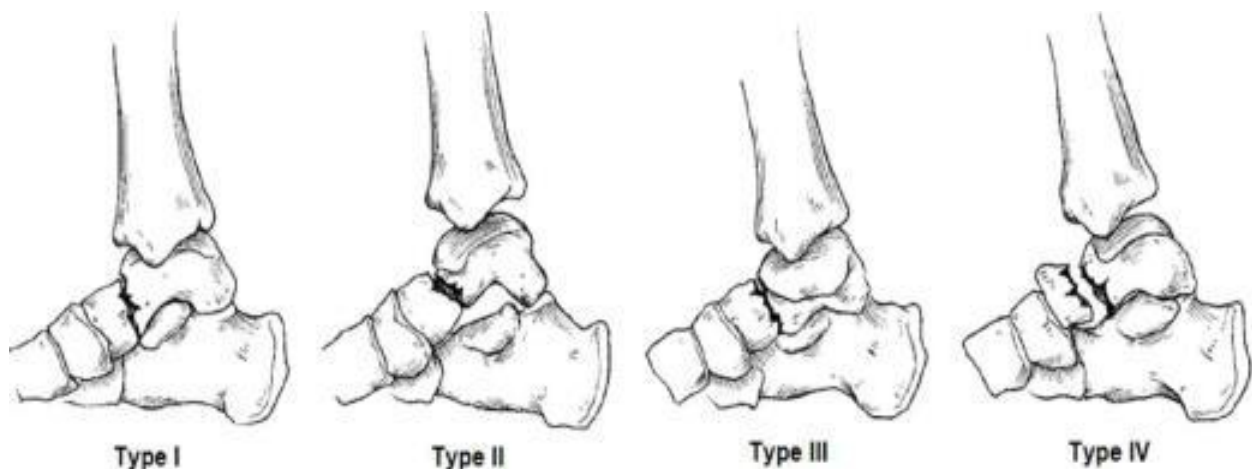
Both fractures preceding and those occurring laterally or laterally next to the lateral process were identified as separate types of fractures in the talus. It is important to distinguish between tibiotalar and subtalar fractures since they both impact the mechanical alignment and congruence of the joints. The talus fracture is the second most common type of tarsal bone fracture, with around half of all talus fractures occurring <sup>(1)</sup>.

There are only 1% of all foot and ankle fractures that result in fractures to the talar neck, which is the most prevalent area for talus damage <sup>(2-4)</sup>. A high-energy axial load coupled with excessive ankle dorsiflexion is the

most common cause of talar neck fractures. Accidents involving automobiles and falls from great heights are two of the most common causes of injury today <sup>(1,3)</sup>.

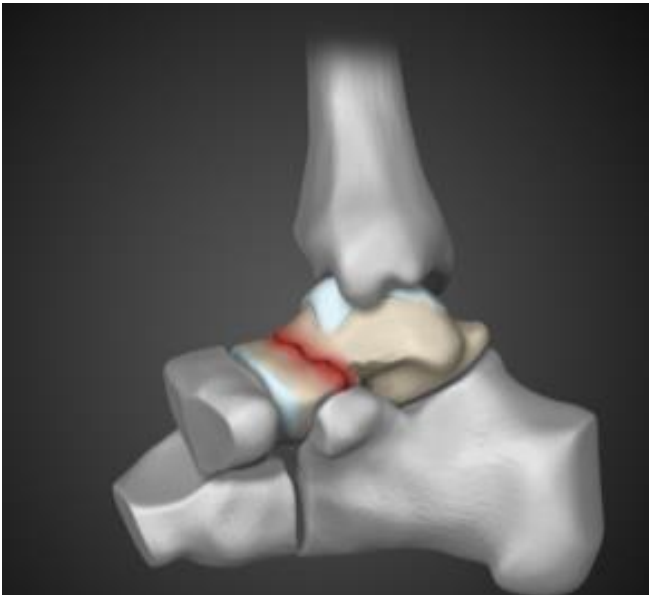
### Talar Neck Fractures:

**Classification:** Hawkins <sup>(5)</sup> described a classification system that might be linked to prognosis in his seminal study. He divided fractures into three groups: I, II, and III. Canale and Kelly published the long-term outcomes of their talus fracture series in 1978. The three Hawkins groups were referred to as "types," and a previously unidentified "type IV" was included <sup>(6)</sup>.



**Figure (1):** Hawkins classification <sup>(7)</sup>

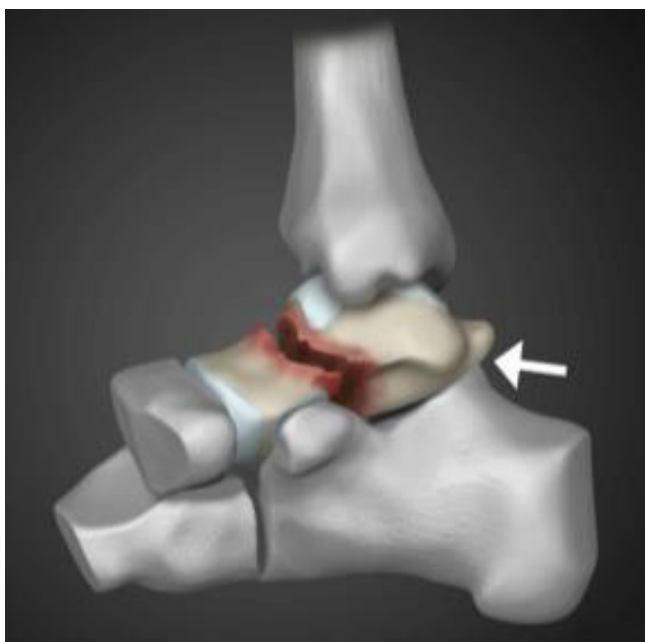**Type I fracture:** Non-displaced talus neck fractures are the most common talus fracture type (Figure 2). Type I fractures become non-type I fractures when there is sufficient displacement. At some point along the tibia's middle or posterior side, the fracture line crosses the subtalar joint. Talus stays in its original position within ankle and subtalar joints. One of three primary blood supply pathways, the anterolateral neck, is impacted in principle <sup>(7)</sup>.



**Figure (2):** Type I fracture <sup>(7)</sup>

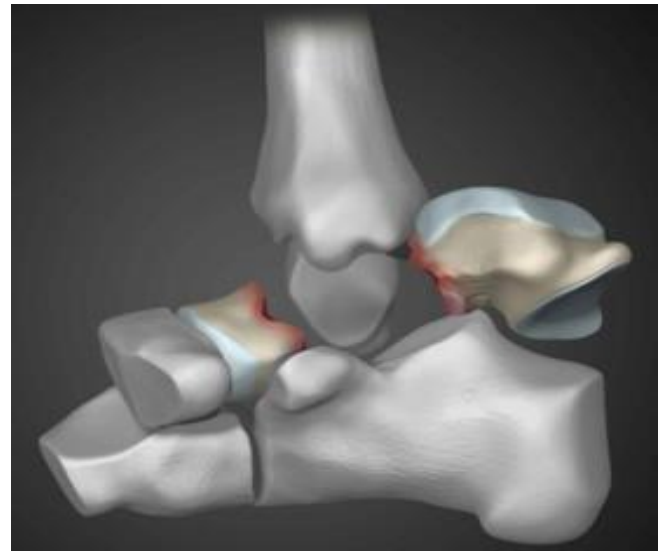Radiographs may miss true type I fractures unless they are confirmed by CT or magnetic resonance imaging (MRI). If the displacement is even 1 to 2 mm, type II fractures (Figure 3) should be investigated instead of type I fractures <sup>(7)</sup>.

Subtalar joint dislocation or subluxation are examples of type II fractures. Of Hawkins' 24 cases, ten had dislocation of the posterior aspect of the talus. In the majority of these cases, a medial subtalar joint dislocation was to blame. Blood flow to the talus has been disrupted in two major ways. Vessels that enter through sinus tarsus and the tarsal canal foramina, as well as those that enter through the neck. The foramina on the medial surface of the body, the third route of blood flow, are typically undamaged, but they can be injured <sup>(7)</sup>.



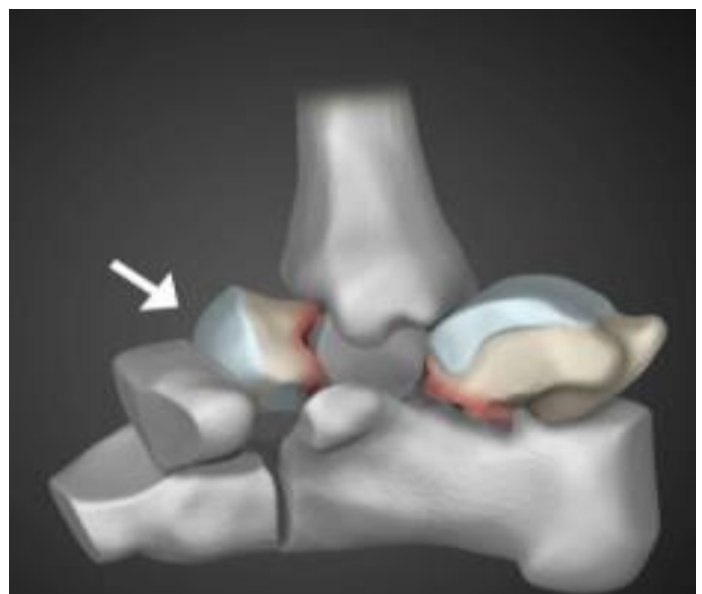**Figure (3):** Type II fracture <sup>(7)</sup>

**Type III:** In type III injuries, a fractured neck is linked to talus body displacement from the subtalar and ankle joints (Figure 4). Anatomical findings by Hawkins revealed that the talus body had protruded from the posterior and medial side and was situated between tibial neurovascular networks and the Achilles tendon. The talus's skeleton could be viewed as a whole. Even though the talus rotates within the ankle mortise, the head of the talus remains in line with the navicular. This type of lesion frequently impairs blood supply to the talus. Open wounds with neurovascular and/or cutaneous sequelae are typical in type III injuries <sup>(8)</sup>.



**Figure (4):** Type III fracture <sup>(8)</sup>

It's estimated that about 80% of people have Type IV. In type IV fractures (Figure 5), the talus head is dislocated or subluxated from the talonavicular joint and the ankle and subtalar joints being dislocated. In the Canale and Kelly dataset, 4% of the 71 talar fractures had type IV injuries, and all three had unsatisfactory outcomes <sup>(8)</sup>.



**Figure (5):** Type IV fracture <sup>(8)</sup>

### Signs and Symptoms:

Talus fractures occur infrequently, approximately 1% of all bone fractures, 2% of all lower extremity injuries, and 3% of all foot fractures. Talus lesions can go unnoticed if they aren't spotted early. Thigh bone fractures are common among young and energetic people. When diagnosing talar process fractures, especially when they are associated with ankle sprain-like processes that involve inversion or eversion, it is critical to have a high degree of suspicion. Detection of tiny fractures necessitates the use of more advanced imaging. Talus fractures may occur as the result of low-energy processes or significant trauma, and they can be life-altering if not treated promptly <sup>(1)</sup>.

Talar fractures are frequently accompanied by soft tissue damage. A Hawkins Type III fracture dislocation is commonly associated with an open talus fracture because the talar body can be extruded posteromedially and wrapped around the deltoid ligament. All high-energy talar fractures result in significant soft tissue envelop degeneration, even if the lesion does not always pierce the skin. If the talus fracture is open, the condition is even more serious. In some circumstances, the talar body can be completely extruded, removing the bone's soft tissues totally. <sup>(9)</sup>.

Managing an injury like an extruded or absent talus is a challenge. When a dislocation occurs, the soft tissue envelope of the hindfoot is at risk, and prompt reduction is necessary to avoid further soft tissue injury and necrosis. In the treatment of talus fractures, the displaced talus must be reduced as soon as feasible <sup>(10)</sup>. Fractures of the talus can lead to neurovascular injury. The posterior tibial nerve and artery can stay intact even when the talus is displaced posteromedially due to the flexor hallucis longus tendon's protective effects on the neurovascular bundle <sup>(11)</sup>. Osteonecrosis of the talus is associated with an increased risk of vascular damage to the talus as a side effect. It's common for the deltoid ligament to feed the talar body with blood when the talus is dislocated laterally <sup>(10)</sup>.

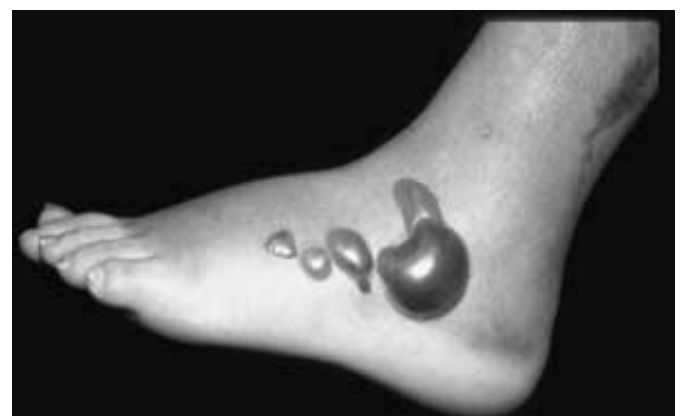Talar fractures have been demonstrated to have little effect on foot perfusion, however this is not always the case. Talus fractures can be associated with a range of midfoot and forefoot fractures, depending on the manner of injury, such as falling from a great height or being involved in a catastrophic car accident. Fractures accompanied by significant soft tissue damage might cause serious neurovascular impairment. These injuries necessitate a thorough assessment of the foot's vascular and neural systems <sup>(11)</sup>.

### Injuries that may occur as a result of the accident:

Other musculoskeletal injuries and systemic trauma are frequently connected with talus fractures. The therapy of the talus fracture in the multiply injured patient can be problematic since the fractures develop as a result of high-energy causes. When possible, emergent reduction of displaced joints remains a key premise. The soft tissue care is made

easier by stabilizing fractures and dislocations. Some multisystem injuries are so severe that talus fracture therapy must be put on hold. Even if proper orthopaedic care is delayed, a positive outcome for a talus fracture is still possible <sup>(12,13)</sup>. First, a thorough assessment of the multi-injured patient is critical, as is adherent to the Advanced Trauma Life Support (ATLS) protocols. An emergency reduction of dislocated joints, followed by the installation of an external fixator, can be performed if the patient is still alive <sup>(14,15)</sup>, or internal fixation <sup>(16)</sup> if possible. In multi-injured patients, foot injuries are among the most frequently neglected disorders <sup>(17)</sup>. As a result, a high level of suspicion is once again required. Numerous studies show that patients with talar fractures are more likely to suffer from multiple injuries, including those to the ipsilateral lower extremity and those with an Injury Severity Score greater than 16, as shown in a collection of more than 70 talar fractures from a level I trauma center <sup>(18)</sup>.

There may be an association between talus fracture dislocation and other high-energy foot injuries, particularly in people who have been injured several times or who have fallen from a height or who have had major motor vehicle trauma. To minimize and stabilize any displaced joints, high-energy foot injuries should be treated along with talus fractures as soon as possible <sup>(19,20)</sup>. Patients with dislocated joints and soft tissue injuries may not be able to undergo definitive fixation of fractures or internal fixation, however early joint stabilization is recommended if possible. High-energy foot (Figure 6) injuries appear to be on the rise, owing in part to the increased usage of air bags in automobiles. Serious damage to the foot, ankle, and lower extremities has become more prevalent as patients who might have perished from chest, head, or visceral traumas have increased their chances of life. In terms of the patient's long-term outcome, these foot injuries can be disastrous. <sup>(21)</sup>.



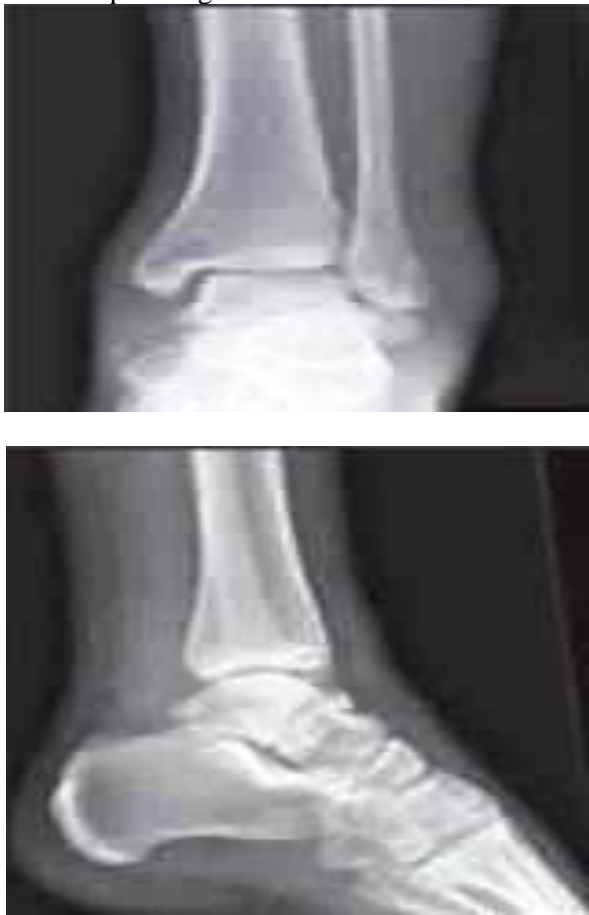**Figure (6):** High-energy foot injuries <sup>(22)</sup>

There is a strong correlation between talar neck and body fractures and foot and ankle fractures <sup>(23)</sup>. Talar fractures are often found in conjunction with tibial plafond or malleolar injuries. At least 19% of patients in prior studies were found to have concurrent malleolar injury <sup>(24)</sup>. Talar fractures can be treated in conjunction

with distal tibia and fibula fractures, and the malleolar injury may even facilitate talar body access. Talar neck fractures are associated with a 10% chance of a calcaneal fracture (23).

**Plain radiographic views are as follows:**

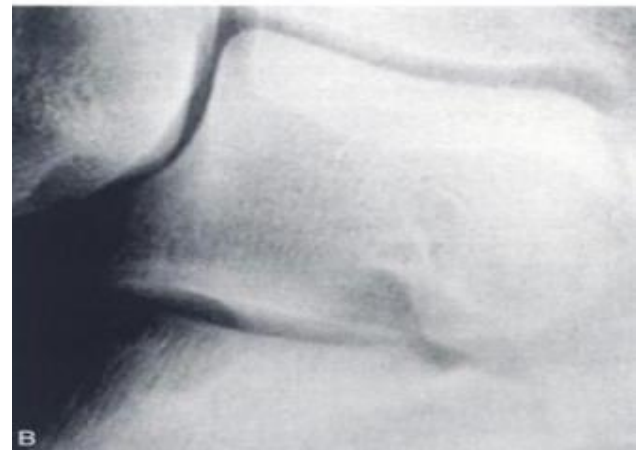
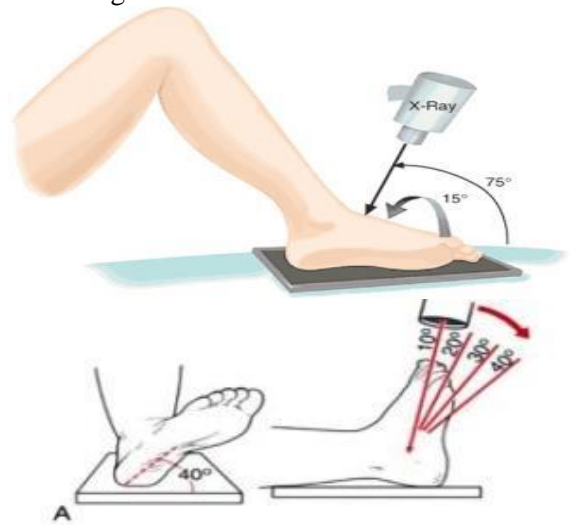
In most cases, talar neck or body fractures can be diagnosed by a series of regular ankle radiographs. When the medial and lateral shoulders of the talar body are superimposed on a real lateral picture of the talus, the risk of missing non-displaced talar neck fractures is reduced. Computed tomography may be required in the case of a non-displaced talar neck fracture. However, because of the talus' unusual structure and associated processes, a collection of basic radiography images is needed to help visualize it. Standard anteroposterior (AP), lateral (Lat), and mortise views of the ankle are essential for diagnosis of talar body and neck fractures and related pathologies (25).



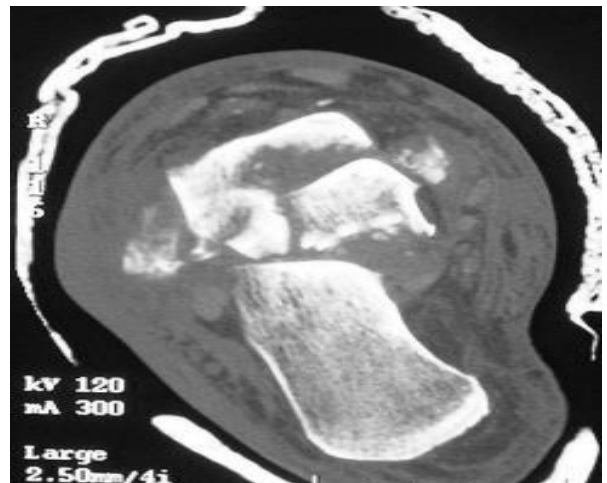
**Figure (7):** Standard plain X-rays: AP view on the left & lateral view on the right (25)

Specialized X-ray images, such as Canale and Broden's views, are utilised to detect surgical reduction of talar fractures. Using the Canale view, it is possible to determine talar varus malalignment by looking at the talar neck from an AP perspective. In order to get the Canale view, you need to do three things: fully plantar-flex your ankle, pronate your foot 15 degrees, and angle the imaging tube 75 degrees cephalad from horizontal. This image is particularly valuable for intraoperative

evaluation of the repair of a talar neck fracture with associated medial comminution and establishing that varus malalignment has been avoided (25).



**Figure (8):** The talar neck from Canale and Kelly's perspective (7)

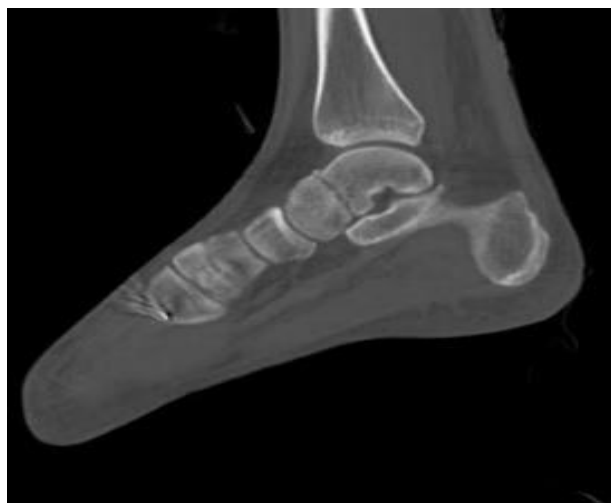

**Figure (9):** Broden view of talus (12)

**Computed Tomography:**

In the case of talar fractures and dislocations, a CT scan can be extremely useful. With CT scans, the congruity of the subtalar joint reduction can be clearly seen, and the level of detail is much higher. There are several instances where CT scans are beneficial, especially for comminuted and subtalar fractures that are difficult to

spot on plain films. Because the talus has a unique shape, CT scans are less useful in detecting the talus' general alignment. Comminuted talar fractures and subtalar dislocations can benefit greatly from routine computed tomography examinations<sup>(26, 27)</sup>.

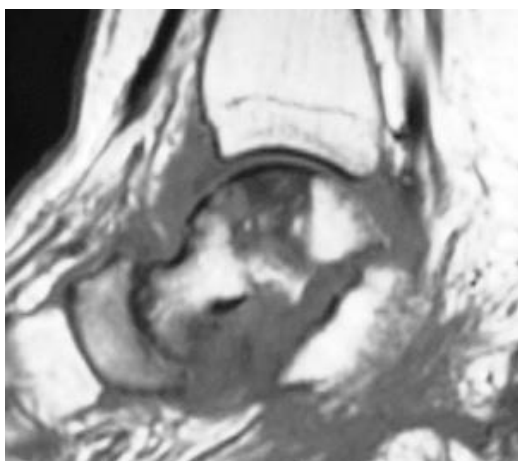


**Figure (10):** Computed tomography (CT) scans<sup>(26)</sup>

Small but severe fractures of the inferior face of the talus are often found in patients with subtalar dislocations, which can be more clearly shown on CT scans than on plain films alone.

#### **Magnetic resonance imaging:**

It has a significant impact on the diagnosis of talar fractures<sup>(28)</sup>. MRI is a good way to check for osteonecrosis. MRI has previously been affected by artefact caused by the installation of a large number of stainless-steel screws. When titanium implants are used to heal fractures, this problem is reduced. Improved MRI technology has reduced metallic artefact to the point where MRI can still deliver relevant information when large amounts of hardware are present<sup>(29)</sup>. Avascular necrosis can be detected early with an MRI. Patients with a negative Hawkins sign should get an MRI 12 weeks following the fracture, especially in high-energy traumatic instances<sup>(27, 29)</sup>.



**Figure (11):** MRI shows osteonecrosis<sup>(25)</sup>

#### **CONCLUSION**

In some cases, talar fractures are accompanied by soft tissue envelope damage. A common link between open talus fractures and Hawkins Type III fracture dislocations is the ability of the talar body to be extruded posteromedially and wrapped around the deltoid ligament. A series of regular ankle radiographs can usually diagnose talar neck or body fractures.

**Financial support and sponsorship:** Nil.

**Conflict of interest:** Nil.

#### **REFERENCES**

1. **Santavirta S, Seitsalo S, Kiliuoto O et al. (1984):** Fracture of the talus. *J Trauma*, 24 (11): 986–989.
2. **Kenwright J, Taylor R (1970):** Major injuries of the talus. *J Bone Joint Surg Br.*, 52 (1): 36–48.
3. **Lorentzen J, Christensen S, Krogsøe O et al. (1977):** Fractures of the neck of the talus. *Acta Orthop Scand.*, 48 (1): 115–120.
4. **Vallier H, Nork S, Barei D et al. (2004):** Talar neck fractures: results and outcomes. *J Bone Joint Surg Am.*, 86–A (8): 1616–1624.
5. **Hawkins L (1970):** Fractures of the neck of the talus. *J Bone Joint Surg Am.*, 52 (5): 991–1002.
6. **Williams T, Barba N, Noailles T et al. (2012):** Total talar fracture—inter- and intra-observer reproducibility of two classification systems (Hawkins and AO) for central talar fractures. *Orthop Traumatol Surg Res.*, 98 (4): 56–65.
7. **Chan G, Sanders D, Yuan X et al. (2008):** Clinical accuracy of imaging techniques for talar neck malunion. *J Orthop Trauma*, 22 (6): 415–418.
8. **Lindvall E, Haidukewych G, DiPasquale T et al. (2004):** Open reduction and stable fixation of isolated, displaced talar neck and body fractures. *J Bone Joint Surg Am.*, 86–A (10): 2229–2234.
9. **Sanders D, Busam M, Hattwick E et al. (2004):** Functional outcomes following displaced talar neck fractures. *J Orthop Trauma*, 18 (5): 265–270.
10. **Bellamy J, Keeling J, Wenke J et al. (2011):** Does a longer delay in fixation of talus fractures cause osteonecrosis? *J Surg Orthop Adv.*, 20 (1): 34–37.
11. **Babu N, Schuberth J (2010):** Partial avascular necrosis after talar neck fracture. *Foot Ankle Int.*, 31 (9): 777–780.
12. **Patel R, Van Bergeyk A, Pinney S (2005):** Are displaced talar neck fractures surgical emergencies? A survey of orthopaedic trauma experts. *Foot Ankle Int.*, 26 (5): 378–381.
13. **Xue Y, Zhang H, Pei F et al. (2014):** Treatment of displaced talar neck fractures using delayed procedures of plate fixation through dual approaches. *Int Orthop.*, 38 (1): 149–154.
14. **Fleuriat Chateau P, Brokaw D, Jelen B et al. (2002):** Plate fixation of talar neck fractures: preliminary review of a new technique in twenty-three patients. *J Orthop Trauma*, 16 (4): 213–219.
15. **Maceroli M, Wong C, Sanders R et al. (2016):** Treatment of comminuted talar neck fractures with use of minifragment plating. *J Orthop Trauma*, 30 (10): 572–578.
16. **Ziran B, Abidi N, Scheel M (2001):** Medial malleolar osteotomy for exposure of complex talar body fractures.

- J Orthop Trauma, 15 (7): 513–518.
17. **Ohl X, Harisboure A, Hemery X et al. (2011):** Long-term follow-up after surgical treatment of talar fractures: twenty cases with an average follow-up of 7.5 years. *Int Orthop.*, 35 (1): 93–99.
  18. **Gonzalez A, Stern R, Assal M (2011):** Reduction of irreducible Hawkins III talar neck fracture by means of a medial malleolar osteotomy: a report of three cases with a 4-year mean follow-up. *J Orthop Trauma*, 25 (5): 47–50.
  19. **van Bergen C, Tuijthof G, Sierevelt I et al. (2011):** Direction of the oblique medial malleolar osteotomy for exposure of the talus. *Arch Orthop Trauma Surg.*, 131 (7): 893–901.
  20. **Prewitt E, Alexander I, Perrine D et al. (2012):** Bimalleolar osteotomy for the surgical approach to a talar body fracture: case report. *Foot Ankle Int.*, 33 (5): 436–440.
  21. **Muir D, Saltzman C, Tochigi Y et al. (2006):** Talar dome access for osteochondral lesions. *Am J Sports Med.*, 34 (9): 1457–1463.
  22. **Simpson R, Auston D (2016):** Open reduction for AO/OTA 81-B3 (Hawkins 3) talar neck fractures: the natural delivery method. *J Orthop Trauma*, 30 (3): 106–109.
  23. **Miller A, Prasarn M, Dyke J et al. (2011):** Quantitative assessment of the vascularity of the talus with gadolinium-enhanced magnetic resonance imaging. *J Bone Joint Surg.*, 93 (12): 1116–1121.
  24. **Liu H, Chen Z, Zeng W et al. (2017):** Surgical management of Hawkins type III talar neck fracture through the approach of medial malleolar osteotomy and mini-plate for fixation. *J Orthop Surg Res.*, 12 (1): 1–9.
  25. **Fortin P, Balazsy J (2001):** Talus fractures: evaluation and treatment. *J Am Acad Orthop Surg.*, 9 (2): 114–127.
  26. **Draper S, Fallat L (2000):** Autogenous bone grafting for the treatment of talar dome lesions. *J Foot Ankle Surg.*, 39 (1): 15–23.
  27. **Arain A, Adams C, Haddad S et al. (2021):** Diagnosis and Treatment of Peritalar Injuries in the Acute Trauma Setting: A Review of the Literature. *Advances in Orthopedics*, 20: 1852025.
  28. **Wu K, Zhou Z, Huang J et al. (2016):** Talar neck fractures treated using a highly selective incision: a case-control study and review of the literature. *J Foot Ankle Surg.*, 55 (3): 450–455.
  29. **Mayo K (1987):** Fractures of the talus: principles of management and techniques of treatment. *Tech Orthop.*, 2 (3): 42–54.