

Identification and Preservation of Pituitary Gland in Pituitary Surgery

Mahamad Tarek Al Hamshary,¹ MBBCH, Abdelkafy Sharaf eldin,¹ MD, Islam Mohamed Al Aghory,¹ MD.

* Corresponding Author:

Mahamad Tarek Al Hamshary
Mohamadalthamshary90@gmail.com

Received for publication
 December 27, 2021; Accepted
 May 14, 2022; Published online
 May 14, 2022.

Copyright The Authors
 published by Al-Azhar
 University, Faculty of Medicine,
 Cairo, Egypt. Users have the
 right to read, download, copy,
 distribute, print, search, or link
 to the full texts of articles under
 the following conditions:
 Creative Commons Attribution-
 Share Alike 4.0 International
 Public License (CC BY-SA 4.0).

doi: 10.21608/aimj.2022.110951.1736

¹Neurosurgery Department, Faculty
 of Medicine, Al-Azhar University,
 Cairo, Egypt.

ABSTRACT

Background: Suppressing hormone hyper-secretion, lowering tumour mass, preserving normal pituitary function, minimizing long-term effects from excess hormone production, and preventing tumour recurrence are all aims of pituitary tumour treatment.

Aim of the study: The purpose of this study was to detect the pituitary gland during pituitary surgery in order to remove as much tumour as possible while preserving pituitary function and minimizing postoperative complications.

Patients and Methods: From June 2019 to November 2021, this study was done at the Neurosurgery Departments of Al-Azhar University Hospitals "Al-Hussein" and "Bab El-Sheria," and the 6th of October Hospital for Health Insurance. In this study, a total of 30 participants with a pituitary single lesion who had trans-sphenoidal surgery were analyzed and evaluated for preoperative, intraoperative, and postoperative factors. Preoperative and intraoperative gland tissue identification, operational issues, resection degree, and postoperative hormone deficiency were all taken into account.

Results: Only 4.76 percent (1 out of 21) of individuals with healthy pituitary gland tissue required postoperative hormone replacement. In the nine cases where intraoperative gland tissue identification failed, postoperative hormone replacement was necessary in 66.67 percent (6 out of 9) of the cases. On postoperative MRI, 66.67 percent of patients had radical tumour excision, whereas 33.33 percent of patients (10) had tumour remnants. According to the findings, endoscopic trans-sphenoidal surgery can locate and retain pituitary gland tissue and function. After surgery, normal pituitary function is predicted if the gland tissue is preserved.

Conclusion: Endoscopic transsphenoidal surgery can identify and maintain pituitary gland tissue and function, according to this study.

Keywords: Pituitary gland; Preservation of hormones; Trans-sphenoidal endoscopy.

Disclosure: The authors have no financial interest to declare in relation to the content of this article. The Article Processing Charge was paid for by the authors.

Authorship: All authors have a substantial contribution to the article.

INTRODUCTION

Pituitary neoplasms are benign tumours that most commonly grow from the adenohypophysis and are classified based on size and endocrine function. Pituitary micro adenomas have a diameter of less than one centimeter, whereas pituitary macro adenomas have a diameter of more than one centimetre. Another method classifies them into functional and non-functional adenomas within functional adenomas, which are called from the hormone they secrete.¹

Suppressing hormone hyper secretion, lowering tumour bulk, keeping normal pituitary function, avoiding long-term effects of excess hormone production, and limiting tumour recurrence are all aims of pituitary tumour therapy. 2 Suprasellar

ectopic pituitary adenomas affecting the stalk have previously been removed using transcranial surgery. The majority of patients lost pituitary function as a result of these treatments, as tumour removal was typically inadequate.³

The goal of this study was to detect pituitary gland in pituitary surgery in order to accomplish maximum tumour removal while conserving pituitary functioning and reducing postoperative consequences.

PATIENTS AND METHODS

An analytical prospective study conducted on 30 Patients who had been diagnosed as Pituitary solitary lesion and underwent Tran's sphenoidal surgery at Neurosurgery Department of Al-Azhar University Hospitals "Al-Hussein" and "Bab El-Shaeria" as well

as 6th Of October Hospital for Health Insurance from June 2019 to November 2021. Follow up of patients done clinically and radiologically over 6 months.

All Patients underwent trans sphenoidal surgery for pituitary solitary lesions were included for this Study. Patients with lateral extension (invasion) to the Cavernous Sinus due to difficulties in achieving complete resection were excluded. Patients with pituitary gland infection or recurrent tumor (prior Pituitary surgery) were excluded. Patients with history of Radiotherapy were excluded. Patient with loss to follow up (from another country) were also excluded.

Preoperative Evaluation: The patient was assessed using a full history, a full general and neurological examination, as well as an endocrinological assessment. A radiological assessment was also performed using a pre- and postoperative MRI with contrast. All of the relevant approvals were received in order to carry out the research. Before beginning the study, the Neurosurgery department provided official authorization for its implementation. The study was authorized by the Ethical Committee of Faculty of Medicine, Al-Azhar University.

Surgical technique: The patient was put supine with the head slightly flexed, elevated, telted, and rotated towards the operating surgeon while under general anaesthetic. In the nasal phase, the endoscope was put into the right nostril parallel to the MT, in line with the floor of the nasal cavity, to first visualize the choana, then to the anterior wall of the sphenoid. After palpating the sphenoid ostium with a blunt dissecting instrument, the sphenoidal sphase was opened. A short portion of the posterior nasal septum was removed to increase exposure, and the sphenoidal septations were carefully reduced. The anterior wall of the pituitary fossa was drilled down until only a thin eggshell of bone was left over the pituitary tumour or gland during the sellar phase. The floor of the sella was first opened using a dissector and subsequently with Kerrison upcutting forceps. A cruciate incision was used to open the dura. The tumor/adenoma then protrudes through the incision and becomes apparent. The tumour was removed using two suction cannulas. Identification of normal pituitary tissue intraoperatively; Gentle irrigation was used to achieve hemostasis. Gelfoam and fibrin glue were used in some situations to pack sellars. The phases of the endoscopic process are depicted in Figure 1. The surgical field was checked for signs of a CSF leak. If a CSF leak was discovered, it was repaired. Merocele nasal packing (tampon). On the second day, the nasal packs were removed. Visual and hormonal problems are being monitored on a regular basis. On the second day after surgery, an MRI with contrast was performed on the brain.

Statistical Analysis: Following data collection, statistical analysis was carried out using EXCEL 2017 and SPSS software (version 15.0, SPSS, Inc.,

Chicago, Illinois). For the qualitative data, the data was provided as a frequency and a percentage. The mean, standard deviation, and range were used to characterize quantitative data. The Chi-square test was used to compare the mean and standard deviation of two sets of quantitative normally distributed data, and the Student's t-test was used to compare the mean and standard deviation of two sets of qualitative normally distributed data. When the p-value was less than 0.05, it was considered statistically significant, less than 0.01 was considered very significant, and less than 0.001 was considered highly significant.

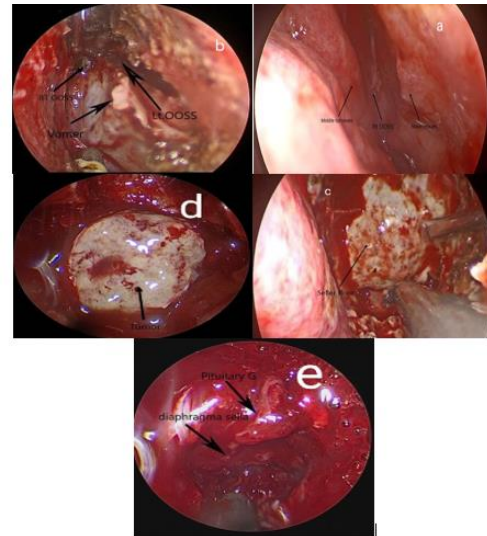


Fig 1: Various stages of the approach and tumour excision (a) nasal phase (b) sphenoidal phase (c) sellar phase (d) removal of the tumor (e) identification of intact pituitary tissue

RESULTS

Thirty patients were joined in this study, 16 men and 14 females, between the ages of 20 to 63 years with a mean age of 46.2 years with Pituitary tumor and underwent transsphenoidal surgery (Table 1).

Variables	Total No. of patients =30	
Age (Years)	20 – 63 years old	
Mean \pm SD	46.2 \pm 9.8	
	No.	%
Sex		
• Male	16	53.33 %
• Female	14	46.67 %

Table 1: Demographic data.

Table 2 shows that 66.67% of patients (20) had visual manifestations (diminution of vision), 80% (24) of patients had functioning adenoma (hormone secreting adenoma) (1 growth hormone, 2 Cushing's disease, 21 prolactinomas) and 83.33% of patients (25) had headache fig (2). 10% of patients (3) had microadenoma and 90% of patients (27) had macroadenoma regarding microadenoma <10mm and macroadenoma >10mm as shown in (Table 3).

The surgeon recognized intact vital pituitary tissue in 70 percent of patients (21) but failed to identify it in 30 percent of patients (9) as indicated in (Table 4; Fig 3).

Table 5 shows that 66.67% of patients (20) had radical tumor resection on postoperative MRI while 33.33% of patients (10) had remnant of tumor on postoperative MRI.

Clinical manifestations	Total no. of cases = 30	
	No.	%
Visual manifestations	20	66.67 %
Functioning (hormone secreting adenoma)	24	80%
- GH	1	3.33 %
- Cushing's disease	2	6.67 %
- Increased Prolactin	21	70 %
Headache	25	83.33%

Table 2: Clinical manifestations.

Tumor characteristics	Cases No.= 30	
Tumor size	No.	%
Microadenoma	3	10%
Macroadenoma	27	90%

Table 3: Tumor size.

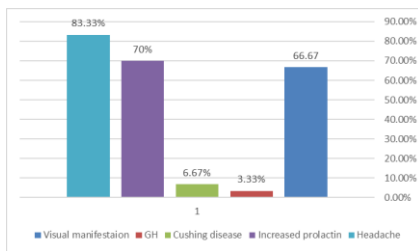


Fig 2: Tumor size.

Intraoperative identification of normal pituitary	Cases No.= 30	
	No.	%
Identified	21	70%
Failed to identify	9	30%

Table 4: Intraoperative identification of normal pituitary tissue.

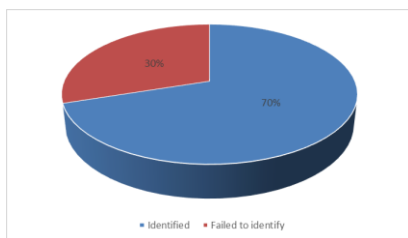


Fig 3: Intraoperative identification of normal pituitary tissue.

Radicality of the tumor on MRI follow up	Cases No.= 30	
	No.	%
Radical resection	20	66.67%
Remnant	10	33.33%

Table 5: Postoperative MRI radical resection of the tumor.

Table 6 reveals that normalization of hyper secretion (postoperative remission of hormone secreting adenomas) was achieved in 83.33 percent (20/24 patients). In four cases of massive prolactinoma, the patient was treated with dopamine agonists postoperatively. In addition, 85 percent (17/20) of patients had complete postoperative remission of visual problems. Postoperative relief was obtained for all headache sufferers.

Postoperative follow up of clinical manifestation	No.	%
Postoperative remission of hormone secreting adenomas (normalization of hyper secretion)	20 of 24	83.33%
Postoperative relief of visual symptoms	17 of 20	85%
Postoperative relief of headache	25 of 25	100%

Table 6: Improvement of clinical manifestation.

Seven patients (23.33 percent) developed a new postoperative endocrinological deficit, with substitution ADH due to persistent diabetic insipidus in five cases and cortisol substitution in two of these seven. There was no postoperative endocrinological impairment of the other pituitary axes in any of the patients. The surgeon discovered intact viable pituitary tissue in 70% (21/30) of patients intraoperatively. The postoperative hormonal status was intact in 20 of the 21 cases (95.24 percent) who had intact pituitary gland tissue identified intraoperatively. Only 4.76 percent (1 out of 21) of patients required postoperative hormone replacement. In two of the nine cases where intraoperative identification of gland tissue failed, a residual tumour was discovered on follow-up MRI. Three of the nine patients (33.33 percent) with failed intraoperative gland tissue identification had an intact postoperative hormonal state (66.67% (6 out of 9) required postoperative hormone replacement. In an endocrinological outcome, there was a significant association between the identification of the pituitary gland intra operatively and a normal pituitary function postoperatively (p 0.05) (Fig 4).

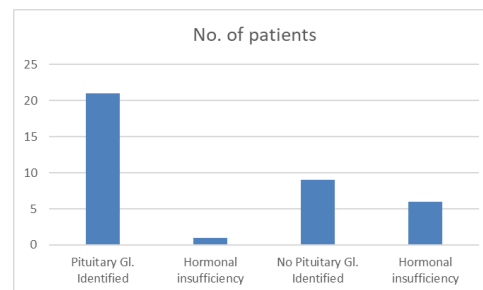


Fig 4: Intraoperative identification of normal pituitary tissue.

Case sample

29 years old male with headache and diminution of vision. visual acuity was 6/12 both eyes, bitemporal hemianopia while fundus examination was normal.

Hormonal abnormalities (prolactin 1000 ng/ml). MRI brain with contrast showed pituitary tuomer. Gross Total Resection was achieved by endoscopic endonasal transsphenoidal approach. Post-operative improvement of prolactin serum level which returned to normal level in 2 days after surgery and the visual disturbance improved postoperatively.

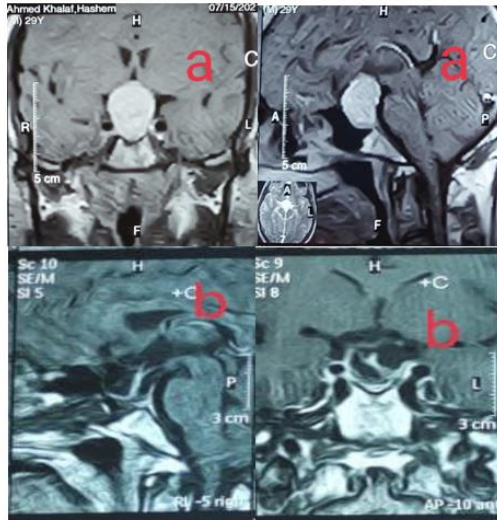


Fig 5: (A) Preoperative, sagittal and coronal contrast-enhanced T1-weighted MR images of a case of pituitary adenoma (B) Postoperative sagittal and coronal T1-weighted MR images of a case of pituitary adenoma after gross total Resection and pituitary gland was preserved.

DISCUSSION

Thirty patients were diagnosed with pituitary adenoma and underwent transsphenoidal surgery in this study. In terms of age, in our study the patients' mean age was 46.2 years ($SD \pm 9.8$), with a range of 20 to 63 years. In our analysis, the male to female ratio was 16 (53.33 percent): 14 (46.67 percent).

These findings are in line with previous research. In a large study comprising 305 surgeries, Jahangiri et al.,⁴ revealed that patients were statistically more likely to be older, male, and have bigger adenomas. Linsler et al.,⁵ investigated a patient population of 29 males and 41 females. The average age at the time of operation was 55.5 years, with a range of 21–87 years. Furthermore, there were 87 males and 66 females in the Li et al.,⁶ study with a mean age of 44.4 ± 30 years. The Galloway et al.⁷ study included 145 individuals who got ETSS for pituitary adenomas. The patients' median age at the time of surgery was 52 years (range 18–81 years). There were 145 patients in the cohort, 76 of whom were female and 69 of them were male.

In our study, 66.76 percent of patients (20 cases) had visual symptoms (diminished vision), 80 percent (24) of patients had functional adenoma (hormone secreting adenoma) (1 growth hormone, 2 Cushing's disease, 21 prolactinomas), and 83.33 percent of patients (25) had headache. In terms of preoperative

tumour size evaluation, 10% of patients (3) had microadenoma and 90% of patients (27) had macroadenoma, with microadenoma >10 mm and macroadenoma 10mm.

These findings back up previous study. Jahangiri et al.,⁴ performed 305 surgeries on 282 NFA patients over a 5 years period in a specialized pituitary surgical center. 295 patients were handled microscopically, and the remaining ten cases endoscopically. Preoperative endocrine abnormalities were present in 50% of their NFA patients. Sandow et al.,⁸ found a pituitary lesion (21 of 22 patients) in preoperative MR-imaging (mean diameter: 9 mm; SD 3.6; 6 macroadenomas, 15 microadenomas, 1 MR-negative) in 22 patients who qualified for transsphenoidal surgery and had a variety of clinical complaints (13 patients with acromegaly, 6 with Cushing, and 3 with other symptoms like vision disorder or dizziness).

Linsler et al.,⁵ evaluated 45 pituitary endocrine inactive macroadenomas. Twenty-five of the adenomas released hormones (10 prolactinomas, 8 growth hormone adenomas, and 7 Cushing's disease). The group had 13 microadenomas and 57 macroadenomas.

In terms of intraoperative identification of intact pituitary tissue, in our study, the surgeon recognised intact vital pituitary tissue in 70% (21) of patients while failing to identify it in 30% of patients.

These findings are consistent with earlier research. Linsler et al.,⁵ found that during tumour removal, the surgeon identified intact vital pituitary tissue in 82 percent (57/70) of cases. Furthermore, in the Linsler et al.⁹ experiment, 74% of gland tissue patients were correctly recognized using endoscopic visualization, but only 8% were correctly identified using microscopic inspection (P 0.05). According to Eljamel et al.,¹⁰ intraoperative optical identification of pituitary adenomas is a realistic and reliable approach of localizing pituitary adenomas during transsphenoidal surgery, and it may result in a higher cure rate and the preservation of normal pituitary functioning. Sandow et al.,⁸ carried out ICG VA during surgery on all 22 patients in their study. There were no technical failures or adverse events as a result of medicine delivery. Around 2.4 minutes after intravenous dosing, visualisation was at its peak.

In terms of tumour resection in postoperative MRI follow-up, in our study, 66.67% of patients (20) had radical tumour excision on postoperative MRI, while 33.33 percent of patients (10) had tumour remnant on postoperative MRI. In our study, normalization of hyper secretion (postoperative remission of hormonal secreting adenomas) was accomplished in 83.33 percent (20/24 cases). Postoperative dopamine agonists were given to four patients with large prolactinoma. In addition, 85 percent of patients (17/20) experienced complete postoperative remission of visual problems. All patients with headache had postoperative relief. In terms of postoperative consequences, there were no

occurrences of postoperative mortality, IC bleeding, IC infection, or worsening of visual impairments in our study. Three patients experienced intraoperative CSF leakage, which was successfully repaired with no persisting postoperative CSF leak. The majority of patients experienced transitory pituitary insufficiencies within the first 4–6 weeks. Postoperative hormonal insufficiency was discovered to be unique endocrinological disorder. Seven patients (23.33 percent) developed a new postoperative endocrinological deficit, with substitution ADH due to persistent diabetic insipidus in five cases and cortisol substitution in two of these seven. There was no postoperative endocrinological impairment of the other pituitary axes in any of the patients.

These findings are in line with previous studies. Arafah,¹¹ found that microscopic surgery increased pituitary function by 65% in a research with a relatively small sample size of 26 subjects. They concluded that surgery might lead to considerable improvements in pituitary function. Nomikos et al.,¹² analyzed a cohort of patients from 1982 to 2000 and reported that 30.1 percent of patients had better function following microscopic surgery. Neither report covers the extent of resection, the rate of recurrence, or the necessity for repeat surgeries.

The research by Laws et al.,¹³ is one of the only exclusively endoscopic series reported in the literature that contains both functional and NFA's. They present data from a smaller sample size of 80 patients. According to the study, 7.4 percent of the 27 patients who received preoperative HRT recovered. At the most recent follow-up, 2 (3.8 percent) of their 53 eupituitary patients had impaired pituitary function, whereas 5 (18.5 percent) of the 27 patients with abnormalities before to surgery had additional worsening of function postoperatively. According to the study, 7.4 percent of the 27 patients who received preoperative HRT recovered. At the most recent follow-up, 2 (3.8 percent) of their 53 eupituitary patients had impaired pituitary function, whereas 5 (18.5 percent) of the 27 patients with abnormalities before to surgery had additional worsening of function postoperatively.

Furthermore, according to Azad et al.,¹⁴ the chance of having DI postoperatively is greater in ETSS. Another research, Kim et al.,¹⁵ discovered that in the hands of a qualified surgeon, endoscopic surgery was a safe procedure for NFAs, even though their standard hormonal results did not differ from previous microscopic surgical series. Harary et al.,¹⁶ conducted a second endoscopic surgery trial in 2018 to investigate gland volume in relation to ETSS endocrine results. Their study concentrated on NFA patients who had had endoscopic surgery. 56.9 percent of patients had preoperative endocrine disorders in at least one anterior pituitary axis. In their patients with preoperative hypopituitarism, Harary et al.,¹⁶ report a full normalization rate of 37.4 percent and a 17.6 percent improvement rate. Furthermore, 37 (23.1%) of the patients have new disabilities. Linsler et al.,⁹ found no new

postoperative hormonal dysfunctions in these patients. According to Wang et al.,¹⁷ a recent international review and meta-analysis, pituitary function recovery after endoscopic surgery is highly varied. In the study of Galloway et al.,⁷ for NFA, based on postoperative MRI, the percentage of gross total resection (GTR) was 77%. During the follow-up period, seven patients (9%) had tumour recurrence, with five (6%) requiring repeat surgery. HRT was not required in 88 patients (61 percent) prior to surgery. During the most recent follow-up, 17 patients (19%) had a new endocrine issue that necessitated HRT. Six patients (11%) out of 57 on hormone replacement preoperatively had improved endocrine function and were able to cease hormone treatment across one or more axes postoperatively. In the same group of patients, 9 (16%) had declining endocrine function and required hormone replacement in one or more new axis. The preoperative deficit rates of each pituitary axis were documented. There were 29 patients (20%) with HPA axis dysfunction, 39 (27%) with thyroid axis dysfunction, 11 men (16%) and 7 females (9%) with gonadal axis dysfunction, and one patient with preoperative diabetic insipidus. Better vision in the endoscopic era, as stated by Galloway et al.,⁷ may allow for a more aggressive resection, perhaps causing more disruption to the remaining functioning pituitary gland.

The comparability of the outcomes across multiple series demonstrates the efficacy of the Endoscopic Endonasal Approach in pituitary surgery.

Pituitary gland identification and appropriate postoperative pituitary function are linked. There was a high correlation between intraoperative pituitary gland identification and postoperative pituitary function in endocrinological outcome in our study ($p < 0.05$). Intra operatively, the surgeon detected intact viable pituitary tissue in 70% (21/30) of patients. The postoperative hormonal status was normal in 20 of the 21 subjects (95.24 percent) who had intact pituitary gland tissue found intra operatively. Only 4.76 percent (1 out of 21) of patients required postoperative hormone replacement. In two of the nine cases where intraoperative identification of gland tissue failed, a residual tumour was discovered on follow-up MRI. Three of the nine patients (33.33 percent) with unsuccessful intraoperative gland tissue identification had a normal postoperative hormonal status (66.67 percent), whereas six of the nine (6 out of 9) required postoperative hormone replacement. The endoscopic approach's excellent visualization of the sellar area is the primary reason for the high likelihood of pituitary function preservation.

These findings are in line with previous studies. Linsler et al.,⁵ observed a significantly substantial link in endocrinological outcome between intraoperative pituitary gland identification and postoperative pituitary function. The postoperative hormonal status was normal in 55 of the 57 people (96.5 percent) who had intact pituitary gland tissue found intra operatively. Only 3.5 percent (2 of 57) of the patients required postoperative hormone

replacement. A persistent tumour was identified on follow-up MRI in three of the 13 cases when intraoperative identification of gland tissue failed. Seven of the thirteen patients (53.8%) who did not have intraoperative gland tissue identification had normal postoperative hormonal status. Sixty-two percent of patients (6 out of 13) required postoperative hormone replacement. Our findings are congruent with those of Laws et al.,¹³ who report a very low risk of hormone deficiency after endoscopic pituitary surgery. They found that the endoscope's superior eyesight over the microscope may enhance tumour distinction from normal glands and the maintenance of normal connections between tumour and pituitary stalk. Zhu et al.,¹⁸ and D'Haens et al.,¹⁹ discovered similar tendencies; as a result, it has long been assumed that increased magnification of intrasellar structures would result in better resection, a lower complication rate, and greater gland tissue and diaphragm preservation. The statistical disparity between our study and the other studies could be explained by our limited sample size.

CONCLUSION

Endoscopic transsphenoidal surgery can identify and maintain pituitary gland tissue and function, according to this study. The preservation of gland tissue predicts normal pituitary function after surgery. In terms of endocrinological outcomes, there is a significant correlation between intraoperative pituitary gland identification and proper pituitary function postoperatively. We recommend acquiring preoperative and intraoperative identification of normal pituitary tissue to minimize long-term surgical hormonal dysfunctions. The endonasal transsphenoidal endoscopic technique can aid in the improvement of surgical results.

REFERENCES

- Zhong A, Pu J, Ruan L, et al. The complications of endoscopic transsphenoidal surgery for pituitary neoplasms. *Int J Clin Exp Med*. 2016; 9(10), 20026-31.
- Dunn LK, Nemergut, E. CAesthesia for transsphenoidal pituitary surgery. *Current Opinion in Anesthesiology*. 2013; 26(5), 549-54..
- Zhao B, Wei YK, Li GL, et al. Extended transsphenoidal approach for pituitary adenomas invading the anterior cranial base, cavernous sinus, and clivus: a single-center experience with 126 consecutive cases. *Journal of neurosurgery*. 2010; 112(1):108-17.
- Jahangiri A, Wagner J, Han SW, et al. Morbidity of repeat transsphenoidal surgery assessed in more than 1000 operations. *Journal of neurosurgery*. 2014; 121(1): 67-74.
- Linsler S, Hero-Gross R, Sharif S, et al. Preservation of hormonal function by identifying pituitary gland at endoscopic surgery. *J Clin Neurosci*. 2017; 25:234-9.
- Li H, Feng C, Zhang C, et al. Microscopic surgery for pituitary adenomas to preserve the pituitary gland and stalk. *Experimental and therapeutic medicine*. 2017; 13(3): 1011-6
- Galloway L, Ali M, Lansdown A, et al. The impact of endoscopic transsphenoidal pituitary adenoma surgery on endocrine function: a single-centre study. *Acta Neurochirurgica*, 2021: 163(2):391-8.
- Sandow N, Klene W, Elbelt U, et al. Intraoperative indocyanine green videoangiography for identification of pituitary adenomas using a microscopic transsphenoidal approach. *Pituitary*. 2015; 18(5):613-20.
- Linsler S, Szameitat N, Senger S, et al. Visualization and identification of the pituitary gland tissue in Endonasal pituitary surgery: is there a difference between high-definition endoscopy and microscopy. *World neurosurgery*. 2018; 116: 921-8.
- Eljamel MS, Leese G and Moseley H. Intraoperative optical identification of pituitary adenomas. *Journal of neuro-oncology*. 2009; 92(3), 417-21.
- Arafah BM. Reversible hypopituitarism in patients with large nonfunctioning pituitary adenomas. *J Clin Endocrinol Metab*. 1986; 62(6):1173-9
- Nomikos P, Ladar C, Fahlbusch R, et al. Impact of primary surgery on pituitary function in patients with nonfunctioning pituitary adenomas – a study on 721 patients. *Acta Neurochir*. 2004; 146(1):27-35.
- Laws ER, Iuliano SL, Cote DJ, et al. A benchmark for preservation of normal pituitary function after endoscopic transsphenoidal surgery for pituitary macroadenomas. *World neurosurgery*. 2016; 91: 371-5.
- Azad TD, Lee YJ, Vail D, et al. Endoscopic vs. microscopic resection of sellar lesions-a matched analysis of clinical and socioeconomic outcomes. *Front Surg*. 2017; 4:33.
- Kim JH, Lee JH, Lee JH, et al. Endoscopic transsphenoidal surgery outcomes in 331 nonfunctioning pituitary adenoma cases after a single surgeon learning curve. *World neurosurgery*. 2018; 109: 409-16.
- Harary M, DiRisio AC, Dawood HY, et al. Endocrine function and gland volume after endoscopic transsphenoidal surgery for nonfunctional pituitary macroadenomas. *J Neurosurg*. 2018; 1-10.
- Wang EW, Zanation AM and Gardner PA. ICAR: endoscopic skull-base surgery. *Int Forum Allergy Rhinol*. 2019; 9(3):145- 365.
- Zhu M, Yang J, Wang Y, et al. Endoscopic transsphenoidal surgery versus microsurgery for the resection of pituitary adenomas: a systematic review. *Chinese Journal of Otorhinolaryngology Head and Neck Surgery*, 2014; 49(3): 236-9.
- D'Haens J, Van Rompaey K, Stadnik T, et al. Fully endoscopic transsphenoidal surgery for functioning pituitary adenomas: a retrospective comparison with traditional transsphenoidal microsurgery in the same institution. *Surgical neurology*. 2009; 72(4), 336-40.