

## A Retrospective Study that Evaluates Reconstruction of Orbital Floor Fractures with Titanium Mesh and Cartilaginous Graft

HALA N. MOHMED, M.B.B.CH.; AMR R. MABROOK, M.D.; HANY S. SETTA, M.D. and EBRAHIM M. AMIN, M.D.

*The Department of Plastic Surgery, Faculty of Medicine, Ain Shams University*

### ABSTRACT

**Background:** Orbital floor fractures represent a challenge for reconstruction. Various treatment techniques had evolved over the past years, each with its weaknesses and strengths. The surgical repair mainly aims to relocate herniated orbital contents back into the orbit for restoration of both the function and aesthetic aspect. Reconstruction of orbital floor can be achieved using various types of materials, either autologous graft as cartilage grafts or alloplastic material as titanium mesh.

**Aim of the Study:** The aim of this retrospective study is to evaluate the results of using autologous conchal cartilage grafts and synthetic titanium mesh in posttraumatic orbital floor defects reconstruction & to determine the most preferable material for different sizes of the defect.

**Patients and Methods:** 40 patients were selected from the database of Ain shams University Hospitals with orbital floor fractures that were surgically treated at the Plastic & Reconstructive Surgery Department over the past 5 years. Cases were retrospectively reviewed by preoperative clinical findings, surgical management and postoperative sequelae. The study evaluated timing, surgical outcomes, and complications of materials used for orbital reconstruction & their effect on the choice of the appropriate method used for reconstruction.

**Results:** In total, there were (40) cases of orbital floor defects that were surgically treated with an average age of (29.2) years. Isolated blow-out fractures represent 30% of cases while fractures of inferior orbital rim associated with orbital floor fractures were 70%. Cartilage graft was used in 16 cases for floor reconstruction while 24 cases were managed by titanium mesh. In the follow-up, 2 patients were complaining of mild enophthalmos, while 6 patients were complaining of mild diplopia.

**Conclusion:** Reconstruction of orbital floor defects using cartilage grafts represents a safe and reliable method for reconstruction with less complication in small-sized defects less than 2.5cm<sup>2</sup>, while titanium mesh was the best for larger bone surface defect more than 2.5cm<sup>2</sup> of the orbital floor bony surface.

**Key Words:** Orbital – Defects – Cartilage - Graft – Titanium – Mesh.

**Disclosure:** No conflict of interest.

### INTRODUCTION

Orbital floor fractures are considered of the most common maxillofacial injuries lately owing to increased incidence of interpersonal violence, road traffic accidents, sports activities, and assault. It is also used to be one of the commonest maxillofacial traumas with surgical importance due to its relation to the eye globe, so, it may affect ocular motility and visual acuity [1].

Fractures of the bony orbit may occur alone or as a part of complex facial fractures. Isolated fractures of the floor may occur without associated fracture of the orbital rim [3].

Since 1844 [1], countless studies have discussed the indications and most appropriate time for surgical intervention as well as the most suitable surgical modality to be used for orbital blowout fractures.

As these fractures may cause significant functional and cosmetic complications, such as hypoaesthesia or paraesthesia through the infraorbital nerve, diplopia, enophthalmos, limited ocular motility especially upward movement due to inferior rectus muscle entrapment and ocular injuries [2,6,8]. So far, numerous studies have been conducted to investigate the indications and best timing for surgical intervention, as well as the best surgical modality for reconstruction [3,7].

Various options of reconstruction were used over the past years which may be autologous as bone & cartilage graft or synthetic as titanium mesh & medpor implant. But in this study, we are going to focus on the use of conchal cartilage & titanium mesh as modalities of orbital floor reconstruction.

Autologous grafts are readily available for harvesting from its donor site, easily shaped to

precisely match the dimensions of the defect to provide structurally intact support for the underlying tissues and structures. It is usually easier to harvest and shape cartilage, which provides a significant contribution to long-term support without resorption [5]. So cartilage grafts were used in different studies as described by Vaanmugil et al., [11].

On the other hand, titanium mesh had been considered in other studies as the gold standard management for orbital floor fracture as it gives the firm structural support needed in reconstruction of the orbital defect, available without donor site morbidity & being totally synthetic gives it the advantage to contribute to long-term support without resorption or the need to blood supply to survive [18].

The main aim of our retrospective study is to evaluate the outcomes of using autologous cartilage graft with those of synthetic titanium mesh in posttraumatic orbital floor defects reconstruction.

#### PATIENTS AND METHODS

40 patients with orbital floor fractures either isolated or as part of midface fractures, were included in this study. All patients underwent treatment at the Department of Plastic & Reconstructive Surgery, Ain Shams University Hospitals. The patient's data were extracted from hospital records between January 2015 and December 2019. The study was approved by the Ethical Committee of Faculty of Medicine.

The patients were retrospectively analyzed for materials used for reconstruction, pre-operative symptoms, post-operative complications & other factors that could affect the reconstruction of the defect as gender, age, mode of trauma, the timing of surgical intervention and surgical approaches & studied the effect of each on the choice of the reconstruction method. The diagnosis was based on clinical presentation and computed tomography (CT) scans of the orbital floor defects. All patients were ophthalmologically examined for assessment of any problem in visual acuity, any change in pupil size, and ocular motility on the day of admission, pre-operative, post-operative, and during follow-up in all cases.

All patients were examined by high resolution multi-slice computed tomography (CT), evaluated with coronal and sagittal images (Fig. 1A,B) of the floor displacement preoperatively. CT scans were performed with 1-mm thickness contiguous slice section under bone window settings. An open source image-processing software (OsiriX, CA)

was used in each patient to reconstruct and manipulate CT scan data.

The CT soft tissue window allowed us to identify the herniation of the orbital fat and the entrapment of the extra-ocular muscles with special regard to the inferior rectus and presence of foreign bodies. We classified orbital floor defects into two types: Small and large. Our classification was based upon the measurements of the bony defect area performed on the coronal and sagittal scans. The method applied consists of depicting two lines corresponding to the fractured floor, calculating the mean value obtained from the higher and the lower line on each view (Fig. 1A,B). The elliptical area was calculated by multiplying the width (C on coronal view) and the length (S on sagittal view), then multi-plying the result by constant ( $\pi$ ) (Fig. 1C).

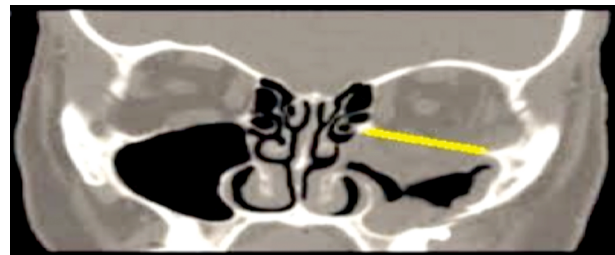


Fig. (1A): Computed tomography scan, coronal view with superior and inferior measurements (C) of the bone defect.



Fig. (1B): Computed tomography scan, sagittal view with superior and inferior measurements (S) of the bone defect.

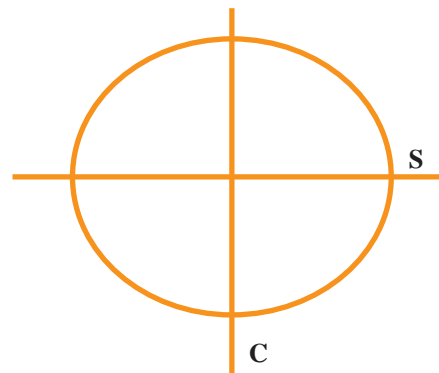


Fig. (1C): Schematic drawing of the orbital floor defect measurements that we evaluate using the radiological data based on coronal (C) and sagittal (S) views, used to obtain the area of the fracture, according to the mathematical formula (width x length x  $\pi$ ).

We had classified the orbital defects as "small" when the fractures with an area of bony defect less than 2.5cm<sup>2</sup>, and "large" with an area more than 2.5cm<sup>2</sup>. All cases were managed by reconstructive surgeries. The indications for surgery were determined by the presence of different ocular symptoms, such as diplopia, enophthalmos, ocular motility disturbance, infraorbital bony stepping, orbital deformity, as well as orbital soft tissue herniation & bony defect in the CT scan (Fig. 1). Patients with medical instability, retinal tear, globe perforation, and intensive care admission were delayed for surgical repair.

All operations were done by plastic surgeons; where three different surgical approaches for orbital floor reconstruction were used; subciliary, transconjunctival, and existing wound incisional approaches (Fig. 2). Forced duction test was done for all cases intraoperatively to confirm the full movement of

the eye globe in all directions and full correction of muscular entrapment.

Orbital floor reconstruction was indicated when affecting more than 10% of orbital floor either by the use of titanium mesh or autogenous conchal cartilage graft (Fig. 3A,B). The sequelae remained after surgery was recorded and patients were followed by clinical data and CT scan data for up to one year.

Data entry and statistical analyses were performed using SPSS (statistical package of social sciences) version 20.0 (SPSS Inc., Chicago, IL, USA). Categorical variables were evaluated using the Chi-square test. In addition, the Kruskal Wallis test (z) was used to compare nonparametric continuous clinical variables in three different groups. *p*-value <0.05 was considered statistically significant.

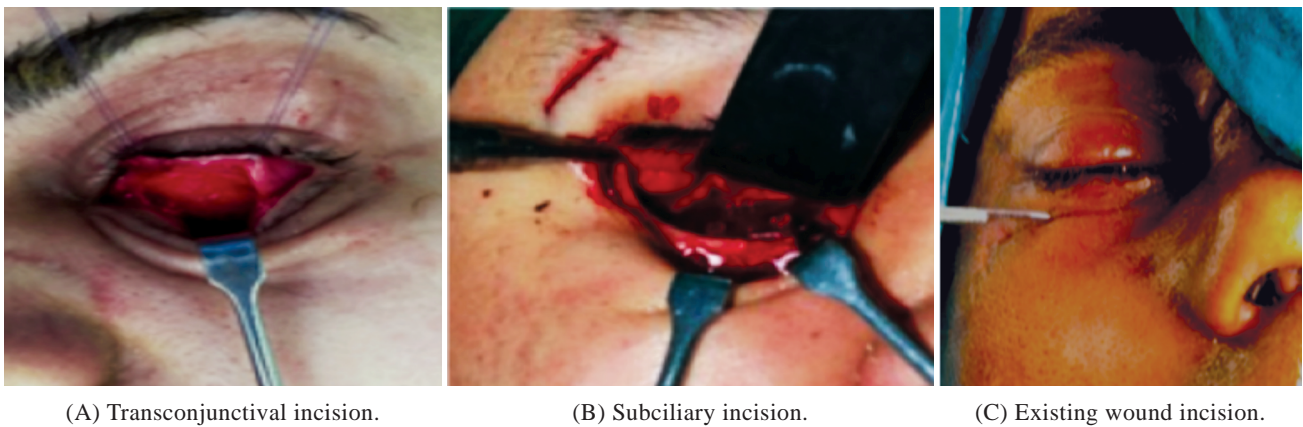


Fig. (2): Different surgical approaches for orbital floor fractures.

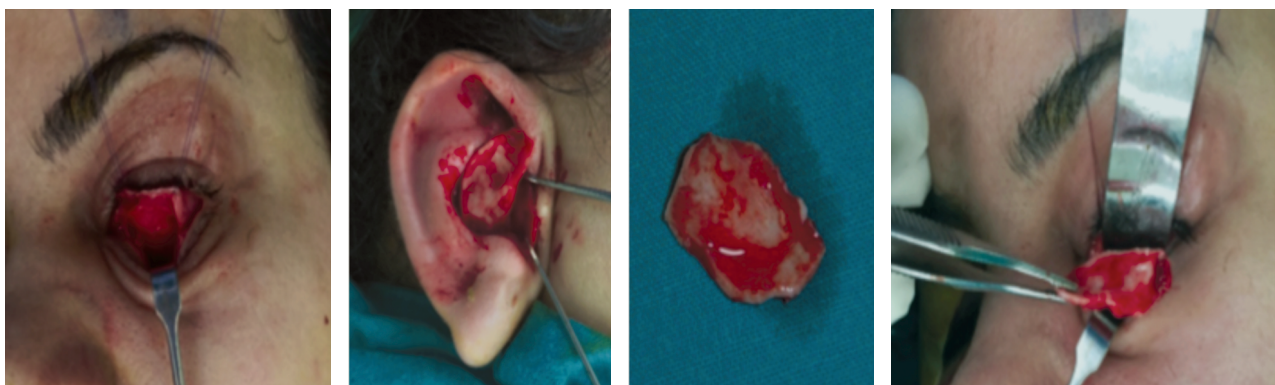

Fig. (3A): Conchal Cartilage Graft Harvesting & application.

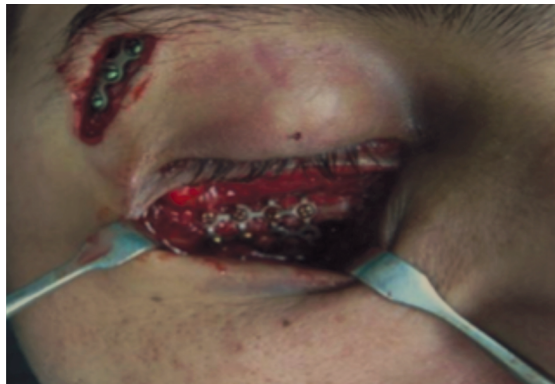

Fig. (3B): Reconstruction with titanium mesh.



Titanium mesh.

Fig. (3): Orbital floor reconstruction with titanium mesh. (A & B).

### RESULTS

The study included 40 cases. Males accounted for 82.5% (n=33), while females accounted for 17.5% (n=7). The mean age of the included cases as a whole was 29.2 years. Thirty percent of cases (12/40) presented with pure orbital floor fractures, while 70% (28/40) were associated with other fractures. Orbital wall fractures were associated with orbital floor fractures in 37.5% of all cases (15/40). Other maxillofacial fractures as zygomatic fractures were 25% (10/40), maxillary fractures were 15% (6/40), frontal bone fractures were 12.5% (5/40) and mandibular fractures were 10% (4/40) (Fig. 4).

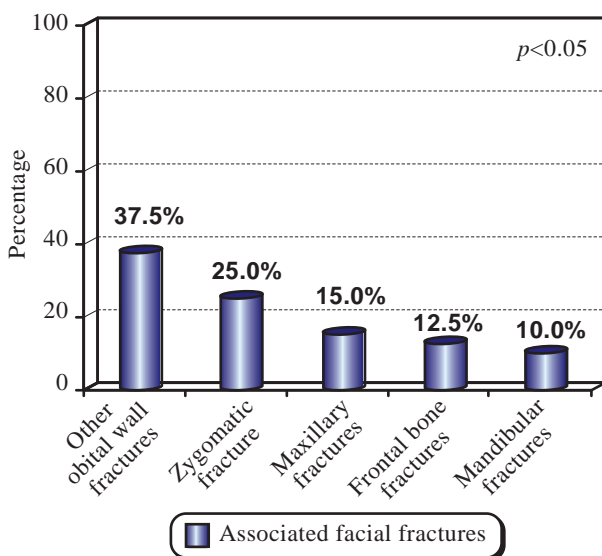


Fig. (4): Associated facial fractures.

The average postoperative hospitalization duration was 3 days till edema was relieved and postoperative ophthalmological examination was performed for visual acuity and ocular motility,

the follow-up period was 8.2 months (6 months to 1 year). Conchal graft was used to reconstruct orbital floor defect in 40% (16 cases) subdivided into 9 cases with small-sized defect & 7 cases of the large-sized defect while 60% (24 cases) were managed by titanium mesh all of them were of large size while only 2 cases were of the small-sized defect.

The most common pre-operative complaints were enophthalmos in 31 patients (77.5%). Enophthalmos improved in 29 patients (71%) postoperatively while 2 patients (6.5%) still complaining of enophthalmos, paraesthesia of the ipsilateral infraorbital nerve in 30 patients (75%) which improved in 26 patients (61.7%) while the remaining 4 patients (13.3%) still having this complaint. The third common complaint was Diplopia which was the complaint of 24 patients (60%), postoperatively 4 (10%) of patients were still complaining of diplopia. The fourth common complaint was limited ocular motility in different directions was observed in 11 patients (27.5%) divided as follows (upward limited ocular motility in (20%) - limited adduction in (2.5%) - limited abduction in (5%). Postoperatively only one case of the patients still having a minimal degree of limited ocular motility but without affection of visual acuity. The last common complaint was hypoglobus in 10 patients (25%) which only reported postoperative by one case also with a mild degree.

Titanium mesh was used in 24 patients while conchal graft was used in 16 patients (Table 1). In patients managed by titanium mesh; the most common signs were enophthalmos (91.7%), infraorbital hypoesthesia (75%), pre-operative diplopia (66.7%), limited upward ocular motility (25%), and limited abduction (8.3%). In patients managed

by conchal graft; (75%) of patients had infraorbital hypoesthesia, (56.3%) complained of enophthalmos, and (50%) with pre-operative diplopia. Also,

1 (6.3%) had limited upward ocular motility, 1 patient (6.3%) with limited abduction, and 1 patient (6.3%) with limited adduction.

Table (1): Comparison between titanium mesh & conchal graft.

	Titanium mesh N=24		Conchal graft N=16		p-value
<i>Pre-operative:</i>	Large defect 22/24	Small defect 2/24	Large defect 7/16	Small defect 9/16	
Enophthalmos	20 (83.3%)	2 (8.3%)	7 (43.8%)	2 (12.5%)	0.4
Diplopia	15 (62.5%)	1 (4.2%)	6 (37.5%)	2 (12.5%)	0.5
Infraorbital hypoesthesia	16 (66.7%)	2 (8.3%)	7 (43.7%)	5 (31.2%)	0.6
<i>Limited ocular motility:</i>	8 (33.3%)		3 (18.8%)		
Adduction	0 (0.00%)	0 (0.00%)	1 (6.3%)	0 (0.00%)	0.3
Abduction	1 (4.2%)	1 (4.2%)	1 (6.3%)	0 (0.00%)	
Upward	5 (20.8%)	1 (4.2%)	1 (6.3%)	0 (0.00%)	
<i>Post-operative:</i>					
<i>Enophthalmos:</i>					
Improved	20 (83.3%)	2 (8.3%)	5 (31.3%)	2 (12.5%)	0.06
Not improved	0 (0%)	0 (0%)	2 (12.5%)	0 (0%)	
<i>Diplopia:</i>					
Improved	14 (58.3%)	1 (4.2%)	3 (18.8%)	2 (12.5%)	0.2
Not improved	1 (4.2%)	0 (0%)	3 (18.8%)	0 (0%)	
<i>Infraorbital hypoesthesia:</i>					
Improved	14 (26.7%)	2 (8.3%)	5 (26.3%)	5 (31.2%)	0.2
Not improved	2 (8.3%)	0 (0%)	2 (12.5%)	0 (0%)	
Limited ocular motility	7 (29.2%)		3 (18.8%)		0.1

N: Number of cases. \*p-value is considered statistically significant <0.05.

## DISCUSSION

Orbital injury is considered one of the common maxillofacial traumas with surgical significance. Management of the orbital floor fracture primarily aimed at restoring the orbit's original shape and volume, repositioning its contents, and recovering the optimum ocular motility. This retrospective study was done on 40 patients with orbital floor fractures admitted in the duration between January 2015 and December 2019.

The age range of the included cases was between (a minimum of 2 years, a maximum of 76 years). The peak incidence emerged in the 2nd decade. Adult patients (>18 years) represented 62.5% (25/40). So, pediatric patients were counted 37.5% (15/40). According to Biesman's research, the average age of included cases was 27.5 years [9]. In another study done by Beige, the patients had a mean age of 37 years (range 7-91 years) [10]. All pediatric patients were managed by conchal cartilage grafts as the surgeons preferred to permit better orbital bone growth without any restriction in contrast to adults where the growth is very slow so it is not affected by the type of implant. That agreed with the study conducted by Chen, which showed that the orbital volume grows rapidly before 20 years & becomes slowly till 40 years so

cartilage graft is preferred in pediatric patients regardless of the size of the defect [12,13].

Impure orbital floor fractures were the most frequent type in 70% of all cases who presented with other maxillofacial fractures as follows; zygomatic fractures were 25% (10/40), maxillary fractures were 15% (6/40), frontal bone fractures were 12.5% (5/40) and mandibular fractures were 10% (4/40) (Fig. 4), while pure orbital floor fractures were 30% of cases. These results by fare matched Gosau et al., in his study, there were 53.8% of patients (n=102) had zygomatic fractures with orbital floor affection, and 26.6% (n=50) had complex midface fractures [9]. Most blowout fractures occur along the thin floor of the orbit. But coming to the medial wall and orbital roof blowout fractures were less common [4].

Reconstruction of orbital floor defect and restoration of volume can be performed using various types of materials, either autologous as bone grafts, cartilage grafts, and fat grafts or alloplastic as titanium mesh and medpor implant [19-22]. But the concomitant fractures as zygomatic & other bone fractures were surgically managed by plates and screws. This was supported by other studies in literature [14-17].

Using a mathematical formula to calculate the oval area based on sagittal and coronal data obtained by CT scans, we estimated the area of the fracture to be repaired [19]. Large sized defect was defined as any orbital bony surface defect measure more than 2.5cm of the orbital floor as mentioned by Eman et al., also small size defect was defined as any orbital bony surface defect measure equal to or less than 2.5cm of the orbital floor as mentioned by Eman et al., [1].

Considering our study; orbital floor reconstructed using either titanium mesh or cartilage grafts. The commonly used material was titanium, used in 24 cases (60%) where 22 cases of them were of large-sized defect & only 2 cases had small size defect as they were old age with comorbidities so surgeons preferred the mesh to decrease the surgical time, while conchal cartilage graft were used in 16 cases (40%), some of them were of the small-sized defect (9 cases) others were of large-sized defect (7 cases), but all of them were pediatric patients.

There was a significant improvement as regard the improvement of limited ocular motility & diplopia by the use of both titanium mesh and conchal graft. In the current study (Table 1), enophthalmos was improved in all cases managed by titanium mesh while in patients with large-sized defects managed by cartilage graft, 2 patients still complaining of enophthalmos; one had been re-operated after 6 months. This may be attributed to subsequent fibrosis and remodeling, otherwise, all cases with small-sized defects reconstructed with cartilage graft were totally improved.

Despite the advantage of having the highest tensile strength, easily bending, and being compatible with radiographic imaging with a low risk of infection, titanium mesh had a limited role in the reconstruction of small size defects in this study (only used with 2 cases) as surgeons preferred using it in large orbital defects measuring  $>2.5\text{cm}^2$ , this may be attributed to the high cost of the mesh for most of the patients [22-24]. This goes with the study done by Elgayar et al., who preferred the use of titanium mesh in large-sized defects in 14 cases with a complete improvement of diplopia, enophthalmos & correction of orbital movement [20].

A study by Kruschewsky also supports our preference in using concha than mesh in small-sized orbital defects as it is available, easily shaped, inert with no reaction, rarely associated with infection, less harmful to orbital soft tissues and due to low socioeconomic standard in many cases as it is

a cheap material for reconstruction [24]. Also, a scar for auricular cartilage can be hidden with the use of the posterior approach.

About the surgical site morbidity; which is one of the most common problems of autogenous grafts there were no recorded surgical site complications in the participating cases.

Sex, mode of trauma, surgical approaches & timing of repair showed no statistical significance in the choice of the method of reconstruction.

#### *Recommendations:*

- Cartilage graft is better used in small sized defects (with bone surface defect less than 2.5cm) & pediatric patients regardless of the defect size.
- Titanium mesh is best used with large sized defects (bone surface defect more than 2.5cm).

Limitations of this study are the lack of consecutive data for longer periods or an equal number of patients at each group for better evaluation and statistical data based on complication rates.

#### *Conclusion:*

Cartilage graft was seen by our surgeons to be the implant of choice as compared with titanium mesh which is very expensive- for the repair of small sized orbital floor defects ( $<2.5\text{cm}^2$ ) as it has the advantages of being an inert substance, cheap, readily obtainable especially conchal graft taken with a posterior approach, could be adapted to the orbital floor and adequate for reconstruction with good functional & aesthetic outcome. In large-sized defects ( $>2.5\text{cm}$ ) & despite being inert & giving reasonable results cartilage graft only used with pediatric patients as they have a rapidly growing orbital bone which could be restricted with mesh usage, otherwise the best implant for large sized defects was titanium mesh as it offers the optimum hardness needed in these cases with no risk of donor site morbidity.

Apart from the defect size; the peak incidence of orbital floor fractures in the 2<sup>nd</sup> decade and age should be considered during implant selection to avoid orbital growth restriction.

## REFERENCES

- 1- Mohamed E.N., Setta H.S. and El Shahat A.: Comparative study between conchal cartilage grafts and split rib grafts in the reconstruction of orbital floor fractures. The Egyptian Journal of Plastic and Reconstructive Surgery, 42 (2): 273-277, 2018.
- 2- Dubois L., Steenen S.A., Gooris P.J.J., Mourits M.P. and Becking A.G.: Controversies in orbital reconstruction-I. Defect-driven orbital reconstruction: A systematic review.

- International Journal of Oral and Maxillofacial Surgery, 44 (3): 308-315, 2015.
- 3- Bachelet J.T., Cordier G., Porcheray M., Bourlet J., Gleizal A. and Foletti J.M.: Orbital reconstruction by patient-specific implant printed in porous titanium: A retrospective case series of 12 patients. *Journal of Oral and Maxillofacial Surgery*, 76 (10): 2161-2167, 2018.
  - 4- Park M.S., Kim Y.J., Kim H., Nam S.H. and Choi Y.W.: Prevalence of Diplopia and Extraocular Movement Limitation according to the Location of Isolated Pure Blowout Fractures. *Arch. Plast. Surg.*, 39 (3): 204-8, 2012.
  - 5- Esmail M.E.K., Ibrahim M.F.K., Abdelrahman R.M., Elshafei A.M.K. and Gawdat T.I.: Orbital Floor Fractures: A review of different management options, 2020.
  - 6- Catherine Z., Courvoisier D.S. and Scolozzi P.: Is the pure and impure distinction of orbital fractures clinically relevant with respect to ocular and periocular injuries? A retrospective study of 473 patients. *Journal of Cranio-maxillo-facial Surgery: Official Publication of the European Association for Cranio-maxillo-facial Surgery*, 47: 1935-1942, 2019.
  - 7- Bartoli D., Fadda M.T., Battisti A., Cassoni A., Pagnoni M., Riccardi E., Sanzi M. and Valentini V.: Retrospective analysis of 301 patients with orbital floor fracture. *J. Craniomaxillofac. Surg.*, 43: 244-247, 2015.
  - 8- Gosau M., Schöneich M., Draenert F.G., Ettl T., Driemel O. and Reichert T.: Retrospective analysis of orbital floor fractures-complications, outcome, and review of literature. *Clin. Oral Investig.*, 15: 305-313, 2011.
  - 9- Biesman B.S., Hornblass A., Lisman R. and Kazlas M.: Diplopia after surgical repair of orbital floor fractures. *Ophthalmic Plast. Reconstr. Surg.*, 12 (1): 9-16; discussion, 17, 1996.
  - 10- Beigi B., Khandwala M. and Gupta D.: Management of pure orbital floor fractures: A proposed protocol to prevent unnecessary or early surgery. *Orbit*, 33 (5): 336-42, 2014.
  - 11- Vaanmugil J., Jimson S., Bhanumurthy L., Arunprakash M. and Kandasamy R.: Conchal Cartilage in Surgical Reconstruction of Orbital Floor Fracture. *Cureus*, 13 (2): 2021.
  - 12- Chen Z., Zheng X.H., Xie B.J., Yuan J.J., Yu H.H. and Li S.H.: Study on the growth of orbital volume in individuals at different ages by computed tomography. *Zhonghua Yan Ke Za Zhi*, 42 (3): 222-5, 2006.
  - 13- Venugopal M.G., Sinha R., Menon P.S., Chattopadhyay P.K. and Roy Chowdhury S.K.: Fractures in the Maxillo-facial Region: A Four Year Retrospective Study. *Med. J. Armed Forces India*, 66 (1): 14-7, 2010.
  - 14- Safi A.F., Richter M.T., Rothamel D., Nickenig H.J., Scheer M., Zöller J. and Kreppel M.: Influence of the volume of soft tissue herniation on clinical symptoms of patients with orbital floor fractures. *J. Craniomaxillofac. Surg.*, 44 (12): 1929-1934, 2016.
  - 15- Wu C.M., Chen Y.A., Liao H.T., Chen C.H., Pan C.H. and Chen C.T.: Surgical treatment of isolated zygomatic fracture: Outcome comparison between titanium plate and bioabsorbable plate. *Asian J. Surg.*, 41: 370-376, 2018.
  - 16- Rosado P. and de Vicente J.C.: Retrospective analysis of 314 orbital fractures. *Oral Surg. Oral Med. Oral Pathol. Oral Radiol.*, 113 (2): 168-71, 2012.
  - 17- Wang S., Xiao J., Liu L., Lin Y., Li X., Tang W., Wang H., Long J., Zheng X. and Tian W.: Orbital floor reconstruction: A retrospective study of 21 cases. *Oral Surg. Oral Med. Oral Pathol. Oral Radiol. Endod.*, 106: 324-330, 2008.
  - 18- Chattopadhyay C., Dev V., Pilania D. and Harsh A.: Reconstruction of Orbital Floor Fractures with Titanium Micromesh: Our Experience. *Journal of Maxillofacial and Oral Surgery*, 1-10, 2020.
  - 19- Piombino P., Iaconetta G., Ciccarelli R., Romeo A., Spinzia A. and Califano L.: Repair of orbital floor fractures: Our experience and new technical findings. *Cranio-maxillofacial Trauma & Reconstruction*, 3 (4): pp. 217-221, 2010.
  - 20- Elgayar H., Shouman O.O., Abdelhalim M.M., Abbas A. and Zeina A.M.: Retrospective Analysis of the Outcomes in Orbital Floor Fractures: Guidelines for Better Strategic Management. *The Egyptian Journal of Plastic and Reconstructive Surgery*, 45 (1): 49-58, 2021.
  - 21- Ghareeb F.M., Amin M., Eissa A., Eissa W. and Tharwat A.: Differential Volumetric Orbital Restoration (DVOR) for Correction of Traumatic Ocular Malposition. *Ann. Plast. Reconstr. Surg.*, 2 (2): 1017, 2018.
  - 22- Düzgün S. and Sirkeci B.: Comparison of post-operative outcomes of graft materials used in reconstruction of blow-out fractures. *Ulus Travma Acil Cerrahi Derg.*, 26: 538-544, 2020.
  - 23- Avashia Y.J., Sastry A., Fan K.L., Mir H.S. and Thaller S.R.: Materials used for reconstruction after orbital floor fracture. *Journal of Craniofacial Surgery*, 23 (7): S49-S55, 2012.
  - 24- De Souza Kruschewsky I., Novais T., Daltro C., Branco B.C., Lessa M., Kruschewsky M.B. and De mellofilho F.V.: Fractured orbital wall reconstruction with an auricular cartilage graft or absorbable polyacid copolymer. *J. Craniofac. Surg.*, 22: 1256-1259, 2011.