
Evaluation of Gestational Sac Diameter, Crown Rump Length, Yolk Sac Diameter and Fetal Heart Rate in Early Detection of Congenital Fetal Malformation

Rehab Abdelhamid Aboshama¹,
Laila Ezzat Abdelfattah²,
Abdelsamie A. Abdelsamie³,
Aalaa A. Abdelghany⁴ and
Mohamed K Etman⁵
1-Lecturer of Obstetrics and
Gynecology, Faculty of
Medicine, Fayoum University,
Egypt
2-Associate professor of
Obstetrics and Gynecology,
Faculty of Medicine, Fayoum
University.
3-Professor of Obstetrics
and Gynecology, Faculty of
Medicine, Fayoum University.
Egypt
4-Resident of Obstetrics
and Gynecology, Faculty of
Medicine, Fayoum University.
Egypt
5-Associate professor of
Obstetrics and Gynecology,
Faculty of Medicine, Fayoum
University.

Corresponding author:

LAILA EZZAT, M.D. The Department
of Obstetrics and Gynecology,
Faculty of Medicine, Fayoum
University, Fayoum, Egypt
Lailaezzat972000@gmail.com

Abstract

Congenital abnormalities impact 3% to 5% of all pregnancies, and they are the leading cause of newborn death. The majority are caused by unknown factors, with pregnancy being the sole risk factor. However, in both affluent and developing nations, they are responsible for rising newborn fatalities.

Aim of the study: The purpose of this study was to see whether there was a link between Gestational sac diameter, crown rump length, yolk sac diameter and fetal heart rate in detection of early congenital fetal malformation.

Patients and methods: our research included 100 pregnant women who were scanned using 2d ultrasonography beginning in the first trimester, with the first scan taking place between 6 and 8 weeks. at 18-22 weeks, a follow-up scan was performed. the first trimester's outcome was documented.

Results: Among cases, 77 (77%) had a normal pregnancy, 20 (20%) had an early miscarriage, 3 (3%) had congenital fetal malformation. a statistically highly significant difference between a normal, early miscarriage and congenital fetal malformation results of scan regarding yolk sac shape ($p < 0.001$). in our research, a small, irregular, calcified, or big yolk sac was a significant predictive factor in pregnancy outcome.

Conclusion: there was a strong link between gestational sac diameter, yolk sac shape and diameter, CRL, and fetal heart rate in pregnancies that ended in a normal first trimester.

Keywords: Gestational sac, crown-rump, yolk sac, fetal heart rate, scan, congenital fetal malformation

Introduction

Pregnancy is one of the marvelous events which a woman experiences in her life and the reality of her whole life. The first trimester is a vital time as the pregnancy gets established. It was concluded that ultrasonography (US) plays an important role in differentiating normal from abnormal pregnancies and, therefore, accurately predicting it is normal or not(1).

Antenatal care must include screening for fetal structural and chromosomal abnormalities(2). Congenital fetal abnormalities, uteroplacental circulation insufficiency, and preterm delivery are the most important causes of perinatal death. Therefore, the significance of ultrasound examination during pregnancy cannot be overstated because fetal abnormalities and placental insufficiency may be detected early in pregnancy(3).

Sonographically, the intrauterine gestational sac is the first to show up, followed by the yolk sac, then the fetal pole with heart activity. The yolk sac is the earliest visible embryonic structure inside the gestational sac(4). Various authors have described numerous sonographic signs to predict pregnancy outcomes. For example, an abnormally big, tiny, or irregularly shaped gestational sac, a low implantation site, a large or irregular yolk sac, a poor decidual response, and a sluggish embryonic heart rate were among the symptoms identified by him (5).

A fetal ultrasound scan is performed between 18 and 22 weeks of pregnancy to establish a baseline against which subsequent scans may be compared to assess development and health. This time frame strikes a balance between accurately timing the pregnancy (which would be more accurate if done earlier) and detecting severe congenital abnormalities on time (2).

Aim of the study: The purpose of this study was to see whether there was a link between Gestational sac diameter ,crown rump length, yolk sac diameter and fetal heart rate in detection of early congenital fetal malformation.

Patients and methods

Study design:

A prospective cohort study.

Study population:

Sample Size (number of participants included): 100 patients

Inclusion criteria:

All pregnant women are in their first trimester of pregnancy at 6-8 weeks of pregnancy.

Exclusion criteria:

- Pregnant women below 18 and above 35 years old.
- Pregnant women with multifetal gestation.
- Structural anomalies of uterus and cervix.
- Chronic diseases as (SLE, hypertension, diabetes, renal diseases, bronchial asthma, anemia, hyperthyroidism, and cardiac disease).
- Previous child with structural or chromosomal anomalies
- Exposure to irradiation or teratogen.-
- Recurrent fetal loss.

All patients were assessed as follows

1. Informed consent: It was written taken from the antenatal women to share in the study.

2. Full history taking, particularly for:

- Menstrual history.
- Obstetric history.
- Presence of medical disorder that affects pregnancy.
- Vaginal bleeding.

3. Screening technique:

The first-trimester ultrasound examination was performed at 6+0 to 7+6 gestational weeks in the prenatal units of Fayoum University Hospitals between November 2020 and July 2021. The rationale for choosing these patients was inclusion/exclusion criteria after verbal and written consent using (Philips Medical Systems) ultrasound machine with the 2D endovaginal probe with frequency 7 MHz.

- The modified Naegele's formula was used to determine gestational age from the known start of the previous

menstrual cycle, verified by sonographic measurement of the crown-rump length.

- The gestational sac was measured using a three-dimensional average (longitudinal, anteroposterior, and transverse). From the interior of the sac to the inside of the decidual reaction, the sac was measured.
- The size of the yolk sac was measured using calipers on the inner boundaries of the larger diameter and the shape, echogenicity, and presence of calcification. Normal YS were those with a 3-6 mm diameter, a rounded form, no degenerative alterations, an echogenic rim, and a hypoechoic center. After two weeks, all pregnancies with an aberrant yolk sac were re-evaluated by sonography.
- CRL was calculated in the embryo's sagittal plane, avoiding the inclusion of YS.
- The embryonic heart rate was calculated using M-mode sonography to average, at least three waves in beats per minute.

Clinical Follow Up

If a subsequent first-trimester scan revealed no heartbeat, the pregnancy was classed as early miscarriage, and if a subsequent second-trimester scan revealed a live baby, it was labeled as living.

Between the 18th and 22nd week of pregnancy, all chosen patients were scheduled for a fetal structural abnormality scan. Following the guidelines established by the Clinical Standards Committee of the International Society of Ultrasound in

Obstetrics and Gynecology (ISUOG), a second-trimester scan was conducted using the same equipment as the first-trimester scan 2D transabdominal probe with frequency 5 MHz:

Statistical Analysis

At the 0.05, 0.01, and 0.001 levels of probability, all statistical computations were performed using Microsoft Excel version 16 and the SPSS (statistical package for the social sciences version 26.00) statistical software. The Chi-squared test was used to compare categorical variables that were given as a number (percent). The Kolmogorov-Smirnov test was used to determine if continuous variables had a normal distribution. Regular or non-normally distributed continuous parameters were given as mean (standard deviation) or median (interquartile range, IQR).

Results

In our study, 100 first trimester pregnant cases attended in the prenatal units of Fayoum University Hospitals were included as per criteria and data collected. The first-trimester pregnancy outcome was evaluated by the normal continuation of pregnancy, early miscarriage, or congenital fetal malformation. Among cases, 77 (77%) had a normal pregnancy, 20 (20%) had an early miscarriage, 3 (3%) had Congenital fetal malformation.

Table (1): Comparison between normal, early miscarriage, and congenital fetal malformation result of the scan regarding YS diameter and GS diameter.

| | | Result of scan | | | Kruskal-Wallis | P-value |
|-------------|--------------|------------------|----------------------------|---------------------------------------|----------------|---------|
| | | Normal (N=77) | Early miscarriage (N = 20) | Congenital fetal malformation (N = 3) | | |
| YS diameter | Median (IQR) | 0.50 (0.40-0.60) | 0.40 (0.30-0.50) | 0.55 (0.52-0.70) | 9.024 | 0.011 S |
| GS diameter | Median (IQR) | 2.77 (2.26-3.0) | 2.24 (1.65 -2.67) | 1.70 (1.50 -2.40) | 8.273 | 0.016 S |

S; significant at p value < 0.05

It reveals a statistically significant difference between normal, early miscarriage, and congenital fetal malformation results of scan regarding YS diameter and GS diameter ($p < 0.05$) as shown in table (1) and figure (1) & (2).

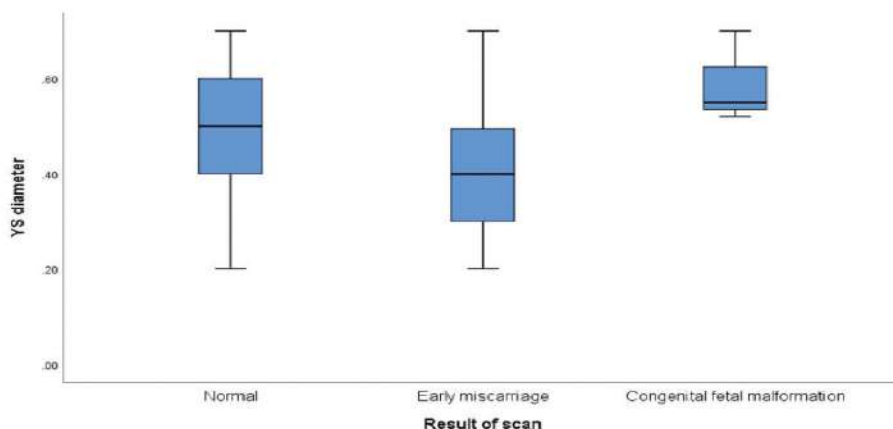


Figure (1): Boxplot compares normal, early miscarriage, and congenital fetal malformation results of scan regarding YS diameter.

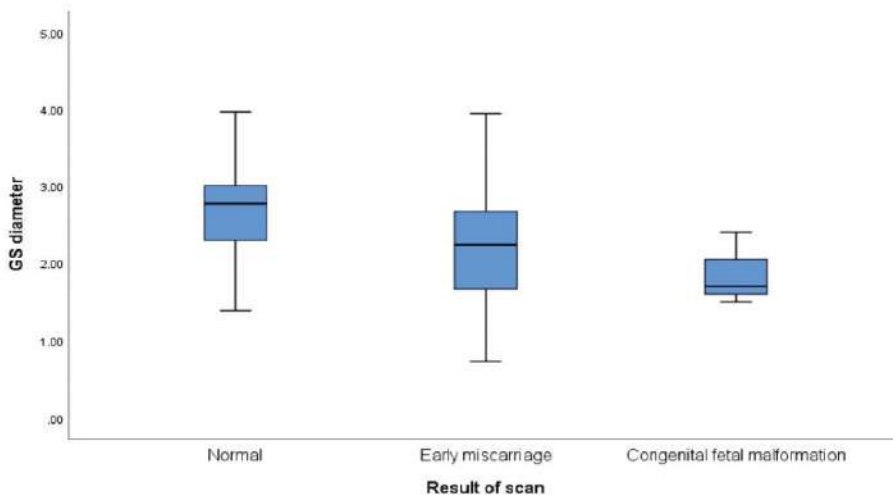


Figure (2): Boxplot compares normal, early miscarriage, and congenital fetal malformation scan results regarding GS diameter

Table (2): Comparison between normal, early miscarriage, and congenital fetal malformation result of the scan regarding YS diameter and GS diameter.

| Yolk sac shape | Result of scan | | | | | | Chi | -square P-value |
|----------------|----------------|-------|-------------------|-------|-------------------------------|--------|--------|-----------------|
| | Normal | | Early miscarriage | | Congenital fetal malformation | | | |
| | N | % | N | % | N | % | | |
| Regular | 76 | 98.7% | 10 | 50.0% | 3 | 100.0% | 41.422 | <0.001 HS |
| Irregular | 0 | 0.0% | 4 | 20.0% | 0 | 0.0% | | |
| Small | 0 | 0.0% | 3 | 15.0% | 0 | 0.0% | | |
| Calcified | 1 | 1.3% | 1 | 5.0% | 0 | 0.0% | | |
| Large | 0 | 0.0% | 2 | 10.0% | 0 | 0.0% | | |

HS; highly significant at p value < 0.001

It reveals a statistically highly significant difference between a normal, early miscarriage and congenital fetal malformation results of scan regarding Yolk sac shape (p < 0.001).

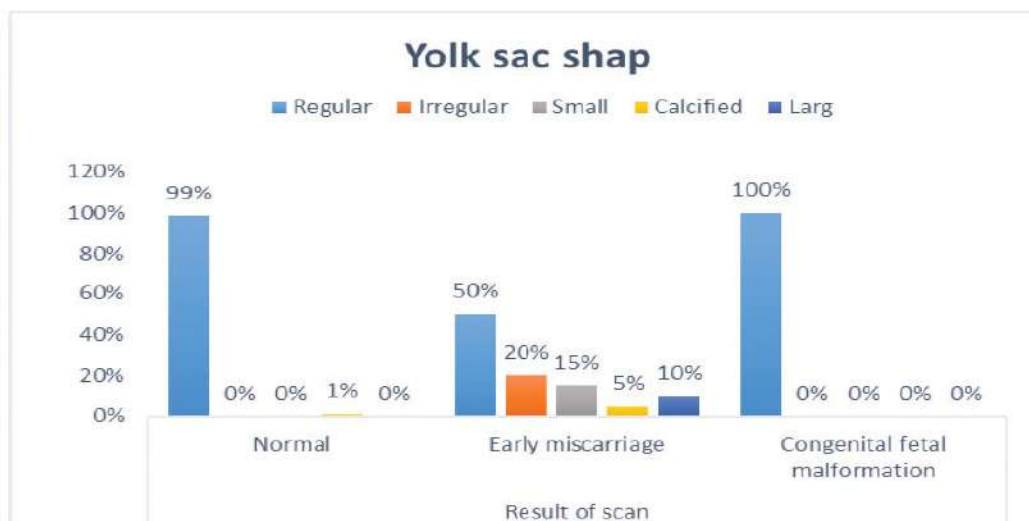


Figure (3): Comparing normal, early miscarriage and congenital fetal malformation results of scan regarding Yolk sac shape.

Table (3): Comparison between normal, early miscarriage and congenital fetal malformation result of the scan regarding FHR and CRL.

| | | Result of scan | | | Kruskal-Wallis | P-value |
|------------|--------------|-------------------|----------------------------|---------------------------------------|----------------|----------|
| | | Normal (N=77) | Early miscarriage (N = 20) | Congenital fetal malformation (N = 3) | | |
| FHR | Median (IQR) | 160.00 (140 -170) | 88.50 (80.00-99.0) | 170.00 (166.0-173.0) | 30.30 | 0.001 HS |
| CRL | Median (IQR) | 1.37 (0.89 -1.66) | 0.29 (0-1.10) | 1.62 (1.56 -1.85) | 19.63 | 0.001 HS |

HS; highly significant at p-value < 0.001

It reveals a highly statistically significant difference between a normal, early miscarriage and congenital fetal malformation results of scan regarding FHR and CRL (p < 0.001).

Discussion

Congenital abnormalities influence 3% to 5% of all pregnancies, and they are the leading cause of newborn death. The majority are caused by unknown factors, with pregnancy being the sole risk factor. However, in both affluent and developing nations, they are responsible for rising newborn fatalities (6).

Sonographically, the intrauterine gestational sac is the first to show up, followed by the yolk sac, then the fetal pole with heart activity. The yolk sac is the earliest visible embryonic structure inside the gestational sac. It manifests as a circular anechoic region between the fifth and twelve weeks of pregnancy, after which it degenerates (7).

Prior studies of early detection of congenital fetal malformation focused mainly on screening at late first trimester between 11-13 weeks gestation. To the best of our knowledge, the present study focused on early first-trimester screening. It was undertaken to describe the relationship between gestational sac (GS), yolk sac (YS) diameter, crown-rump length (CRL), and embryonic heart rate (HR) between 6 and 8 weeks of pregnancy and early detection of major structural fetal malformation.

The significant difference between a normal, early miscarriage and congenital fetal malformation results of scan regarding YS diameter and GS diameter ($p < 0.05$). There is a highly significant difference between a normal, early miscarriage and congenital fetal malformation results of scan regarding Yolk sac shape, FHR, and CRL ($p < 0.001$).

Three cases showed congenital fetal malformation, including 2 cases of anencephaly and 1 case of Cystic hygroma. An early scan of these cases showed a normal gestational sac with smooth normal shape and size yolk sac average CRL with average heart rate. Twenty cases of 100 cases ended by early miscarriage. The highly significant difference between a normal,

early miscarriage and congenital fetal malformation results of scan regarding Yolk sac shape.

In our study, embryonic heart rate influences the pregnancy outcome. Average heart rate between 140-175 beat/ min, resulting in normal pregnancy outcome only 3 cases result in congenital fetal malformation. Fetal bradycardia with average heart rates between 80-100 beats/ min results in early miscarriage.

A further research found that a CRL below the 50th centile on the 28th day of pregnancy was linked to a 19.4% early pregnancy loss rate, compared to just 3.3% when the CRL was above the 50th centile (8)

A very tiny yolk sac has been suggested as a typical feature during the early stages of normal embryologic development. On the other hand, much older research, which has some limitations, indicates that a yolk sac diameter of 2 mm or smaller is linked with a poor result in pregnancies of 8 to 12 weeks gestation. The size of the yolk sac starts to shrink in the late weeks of the first trimester, as is widely known. This is why, while determining the size of the yolk sac, gestational age should be considered. When a smaller-than-expected yolk sac is seen, it is advisable to conduct serial sonographic exams within a short time (9).

A tiny yolk sac with a diameter of less than 3mm between 6-10 weeks or more than 7 mm before 9 weeks suggests an abnormal pregnancy and needs a follow-up ultrasound scan to determine pregnancy viability (10).

Despite the lack of a clear agreement, most writers consider 5 or 6 mm as the maximum limit for the size of a typical yolk sac in pregnancies between the 5th and 10th weeks of pregnancy. According to recent research, a yolk sac diameter of more than 5 mm is linked to a higher chance of spontaneous abortion. However, a few writers have reported a big yolk sac in a normal live pregnancy, such as 8.1 mm (9).

In 2014, Tan et al., reported that an enlarged yolk sac was noted in eight pregnancies (2.6%). Nearly 40% of these pregnancies resulted in a the first trimester miscarriage. These findings indicate that the existence of an enlarged yolk sac (with a diameter of > 5 mm) is of evident clinical significance when it is specified before the 7th week of gestation (9)

In 2015, Shetty et al., also reported that a yolk sac greater than 5 mm (large yolk sac) between 6- 7.5 weeks gestation was a good indicator and that it would end in abortions (11).

In 2016, Ashoush et al., a large yolk sac was most commonly detected (in 36.8%) with isolated congenital anomalies (representing 63.6% of all cases with too-large yolk sac) (12).

In 2016, Srivastava et al., also reported that an enlarged yolk sac was responsible for 77.78% of abortions (13).

Acknowledgments

The authors would like to acknowledge all doctors and staff of the Department of Obstetrics and Gynaecology, Fayoum University Hospital for their sincere support and help.

Funding: No funding sources

Conflict of interest: None declared

Ethical approval: The study was approved by the Institutional Ethics Committee

References

1. Srivastava G, Nagwani M, Tewari V, Kunwar S, Pasricha N, Sthapak E: The Correlation of Shape of Yolk Sac with Spontaneous Abortion-An Ultrasonographic Study. *Era's Journal of Medical Research*. 2018; 5(2):128-133.
2. Salomon LJ, Alfirevic Z, Berghella V, Bilardo C, Hernandez-Andrade E, Johnsen S, Kalache K, Leung KY, Malinger G, Munoz H: Practice guidelines for performance of the routine mid-trimester fetal ultrasound scan. *Ultrasound in Obstetrics & Gynecology*. 2011; 37(1):116-126
3. Carvalho M, Brizot M, Lopes L, Chiba C, Miyadahira S, Zugaib M: Detection of fetal structural abnormalities at the 11–14 week ultrasound scan. *Prenatal Diagnosis: Published in Affiliation With the International Society for Prenatal Diagnosis*. 2002; 22(1):1-4
4. Abd Ellatif EM, Ahmad AK, Halawa MAA: Yolk Sac Size and Shape, Gestational Sac Diameter and Embryonic Heart Rate as Prognostic Factors for First Trimesteric Outcome. *The Egyptian Journal of Hospital Medicine*. 2018; 73(9):7418-7428
5. Safaa A, Ahmed M: Ultrasonography and Pregnancy Outcome in Threatened Abortion: A Prospective Observational Study. *Gynecol Obstet (Sunnyvale)*. 2018; 8(8)
6. Abu-Rustum RS, Daou L, Abu-Rustum SE: Role of first-trimester sonography in the diagnosis of aneuploidy and structural fetal anomalies. *Journal of Ultrasound in Medicine*. 2010; 29(10):1445-1452.
7. Kaur A, Kaur A : Transvaginal ultrasonography in the first trimester of pregnancy and its comparison with transabdominal ultrasonography. *Journal of Pharmacy and Bioallied Sciences*. 2011; 3(3):329
8. Abdallah Y, Daemen A, Guha S, Syed S, Naji O, Pexsters A, Kirk E, Stalder C, Gould D, Ahmed S: Gestational sac and embryonic growth are not useful as criteria to define miscarriage: a multicenter observational study. *Ultrasound in obstetrics & gynecology*. 2011; 38(5):503-509
9. Tan S, Tangal NG, Kanat-Pektas M, Özcan AŞ, Keskin HL, Akgündüz G, Teber

- MA, Arslan H: Abnormal sonographic appearances of the yolk sac: which can be associated with adverse perinatal outcome? *Medical ultrasonography*, 2014; 16(1):15-20
10. Reddy UM, Abuhamad AZ, Levine D, Saade GR, Participants FIWI: Fetal imaging: Executive summary of a joint Eunice Kennedy Shriver National Institute of child health and human development, Society for Maternal-Fetal Medicine, American Institute of ultrasound in medicine, American College of Obstetricians and Gynecologists, American College of Radiology, Society for pediatric radiology, and society of radiologists in ultrasound fetal imaging workshop. *American journal of obstetrics and gynecology*, 2014; Vol 210(5):P.387-397
11. Adithi S Shetty, Harish Shetty, Divya Hegde, B. Suresh Kumar Shetty, Jagadish Rao Padubidri, Diplomate NB : Yolk Sac Abnormalities-Is It a Reliable Indicator of Abortions?-A Prospective Study in the Population Residing in Rural Setup of Mangaluru, Karnataka, India. *Journal of Pharmaceutical and Biomedical Sciences*, 2015; 5 (5): p. 380-4.
12. Ashoush S., Abuelghar W., Tamara T. And Aljobbory: Relation between types of yolk sac abnormalities and early embryonic morphology in the first trimester missed miscarriage. *J. Obstet. Gynaecol. Res.*, 2016; Vol. 42, No. 1: 21-8, DOI: 10.1111/jog.12837.
13. Srivastava G., Nagwani M., Pasricha N., Et Al: Size of Yolk Sac by Ultrasonography and its Correlation with Pregnancy Outcome. *International Journal of Anatomy and Research*, 2016; 4 (1): p. 2052.