

Polyaxial versus Uniaxial Volar Locking Plate for Distal Radial Fractures

Hossam eldin A. Albegawy, Elsayed M. Baiomy, Mohamed A. Barhoma

Department of Orthopaedic Surgery Faculty of medicine, Benha University, Egypt.

Correspondence to: Mohamed A. Barhoma, Department of Orthopaedic Surgery Faculty of medicine, Benha University, Egypt.

Email:

mohamed_abdelkader20122@yahoo.com

Received: 14 September 2021

Accepted: 21 May 2022

Abstract

Background: Distal radius fractures are prevalent injuries that represent about one-sixth of all fractures seen in the emergency department. **The aim** is to compare the management results of comminuted distal radius fractures using polyaxial versus uniaxial volar locking plate. **Methods:** Forty-two patients were included in the study. When calculating the statistical analysis and the results, only 32 patients had fulfilled the follow-up requirements and were included. On admission, all patients were assessed by: history taking, clinical examination and appropriate radiological assessment. **Results:** VAS score has no statistical significance, while MAYO and Quick-DASH scores show statistical significance at six months, and the differences were too small to be of clinical relevance. Radiological results according to comparison of post-operative & end follow up results were also better with polyaxial. The final clinical results were not related to fracture type as there was a positive correlation between hand dominance and the final score. The final

clinical outcome was related to age & smoking habits but not related to sex or occupation.

Conclusion: Treatment of comminuted distal radius fractures with a volar variable angle plate fixation is safe and effective. Using these plates is associated with excellent and good functional outcomes with a significant reduction of hardware complications.

Keywords: Polyaxial; Uniaxial; Volar Locking Plate; Radial Fractures

Introduction

Distal radius fractures are very common injuries that represent about one-sixth of all fractures seen in the emergency department.

While many of these fractures can be successfully managed non-operatively, some require surgical stabilization. Debate

continues to be the optimal treatment modality of unstable fractures, both intra and extra-articular(1).

Some of the most popular stabilization techniques used to be external fixation, pinning dorsal plating or a combination of these. External fixation devices are uncomfortable; need to be kept in place for 6 to 8 weeks and some fracture redisplacement often occurs after the fixation device has been removed. Percutaneous pinning is unsuitable for displaced intra-articular fractures and has less stability in osteoporotic bone. Dorsal plates have the risk of extensor tendons irritation and need to be removed regularly. Volar locking plates are a relatively new concept and widely used in the surgical treatment of distal radius fractures(2).

The volar approach is more physiological than the dorsal approach and is less disruptive to the tendons because there is more space available on the volar aspect of the radius. The volar approach also maintains the dorsal vascularity of the fragments, thus allowing early motion of the wrist joint. Soft tissues well cover the plates in the pronator fossa and implants are not removed routinely. Volar locking plates mechanically bridge the bone and bear the

load through the locking construct, resulting in a lower incidence of failure. The subchondral placement of distal screws is essential to prevent a correction loss and achieve good functional results(3).

Goals in applying a volar implant include the accurate and safe subchondral placement of screws combined with the achievement of true radial column support. In using a fixed-angle plate, this may be difficult to achieve because of variations in the size of the radius and variations in the location of the fracture lines, particularly the volar fracture lines.(4)

Variable-angle screws allow adaptation of the plate position to volar fracture lines in both a proximal-to-distal plane and a radial-to-ulnar plane. This adaptation in position can be achieved while still minimizing the risk of screw perforation of either the distal radio-ulnar joint or the radio-carpal joint by directing screws away from the joint.(5)

Complications associated with fracture of the distal radius can occur at any time during the treatment process and the prevalence rate is up to 27% of all distal radius fractures. These complications include median nerve dysfunction, malunion or nonunion, posttraumatic osteoarthritis, finger, wrist, elbow stiffness, tendon rupture, most

commonly extensor pollicis longus and mid-carpal instability. (6)

This study compared functional and radiological outcomes of distal radial fractures operated with the polyaxial versus uniaxial volar locking plates.

Patients and methods

This prospective case series comparative study was conducted involving 50 patients with distal fracture radius (24 cases fixed polyaxial plates and another 26 with uniaxial plates), in the period between November 2020 and September 2021, Orthopaedic Department at Benha University hospital & Nasser institute hospital.

Ten patients were excluded from the results: seven due to incomplete follow up period (6 months), two refused to attend the follow-up appointments and one patient had ipsilateral open fracture humerus with a complete radial nerve injury that interfere with follow up. This left a total of 40 patients (20 with polyaxial & 20 with uniaxial) who fulfilled the inclusion criteria and completed at least six months follow up period.

The Ethical Committee approved this study of Benha faculty of medicine; informed

written consent in the Arabic language was obtained from all participants.

Inclusion criteria:

- Age: 16 to 70 years.
- Skeletally mature patients.
- Comminuted Distal radial fractures (type C fractures).

Exclusion criteria:

- Age: younger than 16 years (Skeletally immature patients).
- Paralyzed limb.
- Inflammatory arthritis.
- Pathological fractures.
- Simple extra-articular distal radial fractures.
- Associated fractures of radius (segmental).
- Open distal fracture radius.
- Neurovascular injury.

Data recorded included:

- 1- Personal data: Name, age, sex, hand dominance, occupation, address and telephone number.
- 2- Special habits of medical importance.
- 3- Co-morbidities: Diabetes, hypertension, cardiac, renal ...etc.
- 4- Mechanism of injury.

- 5- Side affected.
- 6- Physical examination and laboratory investigations.
- 7- Radiological investigations and classification according to it.

Clinical photographs:

The patient hands were photographed after surgical intervention (after obtaining informed consent) for follow up.

Consent:

Standard consents were taken from the patient.

Operative room sitting:

General anaesthesia.

Position:

- Position the patient supine and place the forearm on a hand table.
- By abducting the shoulder, the surgeon and the assistant can sit on either side of the hand table (radiolucent side table).
- The limb's position should allow complete imaging in the frontal and sagittal plane of the distal radius.
- A non-sterile pneumatic tourniquet is used.

- Prophylactic antibiotics are optional according to local microbiological protocols.

Approach:

Modified Henry approach:

- The modified Henry approach uses the plane between the flexor carpi radialis tendon and the radial artery.
- The flexor carpi radialis tendon is palpated before making the skin incision to the radial side.
- A longitudinal incision is made over the flexor carpi radialis (FCR) tendon.
- The tendon is identified and mobilized ulnarly.
- The floor of the flexor carpi radialis tendon sheath is incised in line with the skin incision.
- The flexor pollicis longus muscle belly is bluntly swept to the ulnar side.
- The pronator quadratus muscle and the anterior wrist capsule are then exposed after blunt dissection. The pronator quadratus is mobilized by releasing its distal and lateral borders with an L-shaped incision. It is then lifted from its bed by sub-periosteal dissection; exposing the fracture site.

Fracture reduction

After exposure and refreshing of the fracture site, the fracture was reduced and provisionally fixed under C-Arm using k-wires. In intra-articular fractures, large fragments were manipulated, reduced and preliminary fixed by wires.

Plate position

- The plate should be positioned on the distal radius proximal to the Watershed line. If placed properly, K-wires are inserted in it to ensure the position. The plate is designed to be elongated in its ulnar side as the volar surface of the ulnar column is more distal than the radial column. C-arm confirms the position of the plate.

According to fracture lines, the plate may be positioned more distally to cover the volar fracture line or more ulnar, if there was a sagittal plane fracture line in the ulnar portion of the distal radius.

A screw is inserted in the oval non-locking hole of the plate, allowing fine adjustment of the plate position either proximally or distally. At this point, the plate is used as a buttress for the lunate facet fragment and as a template for reconstructing the articular surface.

Distal Plate fixation

Uniaxial:

The plate is applied to the bone and a 3.5mm Cortical Screw is inserted into the oblong hole in the shaft following the technique described below. Before fully seating the screw, the plate may be translated distally or proximally as needed. Once optimal plate position has been achieved, fully seat the screw. For the remaining screws, locking screws will be used according to the relevant screw insertion technique as described below.

3.5mm locking screw insertion technique:

Thread the 2.7mm Locking Drill Guide into the screw hole. Drill with the Short 2.7mm Drill Bit and measure for screw length by reading the calibrations on the Drill Bit or by using the 3.5mm Depth Gauge. If using Depth Gauge, the Locking Drill Guide must be removed for accurate measurement. Insert the appropriate length screw using the 3.5mm Screwdriver.

Polyaxial:

The plate was fixed to bone distally; beginning with the most ulnar screw using the funnel-shaped end of the VA-LCP drill sleeve at the desired angle. This funnel-shaped sleeve allows the drill bit up to a 15°

angulation around the central axis of the locking hole.

The more ulnar screws may be directed perpendicular or even angled slightly proximal relative to the plate, to ensure that articular perforation does not occur and for proper screw length.

After each screw insertion, the screw position is confirmed by C-arm to ensure that there is no articular perforation. 20° tilted lateral view was done intra-operative rather than regular lateral view.

Distal fixation of the plate was finished by insertion of lateral screws. If sufficient angulation of the screws relative to the longitudinal the plates of the achieved, one or two screws were directed from the volar radial aspect of the plate in a dorsal and radial direction. This stabilizes the radial column. The direction and the size of 2.4 mm of the screws allow catching small radial styloid fragment.

Definitive plate fixation

Once the distal screws positioning was completed, proximal screws were inserted. In the case of articular fragments, the net result is that the distal articular surface can then be manipulated as one fragment utilizing the plate as a reduction device for final

fine-tuning of the relation between the articular surface and the diaphysis.

Wound closure

After checking reduction, screws lengths and assuring that no screws are placed intra-articular, the tourniquet is deflated and good hemostasis is performed to prevent post-operative hematoma and swelling that might hinder the rehabilitation (a potential risk for post-operative median nerve dysfunction).

The pronator quadratus was repaired over the plate if it was repairable. As in complex fracture patterns, the PQ was almost always lacerated by the injury.

The use of vacuum suction is optional. The subcutaneous layer is closed and the skin is closed with simple interrupted sutures starting at the zigzag portion of the incision. The patient is put in a splint making sure that the MPJ and the fingers are free.

Statistical analysis

Data management and statistical analysis were done using SPSS version 25. (IBM, Armonk, New York, United States). Quantitative data were assessed for normality using the Shapiro-Wilk test and direct data visualization methods. According to normality, numerical data were summarized as means and standard

deviations or medians and ranges. Categorical data were summarized as numbers and percentages. Quantitative data were compared between study groups using independent t-test or Mann-Whitney U test for normally and non-normally distributed numerical variables, respectively. Categorical data were compared using the Chi-square test. All statistical tests were two-sided. P values less than 0.05 were considered significant.

Results

Between November 2020 and September 2021, a prospective comparative study was conducted involving 40 patients with a fracture of distal radius. Patients were categorized into two groups: Group I: Twenty patients with uniaxial plates. Group II: Twenty patients with polyaxial plates. No significant difference was reported between both groups regarding age (P-value = 0.172), gender (P-value = 0.723), occupation (P-value = 0.723), smoking (P-value = 0.110), diabetes mellitus (P-value = 1.0), hypertension (P-value = 1.0), cardiac disease (P-value = 1.0), or previous wrist surgery, **table 1**

Frykman classification VIII was significantly higher in group I (85%) than group II (45%); P-value was 0.008. No

significant difference was noted between both groups regarding affected side (P-value = 0.527), dominant hand (P-value = 1.0), time to intervention (P-value = 0.369) and AO classification (P-value = 1.0) (**Table 2**).

The mean flexion range was significantly higher in group II (50.0) than group I (41); P-value was 0.033. Also, the mean range of extension was significantly higher in group II (58.0) than group I (42); P-value was <0.001. Radial and ulnar deviations were significantly higher in group II (16 and 36, respectively) than group I (12 and 26, respectively); P-values were 0.001 and <0.001, respectively. Grip strength was significantly higher in group II (21 kg) than group I (16 kg); P-value was 0.01. The median VAS score was significantly lower in group II (0.0) than group I (2); P-value was 0.026. Mayo score was significantly higher in group II (85) than group I (71); P-value was = 0.001. The median Q DASH score was significantly lower in group II (0.0) than group I (6.8); P-value was <0.001. The mean radial height was significantly higher in group II (9.9 mm) than group I (7 mm); P-value was 0.002. The mean volar tilt was significantly higher in group II (11) than group I (7); P-value was <0.001 (**Table 3**)

No significant difference was noted between both groups regarding penetrating screw (P-value = 0.127), CTS (P-value = 0.661), delayed wound healing (P-value = 1.0), 4th & 5th finger numbness (P-value = 1.0) and implant failure (P-value = 1.0) (**Table 4**)

Case No. 1

A 45 years old male patient sustained a Frykman VIII (AO 23 C3) fracture of the right distal radius after an RTA. He was managed with a polyaxial plate after seven days of injury. **Figure 1**

Clinical scores

Flexion: 50 & Extension: 40
Radial deviation: 13 & Ulnar deviation: 40
Supination & pronation: normal
Grip strength: 18
VAS: 3
Mayo: 85
QDASH: 4.5

Radial length: 11

Volar tilt: 12

Case No. 2

A 45 years old male patient sustained a Frykman VIII (AO 23 C1) fracture of the left distal radius after a falling on an outstretched hand. He was managed with a uniaxial plate after one day of injury. **figure 2**

Clinical scores

Flexion: 70 & Extension: 50
Radial deviation: 15 & Ulnar deviation: 40
Supination & pronation: normal
Grip strength: 26
VAS: 0
Mayo: 90
QDASH: 4.5
Radial length: 10
Volar tilt: 9

Table (1) General characteristics in both groups

		Group I	Group II	
		(n = 20)	(n = 20)	P-value
Age (years)	Mean \pm SD	45 \pm 11	41 \pm 6	0.172
Gender	Males n (%)	14 (70.0)	15 (75.0)	0.723
	Females n (%)	6 (30.0)	5 (25.0)	
Smoking	n (%)	11 (55.0)	6 (30.0)	0.11
Diabetes mellitus	n (%)	5 (25.0)	4 (20.0)	1.0
Hypertension	n (%)	1 (5.0)	1 (5.0)	1.0
Cardiac disease	n (%)	1 (5.0)	1 (5.0)	1.0
Previous wrist surgery	n (%)	0 (0.0)	0 (0.0)	-

Independent t-test was used for age. Chi-square or Fisher's exact test was used for categorical data

Table (2) Clinical characteristics in both groups

		Group I	Group II	
		(n = 20)	(n = 20)	P-value
Affected side	Right n (%)	11 (55.0)	9 (45.0)	0.527
	Left n (%)	9 (45.0)	11 (55.0)	
Dominant hand	Right n (%)	17 (85.0)	18 (90.0)	1.0
	Left n (%)	3 (15.0)	2 (10.0)	
Time to intervention (days)	Median (range)	4 (1 - 13)	3 (0 - 15)	0.369
Frykman classification	VII n (%)	3 (15.0)	11 (55.0)	0.008
	VIII n (%)	17 (85.0)	9 (45.0)	
AO classification	C1 n (%)	5 (25.0)	4 (20.0)	1.0
	C2 n (%)	6 (30.0)	7 (35.0)	
	C3 n (%)	9 (45.0)	9 (45.0)	

Mann Whitney U test was used for time to intervention. Chi-square or Fisher's exact test was used for categorical data

Table (3) Outcome in both groups

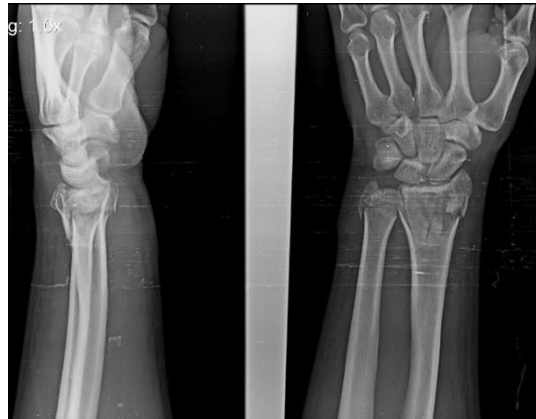		Group I	Group II	
		(n = 20)	(n = 20)	P-value
Flexion	Mean \pm SD	41 \pm 13	50 \pm 13	0.033
Extension	Mean \pm SD	42 \pm 10	58 \pm 12	<0.001
Radial deviation	Mean \pm SD	12 \pm 3	16 \pm 3	0.001
Ulnar deviation	Mean \pm SD	26 \pm 8	36 \pm 5	<0.001
Abnormal supination	n (%)	1 (5.0)	0 (0.0)	NA
Abnormal pronation	n (%)	1 (5.0)	0 (0.0)	NA
Grip strength (Kg)	Mean \pm SD	16 \pm 5	21 \pm 6	0.01
VAS	Median (range)	2 (0 - 6)	0 (0 - 4)	0.026
Mayo score	Mean \pm SD	71 \pm 15	85 \pm 7	0.001
Q DASH	Median (range)	6.8 (0 - 29.5)	0 (0 - 9.1)	<0.001
Radial height (mm)	Mean \pm SD	7 \pm 3	9 \pm 2	0.002
Volar tilt	Mean \pm SD	7 \pm 3	11 \pm 2	<0.001
Independent t-test or Mann-Whitney U test was used			NA: Not applicable	

Table (4) Distribution of complications in both groups

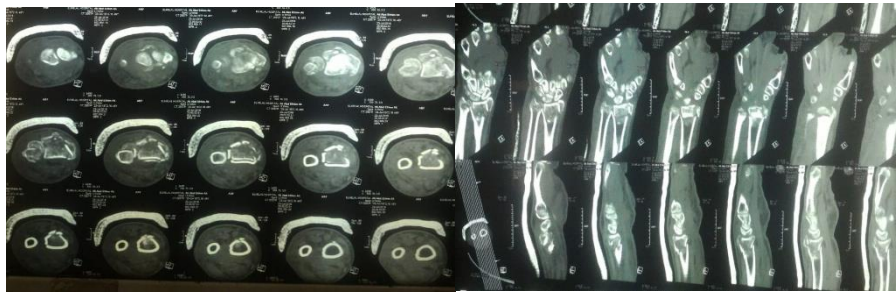		Group I	Group II	
		(n = 20)	(n = 20)	P-value
Penetrating screw	n (%)	7 (35.0)	2 (10.0)	0.127
CTS	n (%)	4 (20.0)	2 (10.0)	0.661
Delayed wound healing	n (%)	2 (10.0)	1 (5.0)	1.0
4th & 5th finger numbness	n (%)	1 (5.0)	1 (5.0)	1.0
Implant failure	n (%)	1 (5.0)	0 (0.0)	1.0

Fisher's exact test was used

Figure 1 (Case No. 1)



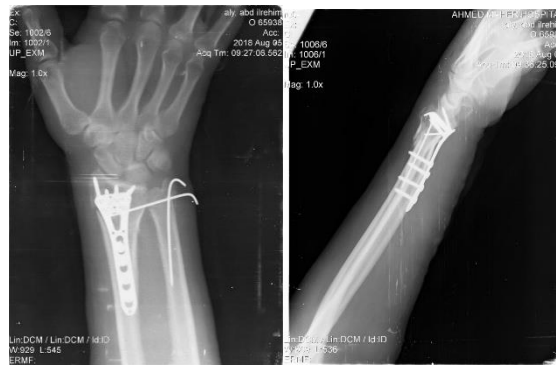A



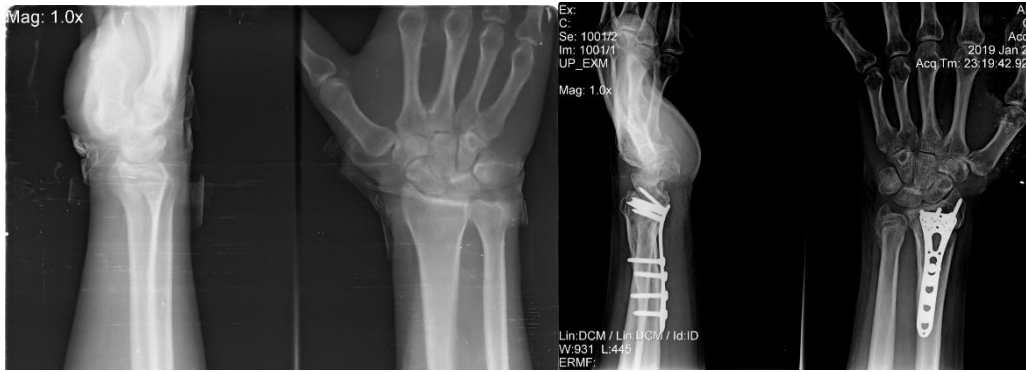B

C

A: preoperative x-ray & CT, B: Immediate postoperative, C: At the end of follow up.

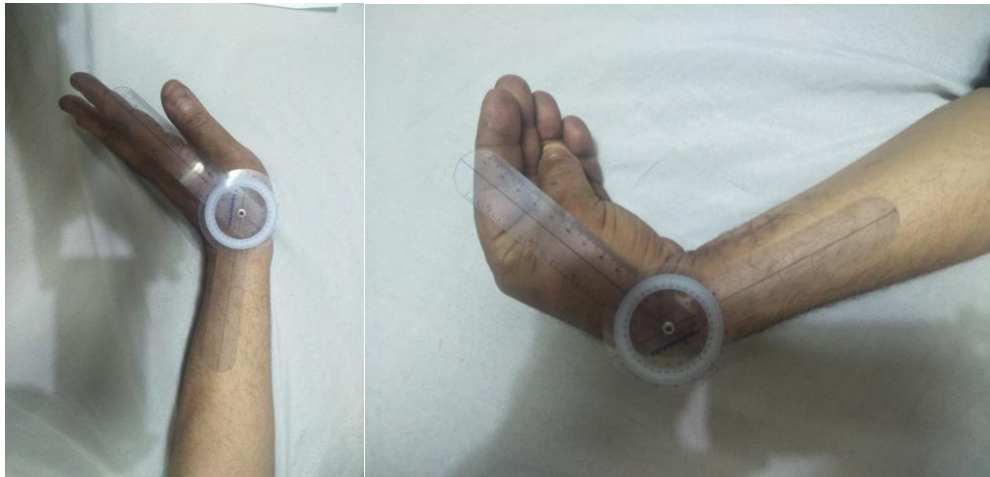

Post-operative X-ray : 1 weak after the operation



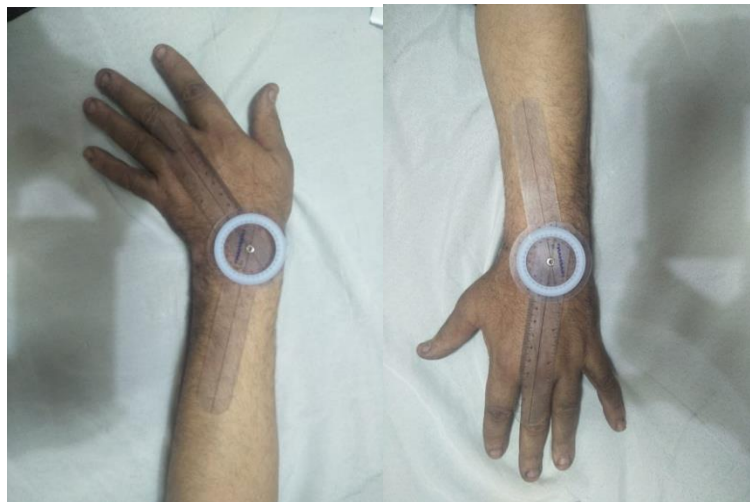Contralateral wrist

Follow up after 6 months



A


B



C

D

Range of motion. A: Dorsiflexion, B: Palmar flexion, and C: Ulnar deviation. C: radial deviation and D: Supination



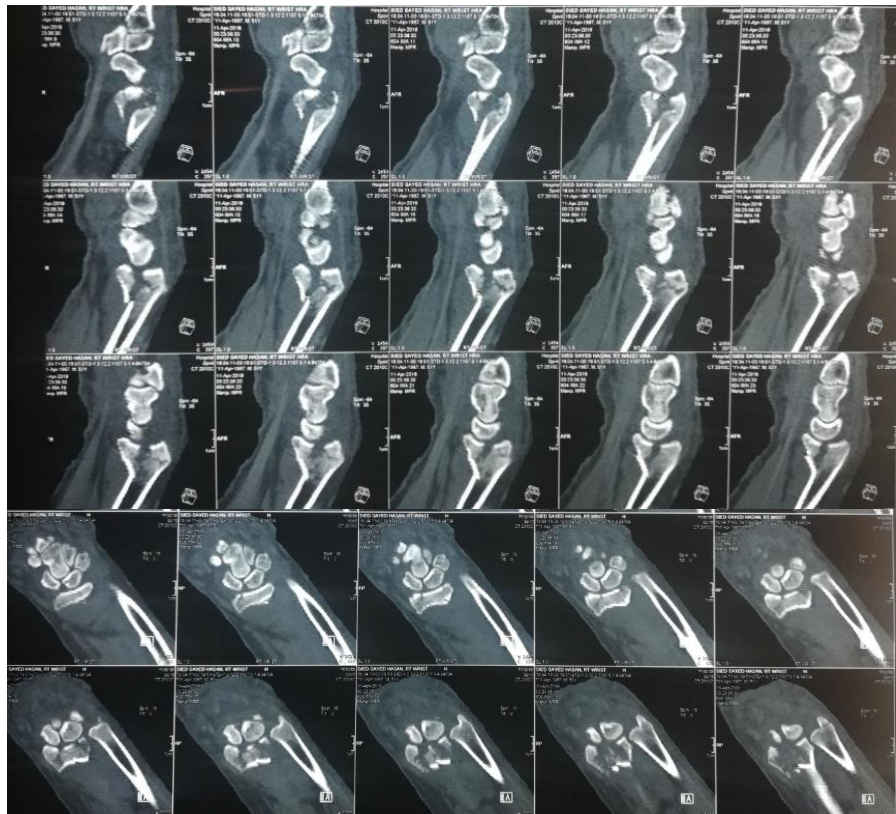
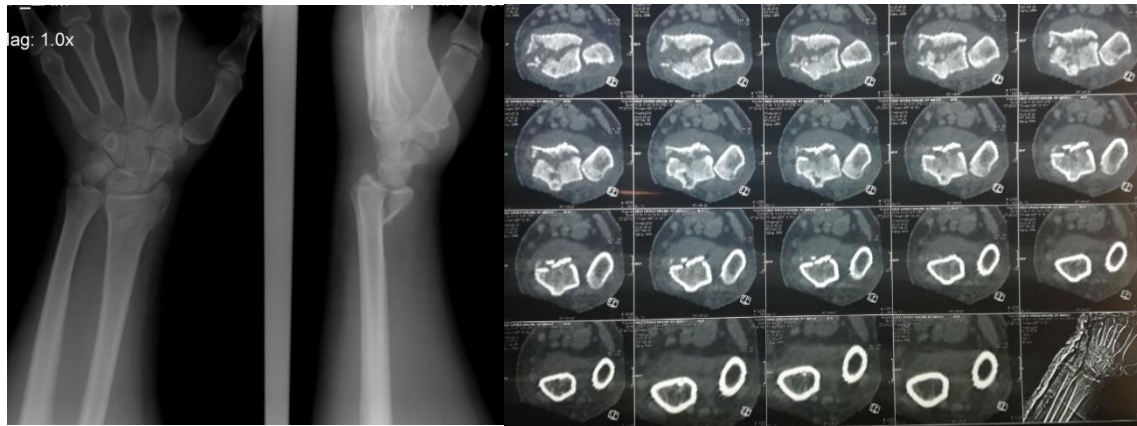
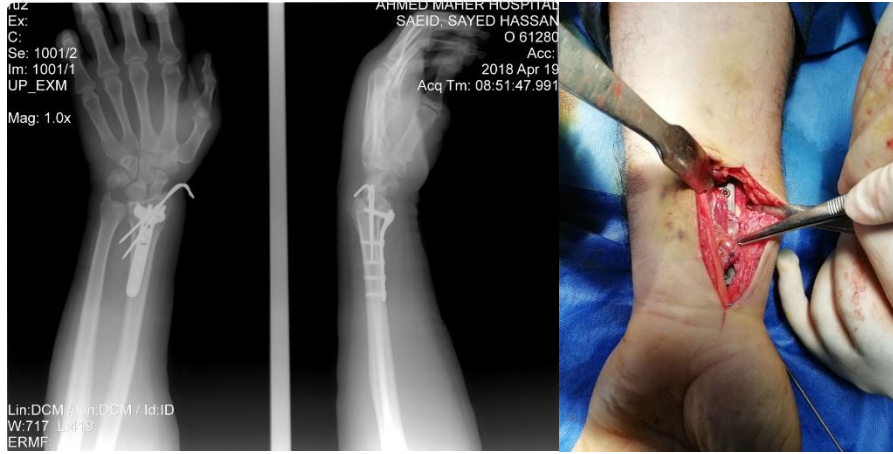
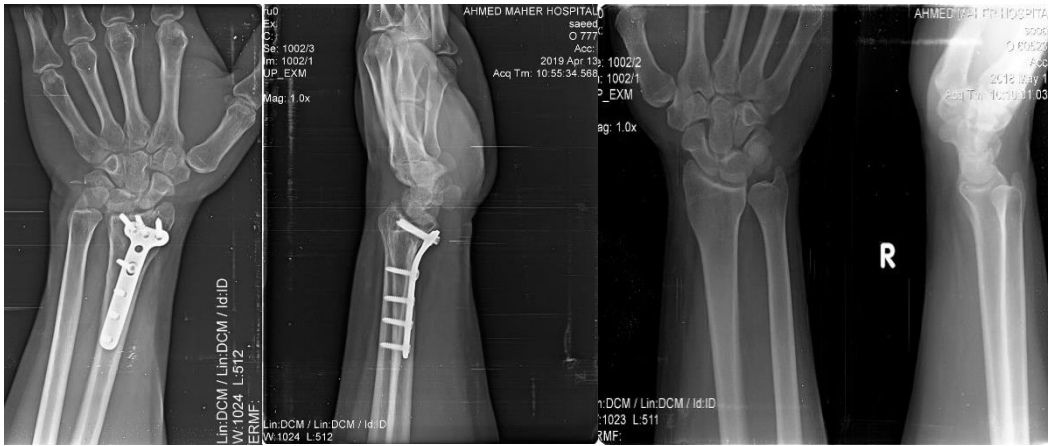
Figure 2 (Case No. 2): Preoperative x-ray & CT.



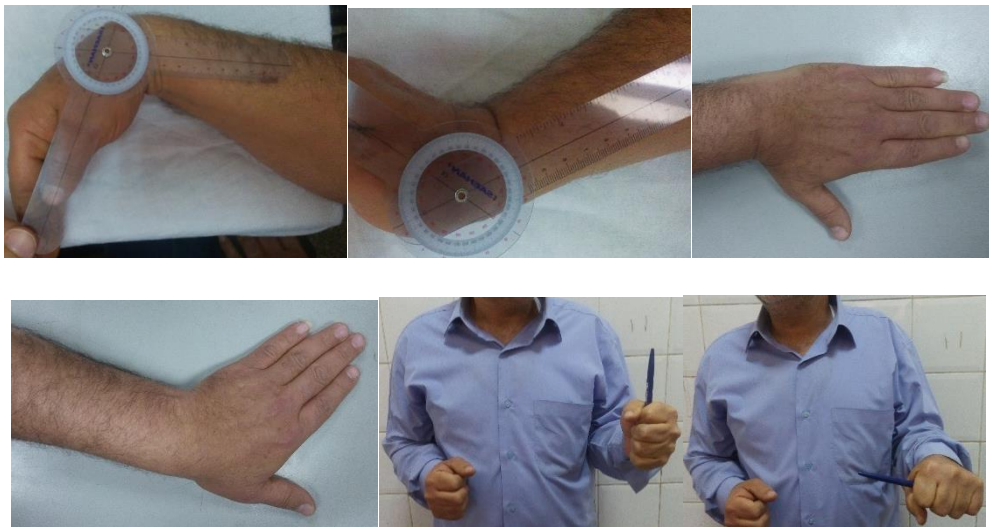Immediate postoperative.

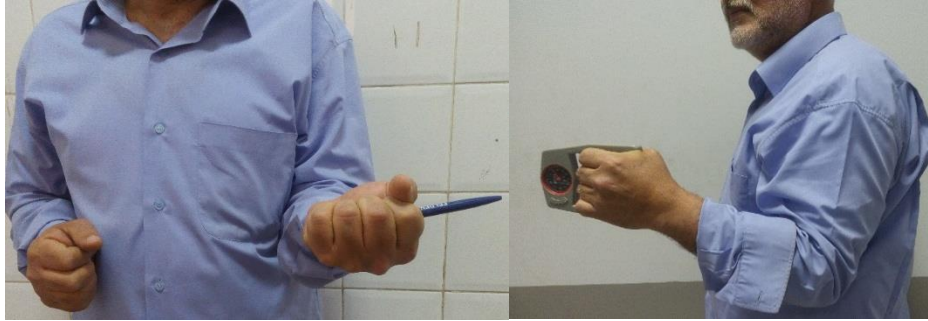Intraoperative.



Follow up.

Normal Side.





Measurements

Discussion

We compare our study with a retrospective study (7), which included 189 patients with all types of distal radial fractures and a long follow up period (32-65 years) but focus mainly on Complication Rate. Comparing Variable Angle & Distal Locking Plate to Fixed Angle Plate Fixation of Distal Radius Fractures concluded that the polyaxial plate could reduce the rate of hardware-related complications compared to standard fixed-angle plate designs for treatment of distal radius fractures. Their study decided that this treatment option allows more flexibility with plate position and more uniform fixation of the subchondral surface with fewer complications requiring secondary procedures. This conclusion is similar to our clinical results in our study.

In another retrospective study that included 23 patients with 4 AO type A3, 9 type C2, and 10 type C3 all were treated with polyaxial plate. The study concern Surgical

Treatment of Unstable Distal Radius Fractures with a Volar Variable-Angle Locking Plate: Clinical and Radiological Outcomes & concluded that” The use of variable-angle locking plates in treating unstable distal end radius fractures is associated with excellent to good functional outcomes with minimal complications”. (5) This also similar to our result with polyaxial.

Our results agrees with a retrospective study that included 87 patients with all types of fracture distal and follow up period 12 months. Its concern Polyaxial versus uniaxial volar locking plate for distal radial fractures and variation in subchondral support and concluded that the polyaxial volar locking plate system enabled deeper insertion of distal screws into the subchondral bone, thus providing better buttress for the fracture fragments (8).

Again in a retrospective study that included 107 patients with all types of distal radial

fractures. Focused on Distal radius volar locking plates: Does a variable angle locking system confer a clinical advantage? Follow up period was for Subjective assessment (7.5months uniaxial & 7.8 months polyaxial) & Objective assessment (17.2 months uniaxial & 32.5 months polyaxial). The study concluded that neither the subjective nor clinical outcomes of this study demonstrated clinical superiority of either plate system (9). This is dissimilar to our result. This may be due to a small sample of our study and a short follow-up period relative to their study. Also their study included all types of fractures of distal radius not only comminuted like ours which affect the result.

A previous study that included 41 patients, including all types of fracture distal radius with minimum follow-up time 6 months. The study focused on Comparative Analysis of the Results of Fixed-angle versus Variable-angle Volar Locking Plate for Distal Radius Fracture Fixation. The study concluded that no differences in clinical or radiologic results were noted between the fixed-angle volar locking plate and variable-angle volar locking plate groups. It is important to minimize complications by using appropriate screws and plates according to the fracture type. However, no

differences in the surgical outcome were noted between the fixed-angle volar locking plate group and variable-angle volar locking plate group with distal radius fracture (10). We also explain the difference between our study and this study because we included the comminuted fracture only which is difficult to do good reduction of articular with uniaxial plate and this affects the result.

Conclusion

The newest concept of the volar locking plates with angle stable screws is becoming widely used. Treatment of comminuted distal radius fractures with a volar variable angle plate fixation is safe and effective. Using these plates is associated with excellent and good functional outcome with significant reduction of hardware complication.

References

1. McFadyen I, Field J, McCann P, Ward J, Nicol S, Curwen C. Should unstable extra-articular distal radial fractures be treated with fixed-angle volar-locked plates or percutaneous Kirschner wires? A prospective randomised controlled trial. *Injury*. 2011;42(2):162–6.
2. Bentley G. *European Instructional Lectures: Volume 9, 2009; 10th EFORT Congress, Vienna, Austria. Vol. 9. Springer Science & Business Media; 2009.*

3. Osada D, Viegas SF, Shah MA, Morris RP, Patterson RM. Comparison of different distal radius dorsal and volar fracture fixation plates: a biomechanical study. *J Hand Surg Am.* 2003;28(1):94–104.
4. Ross M, Heiss-Dunlop W. Volar angle stable plating for distal radius fractures. 2009;
5. Khatri K, Sharma V, Farooque K, Tiwari V. Surgical treatment of unstable distal radius fractures with a volar variable-angle locking plate: clinical and radiological outcomes. *Arch trauma Res.* 2016;5(2).
6. Koval KJ, Harrast JJ, Anglen JO, Weinstein JN. Fractures of the distal part of the radius: The evolution of practice over time. Where's the evidence? *JBJS.* 2008;90(9):1855–61.
7. Mehrzad R, Kim DC. Complication rate comparing variable angle distal locking plate to fixed angle plate fixation of distal radius fractures. *Ann Plast Surg.* 2016;77(6):623–5.
8. Al-Mouazzen L, Chou DTS, Kyriakopoulos G, Hambidge J. Polyaxial versus uniaxial volar locking plate for distal radial fractures. *J Orthop Surg.* 2014;22(1):9–12.
9. Marlow WJ, SiNghAL R, DhEERENDRA S, RALtE P, FiSChER J, Waseem M. Distal radius volar locking plates: does a variable angle locking system confer a clinical advantage? *Acta Orthopædica Belgica.* 2012;78(3):309.
10. Cha S-D, Park J-H, Kim H-S, Chung S-T, Yoo J-H, Kim J-H, et al. Comparative analysis of the results of fixed-angle versus variable-angle volar locking plate for distal radius fracture fixation. *J Korean Fract Soc.* 2012;25(3):197–202.

To cite this article: Hossam eldin A. Albegawy, Elsayed M. Baiomy, Mohamed A. Barhoma. Polyaxial versus Uniaxial Volar Locking Plate for Distal Radial Fractures. *BMFJ* 2022;39(2): 438-455. DOI: 10.21608/bmfj.2022.96019.1483