

COMPARATIVE STUDY BETWEEN VITRECTOMY WITH AND WITHOUT INTERNAL LIMITING MEMBRANE PEELING FOR REFRACTORY DIABETIC MACULAR EDEMA

By

Fathy Mohamed Abo El-Ftoh El-Salhy, Hisham Fawzy Khalil and Mohamed Mohamed-Aly Ibrahim

Department of Ophthalmology, Faculty of Medicine, Al-Azhar University, Cairo, Egypt

Corresponding author: Fathy Mohamed El-Salhy,

Mobile: 01008825143, **E-mail:** fathyelsalhy2010@gmail.com

ABSTRACT

Background: Diabetic macular edema (DME) is a leading cause of visual impairment today, and occurs in approximately 10% of diabetic patients and 29% of those with disease duration of more than 20 years.

Objective: To detect the effectiveness of Pars Plana Vitrectomy PPV in treatment of refractory DME, and the differences in the anatomical and functional outcomes between PPV with and without internal limiting membrane (ILM) peeling.

Patients and methods: This was a prospective comparative study of 50 eyes of patients with refractory DME divided into 2 equal groups: Group A underwent vitrectomy without ILM peeling, and Group B underwent vitrectomy with ILM peeling.

All patients were subjected to full history and ophthalmic examination including Uncorrected / best corrected visual acuity (UCVA/BCVA) expressed in Decimal units, refraction using automated refractometer (Topcon KR-800 Auto refractometer), intraocular pressure (IOP) measurement by Goldman Applanation tonometer, Slit lamp biomicroscopy to assess cornea, depth of anterior chamber, state of pupil dilatation, lens morphology, dilated pupil fundus examination, Fundus Fluorescein Angiography (FFA) to show Features of diabetic maculopathy, Optical Coherence Tomography (OCT) To document macular thickness and Multifocal Electroretinogram (MF ERG) to assess the electrical response in central retinal area. The study was done at Al-Azhar University Hospitals between May 2019 and February 2021.

Results: The mean BCVA in our patients improved from 0.16 ± 0.07 pre-operatively to 0.29 ± 0.11 post-operatively in group A, and from 0.20 ± 0.10 pre-operatively to 0.36 ± 0.14 post-operatively in group B. This showed statistically significant improvements in both groups. The mean CMT in our patients improved from $495.64 \pm 113.37 \mu\text{m}$ pre-operatively to $323.24 \pm 63.21 \mu\text{m}$ post-operatively in group A and from $515.20 \pm 82.47 \mu\text{m}$ pre-operatively to $292.96 \pm 59.33 \mu\text{m}$ post-operatively in group B, and showed statistically significant improvements in both groups. P1 amplitude in ring (1+2) of the MF-ERG improved from $33.36 \pm 9.65 \text{ nv/deg}^2$ preoperatively to $43.00 \pm 9.51 \text{ nv/deg}^2$ at the end of the 3rd month in group A, In Group B, it improved from $35.40 \pm 10.99 \text{ nv/deg}^2$ preoperatively to $42.16 \pm 11.84 \text{ nv/deg}^2$ at the end of the 3rd month. Compared to preoperative values, there were statistically significant differences in both groups. P1 latency in ring (1+2) of the MF-ERG improved from $51.12 \pm 11.43 \text{ ms}$ preoperatively to $36.12 \pm 8.28 \text{ ms}$ at the end of the 3rd month, in group A. In Group B, it improved from $54.85 \pm 12.03 \text{ ms}$ preoperatively to $39.60 \pm 10.09 \text{ ms}$ at the end of the 3rd month. Compared to preoperative values there were statistically significant differences in both groups.

Conclusion: PPV with and without ILM peeling improved refractory DME even without evidence of VMT. This improvement was: structural (anatomical) improvement, i.e decrease in the CMT, functional improvement, i.e improvement in the BCVA, and macular response detected by MF ERG.

Keywords: Pars plana vitrectomy, ILM peeling and Refractory Diabetic macular edema.

INTRODUCTION

Diabetic retinopathy (DR) is a common and specific microvascular complication of diabetes which affects 17–54% of people with diabetes aged 49–60 years and considered one of the leading reasons of visual loss among the working population mainly due to diabetic macular edema (*Modarres, 2016*).

Although the exact pathogenetic mechanism responsible for retinopathy is not perfectly understood, some studies indicate that DR is a neurovascular disease of the retina. Retinal neurodegeneration occurs even much prior to the development of microcirculatory abnormalities (*Wong et al., 2016*).

Retinal laser photocoagulation, which had been used as a treatment for DME to help reduction of visual loss, has demonstrated limited ability to regain lost vision (*Agarwal et al., 2015*).

Anti -vascular endothelial growth factors (VEGFs) have become first line therapy in DME patients in improving macular edema and visual acuity replacing laser photocoagulation (*Takamura et al., 2018*).

Vitrectomy may be considered in patients with DME that is refractory or persistent despite laser or intravitreal injection. The mechanisms by which DME is postulated to improve after vitrectomy include a reduction of VMT, removal of VEGF, and improve oxygenation of the retina (*Jung and Lee, 2019*).

The present work aimed to compare the efficacy of pars plana vitrectomy (PPV) with and without peeling of the internal limiting membrane (ILM) in cases of refractory diabetic macular oedema, and to demonstrate the differences in the anatomical and functional outcomes between both groups.

PATIENTS AND METHODS

This was a prospective comparative study carried out on 50 eyes of 48 patients with refractory DME. The patients were divided into 2 equal groups:

- **Group (A):** where PPV was done without ILM peeling.
- **Group (B):** where PPV was done with ILM peeling.

This work was carried out at Al-Azhar University Hospitals between May 2019 and February 2021.

Inclusion criteria:

- Refractory DME: (central macular thickness (CMT) \geq 300 μ m after at least 3 intravitreal injections of anti VEGF).
- Diabetes Mellitus (DM) type 1 or 2.
- Best corrected visual acuity (BCVA) \geq 6/60.
- Previous treatment with laser photocoagulation for at least 3 months before surgery (but no macular photocoagulation).

Exclusion criteria: Chronic macular oedema more than 2 years, preoperative VA less than 6/60, other conditions

associated with macular edema rather than diabetes, focal edema, macular ischemia, evidence of VMT, and severe ocular illness such as advanced glaucoma.

Preoperative workup: Every patient in the study was subjected to history taking as well as complete ophthalmological examination including visual function assessment (BCVA using Snellen's decimal charts and standard Amsler chart), anterior segment examination, intraocular pressure (IOP) measurement, and detailed fundus examination.

FFA (Topcon Optical Co., Tokyo, Japan) was to show features of diabetic maculopathy, state of DR and areas of capillary drop out, neovascularization, intraretinal microvascular abnormality and other vascular changes.

OCT (DRI OCT TRITON PLUS, TOPCON, Japan) was to document macular thickness, configuration of macular oedema, presence of VMT and/or taut posterior hyaloid.

MF ERG (Ronald Consult RETI-port gamma plus2): Stimulation and recordings of the responses of the MF-ERG were performed using the ISCEV guidelines. By using conjunctival wire loop; patient's pupils were fully dilated with 0.5% tropicamide; visual stimulus consisted of 61 hexagonal areas. A monitor was positioned at a viewing distance of 32 cm.

The first order kernel of the multifocal ERG is formed of a negative wave called (N wave) appearing first. Its descending limb is formed by the hyperpolarization of the OFF-bipolar cells, while its ascending limb gives rise to the positive wave (P wave) which is mainly due to

depolarization of ON-bipolar cells. This is followed by the descent of P wave due to the recovery of the ON- bipolar cells first, then the OFF- bipolar cells recovery.

The P1 amplitude and latency of the first order kernel of the MF ERG from two concentric rings centered at the fovea were averaged and the mean from each ring summation was analyzed.

The procedure: All patients in the study underwent 23 gauge vitrectomy and posterior hyaloid removal. In group B patients (peeling group), additional ILM removal was done. Combined phaco vitrectomy was done in 12 cases, 5 in group A and 7 in group B.

Postoperative examination was done on the first day postoperatively, one week, one month, and three months. While OCT and mf ERG were done after 3 months postoperatively.

Ethical consideration: All The patients signed consents for intervention including advantages, disadvantages, and risks of possible complications.

Statistical analysis:

Data were investigated and analyzed using SPSS V-20. Quantitative values were reported in the form of mean \pm SD (standard deviation) and range. Qualitative data were reported in the form of numbers and percentage. The following tests were done: Independent-samples t-test of significance was used when comparing between two means. paired sample -test of significance was used when comparing between related sample or Mann-Whitney U test. P-value <0.05 was considered significant.

RESULTS

As regard to the baseline characteristics: The mean age of our patients was 55.27 ± 5.41 years in group A and 57.5 ± 6.87 years in group B. The studied cases included 9 (36%) males and 16 (64%) females in group A and 7 (30.4%) males and 16 (69.6%) females in group B.

The mean duration of diabetes was 11.93 ± 3.57 in group A and 9.79 ± 4.39 in group B, The mean preoperative IOP in group A was 16.86 ± 2.17 and 17.54 ± 1.58 in group B, No statistically significant

difference between groups according to baseline characteristics.

The mean preoperative BCVA in our patients was 0.16 ± 0.07 ranging from 0.1 to 0.4 in group A and 0.20 ± 0.10 ranging from 0.1 to 0.4 in group B. The mean postoperative BCVA was 0.29 ± 0.11 ranging from 0.05 to 0.4 in group A and 0.36 ± 0.14 ranging from 0.1 to 0.5 in group B. Compared to the preoperative, this was statistically significant in both groups (**Table 1**).

Table (1): Comparison between Group A and Group B according to BCVA

BCVA \ Groups	Group A (n=25)	Group B (n=25)	p-value
Pre			
Mean±SD	0.16±0.07	0.20±0.10	0.098
Range	0.1-0.4	0.1-0.4	
Post			
Mean±SD	0.29±0.11	0.36±0.14	0.067
Range	0.05-0.4	0.1-0.5	
Paired Sample t-test	4.985	4.650	
p-value	<0.001	<0.001	

The mean preoperative CMT in our patients was 495.64 ± 113.37 μm ranging from 309 μm to 752 μm in group A and 515.20 ± 82.47 μm ranging from 334 μm to 684 μm in group B. The mean postoperative CMT was 323.24 ± 63.21 μm

ranging from 219 μm to 459 μm in group A and 292.96 ± 59.33 μm ranging from 146 μm to 427 μm in group B. Compared to preoperative value This was statistically highly significant in both groups (**Table 2**).

Table (2): Comparison between Group A and Group B according to CMT

CMT \ Groups	Group A (n=25)	Group B (n=25)	p-value
Pre			
Mean±SD	495.64±113.37	515.20±82.47	0.597
Range	309-752	334-684	
Post			
Mean±SD	323.24±63.21	292.96±59.33	0.067
Range	219-459	146-427	
Paired Sample t-test	6.743	10.938	
p-value	<0.001	<0.001	

The mean preoperative P1 amplitude in ring (1+2) (nV/degree²) was 33.36±9.65 ranging from 15 to 60 in group A and 35.40±10.99 ranging from 18 to 62 in group B. The mean postoperative P1 amplitude in ring (1+2) was 43.00±9.51 ranging from 18 to 62 in group A and 42.16±11.84 ranging from 20 to 73 in group B. Compared to preoperative value this was statistically significant difference in both groups.

The mean preoperative P1 latency (ms) in ring (1+2) was 51.12±11.43 ranging from 32 to 70 in group A and 54.85±12.03 ranging from 31 to 65 in group B. The mean post-operative P1 latency (ms) in ring (1+2) was 36.12±8.28 ranging from 20 to 50 in group A and 39.60±10.09 ranging from 23 to 48 in group B. Compared to preoperative value this was statistically highly significant difference in both groups (Table 3).

Table (3): Comparison between Group A and Group B according to MF-ERG

MF-ERG \ Groups	Group A (n=25)	Group B (n=25)	p-value
Amplitude			
Pre			
Mean±SD	33.36±9.65	35.40±10.99	0.630
Range	15-60	18-62	
Post			
Mean±SD	43.00±9.51	42.16±11.84	0.764
Range	18-62	20-73	
Paired Sample t-test	3.558	2.291	
p-value	0.009	0.026	
Latency			
Pre			
Mean±SD	51.12±11.43	54.85±12.03	0.303
Range	32-70	31-65	
Post			
Mean±SD	36.12±8.28	39.60±10.09	0.121
Range	20-50	23-48	
Paired Sample t-test	5.314	5.311	
p-value	<0.001	<0.001	

Amsler grid test was positive in 6 cases (24 %) in group A and 8 cases (32%) in group B.

Only one eye (0.04%) in group A had an iatrogenic break that was treated intraoperatively by endo-laser photocoagulation and air tamponade with postoperative face down positioning. No iatrogenic breaks occurred in group B.

Postoperative vitreous hemorrhage developed in 3 cases: one case (0.04%) in group A, and 2 cases (0.08%) in group B,

with spontaneous resolution at 1 month postoperatively.

Three eyes of iridocyclitis occurred in phacovitrectomy cases: one eye in group A, and 2 eyes in group B. this was treated by frequent topical steroid with cycloplegic eye drops under topical antibiotic cover.

At the end of study, we had 8 cases developed cataract: 5 out of 20 phakic eyes in group A (25%), and 3 out of 18 phakic eyes in group B (16.7%).

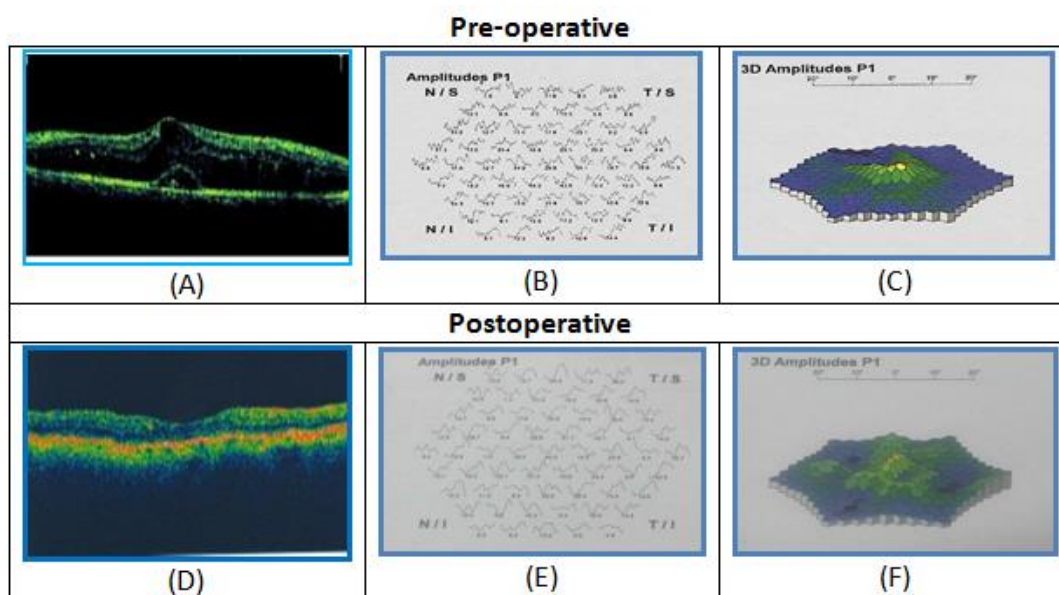


Figure (1): A case of DME before and after PPV and ILM peeling

- (A) OCT image preoperative.
- (B) Trace array image of MF-ERG preoperative.
- (C) 3-D topography image of MF-ERG preoperative.
- (D) OCT image postoperative.
- (E) Trace array image of MF-ERG postoperative.
- (F) 3-D topography image of MF-ERG postoperative.

DISCUSSION

Despite improvement in medical and surgical treatments, DR remains one of the major causes of visual reduction throughout the world. The visual reduction always related to DME and/or retinal neovascularization (Torabi, 2018).

It was found that posterior hyaloid strongly adherent to the retina in diabetic eyes making posterior vitreous detachment rare in diabetic patients and that adherent vitreous may decrease the benefit of intravitreal injection. Therefore, some authors have suggested vitrectomy with or without removal of ILM for treatment of DME (Modarres, 2016).

There have been a number of studies evaluating the role of vitrectomy for non tractional DME and showed variable

results some found positive outcomes; others found good anatomical but less impressive visual results. While some suggested that vitrectomy is not beneficial in non tractional DME (Bandello *et al.*, 2010 and Haller *et al.*, 2010).

Since the 1990s many studies have demonstrated that PPV is effective treatment for DME (Kim *et al.*, 2015, Kumagai *et al.*, 2015, Raizada *et al.*, 2015, Ulrich, 2017 and Someya *et al.*, 2019). A number of subsequent studies reported much less favorable results (Hoerauf *et al.*, 2011, Simunovic *et al.*, 2014 and Jackson *et al.*, 2017).

ILM in diabetic retinopathy patients develops pathological thickening, peeling of this thickened membrane has been suggested to improve retinal plasticity and facilitate diffusion of water retained in the

retina decreasing macular edema (*Hoerauf et al., 2011*). ILM peeling has been added to vitrectomy for DME though its effect is not yet certain (*Shamsi et al., 2013*). Also, ILM peeling can relieve macular traction caused by residual posterior vitreous cortex and furthermore, it prevents secondary epimacular membrane and eliminates the scaffold for astrocyte proliferation (*Shamsi et al., 2013*). However, some authors insist that ILM peeling is not beneficial in non tractional DME (*Flaxel et al., 2010*).

In our study, we found that there was better improvement of CMT and BCVA in group B (peeling group) than in group A (PPV only group) although no statistical significance between both groups. MF ERG parameters showed significant improvement in both groups regarding amplitude and latency which again showed no statistical significance between both groups.

The structural improvement (decrease in CMT) agreed with most of the previously published reports, The functional improvement (VA results) agreed with some reports (*Kumagai et al., 2015, Raizada et al., 2015 and Someya et al., 2019*). But not others (*Flaxel et al., 2010, Haller et al., 2010 and Hoerauf et al., 2011*).

Many studies have reported that there is no VA outcome benefit to ILM peeling compared to no ILM peeling (*Kumagai et al., 2015, Nakajima et al., 2015 and Rinaldi et al., 2018*).

Kumagai et al. (2015) concluded that vitrectomy with and without peeling of ILM seem to be beneficial in eyes with diffuse nontractional DME, and its effectiveness was sustained long term.

In contrast to our study, *Hoerauf and colleagues (2011)* reported no improvement in visual acuity in diabetic patients and cystoid DME without evident of Vitreo macular traction following vitrectomy with or without ILM removal *Bonnin and his associates (2015)* compared the long-term outcomes of vitrectomy including ILM peeling in eyes with tractional and non tractional DME. At 3 years, the mean LogMAR BCVA and CMT had improved significantly in both groups. At the final visit, there was no significant difference between the 2 groups in regard to visual acuity or central macular thickness improvement and they concluded that vitrectomy including ILM peeling showed anatomically and functionally good effects in both groups.

Raizada et al. (2015) in his retrospective study analyzing the results of PPV and ILM peeling in DME without VMT in 22 eyes, the authors reported that 13 eyes (59.1%) improved in VA, 4 eyes (18.2%) showed no improvement in VA and 5 eyes (22.7%) decrease in VA. As regard CMT all the 22 (100%) eyes showed decrease in CMT postoperatively. From mean pre-operative 410.1 μm to 248.8 μm post-operative.

The study of *Kim et al. (2015)* concluded that vitrectomy is an effective treatment for refractory DME, especially in patients without enlarged FAZ.

Ulrich (2017) reported improved retinal anatomy and visual acuity.

Someya et al. (2019) concluded that mean VA and CMT improved significantly in both groups.

Our study focused on P1 amplitude and implicit time in ring 1 and 2. Ring 1 (0–

2.3°) corresponds roughly to the fovea and ring 2 (2.3–7.4°) to the parafovea and partially to the perifovea. Mf ERG parameters showed significant improvement in both ILM & non-ILM peeled groups regarding amplitude and latency which showed no statistical significance between both groups.

Kim et al. (2010) found that the MF-ERG implicit time changes were significant after vitrectomy in DME. It was found that preoperative MF-ERG parameters, especially the implicit time can be useful indicators for predicting functional visual prognosis after vitrectomy in DME.

In our study, Amsler test was positive in 24 % in group A and 32% in group B. Similarly, *Kalinowska et al. (2018)* stated that Amsler test was abnormal in 37% in the DME group and it was normal in the group with diabetes without DME.

Gupta and Khan (2014) found that: Group A had 84 eyes Amsler grid (AG) test was positive in 39%. Group B had 41 eyes. AG test was positive in 63 % .Group C had 21 eyes AG was positive in 66%.

Although PPV is considered as an effective technique in treating PDR, there are some adverse complications associated with the procedure, these include retinal detachment (RD), neovascular glaucoma (NVG), recurrent vitreous hemorrhage (VH) and cataract progression (*Newman, 2010*).

Someya et al. (2019) reported postoperative VH in 23% and NVG in 5.1%. Cataract progression occurred in 4.3%. Revitrectomy needed in 11.2%, intravitreal anti-VEGF injection needed in

5.1%. Subtenon steroid injection also needed in 11.2%.

Kumagai et al. (2015) reported postoperative major complications included glaucoma in 4.5%, hard exudate deposits in the macula in 4.2%, NVG in 3.9%, and vitreous hemorrhage in 2.1%.

Haller et al. (2010) reported postoperative complications after 6 months were increased IOP required treatment, vitreous hemorrhage in, retinal detachment, and endophthalmitis.

CONCLUSION

PPV with and without ILM peeling improved refractory DME even without evidence of VMT.

REFERENCES

1. **Agarwal, D., Gelman, R., Prospero Ponce, C., Stevenson, W. and Christoforidis, J. B. (2015):** The Vitreomacular Interface in Diabetic Retinopathy. *Journal of Ophthalmology*, 39: 29-38.
2. **Bandello, F., Battaglia Parodi, M., Lanzetta, P., Loewenstein, A., Massin, P., Menchini, F. and Veritti, D. (2010):** Diabetic macular edema. *Developments in Ophthalmology*, 47: 73–110.
3. **Bonnin, S., Sandali, O., Bonnel, S., Monin, C. and El Sanharawi, M. (2015):** vitrectomy with internal limiting membrane peeling for tractional and nontractional diabetic macular edema: Long-term Results of a Comparative Study. *Retina (Philadelphia, Pa.)*, 35(5): 921–928.
4. **Haller, J. A., Qin, H., Apte, R. S., Beck, R. R., Bressler, N. M., Browning, D. J., Danis, R. P., Glassman, A. R., Googe, J. M., Kollman, C., Lauer, A. K., Peters, M. A. and Stockman, M. E. (2010):** Vitrectomy outcomes in eyes

- with diabetic macular edema and vitreomacular traction. *Ophthalmology*, 117(6): 1087–1093.e3.
5. **Flaxel, C. J., Edwards, A. R., Aiello, L. P., Arrigg, P. G., Beck, R. W., Bressler, N. M., Bressler, S. B., Ferris, F. L., 3rd, Gupta, S. K., Haller, J. A., Lazarus, H. S. and Qin, H. (2010):** Factors associated with visual acuity outcomes after vitrectomy for diabetic macular edema: diabetic retinopathy clinical research network. *Retina (Philadelphia, Pa.)*, 30(9): 1488–1495.
 6. **Gupta, P. and Khan, P. (2014):** Amsler Grid Test- A Simple Cost Effective Screening Modality for Diabetic Retinopathy. *Sch. Acad. J. Biosci.*, 2(8): 532-535
 7. **Hoerauf, H., Brüggemann, A., Muecke, M., Lüke, J., Müller, M., Stefánsson, E., Hammes, H. P. and Weiss, C. (2011):** Pars plana vitrectomy for diabetic macular edema. Internal limiting membrane delamination vs posterior hyaloid removal. A prospective randomized trial. *Graefe's archive for clinical and experimental ophthalmology. Albrecht von Graefes Archiv für klinische und experimentally Ophthalmology*, 249(7): 997–1008.
 8. **Jackson, T. L., Nicod, E., Angelis, A., Grimaccia, F., Pringle, E. and Kanavos, P. (2017):** Pars plana vitrectomy for diabetic macular edema: A Systematic Review, Meta-Analysis, and Synthesis of Safety Literature. *Retina (Philadelphia, Pa.)*, 37(5): 886–895.
 9. **Jung, Y. H. and Lee, Y. (2019):** Efficacy of vitrectomy combined with an intraoperative dexamethasone implant in refractory diabetic macular edema. *Acta Diabetologica*, 56(6): 691–696.
 10. **Kalinowska, A., Nowomiejska, K., Brzozowska, A., Maciejewski, R. and Rejdak, R. (2018):** Metamorphopsia Score and Central Visual Field Outcomes in Diabetic Cystoid Macular Edema. *BioMed Research International*, 2018, 49(5): 32-45.
 11. **Kim, J., Kang, S. W., Shin, D. H., Kim, S. J. and Cho, G. E. (2015):** Macular ischemia and outcome of vitrectomy for diabetic macular edema. *Japanese Journal of Ophthalmology*, 59(5): 295–304.
 12. **Kim, Y. M., Lee, S. Y. and Koh, H. J. (2010):** Prediction of postoperative visual outcome after pars plana vitrectomy based on preoperative multifocal electroretinography in eyes with diabetic macular edema. *Graefe's archive for clinical and experimental ophthalmology. Albrecht von Graefes Archive für klinische und experimentally Ophthalmology*, 248(10): 1387–1393.
 13. **Kumagai, K., Hangai, M., Ogino, N. and Larson, E. (2015):** Effect of internal limiting membrane peeling on long-term visual outcomes for diabetic macular edema. *Retina (Philadelphia, Pa.)*, 35(7): 1422–1428.
 14. **Modarres M. (2016):** Vitrectomy for diabetic macular edema; where are we?. *Journal of current ophthalmology*, 28(4): 161–162.
 15. **Nakajima, T., Roggia, M. F., Noda, Y. and Ueta, T. (2015):** Effect of internal limiting membrane peeling during vitrectomy for diabetic macular edema: Systematic Review and Meta-analysis. *Retina (Philadelphia, Pa.)*, 35(9): 1719–1725.
 16. **Newman DK. (2010):** Surgical management of the late complications of proliferative diabetic retinopathy. *Eye (London, England)*, 24(3): 441–449.
 17. **Raizada, S., Al Kandari, J., Al Diab, F., Al Sabah, K., Kumar, N. and Mathew, S. (2015):** Pars plana vitrectomy versus three intravitreal

- injections of bevacizumab for nontractional diabetic macular edema. A prospective, randomized comparative study. *Indian Journal of Ophthalmology*, 63(6): 504–510.
18. **Rinaldi, M., dell'Omo, R., Morescalchi, F., Semeraro, F., Gambicorti, E., Cacciatore, F., Chiosi, F. and Costagliola, C. (2018):** ILM peeling in nontractional diabetic macular edema: review and met analysis. *International Ophthalmology*, 38(6): 2709–2714.
 19. **Shamsi, H. N., Masaud, J. S. and Ghazi, N. G. (2013):** Diabetic macular edema: New promising therapies. *World Journal of Diabetes*, 4(6): 324–338.
 20. **Simunovic, M. P., Hunyor, A. P. and Ho, I. V. (2014):** Vitrectomy for diabetic macular edema: a systematic review and meta-analysis. *Canadian journal of ophthalmology. Journal Canadian d'ophtalmologie*, 49(2): 188–195.
 21. **Someya, H., Takayama, K., Takeuchi, M., Yokoyama, H., Kimura, T., Morioka, M., Takamura, Y., Sameshima, S., Ueda, T., Ogata, N., Tashiro, M., Kitano, S. and Sakamoto, T. (2019):** Outcomes of 25-Gauge Vitrectomy for Tractional and Nontractional Diabetic Macular Edema with Proliferative Diabetic Retinopathy. *Journal of Ophthalmology*, 53(4): 5-24.
 22. **Takamura, Y., Ohkoshi, K. and Murata, T. (2018):** New Strategies for Treatment of Diabetic Macular Edema. *Journal of Ophthalmology*, 42(9):21-54.
 23. **Torabi, H. (2018):** Management of Refractory Diabetic Macular Edema: A Review Article. *International Journal of Medical Reviews*, 5(1): 27-34.
 24. **Ulrich J. N. (2017):** Pars Plana Vitrectomy with Internal Limiting Membrane Peeling for Nontractional Diabetic Macular Edema. *The Open Ophthalmology Journal*, 11: 5–10.
 25. **Wong, T. Y., Cheung, C. M., Larsen, M., Sharma, S. and Simó, R. (2016):** Diabetic retinopathy. *Nature reviews. Disease Primers*, 2: 12-16.

دراسة مقارنة بين إستئصال الجسم الزجاجي مع تقشير الغشاء
الداخلي المحدد لماقولة العين أو بدون تقشير ه في حالات
إرتشاح ماقولة العين السكرى المستعصى
فتحى محمد ابو الفتوح الصالحى, هشام فوزى خليل, محمد محمد على ابراهيم

قسم طب وجراحة العيون, كلية الطب, جامعة الازهر

E-mail: fathyelsalhy2010@gmail.com

خلفية البحث: يعد ارتشاح ماقولة العين السكرى سببا رئيسيا لضعف الابصار فى الوقت الحالى, وتقدر نسبة الاصابة به فى مرضى السكر (10%), وتصل الى (29%) فى مرضى السكر ذو فترة اكثر من عشرين سنة.

الهدف من البحث: توضيح فعالية عملية استئصال الجسم الزجاجي فى علاج ارتشاح ماقولة العين السكرى المستعصى, وفروق النتائج التشريحية و الوظيفية بين إستئصال الجسم الزجاجي مع تقشير الغشاء الداخلى المحدد لماقولة العين أو بدون تقشير ه.

المرضى وطرق البحث: تم عمل الدراسة على خمسين عينا لمرضى يعانون من ارتشاح الماقوله السكرى المستعصى. وتم تقسيم المرضى الى مجموعتين متساويتين:

المجموعه (ا): تم فيها إستئصال الجسم الزجاجي بدون تقشير الغشاء الداخلى للشبكية.

المجموعه (ب): تم فيها إستئصال الجسم الزجاجي مع تقشير الغشاء الداخلى للشبكية.

وقد تم أخذ التاريخ المرضي للحالات و الفحص من حيث قياس حدة الإبصار و قياس إنكسار العين و قياس ضغط العين و فحص قاع العين و تم عمل التصوير المقطعى البصرى و اشعه بصبغه الفلورسن على قاع العين و رسم الشبكيه متعدد البورى.

وقد أجريت الدراسة في مستشفيات جامعة الأزهر بالقاهرة فى الفترة ما بين مايو 2019 إلى فبراير 2021.

نتائج البحث: اظهرت هذه الدراسة تحسناً ملحوظاً فى حدة الابصار فى كلتا المجموعتين حيث تحسنت من (0.16) إلى (0.29) فى المجموعة أ, وفى المجموعة ب من (0.20) الى (0.36) كما حدث إنخفاض فى سمك ماقولة العين من (495 ميكرون) الى (323 ميكرون) فى المجموعة أ ومن (515 ميكرون) الى (292) فى المجموعة ب.

وقد تحسن رسم الشبكيه متعدد البؤرى من حيث قوة ووقت الاستجابية حيث ان قوة الاستجابة تحسنت من (33) إلى (43) فى المجموعة أ, ومن (35) إلى (42) فى المجموعة ب, ووقت الاستجابة من 51 مللى ثانية إلى 36 فى المجموعة أ, ومن 54 إلى 39 فى المجموعة ب, إلا أن التحسن لم يكن ذو قيمة إحصائية بين المجموعتين.

الاستنتاج: أدت عملية إستئصال الجسم الزجاجى مع أو بدون تقشير الغشاء الداخلى المحدد للماقولة إلى تحسن حالات إرتشاح ماقولة العين السكرى المستعصى, وقد ظهر هذا التحسن فى صور رتين: الأولى تحسن تشريحي من حيث إنخفاض سمك الماقولة, والثانية تحسن وظيفى من حيث التحسن فى حدة الابصار ووقت وقوة الاستجابة فى رسم الشبكية متعدد البؤر.

الكلمات الدالة: إستئصال الجسم الزجاجى, تقشير الغشاء الداخلى المحدد للشبكية, إرتشاح ماقولة العين السكرى المستعصى.