

## An Updated Overview of Keratoconus Management: Review Article

Mohamed Magdy Ibrahim Mahmoud\*, Alaa Mohamed Hamdy,

Ashraf Bor'i Mohamed, and Yasmine Ahmed Daa El Din

Department of Ophthalmology, Faculty of Medicine, Zagazig University, Egypt

\*Corresponding author: Mohamed Magdy Ibrahim Mahmoud, Mobile: (+20) 01012821666,

E-Mail: mohamedmedo.1234yes@gmail.com

### ABSTRACT

**Background:** Non-inflammatory corneal stromal thinness causes the central or paracentral region of the cornea to thin and protrude anteriorly, leading to myopia, irregular astigmatism, and vision impairment with keratoconus (KC). About 90% of the time, it is bilateral, but the severity and progression are asymmetrical. It normally begins around the time of puberty and continues until the third or fourth decade of life before stopping. The severity of the condition, the degree of visual impairment, and the benefits and drawbacks of each treatment option all play a role in determining the best course of medical or surgical treatment.

**Objective:** review article aimed to assess the new modalities of keratoconus management.

**Methods:** PubMed, Google scholar and Science direct were searched using the following keywords: Keratoconus, keratoconus management, corneal cross linking and intrastromal corneal ring segments. The authors also screened references from the relevant literature, including all the identified studies and reviews, only the most recent or complete study was included between March 2009 and January 2022. Documents in a language apart from English have been excluded as sources for interpretation. Papers apart from main scientific studies (documents unavailable as total written text, conversation, conference abstract papers and dissertations) were excluded.

**Conclusion:** It is possible to conduct corneal cross linking and intrastromal corneal ring segments methods simultaneously or in a sequential order, which has a beneficial effect on KC treatment. Several other methods with promising outcomes have been described in the literature.

**Keywords:** Keratoconus, Management, Corneal cross linking, Intrastromal corneal ring segments.

### INTRODUCTION

Anteriorly bulging, cone-shaped cornea in KC is caused by non-inflammatory thinning of the corneal stroma. This causes myopia, astigmatism, and other vision problems, including blurred vision. About 90% of the time, it is bilateral, but the severity and progression are asymmetrical. It normally begins around the time of puberty and continues until the third or fourth decade of life before stopping. Both men and women are at risk from the side effects of KC according to sex, but it isn't apparent whether there is a major difference between men and women <sup>(1)</sup>.

The aim of the review article was assessment of new modalities of management of keratoconus.

### ETIOLOGY AND PATHOGENESIS

A mix of genetic and environmental factors appears to be at the root of KC, but the exact extent to which each component contributes to the disease's development remains a mystery <sup>(1)</sup>.

#### A- Genetic factors:

Study after study has demonstrated that there is a genetic basis for KC, including family studies, twin studies, and genomic analyses <sup>(1)</sup>.

#### Family studies:

More than 15-67 times greater than the overall population's prevalence of KC among first degree relatives (3.34 percent). Keratoconic patients' family histories in two or three generations show a hereditary component <sup>(1)</sup>.

#### Twin studies:

Most of the time, both identical twins were affected, though to varying degrees of severity, which shows that disease development has a strong genetic component <sup>(2)</sup>.

#### B- Environmental factors:

Many studies have linked the condition to environmental variables such as atopic dermatitis, frequent eye rubbing, and wearing contact lenses <sup>(3)</sup>.

### DIAGNOSIS

Asymptomatic onset is typical for KC. Myopia, uneven astigmatism, corneal thinning, steepening, and corneal scarring all contribute to deterioration of vision and frequent eyeglasses replacement. Patients with acute hydrops, which is caused by a sudden inflow of aqueous into the cornea due to cracks in the Descemet's membrane, complain of pain, photophobia, and a loss in vision <sup>(4)</sup>.

#### \*External signs:

- Downgaze with bulging lower eyelids (Munson's sign).  
- This is known as Rizzuti's sign, and it occurs when the cornea is lighted from the temporal side <sup>(5)</sup>.

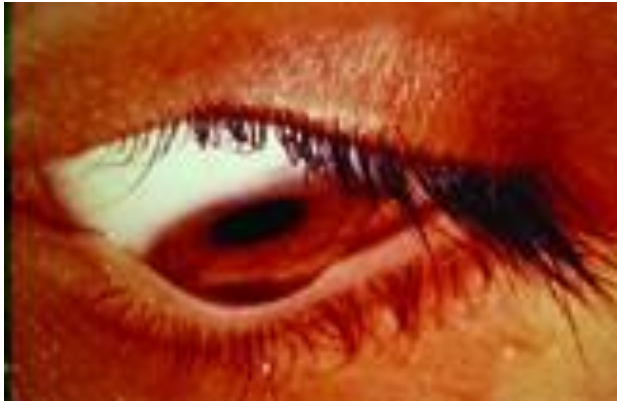#### \* Slit lamp signs:

- Corneal stroma and Descemet's membrane are marked by small vertical lines known as Vogt's striae.  
- There is an iron deposition ring around the cone's base, known as the Fleischer's ring, which might be partial or complete.  
- Thinner stroma.  
- Scarring in the epithelium or beneath the epithelium <sup>(5)</sup>.

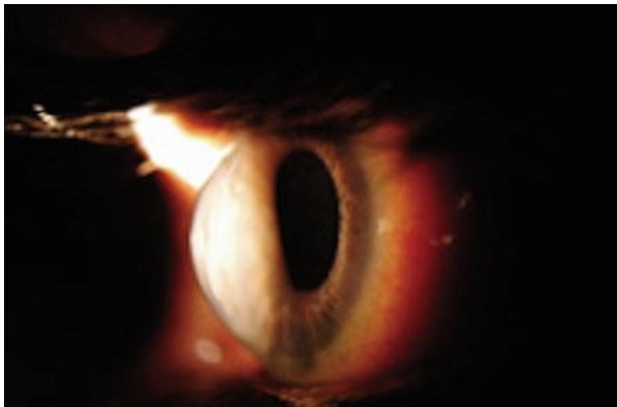
**\* Retroillumination signs:**

- Irregular astigmatism causes the scissoring appearance on the retinoscopy because the light reflex seems to have a dark centre rather than being equally distributed.
- Ophthalmoscopy oil droplet reflex; entire internal reflection of light by conical cornea creates a dark, round shadow in the mid-peripheral of the cornea, separating the bright red reflex at its centre and red corneal periphery reflexes.

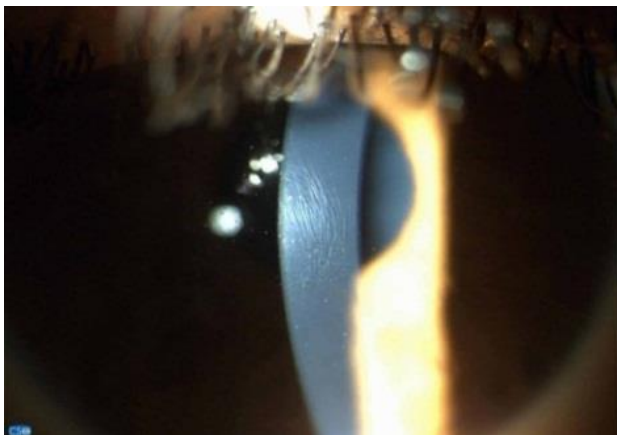*In advanced cases* acute hydrops may occur and is characterized by diffuse stromal edema <sup>(5)</sup>.



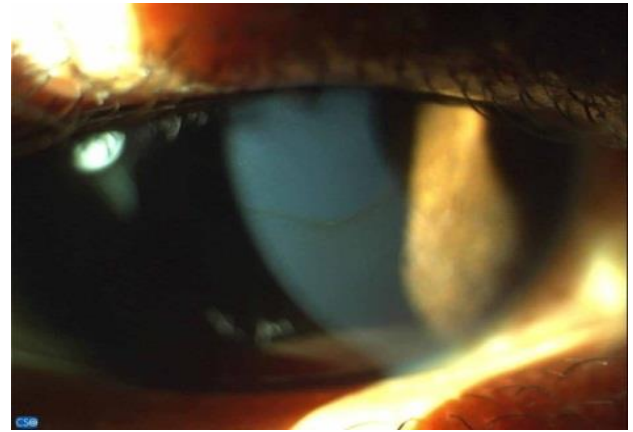
**Figure (1):** Munson's sign <sup>(6)</sup>.



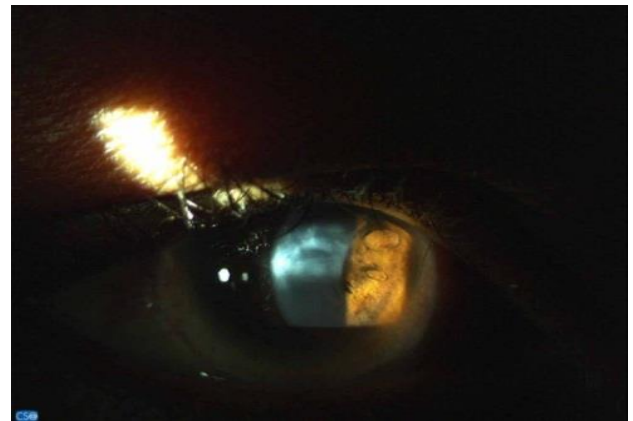
**Figure (2):** Rizzuti's sign <sup>(6)</sup>.



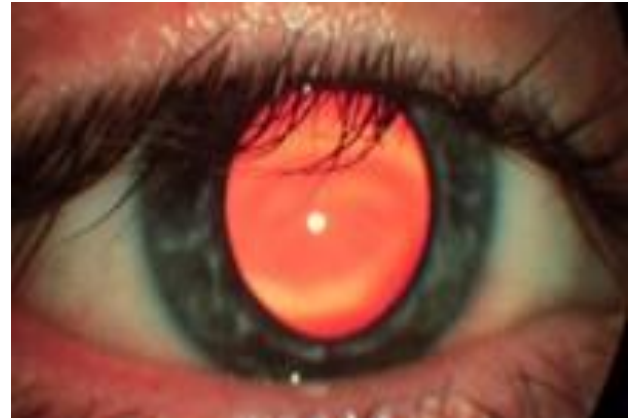
**Figure (3):** Vogt's striae <sup>(7)</sup>.



**Figure (4):** Fleischer's ring <sup>(7)</sup>.



**Figure (5):** Scarring associated with KC <sup>(7)</sup>.



**Figure (6):** Oil droplet reflex <sup>(8)</sup>.

**INVESTIGATIONS**

Corneal topography is derived from the Greek terms “place” (topo) and “write” (graphein), which means to describe a place. This has traditionally been connected to the study of the shape and features of the Earth's surface or those of other planets and moons <sup>(9)</sup>.

**\* Keratometry:**

The anterior corneal surface functions as a convex mirror reflecting light incidence on it. Hence, keratometers are employed to measure the curvature of the middle 3 mm of the cornea <sup>(10)</sup>.

**\* Keratometry:**

More than 70% of the corneal surface can be assessed with this qualitative tool <sup>(10)</sup>.

**\* Videokeratometry:**

In 1984, Klyce's combination of rapid computer processing and digital video led to the first computer imaging of the cornea <sup>(10)</sup>.

**\* Scheimpflug principle-based systems:**

An object that is not parallel to the lens and image planes of the camera, such as the anterior segment of the eye photographed by slit lamp photography, can be documented using the Scheimpflug principle with the maximum feasible depth of focus and minimal picture distortion. Scheimpflug cameras in the human eye focus images from the cornea to the back of the lens in a precise manner <sup>(11)</sup>.

Galilei (Ziemer Group) detailed the use of a Scheimpflug camera and Placido-disk system in ophthalmology after the Pentacam (the first Scheimpflug camera in the field). Sirius (Costruzione Strumenti Oftalmici) and TMS-5 (Tomey Corp) are two new gadgets with a Scheimpflug camera and a Placido-disk system <sup>(11)</sup>.

It is possible to determine the anterior corneal curvature, thickness, and elevation of the cornea using a Scheimpflug-based technique. The steep keratometry (K) values, the inferior-superior asymmetry, and the skewing of the steep axis are the three most critical characteristics <sup>(12)</sup>.

## MANAGEMENT MODALITIES

It is important to consider the severity of the problem, the extent of visual impairment, and the benefits and downsides of each treatment option while deciding on the best course of action <sup>(13)</sup>.

### 1- Spectacles:

Only in the early stages of KC, spectacles can be used. As the condition progresses, so do the uneven astigmatism and aberrations, and wearing eyeglasses will no longer be enough to restore adequate vision <sup>(13)</sup>.

### 2- Contact lenses:

Early to moderate cases of KC have been successfully treated with contact lens usage <sup>(14)</sup>. There are hydrogel, silicone hydrogel, gas permeable, and hybrid contact lenses for KC that are available. The most often used type of contact lenses is gas permeable <sup>(15)</sup>. An anterior refractive surface is provided by rigid gas permeable contact lenses, which can mask corneal abnormalities <sup>(13)</sup>.

### 3- Corneal cross linking (CXL):

The purpose of this operation is to strengthen the cornea's biomechanical stiffness by improving the biochemical linkages between collagen fibres. UVA light and riboflavin, which acts as a photosensitizer, are used to achieve photopolymerization <sup>(16)</sup>.

For CXL, stopping or slowing the progression of corneal ectasia is its major goal. Following refractive surgery, the FDA has approved the treatment for patients between the ages of 14 and 65 who are experiencing progressive keratoconus or corneal ectasia <sup>(17)</sup>.

### 4- Intrastromal corneal ring segments (ICRS):

Just one or two segments of different degrees (90°–210°) or a complete ring (360°) MyoRing "polymethylmethacrylate (PMMA)". An incision (a channel) made in the steep axis of the cornea allows ICRS to be surgically inserted into the cornea to provide central corneal flattening, improvement of uncorrected and best corrected visual acuity <sup>(18)</sup>.

### 5- Combination of CXL and ICRS:

Synergistic effects can be achieved by combining the two methods simultaneously or sequentially. Local collagen alterations near the ICRS were previously assumed to be responsible for the drop in cylinder and keratometric values <sup>(19)</sup>.

### 6- Keratoplasty:

Advanced cases of KC require keratoplasty either partial-thickness deep anterior lamellar keratoplasty "DALK", which is useful in patients with KC who do not have significant scarring at Descemet's membrane or persistent hydrops <sup>(20)</sup>, or full-thickness penetrating keratoplasty "PKP" that is indicated in patients who have advanced progressive KC with significant corneal scarring <sup>(21)</sup>.

## CONCLUSION

It is possible to conduct Corneal cross linking and Intrastromal corneal ring segments methods simultaneously or in a sequential order, which has a beneficial effect on KC treatment. Several more treatment techniques with promising effects have been described in the literature.

**Conflict of interest:** The authors declared no conflict of interest.

**Sources of funding:** This research did not receive any specific grant from funding agencies in the public, commercial, or not-for-profit sectors.

**Author contribution:** Authors contributed equally in the study.

## REFERENCES

1. Hashemi H, Heydarian S, Hooshmand E *et al.* (2020): The Prevalence and Risk Factors for Keratoconus: A Systematic Review and Meta-Analysis. *Cornea*, 39 (2): 263–270.
2. Vingopoulos F, Zisimopoulos A, Kanellopoulos A (2022): Concordance of keratoconus in monozygotic twins before and after combined corneal crosslinking/photorefractive keratectomy (Athens Protocol) using Scheimpflug and OCT tomography. *Journal of Cataract and Refractive Surgery*, 48 (1): 83–88.

3. **McMonnies C (2014):** Mechanisms for acute corneal hydrops and perforation. *Eye & Contact Lens*, 40 (4): 257–264.
4. **David C, Reinstein D, Archer T et al. (2021):** Postoperative Corneal Epithelial Remodeling After Intracorneal Ring Segment Procedures for Keratoconus: An Optical Coherence Tomography Study. *Journal of Refractive Surgery*, 37 (6): 404–413.
5. **Santodomingo-Rubido J, Carracedo G, Suzaki A et al. (2022):** Keratoconus: An updated review. *Contact Lens & Anterior Eye. The Journal of the British Contact Lens Association*, 45 (3): 101559.
6. **Atalay E, Özalp O, Yıldırım N (2021):** Advances in the diagnosis and treatment of keratoconus. *Therapeutic Advances in Ophthalmology*, 13: 25158414211012796.
7. **Kreps E, Claerhout I, Koppen C (2021):** Diagnostic patterns in keratoconus. *Contact lens & Anterior Eye. The Journal of the British Contact Lens Association*, 44 (3): 101333.
8. **Lim L, Lim E (2020):** Current perspectives in the management of keratoconus with contact lenses. *Eye (London, England)*, 34 (12): 2175–2196.
9. **Masiwa L, Moodley V (2020):** A review of corneal imaging methods for the early diagnosis of pre-clinical Keratoconus. *Journal of Optometry*, 13 (4): 269–275.
10. **Fan R, Chan T, Prakash G et al. (2018):** Applications of corneal topography and tomography: a review. *Clinical & Experimental Ophthalmology*, 46 (2): 133–146.
11. **Awnallah M, Salamah M, Shawki M et al. (2020):** Changes in Anterior Chamber Depth and Angle Before and After Phacoemulsification of Intumescent Cataract. *Zagazig University Medical Journal*, 26 (4): 663–668.
12. **Imbornoni L, McGhee C, Belin M (2018):** Evolution of Keratoconus: From Diagnosis to Therapeutics. *Die Evolution in der Behandlung des Keratokonus: von der Diagnose zur Therapie. Klinische Monatsblätter für Augenheilkunde*, 235 (6): 680–688.
13. **Garcia-Ferrer J, Akpek E, Amescua G et al. (2019):** Corneal Ectasia Preferred Practice Pattern®. *Ophthalmology*, 126 (1): 170–74.
14. **Bilgin L, Yilmaz S, Araz B et al. (2009):** 30 years of contact lens prescribing for keratoconic patients in Turkey. *Contact Lens Anterior Eye*, 32: 16–21.
15. **Mitichkina T, Voronin G, Bunyatova L et al. (2021):** Possibilities of increasing contact lens tolerance in keratoconus (a clinical case study). *Vestnik Oftalmologii*, 137 (4): 90–97.
16. **Klyce S (2013):** UVA-riboflavin collagen cross-linking: a misnomer perhaps, but it works! *Invest Ophthalmol Vis Sci.*, 54 (3): 1635.
17. **Gomes J, Tan D, Rapuano C et al. (2015):** Global consensus on keratoconus and ectatic diseases. *Cornea*, 34 (4): 359–369.
18. **Vega-Estrada A, Jorge L (2016):** The use of intracorneal ring segments in keratoconus. *Eye and Vision (London, England)*, 3: 1186–1198.
19. **Mazzotta C, Sgheri A, Bagaglia S et al. (2020):** Customized corneal crosslinking for treatment of progressive keratoconus: Clinical and OCT outcomes using a transepithelial approach with supplemental oxygen. *Journal of Cataract and Refractive Surgery*, 46 (12): 1582–1587.
20. **Li H, Chen M, Zhou Q et al. (2021):** Biomechanical Effects of Deep Anterior Lamellar Keratoplasty and Penetrating Keratoplasty for Keratoconus: A Finite Element Analysis. *Translational Vision Science & Technology*, 10 (9): 15–19.
21. **Shams M, Sharifi A, Akbari Z et al. (2022):** Penetrating Keratoplasty versus Deep Anterior Lamellar Keratoplasty for Keratoconus: A Systematic Review and Meta-analysis. *Journal of Ophthalmic & Vision Research*, 17 (1): 89–107.