

## Assessment of Outcomes of Closed Reduction and Percutaneous Fixation of Lisfranc's Injuries of The Foot

Abduraouf Mosbah Ramadan El-Ajnaf\*, Mohammed Othman Mohammed, Ashraf Abd Eldayem Mohamed and Sami Ibrahim Sadek Ali

Orthopedic Surgery Department, Faculty of Medicine, Zagazig University, Egypt

\*Corresponding author: Abduraouf Mosbah Ramadan El-Ajnaf, Mobile: (+20)01095342010, Email: [lajnaf.raouf3@gmail.com](mailto:lajnaf.raouf3@gmail.com)

### ABSTRACT

**Background:** An early surgical intervention for metatarsal joint injuries (Lisfranc injury) is essential to prevent or treat any foot compartmental syndrome that is the most common outcomes.

**Objective:** to manage outcomes of percutaneous fixation with closed reduction in managing foot Lisfranc's injuries.

**Patients and Methods:** At Orthopedic Departments, Zagazig University Hospital, 18 patients with displaced Lisfranc injury were studied in prospective research. Closed reduction and percutaneous fixation of the Lisfranc injuries by k-wires or screw were done to all patients. All patients were periodically monitored clinically and radiographically for a week, then every 2, 4, 6, and 12 weeks after the index procedure.

**Results:** Favorable outcome were majority with 88.9% (16 cases) (11 patients excellent and 5 good) and unfavorable 11.1% (2 patients) (1 fair and 1 poor). The current study estimated the complication as overall with 4 cases and we found superficial infection in 22.2%, stiffness in only one case (5.6%) and delayed union in 1 case also no case of compartment syndrome of foot in our series.

**Conclusion:** Lisfranc injuries treated with k-wire or screw percutaneous reduction and fixation could be treated efficiently, quickly and simply surgically with predictable and dependable consequences without routine removal of hardware.

**Keywords:** Lisfranc's injuries, Percutaneous fixation, Closed reduction.

### INTRODUCTION

A Lisfranc injury is one in which one or more of the foot's metatarsals are displaced from the tarsus. It was a French surgeon and gynaecologist of the Napoleonic era in 1815 who first described the injury and described an amputation at that level. This name is ascribed to him <sup>(1)</sup>. Injuries to the Lisfranc joint account for 0.2% to 0.8% of all fractures. An 'mortise' between the midfoot and forefoot creates the base of the 2nd metatarsal, which helps to keep it in place at the ankle joint. When it comes to supporting the tarsal joint, interosseous ligament (Lisfranc's ligament) is the most significant structure. It encompasses from the medial cuneiform to the base of the second metatarsal. Joint stability depends heavily on this ligament and the inter cuneiforms interosseous ligament. If one of these ligaments is damaged, instability between the medial and middle columns will result. Because there is no ligament between the first and second metatarsals, the third, fourth, and fifth metatarsals are connected by inter-metatarsal and thin dorsomedial ligaments <sup>(2)</sup>.

This injury is caused by both low- and high-energy sources, such as a sports injury or a motor vehicle accident. Medially or laterally directed rotational forces or a direct impact to the joint are two common ways in which injuries occur <sup>(3)</sup>. Dislocations of the Lisfranc fracture have been categorised in a variety of ways. Myerson *et al.* <sup>(4)</sup> modifications of the Hardcastle classification is the most commonly used classification. Incongruity can be classified into three categories.: full incongruity refers to type A, partial incongruity is referred to as type B (B1 medial column and B2), and diverging injury in which the 1st digit is pushed medially and the mid- and side-columns are moved laterally is classified as type C.

Restrictions on movement and stability of the midfoot are part of conservative treatment. For non-

displaced Lisfranc injuries, cast immobilization for six to 12 weeks is the norm <sup>(3)</sup>. 1) Anteroposterior x-ray widening of the space between the 1st and 2nd metatarsals by > 4 mm is an indication for surgical therapy. 2) Tarsometatarsal incongruence of more than 2 mm in length. 3) Bony pieces trapped within the joint. 2nd Metatarsal Bone Fragment (M.T.B). The so-called "complex dislocation" occurs when soft tissue (e.g., the tibialis anterior tendon) is trapped in a joint <sup>(5)</sup>.

Several factors affect Lisfranc injury treatment, but the most critical is how severe the soft tissue damage was to begin with. surgical recovery period after an injury. A third aspect is the level of precision in the reduction process <sup>(6)</sup>.

Preventing and/or treating foot compartmental syndrome, the most common and most dreaded consequence, requires surgical intervention as soon as possible <sup>(7)</sup>. Treatment options include open reduction, temporary screw fixation, and primary arthrodesis in cases of severe fracture dislocations as well as closed reduction and percutaneous pinning <sup>(8)</sup>. It was the goal of this study to manage outcomes of percutaneous fixation with closed reduction in managing foot Lisfranc's injuries.

### PATIENTS AND METHODS

At Orthopedic Departments, Zagazig University hospital. 18 patients with displaced Lisfranc injury were studied in prospective research. Closed reduction and percutaneous fixation of the Lisfranc injuries by k-wires or screw were done to all patients.

#### Ethical consent:

Research Ethics Council at Zagazig University approved the study (ZU-IRB #8061) as long as all participants provided informed consent forms. Ethics

**guidelines for human experimentation were adhered to by the World Medical Association's Helsinki Declaration.**

**Inclusion criteria:** Acute Lisfranc injury, closed fracture, and fracture within 2 weeks.

**Exclusion criteria:** Infected fractures, open fractures, pathological fracture, and more than 2 weeks injury.

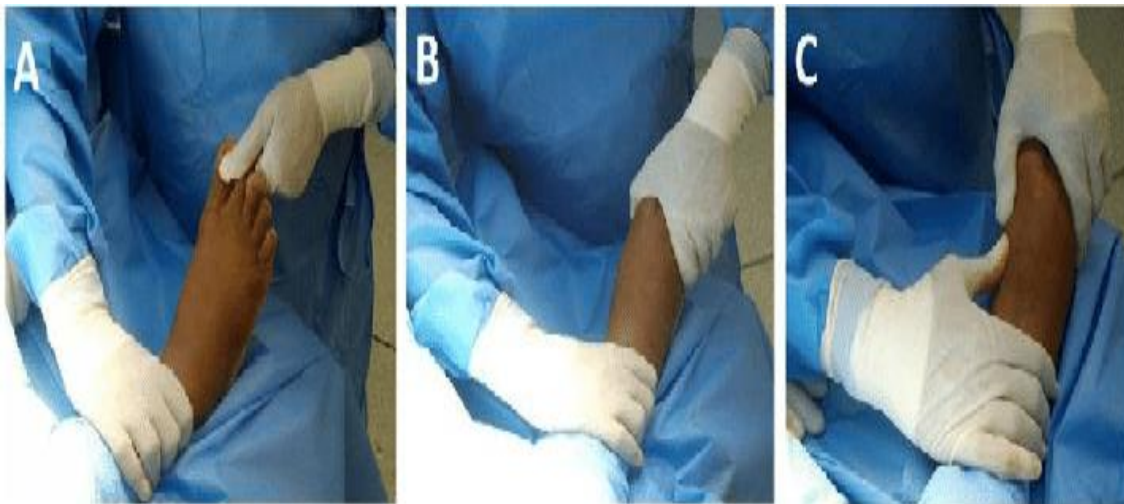
**This is what all of the participants in this research had to go through:**

1. A thorough review of the patient's medical history and an orthopedic examination.
2. X-rays: Oblique, lateral x-ray of the foot, as well as Weightbearing anteroposterior x-ray.
3. All patients had full preoperative lab investigation before surgery including: Complete blood picture,

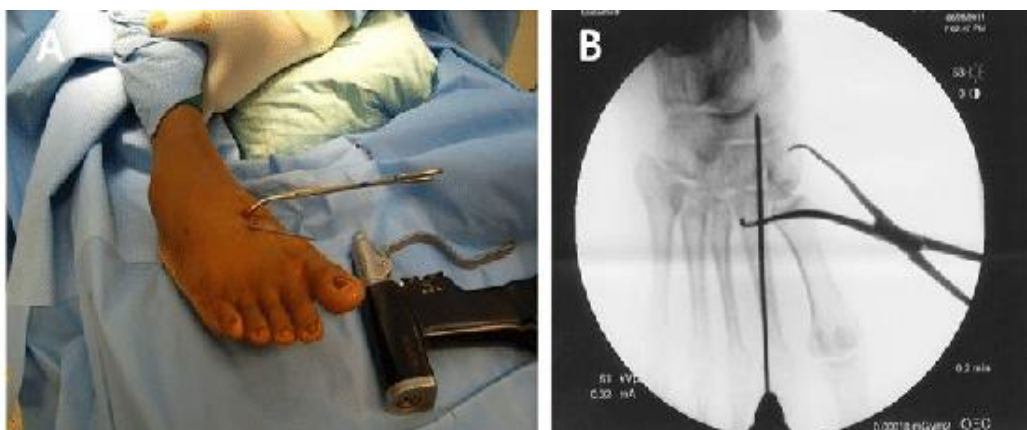
random blood sugar, viral screen, coagulation studies (PT/PTT) as well as kidney and liver function tests.

#### 4. Surgical technique:

An intravenous cephalosporin was used to provide broad-spectrum antibiotics prior to anesthetic induction. Depending on the patient's condition, either spinal or general anesthesia was used. In order to hold the patient's foot in a proper posture on the operating table, a triangle support was employed beneath the knee. An initial attempt at closed reduction was made using toe and leg traction. Forefoot and midfoot alignment were restored, allowing for the full range of motion in a human foot. A varus or valgus force was then given to the forefoot in order to minimize the forefoot varus or valgus deformation.



**Figure (1):** reduction, traction & manipulation. (Traction of toes in A, of foot in B, and manipulation of foot in C). After that, the particular metatarsal was reduced using direct pressure in its anatomic place. The misplaced bone was reduced using a pointed bone reduction forceps, which closed the joint space and temporarily held the reduction in place. For manipulation of the dislocated metatarsal, the K. wire through the distal shaft, which is subsequently advanced through bone's base and crossed joint with cuneiform or cuboid bone, can be utilized as joystick K wire.

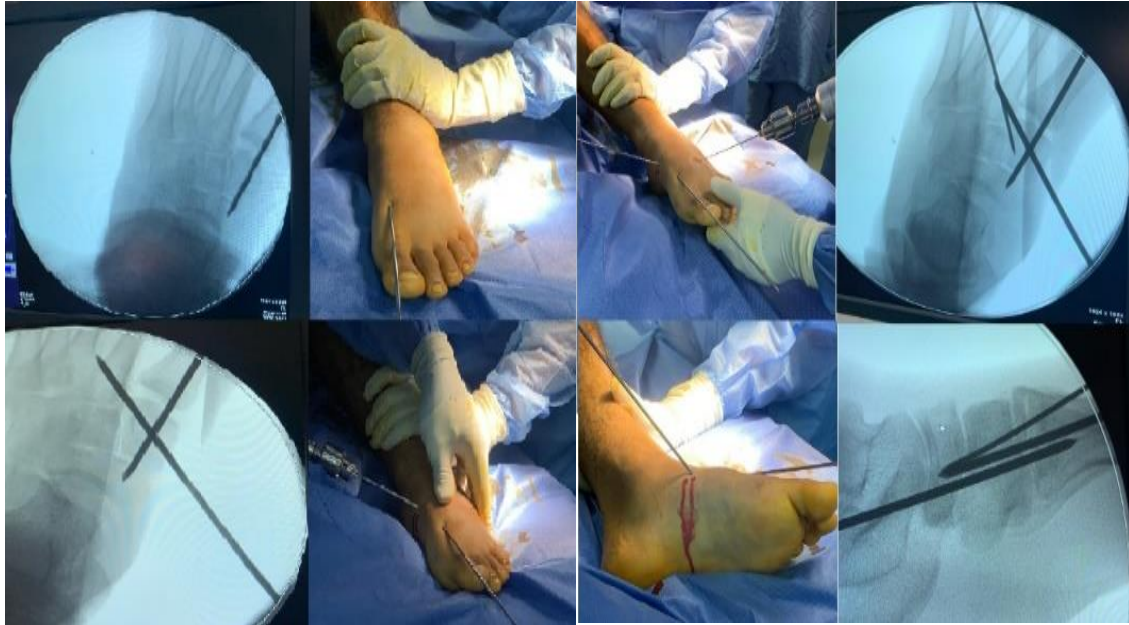

**Figure (2):** K. wires joystick reduction. K wire manipulating the displaced 2<sup>nd</sup> MT with fixation of displaced second MT.

**The following screws or k-wires were used to secure the medial column:**

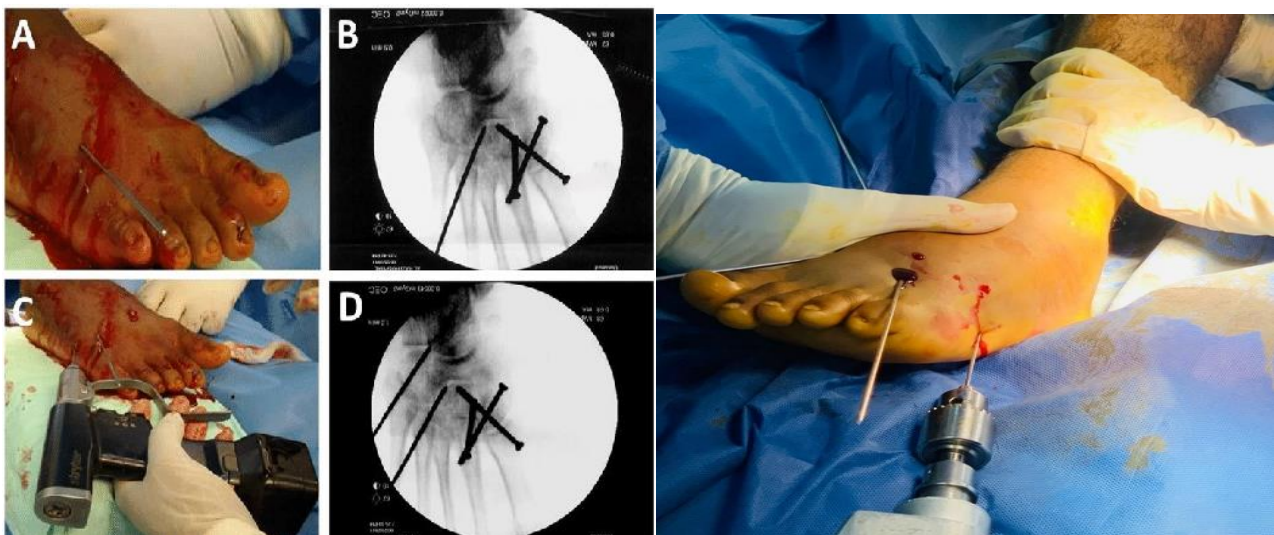
**Method of fixation of medial column by screws:** (1) Medial Cuneiform to base of 2nd MTB, one screw. (2) Inserting a second screw in a crossing manner with the first screw, i.e. from MT to cuneiform, adds further stability.

**Method of fixation of medial column by k- wires:** It was necessary to implant three K-wires, one each coming from the medial cuneiform and the second MT and the second MT and medial Cuneiform, respectively.



**Figure (3):** Fixation of medial column by K-wire.

The lateral column was stabilized by inserting one or two K wires into the base of the 4th and 5th MTs and guiding them proximally through the cuboid bone. Image intensifiers were used to verify the stability of the central column following fixation of the medial and lateral columns. Following anatomical attachment, a proper dressing, cast, and limp elevation were all placed.



**Figure (4):** Fixation of Lateral Column.



**Clinical Evaluation:**

Six weeks after an injury, the American Orthopedic Foot and Ankle Society's (AOFAS) clinical rating system (CRS) was utilized to evaluate the patient's pain and functional results.

**Statistical analysis**

In order to analyze the data acquired, Statistical Package of Social Sciences version 20 was used to execute it on a computer (SPSS). In order to convey the findings, tables and graphs were employed. The quantitative data were presented in the form of mean,

median, standard deviation, and confidence intervals. The information was presented using qualitative statistics such as frequency and percentage. The student's t test (T) was used to assess the data while dealing with quantitative independent variables. Pearson Chi-Square and Chi-Square for Linear Trend ( $X^2$ ) were used to assess qualitatively independent data. The significance of a P value of 0.05 or less was determined.

**RESULTS**

Mean age was  $33.89 \pm 8.17$  years. Males were majority (66.7%) and (38.9%) were smokers (Table 1).

**Table (1): Demographics**

		Age	
<b>Mean <math>\pm</math> SD</b>		33.89 $\pm$ 8.17	
<b>Median (Range)</b>		34.0 (22-45)	
		<b>N</b>	<b>%</b>
<b>Sex</b>	<b>Men</b>	12	67.7
	<b>Women</b>	6	33.3
<b>Smoker</b>	<b>Non</b>	11	61.1
	<b>Smoker</b>	7	38.9
	<b>Total</b>	18	100.0

Operation duration was distributed as  $109.17 \pm 21.84$  with minimum 85 and maximum 160 minutes. Union time, and time of full weight bearing were  $16.61 \pm 3.08$  and  $20.50 \pm 3.45$  weeks respectively (Table 2).

**Table (2): Operation, union time as well as time of full weight bearing**

		Operation duration (minutes)	
<b>Mean<math>\pm</math> SD</b>		109.17 $\pm$ 21.84	
<b>Median (Range)</b>		100.0 (85-160)	
		<b>Union time (weeks)</b>	<b>Time of full weight bearing (weeks)</b>
<b>Mean<math>\pm</math> SD</b>	16.61 $\pm$ 3.08	20.50 $\pm$ 3.45	
<b>Median (Range)</b>	16.0 (13-24)	19.5 (17-28)	

AOAFS score values are shown in table (3).

**Table (3): AOAFS score distribution**

<b>Pain score</b>	<b>Mean <math>\pm</math> SD</b>	35.55 $\pm$ 6.15
	<b>Median (Range)</b>	40.0 (20-40)
<b>ROM score</b>	<b>Mean <math>\pm</math> SD</b>	45.38 $\pm$ 4.14
	<b>Median (Range)</b>	46.5 (34-50)
<b>Alignment score</b>	<b>Mean <math>\pm</math> SD</b>	9.44 $\pm$ 1.61
	<b>Median (Range)</b>	10.0 (5-10)
<b>Total AOAFS</b>	<b>Mean <math>\pm</math> SD</b>	90.38 $\pm$ 10.82
	<b>Median (Range)</b>	94.0 (59-100)

Favorable outcomes were majority with 88.9% (16 cases) (11 patients excellent and 5 good) and unfavorable 11.1% (2 patients) (1 fair and 1 poor). The current study estimated the complication as overall with 4 cases and we found

superficial infection in 22.2%, stiffness in only one case (5.6%) and delayed union in 1 case and no case of compartment syndrome of foot in our series (Table 4).

**Table (4): Outcomes and complications**

		N	%
Outcome	Favorable (good & excellent)	16	88.9
	Unfavorable (fair & poor)	2	11.1
	Total	18	100.0
Superficial infection	Negative	14	77.8
	Positive	4	22.2
Stiffness	Negative	17	94.4
	Positive	1	5.6
Delay union	Negative	17	94.4
	Positive	1	5.6
Overall	Negative	14	77.8
	Positive	4	22.2
Total		18	100.0

Operation duration was significantly higher among unfavorable outcome group (Table 5).

**Table (5): Outcome and management correlation**

	Favorable	Unfavorable	t	P
Time to management (days)	4.18±1.60	4.50±1.85	0.254	0.802
Operation duration (minutes)	103.43±14.91	155.0±7.07	4.781	0.00**
Hospital stay (days)	3.52±0.71	4.50±0.70	1.622	0.124

Union time as well as time of full weight bearing were significantly higher among unfavorable outcome group (Table 6).

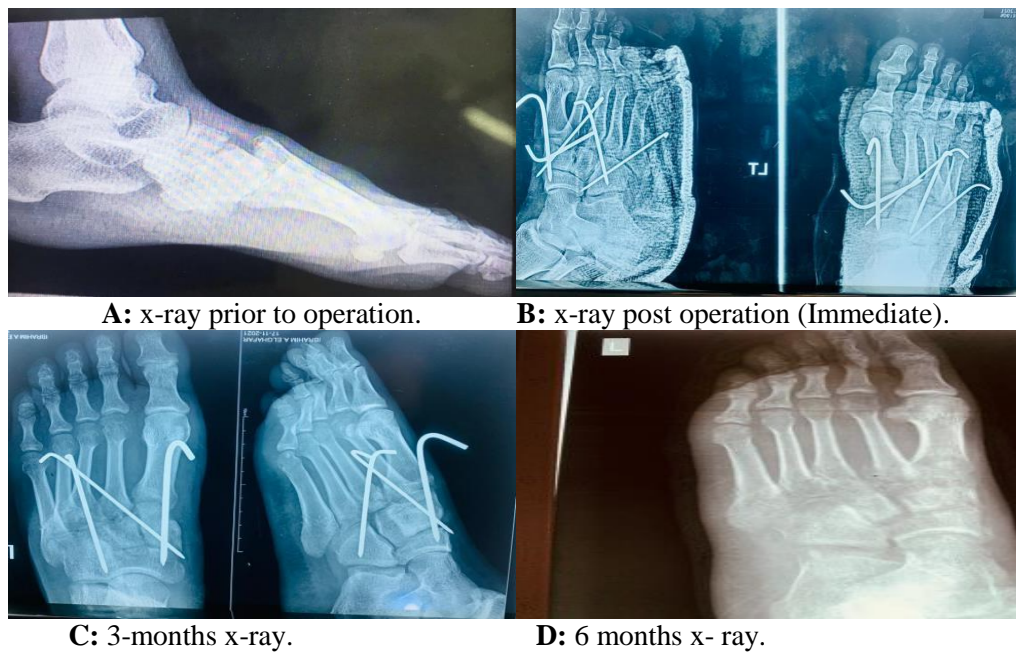
**Table (6): Outcome and union time correlation**

	Favorable	Unfavorable	t	P
Union time (weeks)	16.06±2.51	21.00±4.20	2.412	0.028*
Time of full weight bearing (weeks)	19.93±3.04	25.0±4.24	2.155	0.047*

Complications were significantly associated with unfavorable outcome group (Table 7).

**Table (7): Relation between outcome and complication**

		Favorable	Unfavorable	X <sup>2</sup>	P	
Complication	Not	N	14	0	6.97	0.008*
		%	87.5%	0.0%		
	Complicated	N	2	2		
		%	12.5%	100.0%		
Total		N	16	2		
		%	100.0%	100.0%		



**Fig. (5):** 22 years old male patient presented to The Emergency Hospital with pain, swelling and inability to bear weight on his left foot with history of road traffic accident. X-rays showed Lisfranc fracture dislocation with dorsal subluxation (partial incongruity type B1). The fractured limb was splinted in back slab and routine laboratory tests were done. Surgical intervention was done after three hours. Close reduction and percutaneous fixation done by multiple K-wires. 2 K-wires were removed after 8 weeks and all wires were removed at 16 weeks. Postoperative follow up for 24 weeks, AOFAS at final follow up good result

## DISCUSSION

Various tarsometatarsal joint injuries are referred to as "Lisfranc, tarsometatarsal." These injuries range from low-energy ligament disruptions to high-energy divergent intra-articular fracture dislocations that damage all five tarsometatarsal joints all at once. This study's conclusions are in direct conflict with previous ones<sup>(9)</sup>. It is estimated that between 20% and 40% of Lisfranc injuries are misdiagnosed or disregarded during the first evaluation procedure. Untreated cases might lead to major complications due to the severity of the underlying damage. Painful instabilities, visible deformities, and midfoot degenerative arthritis with restricted function are all prevalent complaints<sup>(10)</sup>.

Our study was conducted on 18 patients with mean age of  $33.89 \pm 8.17$  with minimum 22 and maximum 45 years. The majority were males (12 with 66.7%), females were 33.3% and 38.9% of them were smoker. **Abdelgaid et al.**<sup>(2)</sup> at Al-Razi orthopaedic hospital in Kuwait where Lisfranc joint fracture-dislocation surgery was performed on 37 different patients with this condition (two patients had bilateral injuries). The patients were 21 men and 14 women. The general population was 36.5 years of age (between the ages of 17 and 72).

Operation duration was  $109.17 \pm 21.84$  with minimum 85 and maximum 160 minutes. Union time, and time of full weight bearing were  $16.61 \pm 3.08$  and  $20.50 \pm 3.45$  weeks respectively. **Holy et al.**<sup>(11)</sup> reported that the average recovery time was  $8.38 \pm 2.45$  weeks, with a minimum of six weeks and a maximum of 16 weeks. **Fan et al.**<sup>(12)</sup> showed that the average healing

period for fractures was 9.8 weeks (ranging from 8 to 13 weeks).

The present study estimated the AOFAS components and total as pain score, ROM score and alignment score and total score was  $90.38 \pm 10.82$  with range of 59 -100. Pain, ROM, and Alignment each received scores of  $35.55 \pm 6.15$  (with a range of 20-40),  $45.38 \pm 4.14$  (with a range of 34-50), and  $9.44 \pm 1.61$  (with range of 5-10) respectively. The total AOFAS was 59-100.

Our finding favorable outcome was majority with 88.9% [11 cases obtained excellent result (61.11%), 5 cases had good result (27.8%) and unfavorable 11.1% (2 cases one of them obtained fair result and other one had poor)]. **Wagner et al.**<sup>(13)</sup> reported that percutaneous techniques were used to treat 22 individuals with low-energy injuries. With an AOFAS score of an average of 94, their patient-reported outcomes revealed very good to total satisfaction with early weight-bearing following percutaneous fixation (range, 90-100). Low-energy PRIF When compared to ORIF, the Lisfranc approach has better mid-term clinical outcomes and is safer<sup>(14)</sup>. **Pourmorteza and Vosoughi**<sup>(15)</sup> showed that in all cases, the clinical outcome was outstanding. AOFAS midfoot scale of 100 was achieved by 10 patients (33.3%), whereas 7 patients (23.3%) had FFI. all of whom reported no pain after surgery (VAS discomfort: 0). None of the clinical outcome measures showed a statistically significant age difference<sup>(15)</sup>.

The current study estimated the complication as overall with 4 cases; superficial infection in 22.2%, stiffness in only one case with 5.6%, delayed union in 1

case also no case of compartment syndrome of foot in our series. **Abdelgaid et al.** <sup>(2)</sup> in all patients, there was no evidence of infection or skin problems. After an average of 3.5 months, patients were able to resume routine activities. Lisfranc-Chopart fracture dislocation was present in one of the five individuals with poor health status. An occipital and zygomatic bone fracture was found in the second case that had a negative outcome. Metatarsal head fractures were present in three of the cases with fair outcomes. According to a recent study, infections accounted for 22.2% of all complications, followed by transient numbness, healing delay, and loss decrease, all of which accounted for 5.6% of all problematic cases <sup>(11)</sup>. **Ren et al.** <sup>(16)</sup> reported infection in one patient (5%), secondary diastasis > 3 mm in one patient (5%), and temporary forefoot pain for 3 months in 11 individuals were noted (55%) <sup>(16)</sup>. **Cochran et al.** <sup>(17)</sup> reported that oral antibiotics were able to treat two superficial infections and two irreversible deep peroneal nerve sensory abnormalities in four ORIF patients after implant removal.

## CONCLUSION

To avoid the need for routine hardware removal, closed reduction and percutaneous fixation of Lisfranc injuries with fleck sign using k-wires or screws could be an effective, easy and quick surgical solution. It is therefore a highly effective technique of treatment that can reduce post-operative complications and improve the quality of life for patients, therefore making it an ideal treatment option.

**Conflict of interest:** The authors declared no conflict of interest.

**Sources of funding:** This research did not receive any specific grant from funding agencies in the public, commercial, or not-for-profit sectors.

**Author contribution:** Authors contributed equally in the study.

## REFERENCES

1. **Bucholz R, Heckman J (2002):** Rockwood and Green Fractures in Adults. Philadelphia, PA: Lippincott Williams & Wilkins, Pp: 2182-245. <https://orthopaedics.lwwhealthlibrary.com/book.aspx?bookid=966>
2. **Abdelgaid S, Salah M, Abdulsalam S et al. (2013):** Closed Reduction & Percutaneous Fixation of Lisfranc Joints Injuries: Possibility, Technique & Results. Clin Res Foot Ankle, 1: 109-113.
3. **Moracia-Ochagavía I, Rodríguez-Merchán E (2019):** Lisfranc fracture-dislocations: current management. EFFORT Open Rev., 7: 430-444.
4. **Myerson M, Fisher R, Burgess A et al. (1986):** Fracture dislocations of the tarsometatarsal joints: end results correlated with pathology and treatment. Foot Ankle, 6: 225-242.
5. **Puna R, Tomlinson M (2017):** The Role of Percutaneous Reduction and Fixation of Lisfranc Injuries. Foot Ankle Clin., 22 (1): 15-34.
6. **Zhang H, Min L, Wang G et al. (2013):** Clinical and radiographic evaluation of open reduction and internal fixation with headless compression screws in treatment of lisfranc joint injuries. Zhongguo Xiu Fu Chong Jian Wai Ke Za Zhi., 27(10):1196-201.
7. **Stavrakakis I, Magarakis G, Christoforakis Z (2019):** Percutaneous fixation of Lisfranc joint injuries: A systematic review of the literature. Acta Orthop Traumatol Turc., 53 (6): 457-462.
8. **Ahmed S, Bolt B, McBryde A (2010):** Comparison of standard screw fixation versus suture button fixation in Lisfranc ligament injuries. Foot Ankle Int., 31: 892-896.
9. **Stødle A, Hvaal K, Enger M et al. (2020):** Lisfranc injuries: Incidence, mechanisms of injury and predictors of instability. Foot Ankle Surg., 26: 535-540.
10. **Smith N, Stone C, Furey A (2016):** Does Open Reduction and Internal Fixation versus Primary Arthrodesis Improve Patient Outcomes for Lisfranc Trauma? A Systematic Review and Meta-analysis. Clin Orthop., 474: 1445-1452.
11. **Holy S, Mohammed E, Imam A et al. (2021):** Short Term Assessment of Surgical Treatment of Lisfranc Fracture Dislocation. Egypt J Hosp Med., 85: 2945-2950.
12. **Fan M, Li X, Jiang X et al. (2019):** The surgical outcome of Lisfranc injuries accompanied by multiple metatarsal fractures: A multicenter retrospective study. Injury, 50, 571-578.
13. **Wagner E, Ortiz C, Villalón I et al. (2013):** Early weight-bearing after percutaneous reduction and screw fixation for low-energy lisfranc injury. Foot Ankle Int., 34: 978-983.
14. **Chen P, Ng N, Snowden G et al. (2021):** Percutaneous reduction and fixation of low energy Lisfranc injuries results in better outcome compared to open reduction and internal fixation: Results from a matched case-control study with minimum 12 months follow up. Injury, 52 (4): 1042-1047.
15. **Pourmorteza M, Vosoughi A (2022):** Lisfranc fleck sign: characteristics and clinical outcomes following fixation using a percutaneous position Lisfranc screw. Eur J Trauma Emerg Surg., 48: 471-479.
16. **Ren W, Li H, Lu J et al. (2019):** Undisplaced subtle ligamentous Lisfranc injuries, conservative or surgical treatment with percutaneous position screws? Chin J Traumatol., 22: 196-201.
17. **Cochran G, Renninger C, Tompane T et al. (2017):** Primary Arthrodesis versus Open Reduction and Internal Fixation for Low-Energy Lisfranc Injuries in a Young Athletic Population. Foot Ankle Int., 38: 957-963.