

## Efficacy of Autologous Nano Fat in Hair Transplantation By FUE In Cicatricial Alopecia

Mohamed Hussien Mohamed Hussien Saad,<sup>1</sup> MBBCH, Abdel Raouf Mohamed Almohsen,<sup>1</sup> MD, Shady Mahmoud Attia,<sup>1</sup> MD.

### \* Corresponding Author:

Mohamed Hussien Mohamed Hussien  
[dr6mohamed1h@gmail.com](mailto:dr6mohamed1h@gmail.com)

*Received for publication December 30, 2021; Accepted June 14, 2022; Published online June 14, 2022.*

*Copyright The Authors published by Al-Azhar University, Faculty of Medicine, Cairo, Egypt. Users have the right to read, download, copy, distribute, print, search, or link to the full texts of articles under the following conditions: Creative Commons Attribution-Share Alike 4.0 International Public License (CC BY-SA 4.0).*

**doi:** 10.21608/aimj.2022.113744.1768

<sup>1</sup>Dermatology, Venereology and Andrology Department, Faculty of Medicine, Al-Azhar University, Cairo, Egypt.

### ABSTRACT

**Background:** Cicatricial alopecia is a form of scarring alopecia caused by a collection of diseases in which the hair follicle unit is destroyed and then replaced with fibrous tissue

**Aim of the study:** was to assess efficacy of autologous nano fat in hair transplantation by FUE in cicatricial alopecia.

**Patients and Methods:** This was a Randomized clinical trial for 20 patients presenting with scarring alopecia. The cases were recruited from Dermatology outpatient clinic of Al-Azhar University Hospitals from March 2021 to November 2021.

**Results:** There was a statistically significant difference, with more improvement among patients presenting with cicatricial alopecia and were treated by autologous emulsified fat then hair transplantation by FUE after 1 month.

**Conclusion:** In conclusion, compared with hair transplantation by FUE only, autologous emulsified fat followed by hair transplantation by FUE is more effective in treatment of cicatricial alopecia concerning number of hair grafts remaining after 6 months. Also, needs less number of hairs transplanted with great improvement and yields satisfactory postoperative results.

**Keywords:** Cicatricial alopecia; Autologous Nano Fat; Hair transplantation; Hair follicle.

**Disclosure:** The authors have no financial interest to declare in relation to the content of this article. The Article Processing Charge was paid for by the authors.

**Authorship:** All authors have a substantial contribution to the article.

### INTRODUCTION

Cicatricial alopecia is a type of scarring alopecia caused by a wide variety of diseases that damage the hair follicle and replace it with scar tissue, resulting in permanent hair loss.<sup>1</sup>

Cicatricial alopecia (CA) is divided into two categories: primary and secondary. The permanent component of the hair follicle (stem cells of the bulge area and infundibulum) is the focus of a destructive inflammatory reaction in primary CA.<sup>2</sup>

In CA, spontaneous hair regrowth is uncommon, disappointing the patient. There are numerous therapeutic trials planned to stop or reduce the disease's progression.<sup>3</sup>

Hair transplantation is widely used nowadays as a cosmetic technique in the treatment of cicatricial alopecia by follicular unit extraction (FUE).<sup>4</sup>

As a part of regenerative medicine, the role of adipose tissue in the hair growth cycle is promising nowadays.<sup>5</sup>

Adipose-derived regenerative cells can differentiate into mesenchymal cells and secrete a number of growth factors that appear to have a role in neovascularization, which is significant in the treatment of cicatricial alopecia.<sup>6</sup>

The goal of this research was to assess the efficacy of autologous nano fat in hair transplantation by FUE in cicatricial alopecia.

### PATIENTS AND METHODS

This study was a Randomized clinical trial for 20 patients presenting with Scarring alopecia. The cases were recruited from Dermatology outpatient clinic of Al-Azhar University Hospitals from March 2021 to November 2021.

**Inclusion criteria:** Patients with cicatricial alopecia of scalp or beard area of the face post surgical, post traumatic or post burn of any size with maximum size is 25cm<sup>2</sup> were eligible and age: above 18 years old.

**Exclusion criteria:** Patient with body dysmorphic disorder and unrealistic expectations, patients with chronic severe illness, critical thrombocytopenia, patients on consistent use of anticoagulants within 48 hours of procedure and patient with local inflammatory skin disorders or infection at the site of the procedure.

**Methods Taking a complete history** age, sex, disease duration, family history, history of drug intake and history of other associated diseases and complete general and local examination.

**The 20 patients were randomized into two groups:**

**Group A:** 10 patients presenting with cicatricial alopecia and were treated by autologous emulsified fat then hair transplantation by FUE after 1 month.

**Group B:** 10 patients presenting with cicatricial alopecia and were treated by hair transplantation by FUE only.

#### Procedures:

##### Autologous fat

##### Autologous fat harvesting

**Donor site:** The lower abdomen and thighs were identified as potential donor sites.

**Tumescent anaesthesia:** (500 ml of 0.9% saline solution, 1/2 ampoule of adrenaline 1 mg /ml, and 10-25 ml of lidocaine hydrochloride 2%, 10mEq/L NAHCO<sub>3</sub>) is infiltrated through a 2mm incision made with a number 11 blade in the donor area.

Using a 20-mL Luer Lock syringe and a 2.5mm-15cm harvesting cannula, we manually harvested 120 cc of mixed fat with tumescent solution from subcutaneous fat.

##### Processing

The harvest syringe is placed vertically to decant for 3-5 minutes, allowing the layers to separate. The yellow adipose grafts quickly separate from the underlying infranatant fluid within the syringe based on their density, resulting in the grafts floating in the middle, with the lipid layer on top. We can expect a yield of 1.5 mL of fat graft for every 5 mL of aspirate, and we get about 40 cc of micro fat.

To reduce post-operative bruising, the donor area was covered with a sterile dressing with compression. The top layer of liquid is removed. The oil layer above the harvested graft should not be aspirated into the syringe for micro fat preparation because it can cause oil cysts. A single wash with Ringer's lactate solution should be sufficient to

eliminate any remaining local anaesthetic solution and red blood cells

##### Emulsification Process

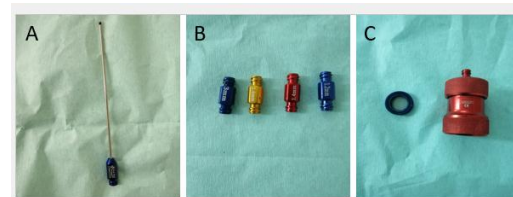
The cleaned microfat is loaded into 20 cc syringes and mechanically emulsified by shifting the contents back and forth 30 times between two 20 cc syringes connected by a 2.4mm connector, then 30 times with a 1.4mm connector, and finally 30 times with a 1.2mm connector, until the fat is liquefied and obtains a whitish appearance.

##### Nanofat Process

The emulsified fat is passed through the nano transfer block one time, which contains a double filter of 400mm and 600mm single use cartridge net and into a 20 cc syringe. This nanofat is transferred into 1 cc Luer Lock syringes for injection.

##### Nanofat Injection

Preparation of the skin with betadine then intradermal injection of nanofat (approximately 0.05-0.1 cc per injection point) The endpoint of the injection is reached with the appearance of a yellowish discoloration over the injection site (Figure 1).



**Fig 1:** Autologous Fat injection instruments. A. Liposuction Cannula; B. Fat Connectors. C. Nano Fat Filter.

##### Follicular unit extraction hair transplantation

Follicular unit extraction hair transplantation instruments based on micromotor, handpiece, Jewelers Forceps, punches of size 0.85mm & needle holder with slits or blade knife no.11.

##### Preoperative Marking

Determine the hair line at a distance from the glabella, ranged from 7 to 9 cm from glabella.

##### Donor site

Back & sides of the scalp. On the day of surgery the donor area from the back of the head is trimmed to 1-2mm length. The patient lies in prone position on the operating table.

##### Donor site anesthesia

using a solution of xylocaine 30 ml with the addition of 30 ml of normal saline with adrenaline (1:1000) for donor and recipient block. The posterior occipital nerve is blocked by injecting the posterior hair line.

### Recipient site anesthesia

The supraorbital and supra-trochlear nerves are blocked by injecting 3 cm on each side into the supraorbital notch. The zygomatico-temporal nerve is blocked by injecting the hairline in the temporal region.

### Harvesting of hair grafts

In this study, punches with a diameter of 0.85 mm were used to harvest follicular units. During the process, hair follicle transplants are stored in cold saline on gauze.

### Creation of recipient sites and implantation of hair grafts

reation of the recipient sites in the recipient area with blade width about 1.1 mm carried on the needle holder. Insertion of the graft with using of implantation forceps. The graft density in the recipient sites should not exceed 15-20 graft/cm<sup>2</sup> due to poor blood supply.

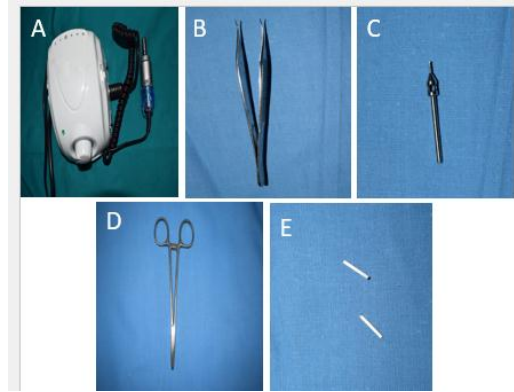
### Dressing

According to site, the closed dressing was removed from 2-4 days postoperatively. The total average time of operation was ranged from 2-4 hours in the post-traumatic or post-burn scar.

### Postoperative care

All patients received antibiotics for 7 days, anti-oedematous drugs, and analgesics after autologous fat injection. after transplantation, a bandage was applied to the donor site. To avoid excessive muscular contraction, the patient was advised to avoid solid food for 5 days. At 24 hours post-

operative, the donor region was shampooed and the transplanted area was cleaned with normal saline at this time. The patient was told to keep washing the transplanted area with saline for another three days. After the 3-day period, the patient was told to wash both regions until the crusts completely faded. To avoid any damage or secondary infection, shaving was allowed after 15 days post-transplantation.



**Fig 2:** FUE Hair Transplantation Instruments. A. Micromotor & Hand Piece. B. Forceps for extraction and implantation. C. Punch. D. Needle Holder. E) slits

Administrative design Approvals: Verbal consent from the participants' parents was obtained.

An official written approval was acquired from the dean of the faculty of medicine, the hospital manager at Al Azhar University, and the head of the university's dermatology and venereology departments. Ethical committee approval was also required.

## RESULTS

	Group A (n=10)		Group B (n=10)		Test	P
Age						
Range	20 – 37		18 – 40			
Mean ± SD	29.1 ± 6.37		27.7 ± 7.29		t=0.457	0.653
Sex	No.	%	No.	%		
Male	10	100.0	10	100.0	χ <sup>2</sup> =1.667	0.197
Type of scar						
Cut wound	5	50.0	6	60.0	χ <sup>2</sup> =0.202	0.654
Post burn	5	50.0	4	40.0		
Duration of scar						
Range	3 – 9		3 – 9			
Mean ± SD	6.3 ± 2.21		5.1 ± 2.08		t=1.250	0.227
Site of scare						
Scalp	8	80.0	7	70.0	χ <sup>2</sup> =0.267	0.606
bearded area of the face	2	20.0	3	30.0		

**Table 1:** Comparison between the studied groups as regard History. This table shows that there was no statistically significant difference between the studied groups as regard Diclofenac History.

	Group A (n=10)		Group B (n=10)		Test	p
<b>Transplanted</b>						
Range	70.0 – 250.0		110.0 – 350.0			
Mean ± SD	140	(122.5 – 192.5)	–	180	(131.25 – 281.25)	U=35.5 0.280
<b>Remained after 6 months</b>						
Range	60.0 – 188.0		44.0 – 210.0			
Mean ± SD	95	(80.75 – 146)	–	105	(66.75 – 170.5)	U=48.0 0.912

**Table 2:** Comparison between the studied groups as regard No. of hair grafts. This table shows that there was no statistically significant difference between the studied groups as regard number of hair grafts.

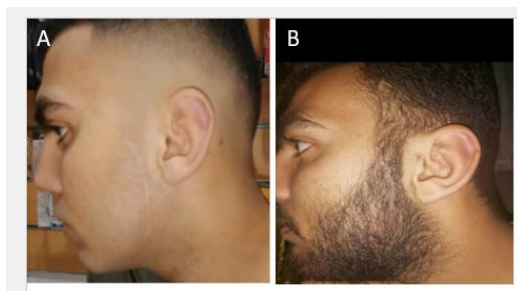	Group A (n=10)		Group B (n=10)		Test	p
<b>Global photography</b>						
Great improvement	7	70.0	4	40.0	$\chi^2=1.818$	0.178
Moderate	3	30.0	6	60.0		

**Table 3:** Comparison between the studied groups as regard Global photography. This table shows that there was no statistically significant difference between the studied groups as regard global photography.

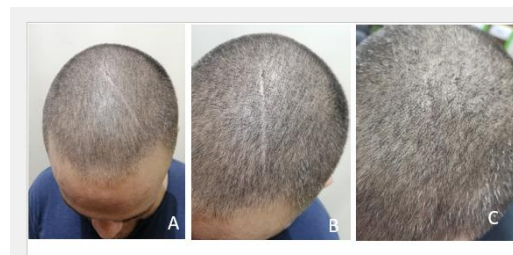	Group A (n=10)		Group B (n=10)		Test	p
<b>Improvement</b>						
Excellent	5	50.0	0	0.0	$\chi^2=8.80$	0.032*
Moderate	4	40.0	4	40.0		
Mild	0	0.0	2	20.0		
Poor	1	10.0	4	40.0		
<b>Satisfaction</b>						
Very satisfied	5	50.0	4	40.0	$\chi^2=2.222$	0.329
Slightly satisfied	5	50.0	4	40.0		
Moderately satisfied	0	0.0	2	20.0		
<b>Complication</b>						
Minimal	8	80.0	6	60.0	$\chi^2=2.222$	0.329
Moderate	2	20.0	4	40.0		

**Table 4:** Comparison between the studied groups as regard outcome. This table shows that there was statistically significant difference between the studied groups as regard Improvement.

**Cases:**



**Fig 3:** Male patient, 25 years old, with cicatricial alopecia of the beard area of the face showing excellent improvement after 6 months of nanofat injection and hair transplantation. A. Before, B. After treatment



**Fig 4:** Male patient, 36 years old, with cicatricial alopecia of the scalp showing excellent improvement after 6 months of nanofat injection and hair transplantation. A and B. Before, C. After treatment

**DISCUSSION**

Cicatricial alopecia (CA) is Scarring alopecia is caused by a variety of diseases in which the hair follicle is damaged and replaced by fibrosis.<sup>7</sup>

Cicatricial alopecia causes persistent damage to the stem cells in the hair follicle bulge, resulting in irreversible hair loss and fibrosis of collagen. Cicatricial alopecia is either primary or secondary.<sup>8</sup>

The pathological causes of cicatricial alopecia are a broad set of disorders that cause skin inflammation confined to the hair follicle.<sup>9</sup>

The aim of this study was to evaluate efficacy of autologous nano fat in hair transplantation by FUE in cicatricial alopecia.

To the best of our knowledge, no similar studies comparing patients presenting with cicatricial alopecia and will be treated by autologous emulsified fat then hair transplantation by FUE after 1 month with patients presenting with cicatricial alopecia and will be treated by hair transplantation by FUE only were found in the literature.

A study consisted of 20 patients presenting with scarring alopecia attended to the Dermatology outpatient clinic of Al-Azhar University Hospitals.

In the present study, there was no statistically significant difference between the studied groups as regard age, sex, and type of scar, duration of scar and site of scar.

While, Saeed<sup>10</sup> reported that among the studied cases there was sixteen (80%) males and four (20%) females, the mean age of the studied cases was 18.85 ( $\pm 2.94$  SD) with range (15-25) years. According to cause of injury among the studied cases there were nine (45%) due to trauma scar, one (5%) due to surgical scar, two (10%) due to post expander and eight (40%) due to burn and according to cause of injury among the studied cases there were five (25%) temporal, four (20%) parietal, two (10%) occipital, three (15%) frontal, three (15%) temp + parietal, two (10%) at occipital + sagittal and one (5%) frontal + temporal. The mean time since injury of studied cases was 11.45 ( $\pm 6$  SD) with range (2-20), Shao<sup>11</sup> carried their study on 37 patients suffering from secondary Cicatricial alopecia in duration of 5 years with mean age of 24.68  $\pm$  5.88 and Radwanski<sup>12</sup> showed that the patients' average age was 44.9 years (range: 39–72 years). On each side, the average number of hair grafts transplanted was 223 (range: 178–357). with success calculated to be around 90%. Also, Oh<sup>13</sup> A total of 62 patients (41 males and 21 females) with an average age of 26.3 years participated in the study. The duration of a scalp burn was three years. expanded flap covering followed by transplantation of hair for 5 patients Jung<sup>14</sup> experienced a study of scar tissue transplantation of 25 cases where most of graft harvesting was obtained from the occipital and posterior auricular areas, Kutlubay<sup>15</sup> also stated that the recommended areas for graft harvesting were the occipital, parietal, and posterior temporal regions, Bicknell<sup>16</sup> recommended using the occipital scalp with a lesser extent the temporal and supra auricular regions as a donor areas and Ors<sup>17</sup> stated that the occipital region is the easiest area for graft harvesting.

Furthermore, Ghazal<sup>18</sup> conducted a study consisted of 30 patients, 23 were males and 7 were females. They were divided into 3 groups according to the

procedure done: A, B and C, with 10 patients in each group. The mean age of patients in group A is 27.40 $\pm$ 9.54 years, in group B 26.20 $\pm$ 8.90 years and 24.50 $\pm$ 8.36 years in group C and used the occipital scalp as a donor area for most cases where accessibility with less transection rate were noticed, while temporal and thin supra auricular hair were used for a lesser extent to mimic the natural appearance of areas with normally thinner hair growth.

In the present study, there was no statistically significant difference between the studied groups (group A and B) as regard number of hair grafts (Transplanted and Remained after 6 months). Also, that there was no statistically significant difference between the studied groups (group A and B) as regard global photography.

In agreement to our study, Tesauro<sup>19</sup> notice that early hair regrowth that began between the second and third month after hair transplantation in scarring alopecia. It's rare to see the procedure's first outcomes after 4 months. Yoo<sup>20</sup> According to the study, follicular unit extraction hair transplantation had an average survival rate of 80.67 percent, according to the study (range 70-90 percent).and Kuka<sup>21</sup> who found that When all patients were evaluated at 24 weeks, there were no statistical differences in terminal hair count or width. In the Norwood Hamilton 3 subgroup, there were increases (mean change from baseline) in terminal hair count for the low-dose adipose-derived regenerative cells group at weeks 6 (13.90 16.68), week 12 (11.75 19.42), week 24 (16.56 14.68), and week 52 (2.78 16.15). The difference in hair count between the low-dose adipose-derived regenerative cell group and the no-fat saline control group at week 24 was statistically significant ( $P = 0.0318$ ) in this subgroup.

Also Zeltzer<sup>22</sup> Physical examination and patient photography were used to evaluate the results. With SNIF, good results were achieved, with results lasting more than a year, which is longer than predicted for resorbable dermal fillers (3 to 6 months).and this supported our study.

Nevertheless, Ghazal<sup>18</sup> reported that the mean hair growth for group A was 83.76 $\pm$ 7.06% after the follow-up period, 84.73 $\pm$ 8.4 for group B and 83.70 $\pm$ 3.29 for group C with no significant difference between the three groups as regards hair growth and this agreed with our study.

In the current study, there was statistically significant difference between the studied groups as regard Improvement while there was no statistically significant difference between the studied groups as regard quartile grading scale, Satisfaction and Complication.

In agreement to our study, Tesauro<sup>19</sup> According to the study, scar tissue that has been previously treated can be transplanted with greater density, reducing the need for multiple hair transplantation sessions. These procedures yield satisfactory post-operative results for the patient and reduce post-operative complications. Zeltzer<sup>22</sup> SNIF was discovered to be a safe and alternative to resorbable dermal fillers for

patients who can accept the little discomfort of fat harvesting from the donor area. There were no significant postoperative complications; bruising and edoema were the most common mild effects. Yoo<sup>20</sup> showed that both patient and observer satisfaction increased significantly postoperatively. and Ghazal<sup>18</sup> reported that no significant difference be-tween levels of satisfaction among patient in all groups.

Also, Saeed<sup>10</sup> demonstrated that in general no patient assigns excellent results , very good results reported in 12 cases (60%), good results was revealed in 6 cases (30%), bad results in two cases (10%). Hassan<sup>23</sup> showed excellent results in 10%, good results in 70%, and satisfactory results in 20% of patients, while Shao<sup>11</sup> stated that patient Satisfaction at their study was 100% for 30 patients, 90% to 100% for five patients and <90% for two patients.

In contrast to our study, Nassih<sup>24</sup> reported that the skin expansion technique is an effective and consistent way of treating cicatricial alopecia of the scalp. Skin expansion is the only surgical option when the alopecia region surpasses 50 cm<sup>2</sup>.

### CONCLUSION

In conclusion, compared with hair transplantation by FUE only, autologous emulsified fat followed by hair transplantation by FUE is more effective in treatment of cicatricial alopecia. Also, needs less number of hairs transplanted with great improvement and yields satisfactory postoperative results.

### REFERENCES

1. Madura C, Vinay N, Kusuma MR, et al. The assessment of hair transplantation outcomes in cicatricial alopecia. *International Journal of Trichology*. 2020; 12(4), 164.
2. Kanti V, R wert- Huber J, Vogt A, et al. Cicatricial alopecia. *JDDG: Journal der Deutschen Dermatologischen Gesellschaft*. 2018; 16(4), 435-61.
3. Ekelem C, Pham C and Mesinkovska NA. A systematic review of the outcome of hair transplantation in primary scarring alopecia. *Skin appendage disorders*. 2019; 5(2): 65-71.
4. Priyadharshini J. Cicatricial alopecia: Clinical, dermoscopy and histopathological study (*Doctoral dissertation, Madras Medical College, Chennai*), 2018.
5. Festa E, Fretz J and Berry R. Adipocyte lineage cells contribute to the skin stem cell niche to drive hair cycling. *Cell*. 2021; 146(5):761–71.
6. Epstein GK and Epstein JS. Mesenchymal stem cells and stromal vascular fraction for hair loss: current status. *Facial Plastic Surgery Clinics*. 2018; 26(4), 503-11.
7. Sundberg JP, Hordinsky MK, Bergfeld W, et al. Cicatricial Alopecia Research Foundation meeting. May 2016: Progress towards the diagnosis, treatment and cure of primary cicatricial alopecias, 2018.
8. Su Y, Yang Q, Dou W, et al. Cicatricial alopecia. *Alopecia*. Intech Open. 2018; 89-111.
9. Fabbrocini G, Annunziata MC, Cantelli M, et al. Hair in Dermatologic Disease. *Hair Disorders: Diagnosis and Management*. 2021; 194.
10. Saeed MM, Hoota AMH and Khallaf AN. Follicular Unit Extraction in Management of Secondary Cicatricial Alopecia. *Al-Azhar International Medical Journal*. 2021; 2(8), 11-7.
11. Shao H, Hang HU, Yunyun J, et al. Follicular unit transplantation for the treatment of secondary cicatricial alopecia. *Plastic Surgery*. 2014; 22(4), 249-53.
12. Radwanski HN, Nunes D, Nazima F, et al. Follicular transplantation for the correction of various stigmas after rhytidoplasty. *Aesthetic plastic surgery*. 2007; 31(1), 62-8.
13. Oh SJ, Koh SH, Lee JW, et al. Expanded flap and hair follicle transplantation for reconstruction of postburn scalp alopecia. *Journal of Craniofacial Surgery*. 2010; 21(6), 1737-40.
14. Jung S, Oh SJ and Koh SH. Hair follicle transplantation on scar tissue. *Journal of Craniofacial Surgery*. 2013; 24(4), 1239-41.
15. Kutlubay Z, Murat K and Engin B. Hair transplantation in the cicatricial alopecias. *Hair Ther Transplant*. 2013; 3(109), 2167-0951.
16. Bicknell L. M, Kash N, Kavouspour C, et al. Follicular unit extraction hair transplant harvest: a review of current recommendations and future considerations. *Dermatology online journal*. 2014; 20(3).
17. Ors S, Ozkose M and Ors S. Follicular unit extraction hair transplantation with micromotor: eight years' experience. *Aesthetic plastic surgery*. 2015; 39(4), 589-96.
18. Ghazal MA, Bahaa El Din A and Zahra T. Outcome of Follicular Unit Extraction in Cicatricial Alopecia. *The Egyptian Journal of Plastic and Reconstructive Surgery*. 2020; 44(1), 159-66.
19. Tesauro P, Trivisonno A, Gennai A, et al. Hair Transplantation in Cicatricial Alopecia: The Role of Autologous Fat Transfer. *International Journal of Regenerative Medicine*. 2020; 3(2), 2-8.
20. Yoo H, Moh J and Park JU. Treatment of postsurgical scalp scar deformity using follicular unit hair transplantation. *BioMed research international*. 2019. <https://doi.org/10.1155/2019/3423657>.
21. Kuka G, Epstein J, Aronowitz J, et al. Cell enriched autologous fat grafts to follicular niche improves hair regrowth in early androgenetic alopecia. *Aesthetic surgery journal*. 2020; 40(6), 328-39.
22. Zeltzer AA, Tonnard PL and Verpaele AM. Sharp-needle intradermal fat grafting (SNIF). *Aesthetic surgery journal*. 2012; 32(5), 554-61.
23. Hassan I, Abdullah Z and Keen A. Hair Transplantation in Cicatricial Alopecia: A Preliminary Report. *Journal of the Turkish Academy of Dermatology*. 2013; 7(4).
24. Nassih, M., Rzin, A and Jidal, B. Skin expansion in cicatricial alopecia of the scalp: 18 cases. *Revue de Stomatologie et de Chirurgie Maxillo-faciale*. 2007; 108(5), 411-8.