

Role of Vacuum Therapy in Treatment of Infected Pseudoaneurysmectomy Wounds

Mohammed Hashem Elgazzar^{1,*} M.B.B.Ch, Omer Mokhtar Alhaig² PhD. And Mohammed AbdElFattah Emam² MD.

** Corresponding Author:*

Mohammed Hashem Elgazzar
elgazzar2012@yahoo.com

Received for publication January 07, 2022; Accepted June 24, 2022;
 Published online June 24, 2022.

Copyright The Authors published by Al-Azhar University, Faculty of Medicine, Cairo, Egypt. Users have the right to read, download, copy, distribute, print, search, or link to the full texts of articles under the following conditions: Creative Commons Attribution-Share Alike 4.0 International Public License (CC BY-SA 4.0).

doi: 10.21608/aimj.2022.112251.1764

¹Department of Vascular surgery, Matariya teaching hospital GOTHI, Egyptian ministry of health.

²Department of Vascular surgery, Faculty of Medicine, Al-Azhar University, Cairo, Egypt.

³Department of General surgery, Faculty of Medicine, Al-Azhar University, Cairo, Egypt.

INTRODUCTION

Wound healing is a sensitive clinical matter & efficient wound handling is important. The primary purpose is to reach a high rate of efficacy in the wound healing.¹

Vacuum-assisted closure (VAC), also known as negative pressure wound therapy (NPWT) is a sealed wound management system & is mainly designed for big chronic difficult lesions & severe complicated lesions. It is composed of pump with electronic control & sponge dressing drains the lesion. A modified negative pressure is created through waterproof sticky sheet that covers the wound. VAC drains lesion exudate & enhances blood circulation & healing.²

Pseudoaneurysm is an assembly of blood that occurs after a vascular wound & maintained inside the tissues around the vessel injured. It is composed of a perfused sac, the false lumen, connected to the blood vessel through a neck.³

Mostly all pseudoaneurysms are infected at arrival to hospital. *S. aureus* is the most common organism as

ABSTRACT

Background: Infected pseudoaneurysmectomy wounds represent great challenge for every vascular surgeon. Delayed wound healing in such complicated & chronic wounds with co morbidities is a major concern. It leads to the pain, morbidity, prolonged treatment, & require major reconstructive surgery which imposes enormous social & financial burden.

Aim of the work: To evaluate the results & benefits brought by the topical application of VAC in patients with infected pseudoaneurysmectomy wounds.

Patients and Methods: This study was conducted at Al-Azhar University Hospitals & Matariya Teaching Hospital, on 15 patients of different age groups & both sexes.

Result: In correlation of duration of VAC with other fields of assessment there was statistical significance for duration with sex (P value; 0.043), HCV infection (P value; 0.032), IV drug abuse (P value; 0.003), ESRD (P value; 0.003), region of pseudoaneurysm (P value; 0.003), size of wound at start (P value; 0) & number of dressings (P value; 0). In correlation of incidence of complications with the fields of assessment there was statistical significance for complications incidence with presence of HCV infection (P value; 0.029) & wound size (P value; 0.029).

Conclusion: VAC is useful in the treatment of infected pseudoaneurysmectomy wounds. It stabilizes the wound, reduces edema, reduces the bacterial load, improves tissue perfusion & stimulates granulation tissue proliferation. It is simple & effective regarding reduction in wound size, treatment duration & complication incidence.

Keywords: VAC; infected pseudoaneurysm; drug abuse.

Disclosure: The authors have no financial interest to declare in relation to the content of this article. The Article Processing Charge was paid for by the authors.

Authorship: All authors have a substantial contribution to the article.

Klonaris showed when found Staph culture growth in 11 (76 %) patients.⁴

The commonest reason for infected pseudoaneurysm is IV addiction substance injection. Piercing lesion as thrust, industrial trauma, gun fire & sometimes manipulation during orthopedic operation are other common causes.⁴

Nearly 75 % of intra-arterial addiction substance injections occur in the lower limb; so, the most prevalent location of infected pseudoaneurysm is the inguinal area. If kept untreated, they will be associated with generalized sepsis, life-risky bleeding, limb loss, or eventually death.⁴

The diffuse utilization of percutaneous arterial maneuvers caused frequent pseudoaneurysm incidence. Endovascular interventions are frequent cause of femoral pseudoaneurysm. It occurs in 0.1% to 0.2% of diagnostic angiograms & 3.5% to 5.5% of therapeutic maneuvers. Prolonged procedures, wide-bore catheters, anticoagulant therapy & wrong low position of puncture are accompanied by more incidence.⁵

The occurrence of aneurysm in arteriovenous fistula (AVF) for hemodialysis extends between 0% & 10%.

Aneurysms may be true aneurysms if all layers of the venous wall are involved or false (pseudo) aneurysms including fibrous tissue & clot. Complications may involve skin ulceration, infection, thrombosis, dialysis failure & rupture. Pseudoaneurysms commonly occurs following disruption of the vessel wall after cannulation troubles often with synthetic grafts due to repeated needle insertion in the same site.^{6&7}

Recurrent cannulation of AVF at haemodialysis is the most common reason for a brachial artery pseudoaneurysm with a reported occurrence of 1/13000 haemodialysis sessions.⁸

Pseudoaneurysms clinically come with the characteristic pulsating mass, felt bruit & audible to-&-fro murmur. Sure diagnosis is proven via multiple radiological modalities.⁵

Arterial duplex could be used in the diagnosis being noninvasive, low-cost & commonly available imaging technique. Yet, the gold standard is ordinary angiography & particularly selective arteriography.⁹

Surgical repair remains the preferred treatment of pseudoaneurysms; but the kind of surgery & rebuilding alter according to the cause & the clinical picture of the patient. Existence of infection excludes any arterial rebuilding so, ligation & removal of the disrupted part is the preferred solution.⁴

The aim of this work is to evaluate the results & benefits brought by the topical application of VAC in patients with infected pseudoaneurysmectomy wounds.

PATIENTS AND METHODS

Patients

This study was performed on 15 patients of different age groups & both sexes at Al-Azhar University Hospitals & Matariya Teaching Hospital. The target was to assess the efficacy of topical application of the VAC system over infected pseudoaneurysmectomy wounds of different etiologies. All patients underwent initial assessment & patient exclusion was based on the presence of contraindication to application of the VAC.

Inclusion criteria included skin & soft tissue loss known to be post pseudoaneurysmectomy with signs of infection.

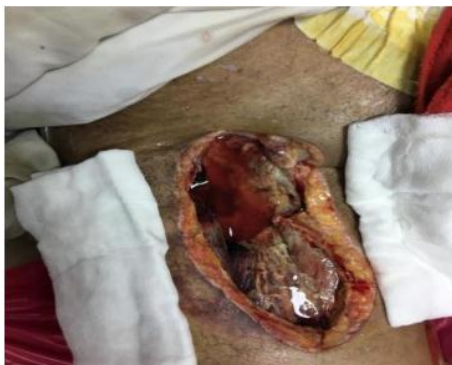

Fig. 1: Infected wound of pseudoaneurysmectomy
Exclusion criteria included incidence of anaphylaxis & clean pseudoaneurysmectomy wounds.

Patients' initial assessment

A detailed history was obtained including personal history & complaint (skin & soft tissue loss).

History of present illness included bleeding characters, pus discharge, incidence of fever & sterilization of puncture needles used in dialysis or drug injection.

Medical history focused on the presence of comorbidities which may affect the wound healing, intake of any medications which may lead to decreased cell proliferation or decreased body immunity & assessment of the nutritional status of the patient.

Surgical history assessed the period passed after surgery & some operative details (e.g. presence of arterial bypass).

Full examination was performed including general & local examination. General examination searched for signs of comorbidities which may affect the wound healing & nutritional status with assessment of vital signs. Local examination for signs of limb ischemia, wound assessment with its surroundings, patency of extra-anatomical arterial bypass & signs of concurrent DVT.

Lab investigations were done before starting VAC & frequently during follow-up as needed including CBC, PT, INR, ESR, CRP, kidney functions, serum electrolytes, liver enzymes, random blood glucose, virology markers for HBV, HCV & HIV & wound swab culture & sensitivity.

Duplex imaging was done before initiating VAC therapy to assess arterial flow & incidence of DVT & was repeated every two weeks in case of presence of arterial bypass or DVT.

Method

VAC machine is formed of 2 main components; suction machine (comes with barometer to adjust the pressure needed for the dressing) & electrical timer (connected to the power supply to adjust the switch on & off of the VAC). The machine had been adjusted to be switched on for 5 minutes & switched off for 3 minutes.





Fig. 2: The VAC machine, (A) the suction machine, (B) the pressure adjusted in bar, (C) the electrical timer circuit.

The dressing is consisted of the sponge, the incifilm & the connecting tube.



Fig. 3: The 2 types of sponges had been used in VAC dressing.



Fig. 4: The opposite sheet.

Dressing application by cutting the sponge to pieces fitting the wound without overlapping on intact skin & cutting the sheet of the incifilm to cover the sponge & an additional 3-5 cm border of the surrounding skin.

Dressing change by removal & discarding previous dressing with inspecting the wound thoroughly to ensure all pieces of dressing components have been removed. Waiting for 15-30 seconds after switch off the machine allows sponge to decompress to facilitate its removal. Any necrotic, non-viable tissues are debrided & the surrounding skin must be clean & dry.

Reassessment of the general condition & the progress of therapy was done at the beginning & weekly to evaluate the wound regarding the size, granulation tissue percentage, its type either healthy or not & the regression of wound infection.

Regarding the wound size, it was measured at the time of beginning & by the end of treatment in centimeter & calculation of the percentage of reduction in wound size was done.

Regarding the wound infection, wound culture & sensitivity plus CBC were done before initiating VAC then CBC was repeated weekly to confirm regression of infection noticed by clinical examination.

After being completely covered by healthy granulation tissue, decision by plastic surgery was taken to continue or prepare for coverage intraoperative.

Statistical analysis

Version 20.0 of SPSS software, IBM corp., Chicago, IL, USA was used to analyze & interpret the collected data.

RESULTS

In correlation of duration of VAC with other fields of assessment there was statistical significance for duration with sex (P value; 0.043), HCV infection (P value; 0.032), IV drug abuse (P value; 0.003), ESRD (P value; 0.003), region of pseudoaneurysm (P value; 0.003), size of wound at start (P value; 0) & number of dressings (P value; 0).

In correlation of incidence of complications with the fields of assessment there was statistical significance for complications incidence with presence of HCV infection (P value; 0.029).

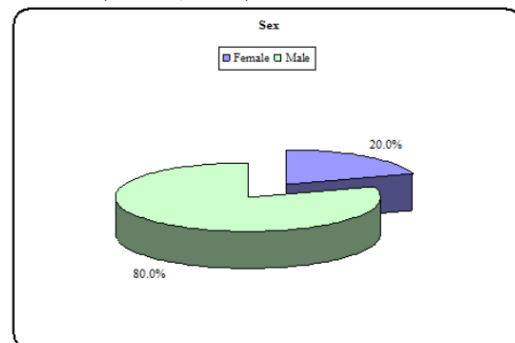


Fig. 5: Sex distribution.

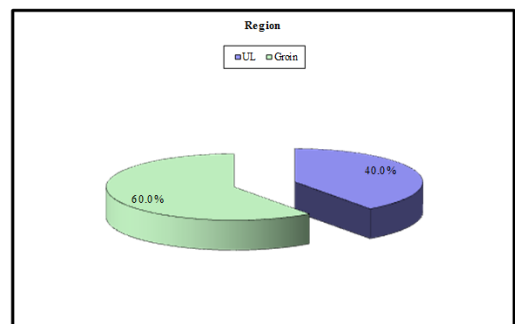


Fig. 6: Diagram of distribution of region.

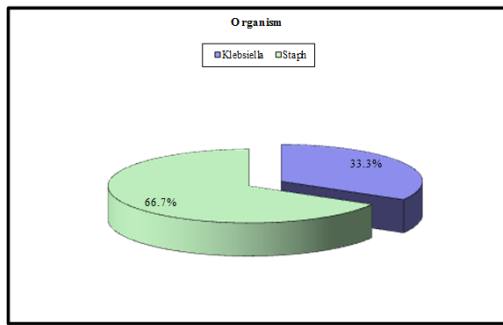


Fig. 7: Distribution of organism.

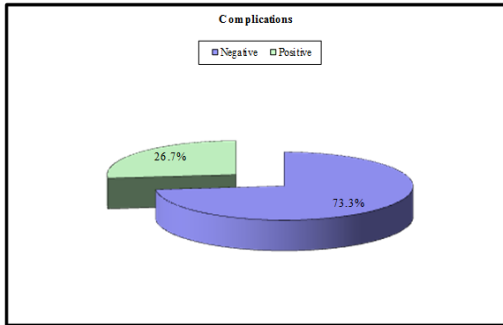


Fig. 8: Distribution of complications incidence.

Co-morbidities	No.	%
HCV	8	53.3%
IV drug abuse	9	60.0%
ESRD	6	40.0%
IHD	1	6.7%
DM	2	13.3%
HTN	2	13.3%
HBV	1	6.7%

Table 1: Distribution of comorbidities.

Size	Start	End
	No. = 15	No. = 14
Median (IQR)	87.5 (60 - 270)	21.25 (10 - 70)
Range	3 - 504	1 - 192

Table 2: Wound size at start & at end.

	Size at start	% of reduction	Test value	P-value
	No. = 15	No. = 15		
Median (IQR)	87.5 (60 - 270)	76.50 (66 - 82)	-3.296	0.001
Range	3 - 504	45 - 91		

Table 3: Significant correlation between size & percentage of reduction.

Size day 0	Complications		Test value	P-value
	Negative	Positive		
	No. = 11	No. = 4		
Median (IQR)	84 (24 - 105)	332 (180 - 444)	-2.089	0.037
Range	3 - 270	80 - 504		

Table 4: Significant correlation between size & complications incidence.

		Median (IQR)	Range	Test value	P-value
Sex	Female	10 (7 - 25)	7 - 25	-2.026	0.043
	Male	39.5 (20 - 51)	15 - 60		
HCV	No	15 (10 - 40)	7 - 47	-2.147	0.032
	Yes	40.5 (27.5 - 57.5)	20 - 60		
IV drug abuse	No	15 (10 - 20)	7 - 25	-3.013	0.003
	Yes	42 (39 - 55)	20 - 60		
ESRD	No	42 (39 - 55)	20 - 60	-3.013	0.003
	Yes	15 (10 - 20)	7 - 25		
Region	UL	15 (10 - 20)	7 - 25	-3.013	0.003
	Groin	42 (39 - 55)	20 - 60		

Table 5: Significant correlation between duration & multiple factors.

	Duration (days)	
	r	P-value
No. of dressings	0.978	0.000
Size day 0	0.836	0.000

Table 6: Significant correlation of duration with dressings number & wound size.

Co-morbidities	Complications		Test value	P-value
	Negative	Positive		
	No. = 11	No. = 4		
HCV	No	7 (63.6%)	4.773	0.029
	Yes	4 (36.4%)		
		0 (0.0%)		
		4 (100.0%)		

Table 7: Significant correlation between HCV & complications incidence.

DISCUSSION

Wound infection exists when contamination & colonization result in bacterial infestation of the wound & surrounding tissue & could lead to aggressive complications which retard wound healing & may be lethal.¹⁰

To stop infection, open-wound handling & enhancement of wound healing have been the motive for evolution of novel maneuvers & wound-protection products. Through the last 2 decades, VAC has been used in clinics for the management of different wounds. According to valid clinical outcomes, VAC has become a remarkable therapeutic option to protect against wound infection. The existing literature concludes that primary modes of action of the VAC system may include pulling the wound edges together, reduction of wound edema, elimination of wound exudate, & micro-deformation of the wound surface.¹⁰

VAC is conservative choice for handling open wounds with deep vascular infections & is started after excision of dead tissue with good hemostasis. The polyurethane foam fills the cavity & are masked by a plastic sheet; a hole is made in the plastic sheet & suction catheter is inserted through it. The other

Duration (days) Test P-

end of the catheter is connected to the vacuum device. The pressure is mostly adjusted to 125 mmHg while several centers adjust the pressure to 50 mmHg in persistent pattern. Replacement of dressing is often done two or three times weekly in the ward.¹¹

This study was carried on 15 patients of different age groups with infected pseudoaneurysm of 2 main etiologies; post IV drug abuse puncture mostly & post hemodialysis puncture to assess the efficacy of the VAC system on such wounds.

The present study showed that 9 patients have wounds in unilateral lower limb specifically in the groin area (60%, all are male). 6 patients have wounds in unilateral upper limb specifically in the arm (40%, 3 male & 3 female). There was statistical significance between the wound region & only duration of VAC (P value; 0.003).

Luther et al. found that femoral artery is the most common artery involved with 37 cases (74 %) then brachial artery.⁴

In our study, 10 patients were infected by staphylococcus organism (66.7%) & 5 patients were infected by klebsiella organism (33.3%).

Bell et al. have stated that mostly all pseudoaneurysms arrive infected to hospital. Most patients are infected, with *S. aureus* matching with *Klonaris* who found Staph culture growth in eleven (76 %) patients.⁴

In other study, VAC could affect the *S. aureus* colony, morphology & spatial distribution whether over the surface or inside tissue of animal wounds & lower *S. aureus* after 48 hours from starting therapy. Additionally, VAC prohibits bacterial fission proliferation in microcolonies as the continuing suction during VAC may physically expel the edema & nutrients essential for bacterial multiplication.¹⁰

The current study showed that duration of VAC for the studied patients, it was ranged 7-60 days with median (IQR): 30 (15-47). In correlation of duration of VAC therapy with the fields of assessment there was statistical significance for duration with sex (P value; 0.043), HCV infection (P value; 0.032), IV drug abuse (P value; 0.003), ESRD (P value; 0.003), region of pseudoaneurysm (P value; 0.003), size of wound at start (P value; 0) & number of dressings (P value; 0).

Moreover, Dosluoglu et al. showed that mean period of VAC usage was 22.8 days (ranging from 6 to 53 days). The duration for complete healing ranged from 30 to 63 days (mean; 41 days). Accommodation in hospital ranged from 11 to 31 days (mean; 21 days). The duration of accommodation in rehabilitation center ranged from 0 to 57 days (mean; 34 days). Following formation of granulation tissue all over the naked anastomoses, 2 patients stayed in a rehabilitation center on VAC system for 13 & 28 days.¹²

The operative solution of infected femoral artery pseudoaneurysm is complicated & debatable. The classic choice is extra-anatomical bypass graft with removal & debridement of the infected pseudoaneurysm & infected soft tissues where the incidence of graft infection, thrombosis & amputation isn't low. Passage of direct arterial graft along the infected area has been accepted by some but is accompanied by infection in over half the

cases. Ligation of the femoral artery followed by elective revascularization later on, according to incidence of ischemia clinically, is choice used sometimes with possible high incidence of complications.¹³

The application of VAC system without muscular flap cover has been reported recently following repair of infected pseudoaneurysms also in postoperative groin infection following patch angioplasty, bypass procedure by vein & synthetic graft with limited graft exposure.¹⁴

During our study, one patient (6.6%) experienced active bleeding from groin wound on the 2nd day of VAC that was controlled by bed-side hemostatic sutures & returned to VAC after 24 hours with no incidence of bleeding later on. Another patient (6.6%) with lateral extra-anatomical ilio-popliteal synthetic bypass suffered subcutaneous hematoma related to the abdominal wound of iliac artery exploration with no relation or extension to deep anastomosis of iliac artery as proved by duplex imaging & was controlled by compression & continued on VAC with no complication to bypass graft integrity. The other patient in the study with trans-obturator bypass passed with no complication to bypass graft. Totally, graft preservation was achieved in the two patients (100%) with extra-anatomical bypass in our study.

Koncar I, et al mentioned various literature data discussing experience in management of vascular surgical site infection (SSI) by VAC involving one randomized controlled trial. Beneficial results were graft maintenance (over 80%), wound healing (20–50 days) & cost-effectiveness (compared to alginate dressing), while the most serious complication was major bleeding (less than 10%). Minimal incidence of complications with elevated success rate assist recent trend to put VAC as the first option in patients with groin early & deep SSI.¹⁵

Pseudoaneurysms in A-V fistulas commonly occur after disruption of the vessel wall often with synthetic grafts owing to repeated puncture in the same site. Complications include skin erosion, infection, thrombosis, dialysis failure & rupture.^{5&16}

Infection represents around 20% of vascular access complications more with synthetic grafts because of repeated needle puncture. VAC was reported to be beneficial in the treatment of these infections via lowering the wound bacterial counts & enhancing granulation tissue formation. In four cases, graft preservation was achieved by extensive local care, VAC & systemic antibiotics.¹⁷

A new hybrid technique using VAC was announced for infected vascular structures, known as EndoVAC. The constituents involve: covered stenting of the infected vessel; operative procedure with no clamping on the vessel & VAC for enhancing granulation & secondary healing. The essential benefits of this maneuver are the minimal dissection required in a generally fibrotic zone, no risk of anastomosis disruption inside the infected area & no clamping of the circulation is mandatory. The EndoVAC technique can be used with infected carotid patch, infected extra-anatomical bypass in the neck & infected vascular structures in the groin. Report about its efficacy in all 16 patients in one series without infection during a 5-year follow-up has been published.¹⁸

Koncar I, et al concluded that VAC is the “second best primary” choice for groin wound sepsis over synthetic graft (Szilagey grade III) that is threatening to limb &/or life when general condition of such patients stands against aggressive radical surgery. For groin wounds with bare synthetic graft, application of VAC is not accredited & not united. The major possible troubles include ingrowth, adherence to wound & hemorrhage from infected graft & anastomosis. They could be prohibited by impregnating non-sticky silicone-based dressing prior to putting polyurethane sponge. Other mentioned method is putting two layers (polyvinyl alcohol & polyurethane) foams. Authors published data that was gathered through 7 years in their institution from 35 patients complaining of early deep groin infection in presence of uncovered synthetic graft managed by VAC showing that severe hemorrhage reported in one patient; it was impossible to preserve the graft in 7 patients (20%), while secondary suturing was the method of healing in all other wounds. Through follow-up, infection had returned in two patients who underwent radical treatment.¹⁵

Progress in treatment of this complicated disease by VAC might be reached with usage of novel appliances provide injection of antibiotics & other antiseptic solutions washing the wound on VAC.¹⁵

CONCLUSION

The use of VAC has proven to ease some of the economic burden of such complicated wounds by providing suitable background & environment for wound-healing, lowering the frequency of dressing change, relieving the patient & reducing the required costs. This technique is simple & cost effective & permits these wounds to be managed in a non-emergent fashion & allows for medical stabilization & optimization of these patients.

REFERENCES

1. Sankalp Y, Gautam R, Mudit B. Vacuum assisted closure technique: a short review. *Pan Afr Med J*. 2017; 28: 246.
2. Frank P and Stefan S. Negative-Pressure Wound Therapy: a systematic Review of Randomized Controlled Trials. *Dtsch Arztebl Int*. 2011; 108 (22): 381–9.
3. Alhaieg OM, Saleh MS, Salama MH, et al. Femoral artery pseudoaneurysm: our department experience *Al-Azhar Assuit Medical Journal (AAMJ)*, 2014; (12): 4.
4. Luther A, Kumar A, Negi KN. Peripheral Arterial Pseudoaneurysms—a 10-Year Clinical Study. *Indian Journal of Surgery*. 2015; 77(2):603-7.
5. Darbari A, Tandon S, Chandra G, et al. Post-traumatic peripheral arterial pseudoaneurysms: our experience. *Indian Journal of Thoracic and Cardiovascular Surgery*. 2006; 22(3):182-7.
6. Pasklinsky G, Meisner RJ, Labropoulos N, et al. Management of true aneurysms of hemodialysis access fistulas. *J Vasc Surg*. 2011;53(5):1291-7.
7. Bachleda P, Utikal P, Kalinova L, et al. Surgical remodelling of haemodialysis fistula aneurysms. *Ann Acad Med Singapore*. 2011; 40(3):136-9.
8. Nicola C, Kapil S, Chris PY, et al. Brachial artery pseudoaneurysm arising from the stump of a ligated arteriovenous fistula. *BMJ Case Rep*. 2015: bcr2014206993.
9. Elias P, Efstratios A, Charalampos M, et al. Compound and acutely ruptured false aneurysm of the brachial artery: a case report. *J Med Case Reports*. 2009; 3: 6627.
10. Li Z, Yu Q, Wang S, et al. Impact of negative-pressure wound therapy on bacterial behaviour and bioburden in a contaminated full-thickness wound. *Int Wound J*. 2019; 16(5):1214-21.
11. Salehian MT, Shahid N, Mohseni M. Treatment of infected pseudoaneurysms in drug abusers: ligation or reconstruction? *Arch Iranian Med*. 2006; 9:49–52.
12. Dosluoglu HH, Schimpf DK, Schultz R, et al. Preservation of infected and exposed vascular grafts using vacuum assisted closure without muscle flap coverage. *Journal of vascular surgery*. 2005 Nov 1;42(5):989-92.69.
13. Arora S, Weber MA, Fox CJ, et al. Common femoral artery ligation and local debridement: a safe treatment for infected femoral artery pseudoaneurysms. *Journal of vascular surgery*. 2001; 33(5):990-3.
14. Pinocoy J, Albes JM, Wicke C, et al. Treatment of periprosthetic soft tissue infection of the groin following vascular surgical procedures by means of a polyvinyl alcohol-vacuum sponge system. *Wound Repair Regen* 2003;11:104-9.
15. Koncar I, Ilic N, Sladojevic M, et al. Negative-Pressure Wound Therapy in Vascular Surgery. In: Recent Clinical Techniques, Results, and Research in Wounds. Springer, Cham. 2018 ; 11:503-8.
16. Lee JY, Kim H, Kwon H, et al. Delayed rupture of a pseudoaneurysm in the brachial artery of a burn reconstruction patient. *World J Emerg Surg* 2013;8:21.
17. Vallet C, Saucy F, Haller C, et al. Vacuum-assisted conservative treatment for the management and salvage of exposed prosthetic hemodialysis access. *European journal of vascular and endovascular surgery*. 2004; 28(4):397-9.
18. Acosta S, Björck M, Wanhainen A. Negative-pressure wound therapy for prevention and treatment of surgical-site infections after vascular surgery. *Br J Surg*, 2017; 104: 75-84.