

EVALUATION OF LYCOPENE IN THE TREATMENT OF EROSIVE ORAL LICHEN PLANUS (A RANDOMIZED CLINICAL TRIAL)

Aliaa A. Bedeir¹**BDS*, Azza M. Zaki² *PhD*, Sabah A. Mahmoud³ *PhD*

ABSTRACT

INTRODUCTION: Oral lichen planus is an autoimmune disorder of unknown etiology. It is believed that oxidative stress plays an important role in its pathogenesis. Topical corticosteroids are the gold standard treatment for oral lichen planus. However, for resistant and severe lesions systemic corticosteroids are indicated. The side effects of oral steroids necessitate searching for safer lines of treatment. Lycopene is an antioxidant with promising effects on human health. It is also found to play roles in the treatment of various oral mucosal diseases especially oral lichen planus.

OBJECTIVES: The aim of this study was to evaluate the effect of oral lycopene and systemic steroids in the treatment of erosive oral lichen planus and compare between the two therapeutic modalities.

MATERIALS AND METHODS: Twenty patients were recruited and randomly assigned in one of two groups, the test (lycopene) and control (corticosteroids) group. Subjective assessment using Visual Analogue Scale and objective assessment using Thongprasom et al. lesion scoring were taken at baseline and after one, two and five months from baseline (three months after treatment termination).

RESULTS: In both study groups, there was a significant decrease in the scores of objective and subjective outcomes after one, two and five months. The mean score values of both outcomes were in favor of the test group after two and five months. However, there was no statistically significant difference between the test and control groups throughout the study period.

CONCLUSIONS: Lycopene is an effective therapeutic modality for erosive oral lichen planus.

KEYWORDS: antioxidant, lycopene, oral lichen planus, systemic corticosteroids

RUNNING TITLE: Lycopene for erosive oral lichen planus treatment

1 BDS, Faculty of Dentistry, Alexandria University, Alexandria, Egypt

2 Professor of Oral Medicine, Periodontology, Diagnosis and Radiology Department, Faculty of Dentistry Alexandria University, Alexandria, Egypt

3 Professor of Medical Biochemistry Department, Faculty of Medicine Alexandria University, Alexandria, Egypt

* Corresponding Author:

Email: aliaa_bedeir@hotmail.com

INTRODUCTION

Lichen planus (LP) is an autoimmune inflammatory disease that affects the skin, nails, scalp, and mucosal tissues as the oral mucosa (1). A clear explanation about the exact pathogenesis of oral lichen planus (OLP) remains incomplete. It is believed to be an immune-mediated basal keratinocytes apoptotic process through T lymphocytes (CD8+) (2, 3).

Oxidative stress occurs in situations of cellular oxidant-antioxidant imbalance (4). OLP pathology is linked to oxidative stress (5). Increased concentrations of reactive intermediates like reactive oxygen species (ROS) and free radicals are found to be released from OLP cells. There is evidence that they play a role in influencing apoptosis (6).

OLP is a disease of chronic and remissive nature where lesions can appear in reticular, papular, plaque, atrophic, bullous, and erosive forms. Erosive oral lichen planus (EOLP) is considered the most severe symptomatic variant of LP that necessitates intervention to help reverse phases of exacerbation (1). Topical corticosteroids are the mainstay line of treatment for OLP. However, systemic steroids are beneficial for unresponsive cases or when extensive lesions

develop (3). Systemic therapy can be complicated by giving rise to some

adverse effects as fluid retention, gastritis and immune compromise (7). Therefore, different modalities have been proposed as safe alternatives for OLP treatment (8).

Lycopene (LYC) is a lipophilic antioxidant found mainly in red and pink fruits. It is considered a special member of the carotenoid family with different biochemistry due to having an acyclic structure that renders it lack a pro-vitamin A activity (9, 10). Lycopene efficiently scavenges singlet oxygen and is also known to have potent neutralizing effects on hydroxyl radical (OH·), nitrogen dioxide (NO₂·) and thiyl radical (RS·) (11, 12). Moreover, lycopene bears some beneficial properties, it protects against cardiovascular disease, cancer, osteoporosis and atherosclerosis. Besides, it was found to be effective in the treatment of different diseases as neurodegenerative, gastrointestinal, periodontal and oral mucosal diseases. Based on all those grounds, it is useful to assess the effects of

lycopene in the treatment of OLP as a safe therapeutic modality (13, 14).

The aim of the present trial was to evaluate the effect of oral pure lycopene and systemic steroids (prednisolone) in the treatment of erosive oral lichen planus and compare between the two therapeutic modalities.

The null hypothesis of this study was that there will be no statistically significant difference between the test and control groups regarding the clinical findings after treatment with both lycopene and prednisolone.

MATERIALS AND METHODS

Participants and study design

A Parallel randomized controlled clinical trial following the CONSORT guidelines(15) was conducted on twenty patients attending the outpatient clinic of the Oral Medicine, Periodontology, Diagnosis, and Radiology Department, Faculty of Dentistry, Alexandria University, Egypt. Patients were clinically and histopathologically diagnosed with erosive oral lichen planus according to the modified WHO criteria of oral lichen planus 2003(16). The study was approved by the Research Ethics committee of the Faculty of Dentistry, Alexandria University, Egypt (IRB NO: 00010556) - (IORG 0008839). The trial's registry ID is NCT04652739. All participants signed an informed written consent form according to the ethical committee's guidelines after full explanation about the study protocol. Patients were treated according to the principles of the modified Helsinki's code for human clinical studies, 2013 (17).

Two different treatment modalities were proposed namely lycopene and corticosteroids. Patients were randomly allocated into two groups:

Test group: Comprised ten EOLP patients who were given 10 mg of lycopene softgel capsules once daily for two months (18, 19). Capsules were purchased from Best Naturals, New Jersey, USA. The active ingredient in each capsule consists of 10 mg lycopene from natural tomato extract.

Control group: Comprised ten EOLP patients who were given 40 mg of prednisolone tablets once daily in the morning for one month, afterwards, the dose was tapered along the following month. Incremental reduction of 10 mg each week for the first three weeks, followed by 5 mg reduction in the last week, was the tapering protocol in this study (18, 20). Tablets were purchased from Sanofi-aventis, Paris, France. The active ingredient in each tablet consists of Prednisolone metasulfobenzoate sodium 31.44 mg (equivalent to 20 mg of Prednisolone).

Inclusion criteria

- Erosive oral lichen planus patients with severe, extensive and painful erythematous, erosive and/ or ulcerative lesions who are in need for systemic corticosteroid therapy (3).
- Patients from 30 to 60 years of both sexes.

Exclusion criteria

- Pregnant females and smokers.
- Patients suggestive of having lichenoid contact/drug reactions.
- Patients suffering from any systemic disease as diabetes, liver disease, renal disease, any other autoimmune or collagen disease.
- Lesions showing histological features of dysplasia.
- Patients with skin lichen planus lesions.

For all study patients, scaling and root planing were conducted and the proper oral hygiene measures were explained. Also, sharp cusps and areas of traumatization were smoothed.

Clinical assessment

Subjective assessment

Pain assessment was conducted using Visual Analogue Scale (VAS) (21). The VAS is a simple reproducible method that expresses pain severity in numerical values. Patients were instructed to mark a 100 mm line at a point equivalent to their present pain. The score was determined by measuring the distance on the line from the "no pain" anchor to the patient's mark, providing a range of scores from 0–100. A Pain-free experience was scored zero, while the worst pain was scored 100. Values were taken at baseline, after one, two, and five months from baseline.

Objective assessment

Assessment of OLP lesions was performed using the Thongprasom et al. (22) scoring index where:

Score 0: No lesion/Normal mucosa.

Score 1: Mild white striae only.

Score 2: White striae with erythematous area <1cm².

Score 3: White striae with erythematous area >1cm².

Score 4: White striae with erosive area <1cm².

Score 5: White striae with erosive area >1cm².

Each involved mucosal site was scored from 0-5 and a total score for every patient was obtained by adding the score values giving a range of scores from 0-50 with 0 representing the least severe clinical lesions presentation and 50 representing the most severe one (23). Values were taken at baseline, after one, two, and five months from baseline.

Sample size

Sample size was estimated based on previous reports about the effects of lycopene and corticosteroids in the treatment of oral lichen planus (21, 24) assuming 5 % alpha error and 80% study power. Minimum sample size was calculated to be 9 per group which was increased to 10 to make up for cases lost to follow-up (25, 26). The total sample size = number of groups × number per group = 2 × 10 = 20.

Randomization, allocation concealment and blinding

Patients meeting the eligibility criteria were assigned randomly to one of two groups using the permuted block randomization method with variable block sizes (27). An independent examiner was responsible for allocating the subjects to their groups using sealed opaque envelopes enclosing allocation codes (28). Both patients and the statistician were blind. Study investigators were not blind due to the differences in regimens of both therapeutic modalities used.

Statistical analysis

Normality was checked for all variables using descriptive statistics, plots, and normality tests. All study variables showed normal distribution, so means, standard deviations (SD) and parametric tests were used. T-test was used for comparing both groups at different time points, while repeated measures ANOVA was used for comparing different time points within the same group, followed by Bonferroni adjustment for multiple pairwise comparisons. Significance was set at 0.05. Data were analyzed using IBM SPSS for windows version 23.0.

RESULTS

Twenty patients with clinically and histopathologically diagnosed EOLP participated in the following clinical trial. The buccal mucosa was the mostly affected site. Other oral

sites as the tongue, palate, gingiva and lips were involved but less commonly.

Table 1 shows the demographic data of all patients regarding sex and age where comparisons revealed no statistically significant difference between the two studied groups.

Results of the clinical assessment revealed a statistically significant reduction in VAS and Thongprasom et al. lesion mean scores at all time points from baseline (one, two and five months) in each studied group ($p < 0.001^*$). Further comparisons between all time points in the test and control groups are shown in (Tables 1 and 2).

The overall percent change after five months of follow up was lower following treatment with lycopene than prednisolone (Figure 1). However, there was no statistically significant difference in pain and OLP severity between the test and control groups at all time points (Tables 1 and 2).

Throughout the treatment phase (two months), only one patient reported mild bloating after lycopene administration, while 50% of patients reported slight weight gain, lethargy and stomach aches following administration of prednisolone.

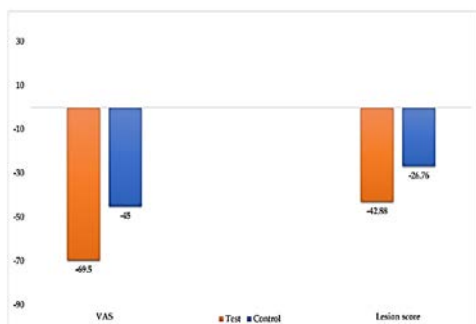


Figure 1: Percent change in VAS and lesion score in the two study groups

Table 1: Patients' demographic characteristics in both study groups.

	Lycopene group (n=10)	Corticosteroids group (n=10)	P value
Age in years (Mean ± SD)	51.90±7.72	46.60±9.81	0.14
Gender			1.00
Female: n (%)	7 (70%)	6 (60%)	
Male: n (%)	3 (30%)	4 (40%)	

Mann-Whitney and Fisher exact tests were used for age and gender comparisons, respectively.

n: Number of patients, SD: Standard deviation

Table 2: Pain using Visual Analogue Score (VAS) in the two study groups at different time points.

	Test group (n=10)	Control group (n=10)	T- test p value
	Mean ± SD		
Baseline	59.00 ± 18.53 ^a	56.00 ± 14.30 ^a	0.69
1 month	33.00 ± 14.18 ^b	28.00 ± 12.29 ^b	0.41
2 months	21.00 ± 11.97 ^b	27.00 ± 10.59 ^b	0.25
5 months	19.00 ± 17.92 ^b	29.00 ± 14.49 ^b	0.19
Percent change from baseline to 5M	-69.50 ± 24.46	-45.00 ± 27.74	0.051
Repeated measures ANOVA p value	<0.001*	<0.001*	

*statistically significant at p value < 0.05

a,b Different superscripted letters denote statistically significant differences between different time points within each group using Bonferroni adjustment for multiple pairwise comparisons.

Table 3: Thongprasom et al. lesion scores in the two study groups at different time points.

	Test group (n=10)	Control group (n=10)	T- test p value
	Mean ± SD		
Baseline	11.00 ± 4.16 ^a	10.20 ± 3.82 ^a	0.66
1 month	8.40 ± 4.14 ^b	7.80 ± 3.26 ^b	0.72
2 months	6.80 ± 3.58 ^c	7.10 ± 3.07 ^b	0.84
5 months	6.40 ± 4.45 ^{b,c}	7.60 ± 3.53 ^b	0.51
Percent change from baseline to 5M	-42.88 ± 29.72	-26.76 ± 21.08	0.18
Repeated measures ANOVA p value	0.005*	0.006*	

*statistically significant at p value < 0.05

a,b,c Different superscripted letters denote statistically significant differences between different time points within each group using Bonferroni adjustment for multiple pairwise comparisons.

DISCUSSION

Oral lichen planus is an autoimmune disease of unknown etiopathogenesis (6). The involvement of oxidative stress in its course strengthens the idea of evaluating antioxidants as effective and safe treatments in order to aid patients gain the optimal therapeutic benefits (5, 29). In the following trial, the choice of lycopene was based on the scientific background from previous studies about its multiple beneficial characteristics and usefulness in the treatment of different oral mucosal diseases as oral leukoplakia, oral cancer (30), submucous fibrosis (31) and oral lichen planus (18, 21).

At the beginning of the study, almost all patients developed varying pain intensities with severe OLP lesions (extensive erosions and ulcers with deep redness). Following the completion of treatment (two months from baseline), there was a significant downward shift in OLP signs and symptoms in both study groups (Figures 2 and 3). This was in line with a study by Kushwaha et al. (18) that reported a significant reduction in patient outcomes after administration of systemic lycopene and systemic prednisolone for the same therapeutic period. Furthermore, Saawarn et al. (21) stated that lycopene has significantly decreased VAS and lesion scores as compared to placebo following two months of treatment as well. However, both studies used lower doses of lycopene in combination with multiple antioxidants which might have acted synergistically to provide such positive results.

Observing the shift of OLP severity along the follow up visits revealed that after one month of treatment, 40 % of patients had mild lesions (almost complete resolution) in both groups. After a further month of treatment (two months from baseline), the percentage of patients manifesting mild lesions was raised to 80% and 70% in the test and control groups respectively. Moreover, pain scores revealed consistent

reduction throughout the treatment phase to almost complete relief in both groups.

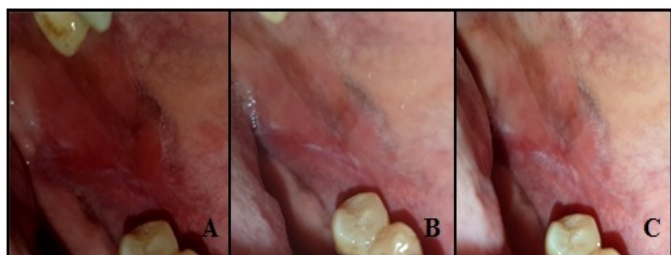


Figure 2: (A-C). OLP lesions in a case of the lycopene group at baseline and after two and five months of follow up respectively. The changes show stability of lesions after treatment termination

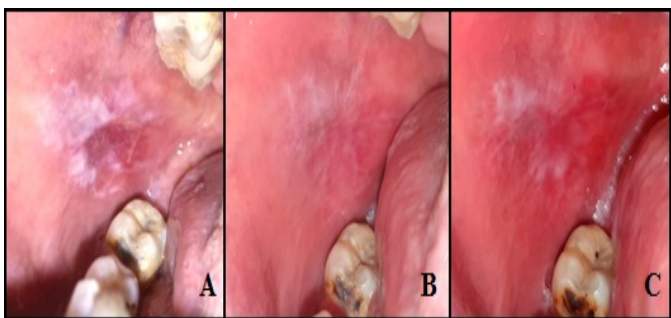


Figure 3: (A-C). OLP lesions in a case of the corticosteroids group at baseline and after two and five months of follow up respectively. The changes show relapse of lesions after treatment termination

The significant improvement of patients in the test group can be supported by the potent effects of lycopene. It enhances the antioxidant response, contributes to the synthesis of cytoprotective enzymes, up-regulates lymphocytes resistance to stress (29), besides, it bears anti-inflammatory and antifungal actions (32). Therefore, it can be postulated that lycopene plays a role in OLP regression. On the other hand, the significant changes of disease manifestations in the control group can be reinforced by the famously known actions of prednisolone in counteracting inflammation and the immune response (33).

After three months without treatment (five months from baseline), four patients of the control group have experienced an upward shift in OLP manifestations. Those patients might have been subjected to stress which triggered an exacerbation of OLP episode (34). Contrarily, in the test group, the majority of patients were stable to previous lycopene treatment with three experiencing even complete pain relief. Oxidative stress is found to promote the pain pathway (35). The potency of lycopene in reversing the oxidative damage caused by reactive intermediates might have influenced those positive effects on OLP symptoms.

The present trial did not show a significant difference between the test and control groups at all time intervals. Conversely, Kushwaha et al. (18) noted a statistically significant difference between the lycopene and prednisolone groups as regards the lesion scores only and after two months of treatment, with prednisolone being of lower mean score values. This may be due to the different study designs followed by both trials.

Despite the promising effects that lycopene revealed, further studies of larger sample size to evaluate the effects of different formulations, doses and regimens of lycopene in OLP are highly recommended.

CONCLUSION

Lycopene is an effective and safe antioxidant that can be used for the treatment of erosive oral lichen planus.

Conflict of interest

The authors declare that they have no conflicts of interest.

Acknowledgement

The authors would like to thank Nourhan M Aly, Assistant Lecturer of Dental Public Health, Faculty of Dentistry, Alexandria University, Egypt, for making the statistical analysis of the trial.

REFERENCES

1. Rajendran R, Sivapadasundaram B. Shafer's Textbook of Oral Pathology, 7th ed. New Delhi, India: Elsevier; 2012.
2. Roopashree MR, Gondhalekar RV, Shashikanth MC, George J, Thippeswamy SH, Shukla A. Pathogenesis of oral lichen planus--a review. *J Oral Pathol Med.* 2010;39:729-34.
3. Au J, Patel D, Campbell JH. Oral lichen planus. *Oral Maxillofac Surg Clin North. Am.* 2013;25:93-100.
4. Ergun S, Troşala SC, Warnakulasuriya S, Özel S, Önal AE, Ofluoglu D, Güven Y, Tanyeri H. Evaluation of oxidative stress and antioxidant profile in patients with oral lichen planus. *J Oral Pathol Med.* 2011;40:286-93.
5. Rekha VR, Sunil S, Rathy R. Evaluation of oxidative stress markers in oral lichen planus. *J Oral Maxillofac Pathol.* 2017;21:387-93.
6. Azizi A, Farshchi F. Comparison of salivary and plasma antioxidant levels in lichen planus patients and healthy subjects. *J Oral Pathol Med.* 2012;41:524-6.
7. Williams DM. Clinical Pharmacology of Corticosteroids. *Respir Care.* 2018;63:655-70.
8. Patil RP, Khandelwal S, Sinha N, Kaswan S. Treatment modalities of oral lichen planus: an update. *J Oral Diag.* 2016;01:e3.
9. Story EN, Kopec RE, Schwartz SJ, Harris GK. An update on the health effects of tomato lycopene. *Annu Rev Food Sci Technol.* 2010;1:189-210.
10. Milani A, Basirnejad M, Shahbazi S, Bolhassani A. Carotenoids: biochemistry, pharmacology and treatment. *Br. J. Pharmacol.* 2017;174:1290-324.
11. Krinsky NI, Johnson EJ. Carotenoid action and their relation to health and disease. *Mol. Aspects Med.* 2005;26:459-516.
12. Böhm F, Edge R, Truscott TG. Interaction of dietary carotenoids with activated singlet oxygen (1O_2) and free radicals potential effects for human health. *Mol Nutr Food Res.* 2012;56:205-216.
13. Bacanlı M, Başaran N, Başaran AA. Lycopene: Is it Beneficial to Human Health as an Antioxidant?. *Turk J Pharm Sci.* 2017;14:311-18.
14. Sonune S, Tupsakhare S, Kandalgaonkar S, Patil K, Gabhane M, Saraf K. Lycopene: potent antioxidant for oral

- pre-malignancy and oral cancer. *European J Biomed Pharm Sci.* 2015;2:135-44.
15. Schulz KF, Altman DG, Moher D, CONSORT Group. CONSORT 2010 statement: updated guidelines for reporting parallel group randomised trials. *Int J Surg.* 2011;9:672-7.
 16. van der Meiji EH, van der Waal I. Lack of clinicopathological correlation in the diagnosis of oral lichen planus based on the presently available diagnostic criteria and suggestions for modifications. *J Oral Pathol Med.* 2003;32:507-12.
 17. World Medical Association. World Medical Association Declaration of Helsinki. Ethical principles for medical research involving human subjects. *JAMA.* 2013;310: 2191-4.
 18. Kushwaha RP, Rauniar GP, Rimal J. Comparative study of the efficacy of lycopene versus prednisolone in the management of oral lichen planus-a randomized, double blind clinical trial. *World J Pharm Pharm Sci.* 2017;6:1103-15.
 19. Kaur G, Sandal A, Dhillon NS. Lycopene and human health-A review. *Agric Rev.* 2017;38:282-9.
 20. Kini R, Nagaratna DV, Saha A, Praveen BN. Therapeutic management of oral lichen planus: A review for the clinicians. *World J Dent.* 2011;2:249-53.
 21. Saawarn N, Shashikanth MC, Saawarn S, Jirge V, Chaitanya NC, Pinakapani R. Lycopene in the management of oral lichen planus: a placebo-controlled study. *Indian J Dent Res.* 2011;22:639-43.
 22. Thongprasom K, Luangjarmekorn L, Sererat T, Taweessap W. Relative efficacy of fluocinolone acetonide compared with triamcinolone acetonide in treatment of oral lichen planus. *J Oral Pathol Med.* 1992;21:456-8.
 23. Gobbo M, Rupel K, Zoi V, Perinetti G, Ottaviani G, Di Lenarda R et al. Scoring systems for Oral Lichen Planus used by differently experienced raters. *Med Oral Patol Oral Cir Bucal.* 2017;22:e562-71.
 24. El Shenawy HM, Eldin AM, Nasry SA. Management of pain in oral lichen planus patients: a comparative pilot study. *Bull Natl Res Cent.* 2018;42:15.
 25. Chow SC, Shao J, Wang H. *Sample Size Calculations in Clinical Research.* 2nd ed. Boca Raton, FL : CRC Press; 2018.
 26. Hylown Consulting LLC. *Power and Sample Size Calculator.* 2013. Available at <http://powerandsamplesize.com/Calculators/Compare-2-Means/2-Sample-Equality>.
 27. Schulz KF, Grimes DA. Generation of allocation sequences in randomised trials: chance, not choice. *Lancet.* 2002;359:515-9.
 28. Schulz KF, Grimes DA. Allocation concealment in randomised trials: defending against deciphering. *Lancet.* 2002;359:614-8.
 29. Nagarajappa AK, Pandya D, Sreedevi, Ravi KS. Role of Free Radicals and Common Antioxidants in Oral Health, an Update. *BJMMR.* 2015;9:1-12.
 30. Singh M, Krishanappa R, Bagewadi A, Keluskar V. Efficacy of oral lycopene in the treatment of oral leukoplakia. *Oral Oncol.* 2004;40:591-6.
 31. Selvam NP, Dayanand AA. Lycopene in the management of Oral submucous fibrosis. *Asian J Pharm Clin Res.* 2013;6:58-61.
 32. Choi H, Lee DG. Lycopene induces apoptosis in *Candida albicans* through reactive oxygen species production and mitochondrial dysfunction. *Biochimie.* 2015;115:108-15.
 33. Ramamoorthy S, Rheum JA. Corticosteroids-Mechanisms of Action in Health and Disease. *Dis Clin North Am.* 2016;42:15-31.
 34. Sandhu SV, Sandhu JS, Bansal H, Dua V. Oral lichen planus and stress: An appraisal. *Contemp Clin Dent.* 2014;5:352-356.
 35. Salvemini D, Little JW, Doyle T, Neumann WL. Roles of reactive oxygen and nitrogen species in pain. *Free Radic Biol Med.* 2011;51:951-66.